



Metastatic pulmonary carcinomas in cats ('feline lung–digit syndrome'): further variations on a theme

Elizabeth Thrift¹, Chris Greenwell², Audra-Lynne Turner³, Andrea M Harvey², Donna Maher⁴ and Richard Malik⁵

Journal of Feline Medicine and Surgery Open Reports
1–8

© The Author(s) 2017

Reprints and permissions:

sagepub.co.uk/journalsPermissions.nav

DOI: 10.1177/2055116917691069

journals.sagepub.com/home/jfmsopenreports

This paper was handled and processed by the European Editorial Office (ISFM) for publication in *JFMS Open Reports*



Abstract

Case series summary The aim of this retrospective case series was to describe seven cases where cats with primary lung tumours were presented because of metastases to extra-pulmonary sites ('feline lung–digit syndrome'). Specifically, we wanted to emphasise less typical case descriptions where tumour emboli resulted in lesions developing in the musculature (including the muscles of the head), skin or distal aorta.

Relevance and novel information The cases are presented to increase clinical awareness of this entity in feline practice, especially when characteristic combinations of clinical signs are present. When clinicians have a high index of suspicion for these presentations, radiology (thorax and digits) or ultrasound (distal aorta), combined with collection of fine needle aspirate specimens for cytology, are usually sufficient to secure a definitive diagnosis. Novel information in this series includes CT and MRI findings from some cases. Typically, needle aspiration or biopsy targeting the skin, digits and lesions in musculature is far easier compared with sampling the primary tumour site in the lungs. The differential diagnosis and investigation of multiple digital lesions is also considered.

Accepted: 13 December 2016

Introduction

Feline lung–digit syndrome (FLDS) refers to a clinical entity where primary lung tumours (often bronchogenic adenocarcinoma), which may be clinically silent in themselves, present because of metastatic lesions in one or more digits.^{1,2} Although Moore and Middleton first reported primary lung tumours metastasising to the digits of three cats in 1982,³ this entity was not well recognised until a subsequent and more substantial series of 30 cases was published in the *Journal of the American Animal Hospital Association*.⁴ The authors coined the term 'lung–digit syndrome', thereby giving people a more accessible moniker or 'generic illness script' with which to remember the entity.⁵ Subsequently, variations of the theme were reported, with some cats having tumour emboli mimicking aortic thromboembolism due to primary cardiac disease,⁶ some cats having vertebral metastasis resulting in back pain and/or transverse myelopathy, other cats having ocular metastasis, while still other cats had nodules in skeletal muscle instead of, or as well as, digital involvement.^{2,4}

This report describes seven different FLDS cases, including 'classical cases' where the diagnosis was straightforward and some atypical or cryptic cases. The index case is presented in detail, as it was the first such case encountered by the first author (at the beginning of

¹Animal Referral Hospital, 250 Parramatta Road, Homebush West, NSW, Australia

²Small Animal Specialist Hospital, 1 Richardson Place, North Ryde, NSW, Australia

³Purrfect Health, 23 Church Street, Rickmansworth, Hertfordshire, UK

⁴Gungahlin Veterinary Hospital, 21 Crinigan Circle, Gungahlin, ACT, Australia

⁵Centre of Veterinary Education, B22, The University of Sydney, NSW, Australia

Corresponding author:

Elizabeth Thrift BVSc (Hons), MANZCVS (Small Animal Internal Medicine), 250 Parramatta Road, Homebush West, NSW 2140, Australia

Email: e.thrift@arhvets.com



Creative Commons Non Commercial CC-BY-NC: This article is distributed under the terms of the Creative Commons

Attribution-NonCommercial 3.0 License (<http://www.creativecommons.org/licenses/by-nc/3.0/>) which permits non-commercial use, reproduction and distribution of the work without further permission provided the original work is attributed as specified on the SAGE and Open Access pages (<https://us.sagepub.com/en-us/nam/open-access-at-sage>).

her training programme); in retrospect this case was not diagnosed in a timely manner and in turn impacted adversely on the welfare of the patient. The remaining cases, where the diagnosis was reached more quickly, or where the authors assisted colleagues through e-mail or telephone consultations, have been presented more circumspectly.

Indeed, the suboptimal management of the first case provided the impetus for the authors to present the further cases – to demonstrate that, with a high index of suspicion, the diagnosis can be reached much more quickly and usually with much less expenditure of client financial resources. The intention of this case series is to increase the index of suspicion for this syndrome among small animal clinicians when certain characteristic clinical features (clinical stigmata) are present, thereby preventing unnecessary digital amputations and muscle biopsies and extensive, expensive diagnostic investigations. If the clinician has this entity high on the list of diagnostic possibilities, in most cases chest radiographs and needle aspirates of digital swelling or intramuscular nodules are sufficient to secure a timely, definitive and inexpensive diagnosis. Finally, other disease processes that cause multiple digital involvement, especially infectious diseases, are discussed briefly, as these have a far better prognosis for control or cure.

Case series description

Case 1

A 12-year-old, spayed domestic shorthair (DSH) cat presented for acute hindlimb paralysis. Physical findings included hypothermia (36.3°C), a soft systolic parasternal heart murmur (grade 1/6), tachypnoea (60 breaths/min), pale pink mucous membranes, cool extremities, cyanosis of hindlimb footpads and bilaterally absent femoral pulses. On neurological testing, deep pain was absent and no withdrawal reflexes could be elicited in either hindlimb. Systolic blood pressure was 168 mmHg using a size 2 cuff on the left forelimb and a Parks Doppler device. Pulsatile flow in the proximal and distal hindlimbs was undetectable using the Doppler instrument in both distal hindlimbs and a pulse oximeter failed to give a reading. Haematology demonstrated monocytopenia ($0.25 \times 10^9/l$; reference interval [RI] $0.3\text{--}2.0 \times 10^9/l$), eosinopenia ($0.03 \times 10^9/l$; RI $0.1\text{--}1.49 \times 10^9/l$) and a non-regenerative anaemia (haematocrit 0.19 l/l; RI 0.37–0.55). Serum biochemistry revealed hypokalaemia (3.1 mmol/l; RI 3.5–5.8) and hyperglycaemia (11 mmol/l; RI 4–8 mmol/l). All these findings were considered non-specific and consistent with stress and chronic disease.

The physical findings were consistent with aortic thromboembolism (ATE). The cat was hospitalised and treated with cage rest, clopidogrel (18.75 mg PO q24h), furosemide (5 mg PO as a single dose) and benazepril (2.5 mg PO q24h) due to possible underlying cardiac

disease. Buprenorphine (0.05 mg transmucosally q8h) was administered to provide analgesia. Thoracic radiographs failed to show cardiomegaly (vertebral heart score 7.3; RI 7.2–7.8)⁷ and no pulmonary mass lesions were evident. Echocardiography was unremarkable, with the left atrium and auricle both normal in size. Myocardial disease was not evident. A reason for the soft murmur and the embolus at the aortic trifurcation, visualised subsequently using abdominal ultrasonography, was not apparent. Over the following 4 days, the cat's clinical signs improved and it regained some voluntary movement in both hindlimbs. The cat was discharged on clopidogrel, benazepril and buprenorphine. Benazepril was included as there were concerns about subtle underlying myocardial disease, despite the normal echocardiographic study.

Three weeks after initial presentation, the cat returned for review and a repeat echocardiogram. The owners elected not to have a review sooner because of the cat's bright demeanour, even though neurological status was possibly unsatisfactory from a welfare standpoint. There was absent motor and sensory function in, and neurogenic muscle atrophy and contracture of, both distal hindlimbs. Areas of necrosis were evident on each hindlimb and both hocks were hyperextended (Figure 1). The right hindlimb was more severely affected, with skin necrosis extending to the mid-metatarsus. A heart murmur could no longer be auscultated. Repeat echocardiography showed marginally reduced fractional shortening (36.0%; RI 40–67%) but was otherwise unremarkable.

The cat was otherwise well in itself, with a bright demeanour and normal appetite. The owners felt the cat's quality of life was satisfactory, although this was debatable. On discussion with the owner, partial amputation of the right hindlimb at the level of the tarsometatarsal joint and permanent bandaging of the stump, were considered to manage the more severe lesions present on that limb. With the cause of the aortic thromboembolism unclear, whole body CT examination was recommended to assess for underlying neoplasia, given the absence of any lesions on previous thoracic radiographs. The CT images were interpreted by a specialist radiologist via a remote telemedicine service. The study demonstrated a focal lesion in the caudomedial musculature of the left hindlimb (Figure 2). Diagnostic possibilities included necrotising myositis, neoplasia, abscessation and necrosis secondary to vascular compromise. Two soft tissue pulmonary masses associated with the right caudal bronchus and extending into the right caudal and accessory lung lobes were also identified (Figure 3). The lung lesions were reported to have CT characteristics consistent with bronchoalveolar carcinoma or pulmonary infarcts.⁸ Although the broad-based appearance of the lesions were thought to be more suggestive of the latter by the radiologist, the presence of lung lesions, muscle lesions and a history of ATE were most consistent with

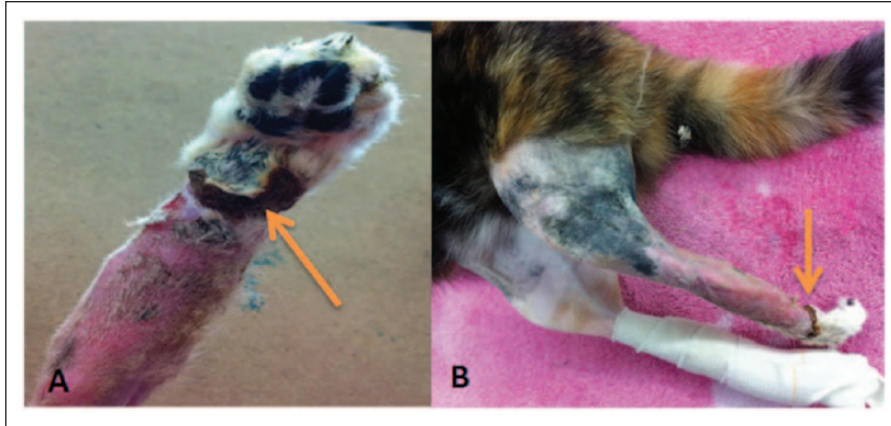


Figure 1 Case 1. (a) Appearance of the distal right hindlimb prior to amputation; plantar aspect. (b) Appearance of both hindlimbs immediately prior to amputation. Note the neurogenic muscle atrophy and hindlimb contracture. The orange arrows in (a) and (b) highlight the region of skin necrosis

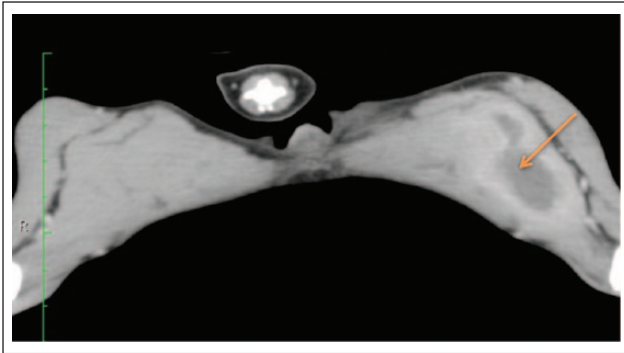


Figure 2 CT image of a metastatic lesion (arrow) in the caudomedial musculature of the left hindlimb of case 1. Note the marked atrophy of the hindlimb musculature

atypical lung–digit syndrome.⁶ Neither pulmonary arterial emboli nor distal aortic emboli could be visualised in the CT scans after intravenous iohexol administration.

The cat returned 1 week later for review. There was a new firm, soft tissue mass within the left gastrocnemius muscle (1–2 cm diameter) and a firm mass in the left semimembranosus/semiotendinosus muscle group (2–3 cm diameter). Incisional wedge biopsies of both soft tissue masses in the left hindlimb were performed for diagnostic purposes and under the same anaesthesia partial right hindlimb amputation was also performed to help preserve quality of life for the cat. Both biopsies were of similar histologic appearance with epithelial cell proliferation and the occasional formation of crude glandular structures, consistent with an adenocarcinoma (either metastatic pulmonary adenocarcinoma or an alternative primary site).

A diagnosis of likely pulmonary adenocarcinoma with metastases to the left hindlimb (FLDS) and aortic trifurcation was made. Four weeks after the partial limb amputation, the cat's quality of life deteriorated. Despite

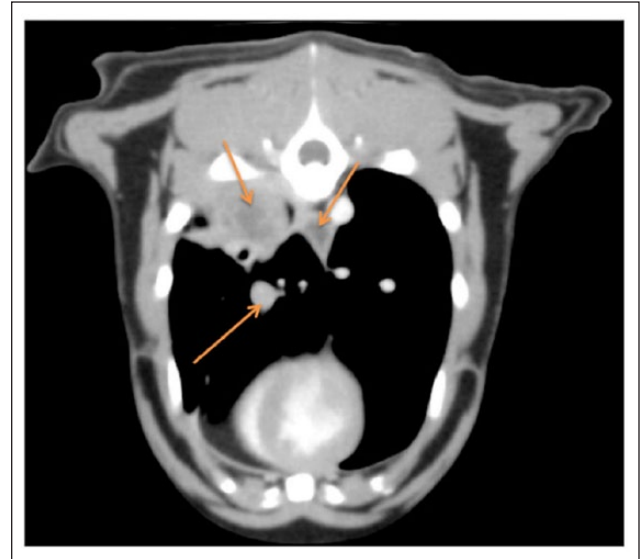


Figure 3 Transverse CT slice of the thorax of a cat with suspected multiple pulmonary carcinomas (case 1). Note the pulmonary masses (orange arrows), some of which are wedge-shaped, consistent with tumour emboli causing pulmonary infarcts

a brief and unsuccessful treatment trial of prednisolone (5mg PO q12h), the cat was euthanased 12 weeks after initial presentation. With the benefit of hindsight, it would have been more appropriate to collect fine needle aspirates from the nodular muscle lesions, and then counsel the owners on the poor outcome of any planned surgical interventions.

Case 2

An 11-year-old, spayed DSH cat presented for left hindlimb lameness. Physical examination was unremarkable, except for a diffuse soft tissue swelling of the

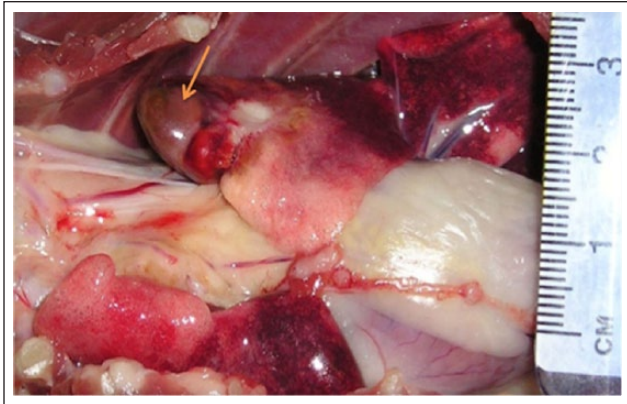


Figure 4 Necropsy photograph of the pulmonary lesions in case 2. The cranial tip of the left cranial lung lobe is dark brown (arrow) and sharply demarcated from normal tissue by a firm, irregular, pale tan, depressed lesion

left plantar metatarsus. A lateral radiograph of the affected limb showed soft tissue swelling on the plantar surface of the metatarsus. Meloxicam (0.05 mg/kg PO for 5 days) was prescribed and the lameness improved. The cat re-presented 3 weeks later for recurrence of lameness and anorexia. The left hindlimb swelling had returned but now extended proximally above the hock. Multiple variably sized, firm swellings were present within the musculature of the left thigh and also in the muscles immediately dorsal to both scapulae. A raised, red, well-defined mass (6 mm diameter) was present in the left upper lip within the bed of a vibrissa. At the time of intubation, a 5 mm diameter ulcer was present at the junction of the soft and hard palate, while a pale tan, multinodular mass infiltrated the length of the soft palate. Representative punch and wedge biopsies were taken from nodules in the left thigh and above the right scapula (but not from the palate). The biopsy specimens were all of similar appearance microscopically, the diagnosis being invasive ductal carcinoma. Further investigations were offered but the cat was depressed and anorexic, and the owners requested euthanasia.

At necropsy, within the thorax, there were multiple white nodules (2–3 mm diameter) on both sides of the caudal mediastinum and on the chest walls. A few variably sized, pale tan, depressed focal lesions were scattered on the pleural surfaces of several lung lobes (Figure 4). In addition, three variably sized firm smooth grey masses were found deep to the biceps femoris muscle. Two small masses of similar character were present on the caudal aspect of the right scapula and two larger masses were present beneath the trapezius muscles. A diagnosis of a disseminated poorly differentiated adenocarcinoma of unknown histogenesis was made. In this case the primary site could not be determined with certainty. Microscopy could not provide the definitive site of origin, but due to the variation in histologic pattern

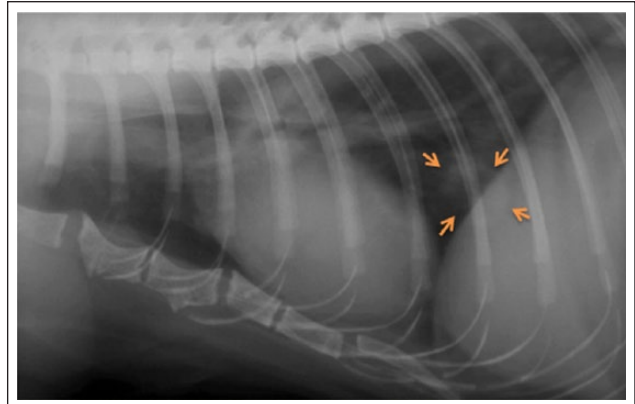


Figure 5 Plain lateral thoracic radiograph of case 3, showing a well-defined focal radiodensity in the caudal lung field (arrows)

throughout the respiratory system, the lungs and/or nasal cavity (ie, adjacent to the palate) seemed the most likely primary site.

Case 3

An 11-year-old, castrated DSH cat (interestingly, the offspring of case 2) presented with a left hindlimb lameness. No physical abnormalities were evident except for pain on palpation of the phalanges. The lameness did not improve with rest and analgesia (meloxicam 0.05 mg/kg PO). Plain radiographs of the digits and thorax revealed lysis of P3 of the third and fourth digits of the left hindlimb and a focal well-defined density in the right caudal lung field (Figure 5). The findings were consistent with a pulmonary tumour with metastasis to the left hindlimb digits. The owners elected palliative care with opioid analgesia. The cat deteriorated rapidly and further examination revealed additional lesions affecting the upper left eyelid and cheek, a palpable increase in size of the digital lesions and popliteal lymph node enlargement. The owners elected euthanasia. Necropsy and histological examinations confirmed a primary bronchogenic carcinoma with digital metastases.

Case 4

A 12-year-old, spayed DSH cat presented for sudden-onset hindlimb paresis. Physical abnormalities consisted of a firm swelling of the fifth digit of the left forelimb and the third digit of the right forelimb. Blood results revealed a severe non- or pre-regenerative anaemia and a marked coagulopathy. Thoracic radiographs did not reveal an obvious pulmonary mass. Radiographs of the digits revealed osteolysis of the affected digits (P3). Needle aspirates from the digital swellings demonstrated multiple cytological features of malignancy, including well-differentiated respiratory epithelial cells, suggestive of metastatic pulmonary neoplasia.

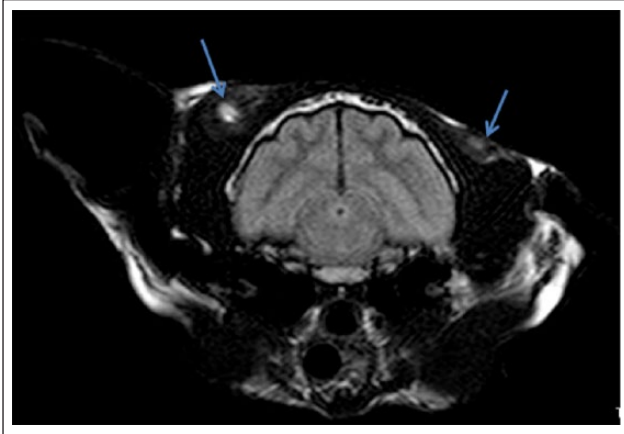


Figure 6 Post-gadolinium contrast transverse fluid-attenuated inversion recovery (FLAIR) magnetic resonance image from case 7, revealing fluid-filled lesions (blue arrows) in the temporalis muscles with surrounding oedema

Case 5

A 13-year-old, castrated DSH cat presented with a firm subcutaneous mass, lethargy of recent onset and reduced appetite. Physical examination revealed multiple nodules within the proximal musculature of the hindlimbs, a firm nodule (10 mm diameter) in the dorsal cervical musculature and multiple nodular masses in the abdominal wall. Thoracic radiographs revealed a soft tissue density (24 mm diameter) cranio-lateral to the cardiac silhouette. Wedge biopsies from the intramuscular nodules (left hindlimb, abdominal wall and cervical region) were obtained. The histological diagnosis was multifocal metastatic adenocarcinoma in all three locations.

Case 6

An 8-year-old, castrated DSH cat presented for inappetence. The only abnormality detected by serum biochemical testing was an elevated creatine kinase (CK) activity (966 U/l; RI <400 U/l). Thoracic radiographs revealed a possible lung mass. The patient re-presented 2 weeks later with acute onset hindlimb paresis associated with poor femoral pulses. The CK activity was now 42,939 U/l, consistent with muscle injury, presumably due to ischaemia of the poorly perfused hindlimbs. Further thoracic radiographs obtained 1 week later (3 weeks after initial presentation) demonstrated a discrete round radiodensity caudal to the cardiac silhouette. The most likely diagnosis was primary pulmonary neoplasia with tumour embolism at the aortic trifurcation. Ultrasonographic findings included difficulty tracing the abdominal aorta caudally, with the suspicion of an aortic 'saddle' embolus. Echocardiography demonstrated equivocal thickening of the interventricular septum and left ventricular free wall without dilation of the left atrium. A neoplastic embolus was the presumptive diagnosis. Physical examination subsequently

revealed thickening of the distal quadriceps muscle although no distinct nodule could be palpated. Further tissue sampling was not performed.

Case 7

A 12-year-old, castrated DSH cat presented with inappetence and behavioural changes. The cat was poorly responsive, had reduced conscious proprioception in both hindlimbs and appeared disoriented. Systolic blood pressure measured using a Doppler device was within limits of normality. A cryptococcal antigen test was negative. Testing for toxoplasmosis revealed an IgG titre of 128 and a negative IgM titre, consistent with previous exposure. An MRI scan of the head did not reveal any brain abnormalities. Nodular lesions were, however, evident within the temporalis muscle (Figure 6) and the cervical paraspinal musculature. Thoracic radiographs taken after the MRI scan revealed a likely pulmonary mass within the right middle or right caudal lung lobe. A subcutaneous flank mass was detected subsequently. Needle aspiration of the flank mass and right cervical paraspinal muscle lesions revealed carcinoma cells, which were considered to be metastatic from an unconfirmed primary site, likely the lung.

Discussion

Pulmonary carcinoma with widespread metastases to distal muscles and bones (digits) is a devastating disease to diagnose because the prognosis is so poor for most affected feline patients. This is often compounded by more cryptic presentations, such as aortic tumour thromboembolism or involvement of the eye, which result in a cat near the end of its life being subjected to expensive and sometimes painful investigations, which have no impact on the natural course of the disease. The purpose of this case series is to increase the index of suspicion for this disease for the average small animal clinician and provide recommendations that will result in a speedy and inexpensive diagnosis, without the need for digital amputation or deep tissue biopsies. For example, in case 1, the case we consider in the greatest depth, fine-needle aspiration of one of the intramuscular lesions would have probably represented a simple test that could provide a definitive diagnosis with minimal expense. Had this been undertaken, much cost and unnecessary investigation and trauma might have been avoided. At the end of this article we recommend a mnemonic that will perhaps increase the 'availability heuristic' for this diagnosis. Other disease conditions affecting the digits, including multiple digits, will be touched on, as many of these conditions have an infectious aetiology and a far more favourable prognosis than pulmonary carcinoma with haematogenous dissemination.

By definition, FLDS is caused by a primary lung tumour (often a bronchogenic adenocarcinoma) with

metastatic lesions within one or more digits.^{1,2} Typically, physical findings and signs suggestive of a primary lung tumour (eg, dyspnoea, coughing, pleural effusion) are absent, which is counterintuitive. A similar syndrome occurs in humans, where subungual metastases are most commonly the result of primary lung tumours.⁹ In a small proportion of reported FLDS cases, including the seminal report,³ the site of metastasis includes skeletal muscle, rather than digital bone (P3). For example, Langlais and colleagues described a cat with a pulmonary adenocarcinoma that presented for non-specific signs, a cough and an abnormal gait.¹⁰ On examination, four soft tissue lesions, subsequently shown to be metastases, were evident in both fore- and hindlimbs. At necropsy, the lesion in the semimembranosus muscle was larger than the primary tumour in the left middle lung lobe.

Our suspicion is that metastasis to muscle occurs more commonly than the literature reflects, because it has not been given a descriptive title as evocative as FLDS. As a result, the generic illness script is less accessible to the clinician. Likewise, metastases to other sites such as the aortic trifurcation,⁶ vertebrae,¹¹ skin (this report) and eye² do not immediately trigger an accessible generic illness script that focuses the clinician's attention on the possibility of an underlying primary lung tumour. The disparate tissues in which metastases are observed may have in common a pattern of vascular perfusion with tortuosity or narrowing that favours small tumour emboli to lodge and give rise to nodular secondary tumours.^{3,11} Many experienced feline physicians therefore recommend obtaining thoracic radiographs in all cats without obvious localisable signs, because of the propensity of cats to 'hide' signs of intrathoracic disease, whether it is located in the lungs, mediastinum or pleural space.

In order to achieve a definitive diagnosis of FLDS, cytology or histology needs to be performed on both the primary pulmonary and metastatic lesions. However, the reality of practice is that the nodular lesions in digits or muscles are more readily sampled by either aspiration or core/wedge biopsy than lung lesions, which can be situated in relatively inaccessible locations. Therefore, a presumptive diagnosis is typically made by aspiration or biopsy of lesions in peripheral locations, typically within digits or muscles. Histological or cytological evidence provided a definitive diagnosis or was strongly suggestive of metastatic carcinoma in five of the seven cats in the present series, while in the two remaining cases circumstantial evidence for this pathoetiology was compelling.

CT is more sensitive than radiography at detecting pulmonary neoplasia.¹² This was well illustrated in case 1, where the pulmonary mass was not evident in chest films (which included dorsoventral and both lateral

projections) but was readily observed with thoracic CT (albeit 3 weeks later). Radiography is, however, sufficient for characterisation of digital lesions, with metastatic tumours typically demonstrating osteolysis of P3, intra-articular invasion and possibly involvement of P2.² Muscle lesions can often be palpated, especially when nodules are large and present within the limb musculature, making further imaging unnecessary. Conversely, some nodules are missed on routine physical examination but picked up using cross-sectional imaging (CT or MRI), as exemplified by case 7, where metastases were detected in the temporalis muscle during an MRI scan directed at the central nervous system.

Primary lung tumours in the cat are considered rare, with adenocarcinomas being the most common primary pulmonary tumour in this species.¹ Van der Linden-Sipman and van den Ingh noted 88% of carcinomas in digits are the result of metastases from a primary pulmonary carcinoma;¹³ thus, FLDS should be considered in cats with digital lesions in which there is lysis of P3. However, other causes of digital disease must also be considered and investigated, such as staphylococcal bacterial paronychia, and diseases caused by soil organisms (saprobes) such as *Nocardia* species,¹⁴ *Mycobacterium* species (eg, feline leprosy syndrome)¹⁵ and a variety of fungi including pigmented filamentous or yeast-like species.¹⁶ Goldfinch and Argyle note that neoplasia is diagnosed in one in eight nail and nail bed disorder cases.² Furthermore, approximately one in six amputated feline digits have evidence of metastatic disease (with the primary location not [yet] identified).² The combination of a digital lesion (especially when diagnostic tests have failed to identify an infectious aetiology) with a pulmonary lesion is very suggestive of FLDS, as infectious diseases rarely cause lesions in both the digits and the lungs.

ATE is a well-recognised condition in cats. It generally occurs in patients with substantial underlying cardiac disease, where dilatation of the left atrium (and auricle), possibly combined with an underlying hypercoagulable state, causes a clot to form in the auricle, which subsequently detaches to lodge distally, most commonly at the aortic trifurcation.¹⁷ The exact pathomechanism by which metastatic neoplasia causes ATE in cats is not known, but most likely a small tumour embolus detaches from the primary lung neoplasm and travels to the heart via pulmonary veins, and thence down the aorta, lodging when the luminal diameter is reduced at its caudal extent where the external iliac arteries arise. Presumably smaller tumour emboli continue further along the arterial tree, before becoming lodged in small arterioles supplying skin, bone or muscle, typically in distal extremities. Moore and Middleton first proposed that the delicate structure and conformation of the pulmonary veins in cats facilitates carcinoma invasion and

hence the development of tumour emboli.³ Paraneoplastic hypercoagulability potentially plays a supporting role, permitting platelets and later fibrin to be deposited on top of the tumour embolus.¹⁸ Furthermore, secondary thrombosis in the vicinity of the tumour embolus likely results in activation of local mechanisms resulting in shutdown of collateral circulation. In a retrospective study by Smith and colleagues of 127 cats with ATE, neoplasia was the second most common cause of feline ATE (after myocardial disease), occurring in 6% of cases,¹⁷ and pulmonary carcinoma was the commonest neoplastic condition.^{6,18,19} The literature suggests that acute onset of hindlimb ischaemia occurs as the primary presenting complaint of a systemic disease process in about three-quarters of ATE cases,^{19,20} perhaps because cats in general are good at hiding the signs of many disease processes, but not ischaemic neuromyopathy, because it is so intensely painful.

The report by Moore and Middleton consisted of two cases with cogent similarities with our index case.³ One cat presented with right forelimb lameness referable to a metastatic lesion in the distal carpal bones and a subsequent metastasis in the left biceps femoris. The second presented with swelling of the third digit of the left forelimb, a further lesion in the soft tissues of the prescapular region, and subsequently numerous lesions in the quadriceps. Similar findings were later documented in a series of 64 cats with digital carcinomas.¹³ Of the 64 cats documented, all presented with a primary complaint of 'painful digits'. A total of 56 cats had metastases of a pulmonary carcinoma in the digits, with many cats also having lesions within the skin and/or muscles. Only eight cats had primary squamous cell carcinomas (SCCs) of the digit or multiple digits. Therefore, most carcinomas found within the digits of cats are likely to be metastases from a primary pulmonary carcinoma, and even SCC may arise in this fashion from a primary focus in the lung. Sykes⁶ discusses a very similar case to case 1, but with a slightly different chronology: a cat with a history of coughing was diagnosed with a pulmonary mass in the left caudal lung lobe. One month later, the cat developed signs consistent with distal aortic thromboembolism. Two weeks later, the cat's left hindlimb was amputated due to severe necrosis and sloughing of the skin. Histopathological examination demonstrated aggregates of anaplastic epithelial cells, consistent with tumour emboli, within arteries in the amputated hindlimb. Cases 2 and 3 in this series are somewhat unique in that both cats were closely related, perhaps suggesting there was either a common genetic factor predisposing to pulmonary neoplasia, or a common environmental factor (such as cigarette smoke).²¹

Pulmonary adenocarcinoma is not considered to be a chemotherapy-responsive disease in the cat.²¹

Accordingly, treatment of cats with FLDS using chemotherapy has not been well documented and the disease is considered to have a very poor prognosis. There is limited literature regarding chemotherapy (as adjuvant treatment post-pneumonectomy) for cats with primary pulmonary carcinoma without evidence of metastatic disease.²¹ Further areas of possible research include tyrosine kinase inhibitors,²² given their potential in the palliative treatment of other carcinomas, as well as non-steroidal anti-inflammatories such as piroxicam,^{23,24} which also have been shown to have some activity against certain carcinomas and seems generally well tolerated by feline oncology patients.

Conclusions

In feline patients with non-cardiogenic ATE and/or digit lesions, FLDS should be placed high on the list of diagnostic differentials. Accordingly, thorough palpation of the musculature (limbs, abdominal wall and muscles of mastication), followed by examination of all digits and three-view thoracic radiography, is mandatory. If a serum biochemical profile is available, scrutinise the CK activity, as its elevation may be a marker for metastases of occult tumour emboli to skeletal muscle. Thoracic radiographs represent a cost-effective screening tool when FLDS is part of the differential diagnosis, even though CT is more sensitive and potentially faster (using a Perspex restraining device).²⁴ If the index of suspicion is sufficiently high and no lesions are seen in routine orthogonal chest radiographs (such as case 1), then CT of the thorax with and without iodinated contrast medium should be considered.

Because FLDS sometimes involves muscles, spine or ocular structures rather than digits, and can result in tumour emboli mimicking cardiogenic aortothromboembolism, we propose the aide-mémoire muscle/ocular/digit/aorta/lung syndrome (MODAL syndrome) to remind clinicians that the metastatic manifestations of primary lung tumours in cats can variously involve digits, eye, muscle, skin, bone and distal aorta. Pathophysiologically, we suspect that the size of the tumour emboli determines the clinical presentation, with the largest emboli lodging in the aortic trifurcation, small emboli travelling further to the arteries subserving skeletal muscles, while the smallest tumour emboli reach the digits. The experience of our index cases and the first two cases in the series recently reported by van Stee and colleagues²⁵ suggest that any surgical intervention in cases with aortic involvement is completely unjustified, as survival is short despite removal of the primary lung tumour. The value of lobectomy in concert with digital amputation of all demonstrable lesions has not been determined, although we suspect that undetected digital or muscular metastatic disease would develop subsequently.

Funding The authors received no financial support for the research, authorship, and/or publication of this article.

Conflict of interest The authors declared no potential conflicts of interest with respect to the research, authorship, and/or publication of this article.

References

- Sugiyama H, Maruo T, Shida T, et al. **Clinical findings in lung-digit syndrome in five cats.** *J Jpn Vet Cancer Soc* 2010; 1: 8–13.
- Goldfinch N and Argyle D. **Feline lung-digit syndrome: unusual metastatic patterns of primary lung tumours in cats.** *J Feline Med Surg* 2012; 13: 202–208.
- Moore AS and Middleton DJ. **Pulmonary adenocarcinoma in three cats with non-respiratory signs only.** *J Small Anim Pract* 1982; 23: 501–509.
- Gottfried SD, Popovitch CA, Goldschmidt MH, et al. **Metastatic digital carcinoma in the cat: a retrospective study of 36 cats (1992–1998).** *J Am Anim Hosp Assoc* 2000; 36: 501–509.
- Whitehead ML, Canfield PJ, Johnson R, et al. **Case-based clinical reasoning in feline medicine 3: Use of heuristics and illness scripts.** *J Feline Med Surg* 2016; 18: 418–426.
- Sykes JE. **Ischemic neuromyopathy due to peripheral arterial embolization of an adenocarcinoma in a cat.** *J Feline Med Surg* 2003; 5: 353–356.
- Litster AL and Buchanan JW. **Vertebral scale system to measure heart size in radiographs of cats.** *J Am Vet Med Assoc* 2000; 216: 210–214.
- Aarsvold S, Reetz JA, Reichle JK, et al. **Computed tomographic findings in 57 cats with primary pulmonary neoplasia.** *Vet Radiol Ultrasound* 2015; 56: 272–277.
- Cohen PR. **Metastatic tumors to the nail unit: subungual metastases.** *Dermatol Surg* 2001; 27: 280–293.
- Langlais LM, Gibson J, Taylor JA, et al. **Pulmonary adenocarcinoma with metastasis to skeletal muscle in a cat.** *Can Vet J* 2006; 47: 1122–1123.
- Nakanishi M, Kuwamura M, Ueno M, et al. **Pulmonary adenocarcinoma with osteoblastic bone metastases in a cat.** *J Small Anim Pract* 2003; 44: 464–466.
- Johnson E and Wisner E. **Advances in respiratory imaging.** *Vet Clin Small Anim Pract* 2007; 37: 879–900.
- van der Linde-Sipman JS and van den Ingh TS. **Primary and metastatic carcinomas in the digits of cats.** *Vet Q* 2000; 22: 141–145.
- Malik R, Krockenberger MB, O'Brien CR, et al. **Nocardia infections in cats: a retrospective multi-institutional study of 17 cases.** *Aust Vet J* 2006; 84: 235–245.
- Malik R, Hughes MS and James G. **Feline leprosy: two different clinical syndromes.** *J Feline Med Surg* 2002; 4: 43–59.
- Reppas G, Gottlieb T, Krockenberger MB, et al. **Microspora arundinis: an emerging cause of phaeohyphomycosis in cats and people.** *Microbiol Aust* 2015; 36, 74–78.
- Hogan DF, Chaliwal RS, Sisson DD, et al. **Paraneoplastic thrombocytosis-induced systemic thromboembolism in a cat.** *J Am Anim Hosp Assoc* 1999; 35: 483–486.
- Tobias AH and Fine DM. **Arterial thromboembolism in cats.** In: Bonagura JD and Twedt DC (eds). *Kirk's current veterinary therapy*. 14th ed, St Louis, MO: Saunders Elsevier, 2008, pp 819–822.
- Smith AS, Tobias AH, Jacob KA, et al. **Arterial thromboembolism in cats: acute crisis in 127 cases (1992–2001) and long-term management with low-dose aspirin in 24 cases.** *J Vet Intern Med* 2003; 17: 73–83.
- Schoeman JP. **Feline distal aortic thromboembolism: a review of 44 cases (1990–1998).** *J Feline Med Surg* 1999; 1: 221–231.
- Bertone ER, Snyder LA and Moore AS. **Environmental and lifestyle risk factors for oral squamous cell carcinoma in domestic cats.** *J Vet Intern Med* 2003; 17: 557–562.
- Wiles V, Hohenhaus A, Lamb K, et al. **Retrospective evaluation of toceranib phosphate (Palladia) in cats with oral squamous cell carcinoma.** *J Feline Med Surg* 2017; 19: 185–193.
- Marioni-Henry K, Schwarz T, Weisse C, et al. **Cystic nasal adenocarcinoma in a cat treated with piroxicam and chemoembolization.** *J Am Anim Hosp Assoc* 2007; 43: 347–351.
- Oliveira CR, Ranallo FN, Pijanowski GJ, et al. **The Vet-Mousetrap: a device for computed tomographic imaging of the thorax of awake cats.** *Vet Radiol Ultrasound* 2011; 52: 41–52.
- van Stee L, Boston S, Singh A, et al. **Monopresis in association with feline pulmonary carcinoma: a literature review with 3 new cases.** *Can Vet J* 2014; 55: 849–856.