

# The Granulomatous Disorders

## The Tudor Edwards Lecture 1983

D. GERAINT JAMES, MD, FRCP

Dean and Senior Physician, Royal Northern Hospital, London

The sarcoid granuloma is a battleground between antigen and the cellular and humoral defences of the body. Macrophages are stimulated by the antigenic attack and eventually coalesce into giant cells and epithelioid cell granulomas (Fig. 1). T helper cells are mobilised to this point of activity and co-operate with macrophages, which leads to B cell overactivity. The T cells provide various lymphokines and the B cells produce immunoglobulins and various antibodies. The enzymes secreted by the granuloma include angiotensin-converting enzyme, lysozyme, glucuronidase, collagenase and elastase. With ageing, the granulomas are infiltrated by fibroblasts, and early fibrosis is recognised by increasing deposition of reticulin, which is gradually replaced by collagen which in turn is transformed into structureless eosinophilic hyaline material.

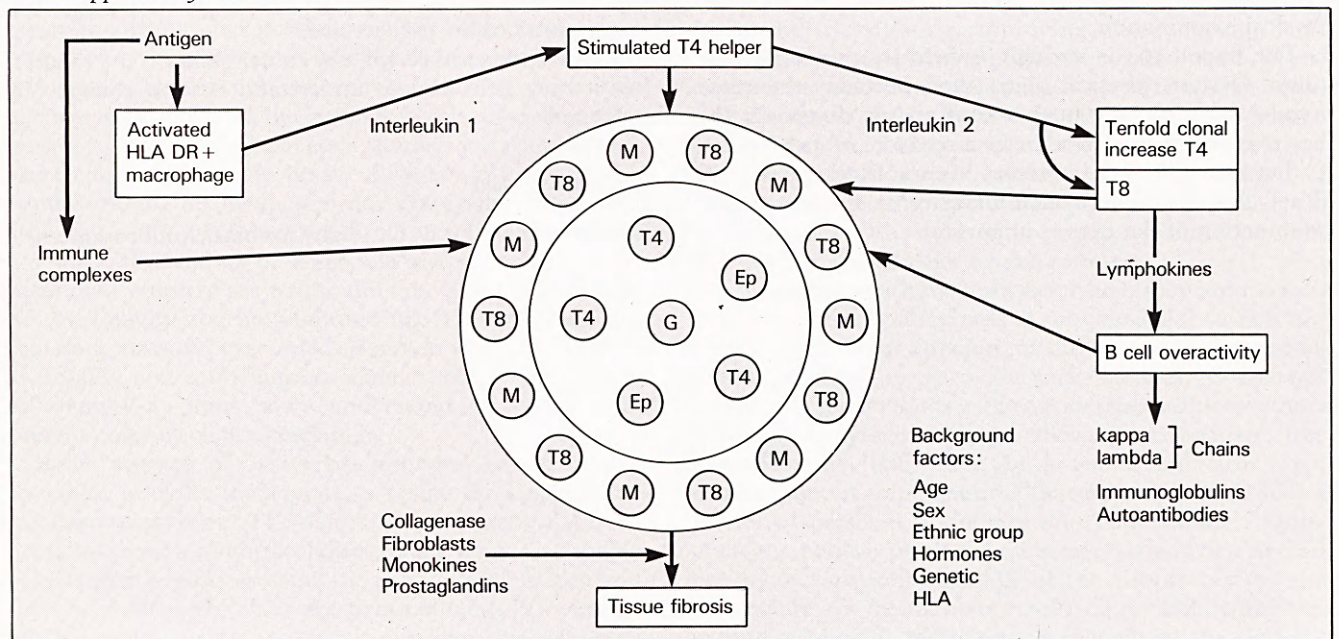
Activated macrophages within various sarcoid granulomas are now being finger-printed by a combination of immunofluorescent and histochemical techniques, and by monoclonal antibodies directed against antigen-present-

ing macrophage subsets. This dynamic approach should lead to a better understanding of both the basic molecular biology and the aetiology of sarcoidosis.

Macrophages with the phenotype HLA-DR+, RFD 2±, acid phosphatase (ACP)±, adenosine triphosphatase (ATPase)±, make up 66 per cent of the cell population of the sarcoid granuloma, the remainder being T cells. The suppressor-cytotoxic T8 cells are limited to the periphery of the granuloma, whereas the T4 cells are found throughout the granuloma (Fig. 1). The T4:T8 ratio is of the order 5:1 to 3:1. The same configuration is observed in the Kveim granuloma.

We are now able to recognise three different types of macrophages in the sarcoid granuloma (Table 1). The periphery contains a large number of antigen-presenting interdigitating (ID) cells similar to those found in the lymph node paracortex and at the cortico-medullary junction of the thymus. The centre of the granuloma consists of epithelioid and giant cells, which are derived from macrophages. The third type, tissue histiocytes, are

Fig. 1. The sarcoid granuloma. M = macrophage. Ep = epithelioid cell. G = giant cell. T4 = thymus-mediated helper cell. T8 = suppressor-cytotoxic.



**Table 1.** Frequency and distribution of cell types in sarcoid and Kveim granulomas, and in negative tuberculin skin biopsies in sarcoidosis. Percentages represent proportion of total lymphoid cells or of total non-lymphoid cells in granuloma. UCHT = University College Hospital. TO 15 = B cell monoclonal antibody. RFD = Royal Free. ACP = acid phosphatase. ATPase = adenosine triphosphatase.

Cell Type	Phenotype	Sarcoid/Kveim granuloma	Negative tuberculin
T	UCHT1 + HLA-DR - TO 15 -	40%	40%
OKT4:T8 ratio	OKT4:OKT8	5:1	3:2
Macrophages	HLA-DR + RFD 2 + RFD 1 - ACP + ATPase ±	66%	60%
Activated macrophages epithelioid and giant cells	As for macrophages	50%	27%
Interdigitating cells	HLA-DR + RFD 2 - ACP - ATPase + RFD 1 +	50%	72%
Tissue histiocytes	HLA-DR - RFD 2 + ACP - ATPase ± RFD 1 -	occasional	occasional

occasionally seen, more diffusely distributed in the granuloma and not even restricted to the granuloma itself. There is evidence of synergism between the interdigitating cells and T8 cells in the periphery of the granuloma and the epithelioid cells with T4 cells in its centre[1]. This pattern is also seen in skin biopsies of patients with tuberculoid leprosy, but not in those with lepromatous leprosy. It is suggested that the architectural segregation of T lymphocyte sub-populations in the tuberculoid leprosy granuloma is immunologically efficient in reducing the bacillary load, whereas the haphazard arrangement in lepromatous leprosy favours bacillary proliferation[2]. This configuration may be important in the pathogenesis of sarcoidosis and other granulomatous diseases.

### Lymphokines and Monokines

Lymphokines are the humoral products of antigen-stimulated sensitised T cells.

The activated macrophage, bearing cell-surface HLA-DR+ gene products, when stimulated by antigen produces interleukin 1, which in turn activates OKT4 helper-inducer cells. These activated T4 cells produce interleukin 2 which then causes a tenfold clonal replication of these T4 helper cells. Interleukin 2 is a 15,000-

20,000 dalton glycoprotein; it is the T cell growth factor which signals clonal proliferation in the lungs. It does not stimulate blood T lymphocytes[3]. The action of interleukin 1 on the T lymphocyte may call into play a prostaglandin-induced feedback mechanism that is inhibited by prostaglandin inhibitors. Interleukin 2 production is inhibited by cyclosporin A.

Several other soluble and secretory products play an important role in inhibiting macrophage migration away from the sarcoid battleground.

### Classification of Granulomatous Disorders

The sarcoid granuloma is a non-specific response to many different antigens or irritants, some of which are recognised and others still unknown. The inciting agents are persistent or poorly degradable. The best-recognised causes are infections, chemicals, an enzyme defect, neoplasia and those antigens causing extrinsic allergic alveolitis (Table 2).

The naked non-specific sarcoid granuloma needs to be clothed with clinical features in order to make it recognisable. This classification represents the differential diagnosis of these granulomatous processes. An effort is made to delineate and classify them because they are the source of considerable histological confusion. Moreover, the recognition of a causal agent may lead to a more rational form of treatment. Finally, improved knowledge of the mechanisms in one granulomatous disorder may lead to a better understanding of the pathogenesis of other granulomatous disorders.

#### *Infectious Granulomas*

Infectious granulomas are caused by fungi, protozoa, metazoa, spirochaetes, mycobacteria and bacteria. They are differentiated by culture and special stains so that the causal organism or antigen becomes recognisable.

Worldwide, the most important are mycobacteria, which cause human tuberculosis, opportunistic infections and leprosy. There are points of similarity and differences between sarcoidosis and tuberculosis (Table 3) and between sarcoidosis and leprosy (Table 4).

#### *Chemical Granulomas*

Sarcoid granulomas may be produced by beryllium, zirconium, silica and starch.

*Beryllium Disease.* This is an occupational hazard with important points of differentiation from sarcoidosis (Table 5).

*Zirconium.* This chemical caused sarcoid granulomas in the axillae of women sensitised by deodorants containing zirconium.

*Silicosis.* Inhalation of silica leads to dense nodular lesions of the lung and, rarely, diffuse pulmonary fibrosis. Hilar adenopathy is not a feature and extrathoracic lesions are rare. Silica and silicate granulomas are readily identified

**Table 2.** A classification of granulomatous disorders.

INFECTIONS	CHEMICALS
<i>Fungi</i>	Beryllium
Histoplasma	Zirconium
Coccidioides	Silica
Blastomyces	Starch
Sporothrix	
Aspergillus	IMMUNOLOGIC ABERRATION
Cryptococcus	Sarcoidosis
	Crohn's disease
<i>Protozoa</i>	Primary biliary cirrhosis
Toxoplasma	Wegener's granulomatosis
Leishmania	Giant cell arteritis
	Peyronie's disease
<i>Metazoa</i>	Hypogammaglobulinaemia
Toxocara	Systemic lupus erythematosus
Schistosoma	Lymphomatoid granulomatosis
	Histiocytosis X
<i>Spirochaetes</i>	Hepatic granulomatous disease
<i>T. pallidum</i>	Immune complex disease
<i>T. pertenue</i>	Rosenthal-Melkersson syndrome
<i>T. carateum</i>	Churg-Strauss allergic granulomatosis
<i>Mycobacteria</i>	LEUCOCYTE OXIDASE DEFECT
<i>M. tuberculosis</i>	Chronic granulomatous
<i>M. leprae</i>	Disease of childhood
<i>M. Kansasii</i>	
<i>M. marinum</i>	
<i>M. avian</i>	EXTRINSIC ALLERGIC ALVEOLITIS
BCG vaccine	Farmers' lung
	Bird fanciers'
<i>Bacteria</i>	Mushroom workers'
Brucella	Suberosis (cork dust)
Yersinia	Bagassosis
	Maple bark strippers'
OTHER INFECTIONS	Paprika splitters'
Cat scratch	Coffee bean
Lymphogranuloma	
NEOPLASIA	OTHER
Carcinoma	Whipple's disease
Reticulosis	Pyrexia of unknown origin
Pinealoma	Radiotherapy
Dysgerminoma	Cancer chemotherapy
Seminoma	Panniculitis
Reticulum	Chalazion
cell sarcoma	Sebaceous cyst
Malignant nasal	Dermoid
granuloma	Sea urchin spine injury

by finding crystalline birefringent crystals in macrophages with foreign body rather than Langhans' giant cells.

**Pulmonary Talc Granulomatosis.** Pulmonary talc granulomatosis is due to inhalation or intravenous administration of talc or intravenous pentazocaine, which is 75 per cent talc. Six patients developed lung granulomas following prolonged intravenous pentazocaine, mimicking sarcoidosis with raised serum angiotensin converting enzyme (SACE), positive gallium scans and increased lymphocyte counts in fluid from bronchoalveolar lavage. The diag-

**Table 3.** Differences between tuberculosis and sarcoidosis.

Features	Tuberculosis	Sarcoidosis
Ethnic groups	Pakistani/Indian/ Bangladeshi	West Indian/Irish
Age incidence (years)	Over 50	20-50
Fever	Common	Rare
Erythema Nodosum	Uncommon	Common
Uveitis	} Very rare	} Common
Skin involvement		
Enlarged parotids		
Bone cysts		
Ulceration and sinuses	Common	No
Involvement of: pleura peritoneum pericardium meninges small intestine	} Common	} Very rare
Caseation		
Acid-fast bacilli		
Tuberculin test		
Kveim-Siltzbach test		
Hypercalcaemia	No	Yes
Hypercalciuria	No	Yes
Serum angiotensin-converting enzyme	Elevated in up to 10%	Elevated in 60%
Calcification	Yes	Rare
Hilar lymphadenopathy	Unilateral	Bilateral
Pulmonary cavities	Common, early	Rare, late
Ghon focus	Yes	No
Corticosteroids	Harmful alone	Helpful
Anti-tuberculous drugs	Treatment of choice	Unhelpful

nosis was established by finding talc crystals in miliary pulmonary granulomas and in bronchoalveolar fluid[4]. Crystal size distinguishes inhaled (3.57  $\mu\text{m}$ ) from injected (14.7  $\mu\text{m}$ ) crystals[5].

#### *Immunological Aberrations*

There are several well-recognised disorders in which sarcoid granulomas are produced in one or several organs because of some immunological upset (Table 2). Sarcoidosis, Crohn's enteritis and primary biliary cirrhosis have histological similarities but many clinical differences (Tables 6 and 7).

**Chronic Granulomatous Disease of Childhood (CGDC).** Killing of bacteria depends on a burst of respiratory enzyme activity, which leads to the production of hydrogen peroxide and superoxide in phagocytes. Neutrophils in CGDC are unable to kill some ingested bacteria because they are deficient in enzymes needed for this superoxide respiratory burst. These defective enzymes may be nicotinamide adenine dinucleotide phosphate (NADPH) oxidase, myeloperoxidase, cytochrome B, pyruvate kinase, glucose-6-phosphate dehydrogenase, or the lack of lyso-

**Table 4.** Immunology of sarcoidosis and leprosy. ENL = erythema nodosum leprosum.

Feature	Sarcoidosis	Leprosy Lepromatous	Tuberculoid
<i>Skin Tests</i>			
Lepromin			
human	Negative	Negative	Positive
armadillo		Negative	Positive
Tuberculin	Negative	Positive	Positive
Candida	Negative	Weak positive	Positive
Trichophyton	Negative	Weak positive	Positive
Kveim-Siltzbach	Positive	Negative	Negative
<i>T Cells</i>			
helper	Active in lungs		Normal
suppressor	Active in blood	Very active	
Lymphocyte transformation with PHA	Poor	Poor	Normal
with <i>M. leprae</i>		Very poor	Normal
Delayed allograft rejection		4 days longer	2 days longer
Macrophage function	? Efficient	Defective Unable to kill intracellular <i>M. leprae</i>	Normal
Serum immunoglobulins	Raised	Normal	
Antibodies against			
<i>M. leprae</i>		Normal	Normal
typhoid vaccine	Normal	Normal	Normal
Rheumatoid factor	May be positive	±	Normal
Immune complexes	Yes	Yes	No
HLA	B8-A1	? DW3	
Erythema nodosum	Common	Occurs with treatment	Unusual
Amyloid	No	Yes with chronic ENL	No
Effect of steroids on immune response	Improves	Impairs	Impairs
Effect of transfer factor	? Improves	Improves	Unknown

zyme or lactoferrin, each perhaps contributing a different clinical profile.

The classical X-linked disorder occurs in boys aged about five years, who present with hepatosplenomegaly, generalised lymphadenopathy, weeping granulomatous skin lesions and diffuse miliary lung infiltration. The histology is of multi-system sarcoid granulomas. There may be more than one X-linked form and also more than one autosomal recessive variety. The group is heterogeneous because there are now reports of defective oxidative metabolism with phagocytic stimuli such as bacteria but not with non-phagocytic metabolic stimuli such as sodium fluoride or concanavalin A. There is certainly more than one mechanism for initiating oxidative metabolism.

Patients with CGDC only suffer from catalase-producing staphylococci and enterobacteria. Organisms that lack catalase supply the neutrophil with the hydrogen peroxide for their own destruction. Thus catalase-negative organisms such as pneumococci or streptococci, present no problem to these patients.

Neutrophil leucocytes of normal patients with bacterial infections reduce nitroblue tetrazolium (NBT) to form blue-black formazan granules in the cytoplasm. This fails to occur in the leucocytes of CGDC children or in the mothers of boys with the X-linked disorder.

### Neoplasia

Sarcoid granulomas related to tumours may cause diagnostic difficulty, particularly in Hodgkin's disease. Intrathoracic Hodgkin's disease most frequently affects the upper mediastinum rather than hilar lymph nodes, and it is predominantly unilateral. The hilar nodes tend to fuse with the right cardiac border, whereas in sarcoidosis they stand away from the cardiac border. Both diseases show depression of cellular immunity, but Hodgkin's disease is not associated with significantly raised serum immunoglobulins, the Kveim test is negative and SACE levels are seldom elevated. The histological distinction of granulomas in Hodgkin's disease is considerably helped by the frequent admixture of eosinophils and the close proximity of the tumour. Diagnostic difficulty may arise in the interpretation of small aspiration liver biopsy specimens, or in the occasional patient whose spleen has been replaced by sarcoid tissue which has obliterated tumour tissue.

Isolated sarcoid granulomas may be noted in lymph nodes draining carcinoma of the lung, stomach and uterus. Two patients with testicular carcinoma treated by radiotherapy or cytotoxic therapy developed bilateral hilar lymphadenopathy containing sarcoid granulomas [6].

**Table 5.** Features distinguishing sarcoidosis and beryllium disease.

Feature	Sarcoidosis	Beryllium Disease
Occupational exposure	No	Metal/Alloy/ Ceramics
Onset	Acute or insidious	Insidious
Granuloma	Non-caseating	Rarely necrotic
Schaumann bodies	70%	80%
Pulmonary fibrosis	10%	100%
Respiratory symptoms	Minimal	Moderate
Erythema nodosum	Frequent	No
Skin lesions	in 14%	Inoculation ulcer only
Bilateral hilar lymphadenopathy	Frequent	Rare
Uveitis	in 27%	Very rare
Bone cysts	in 3%	No
Skin tests		
Tuberculin	Negative in 66%	Normal
Kveim	Positive in 80%	Negative
Beryllium	Negative	Positive
Beryllium lymphocyte transformation test	Negative	Positive in 100%
Immune complexes	Positive in 50%	No
Raised SACE	in 60%	Rare
Genetic background	B8/A1/CW7/DR3	Not recognised
Prognosis	Good	Progressive fibrosis

### *Extrinsic Allergic Alveolitis (EAA)*

An increasing number of inhaled antigens, usually organic, are being recognised as a cause of antigen-antibody-induced lung disease in which identical sarcoid granulomas may be present (Table 8). The essential basis for distinction from sarcoidosis is a history of exposure, environmental and often occupational; prominent alveolitis; the presence of circulating antibodies to the causative antigens and a negative Kveim-Siltzbach skin test. The prototype of this family of pulmonary granulomatoses or hypersensitivity pneumonitis is farmers' lung. Antibodies indicate exposure but not necessarily the disease itself. The granulomas of EAA are very similar to sarcoidosis but Schaumann bodies are rare. In the chronic stage of EAA the granulomas somewhat surprisingly disappear without leaving the small round hyalinised scars which are the hallmark of sarcoidosis.

### **Sarcoidosis**

#### *Aetiology*

The cause of sarcoidosis remains unknown despite an extensive search to uncover an infective agent, an immunological upset, an allergic mechanism, or a specific diathesis.

*Is it an Infection?* It was traditional to regard sarcoidosis as an odd form of tuberculosis, and the two diseases have

**Table 6.** Difference between sarcoidosis and Crohn's regional ileitis. (The granulomas are similar.)

Features	Sarcoidosis	Crohn's regional ileitis
Involvement of:		
Intestine	Rare	Invariable
Intrathoracic	Yes in 90%	No
Skin	Yes in 25%, but they do not ulcerate	Muco-cutaneous ulceration extending to involve genitalia
Erythema nodosum	Yes	Yes
Eyes	Yes in 25%	No
Associated:		
Ankylosing spondylitis	No	Yes
Complicating:		
Malabsorption	No	Yes
Amyloidosis	No	Yes
Peritonitis	No	Yes
Hepatic granulomas	Yes	Yes
Depression of delayed-type hypersensitivity	Yes	Yes
Kveim-Siltzbach test	Positive in 80%	Negative
Abnormal calcium metabolism	Hypercalcaemia and hypercalciuria	Hypocalcaemia associated with malabsorption
Serum:		
Antitreulin antibodies	Negative	Positive in 25%
Lysozyme	Raised	Raised
Angiotensin-convertase	Raised	Normal
Surgical treatment	No	Yes
Corticosteroids	Yes	Yes
Azathioprine	±	Yes
Calciferol	Contraindicated	Indicated

certainly been confused with each other throughout this century. There are crucial differences (*see* Table 3). Attempts have been made to detect granulomagenic components of various mycobacteria in sarcoid tissue. The presence of mycolic acid esters aroused interest, but they are also found in normal tissue. Muramyl dipeptide and bacterial lipopolysaccharides are granulomagenic at injection sites but they do not produce multi-system granulomas.

Many claims have been made for infection due to fungi, viruses and bacteria as a cause of sarcoidosis; the occasional presence of these infective agents seems coincidental rather than causal.

**Table 7.** Features distinguishing sarcoidosis from primary biliary cirrhosis.

Features	Sarcoidosis	Primary biliary cirrhosis
Sex F:M	Equal	8:1
Decade of onset	3, 4	5
Diagnosis over 40 years	Rare	Frequent
Erythema nodosum	Yes	No
Uveitis	Yes	No
Respiratory	Yes	No
Pruritus	No	Yes, eventually
Jaundice	No	Yes, late
Xanthomas	No	Yes, late
Clubbing	No	Yes
Hepatomegaly	Infrequent	Usually
Splenomegaly	Yes	Yes
Skin pigmentation	No	Yes
Steatorrhoea	No	Yes with jaundice
Bilateral hilar lymphadenopathy	Yes	No
Kveim-Siltzbach test	Positive in 80%	Always negative
Depression of delayed-type hypersensitivity	Yes	Yes
Circulating mitochondrial antibodies	No	Yes (in 99%)
Calcium metabolism	Hypercalcaemia Vitamin D sensitivity	Hypocalcaemia (steatorrhoea)
Raised alkaline phosphatase	Yes, minority	Yes, in most
Raised angiotensin-converting enzyme	Yes, in 60%	Yes, in 16%
Liver granulomas	Yes	Yes
Corticosteroids	Helpful	Contraindicated
Vitamin D	Contraindicated	Helpful
Cholestyramine	Not necessary	Helpful
Prognosis	Very good	Variable

**Table 8.** Differences between sarcoidosis and extrinsic allergic alveolitis.

Feature	Sarcoidosis	Extrinsic allergic alveolitis Hypersensitivity pneumonitis
Histology	Very similar. Look for foreign body giant cell reaction	
Birefringent bodies	No	Yes
Occupational history	No	Yes
Multi-system	Always	Sometimes
Erythema nodosum	Common	Absent
Hilar adenopathy	Frequent	Infrequent
Wheezing	Rare	Common
Uveitis	Frequent	Absent
Depression of delayed type hypersensitivity	Yes	Yes
Raised or abnormal immunoglobulins	Yes	Yes
Kveim-Siltzbach test	Positive	Negative
Serum angiotensin-converting enzyme	Raised	Normal
Abnormal calcium metabolism	Frequent	Absent
Response to steroids	Good	Good
Prognosis	Good	Good if removed from exposure to antigen

*Is it an Immunological Aberration?* Sarcoidosis is a lymphoproliferative disorder with evidence of depression of delayed-type hypersensitivity, imbalance of OKT4:T8 subsets, hyperreactive B cells and frequent circulating immune complexes. Could this be a background factor which provides an infective agent or other antigenic insult with a salubrious soil?

*Is it due to Hypersensitivity?* Claims have been made for such diverse regional contributory factors as pine pollen, peanut dust, clay-eating and chewing pine pitch. Beryllium and zirconium are known to produce sarcoid granulomas in sensitised individuals.

*Is there a Predisposition?* Hormonal factors play some part, for erythema nodosum due to sarcoidosis commonly occurs in women of child-bearing age, during early pregnancy, and also in women taking the oral contraceptive pill.

Sarcoid arthritis and erythema nodosum are most likely to occur in women who are HLA-B8, A1, CW7, DR3. This predisposition is associated with a short course and good prognosis, whereas HLA-B13 is more likely to be associated with chronic disease (Table 9).

#### *Epidemiology*

Sarcoidosis has a worldwide distribution but is more frequently recognised in sophisticated communities. Whenever tuberculosis or leprosy is rampant, sarcoidosis

**Table 9.** HLA types and their significance in sarcoidosis.

HLA Type	Significance in sarcoidosis
B8/A1	Sarcoid arthritis Erythema nodosum
B13	Chronicity
CW7	Sarcoidosis in English
B8/CW7/DR3	Good prognosis in sarcoidosis in English
DR3	Short duration of disease
B7	Symptomatic tuberculin-negative Swedish
BW15	Black Americans

is in eclipse, but as they are brought under control so will sarcoidosis become more evident. It has a similar prevalence in the Western world and in Eastern Europe.

Sarcoidosis is ten times more frequent in the American black population than in the white. It is a very common disorder in the black population of the Caribbean, particularly when they migrate to London (from the British West Indies) or to Paris (from Martinique). Likewise it is common in Puerto Ricans living in New York. Whether it is due to genetic predisposition or environmental factors confronting susceptible individuals migrating from a rural to an urban community is unknown, and the breeding ground for sarcoidosis may be the native environment or the sophisticated new world or both.

Sarcoidosis is also becoming more evident in the black populations of Africa. In the next thirty years it is likely to become a common disorder of the African, either at home or, particularly, when he lives abroad.

It is also frequently seen in the white population of Europe. That it is well recognised in Japan is shown by the fact that the Japanese have a special commission on the look-out for it. It is extremely rare in the rest of Asia, possibly because it is obscured by the considerable presence of tuberculosis.

#### *Clinical Features*

We have analysed a series of 818 patients with clinical and histological evidence of sarcoidosis attending the Royal Northern Hospital, London. Five hundred (51 per cent) were female, nine-tenths were Caucasian and one-tenth from the Caribbean. Seven hundred (88 per cent) had radiographic evidence of intrathoracic sarcoidosis. Since sarcoidosis is a multi-system disorder, it was also evident in other systems, notably the skin (overall in 50 per cent of the series), eyes (27 per cent), reticulo-endothelial system (39 per cent) and upper respiratory tract (6 per cent).

We have compared this series from one London hospital with sarcoidosis seen in various centres throughout the world[7] (Table 10).

**Table 10.** Features of sarcoidosis in the Royal Northern Hospital series compared with a worldwide survey.

Sarcoidosis	Royal Northern Hospital		Worldwide	
	No. = 818	%	No. = 3,676	%
Female	500	61	2082	57
Presentation < 40 years	604	74	2504	68
Caucasian	728	89		
West Indian	81	10		
Intrathoracic	700	88	3224	87
Ocular	224	27		
Erythema nodosum	251	34	640	17
Lupus pernio	35	4		
Other skin lesions	113	14	324	9
Ocular lesions	224	27	539	15
Parotid enlargement	52	6	160	4
Nervous system	77	9	134	4
Bone	31	3	109	3
Lymph nodes and spleen	326	39	1031	28
Lymphadenopathy	225	27		
Splenomegaly	101	12		
Hepatomegaly	82	10		
Heart	27	3		
Lacrimal gland	22	3		
Kidney	10	1		
Upper respiratory tract	53	6		
Systemic corticosteroid therapy	344	42	1738	47
Mortality due to				
Sarcoidosis	25	3	84	2.2
Other causes	23	3	54	1.4
Skin tests				
Positive Kveim-Siltzbach	550/657	84	1714/2189	78
Negative tuberculin test	488/702	70	2093/3268	64
Hyperglobulinaemia	161/526	31	808/1832	44
Hypercalcaemia	99/547	18	200/1760	11

## Criteria of Activity

In the last 100 years there have been very few markers of activity of sarcoidosis. During the last ten years we have been inundated with too many, so it is becoming increasingly difficult to choose the most helpful. We have grouped them into the following categories (Table 11):

1. Clinical features which indicate activity, and bedside techniques which proclaim activity.
2. Biochemical markers.
3. Immunological markers.

**Table 11.** Markers of activity of sarcoidosis. LACE = lung angiotensin converting enzyme. KCO = carbon monoxide factor.

Clinical	Biochemical	Immunological
Erythema nodosum Uveitis	Hypercalcaemia Hypercalciuria	B2 microglobulins TM helper cells in BAL
Maculopapular rash	SACE	Increased OKT4:OKT8 ratio (in BAL)
Dactylitis Polyarthralgia	LACE Serum lysozyme	Decreased OKT4:OKT8 ratio (in blood)
Myopathy	Serum collagenase	Kappa and lamda light chains (by radio-immunoassay)
Neuropathy	Urinary hydroxyproline Glucuronidase	Circulating immune complexes
Granulomatous scars Splenomegaly Lymphadenopathy Salivary and lacrimal gland enlargement Cardiac arrhythmia Changing chest X- ray Transfer factor Exercise KCO Fluorescein angiography Tuberculin skin test Kveim-Siltzbach skin test Biopsies Radioactive gallium scan Thallium 201 myocardial scan 24 hour ECG tape Bronchoalveolar lavage		

In clinical practice, we would prefer to choose a measure that is specific and reliable, reproducible around the world, preferably cheap, and sufficiently easy to permit serial measurements to monitor progress. Each of the methods to be discussed has some defect which prevents it from being the perfect bedside tool.

*Serum Angiotensin Converting Enzyme (SACE).* SACE is elevated in about 60 per cent of patients with active sarcoidosis but it is also associated with a false positive rate of about 10 per cent; thus it is not a good diagnostic test. Its true value is in monitoring the progress of known sarcoidosis[8]. In this respect it is a more sensitive index of activity of epithelioid cell granulomas than the chest radiograph. Its introduction should halve the number of chest radiographs done, since many are unnecessary. It is an invaluable monitor in pregnancy.

The Japanese have just introduced a do-it-yourself bedside kit which should be as helpful as bedside blood glucose sticks for diabetes mellitus.

*Radioactive Gallium-Scanning.* The activated macrophages in granulomas avidly accumulate gallium and delineate the extent of granulomatous involvement in lungs and hilar lymph nodes. Gallium is taken up by liver, spleen and bone in the normal person, so it is not helpful in detecting granulomas in the abdominal viscera or the central nervous system. Lung uptake is crudely measured by comparison with the density of liver uptake. Radioactive gallium is also taken up by the protein of inflammatory exudates so it is not specific for sarcoidosis. Positive scans are found in asbestosis, silicosis, fibrosing alveolitis, cancer, bleomycin lung and lymphomas. Its value, like SACE, is as a monitor of progress. Its other defect is its cost, which would be prohibitive in many centres.

*Bronchoalveolar Lavage (BAL).* Bronchopulmonary lavage with about 100–300 ml of fluid provides specimens which can be measured for alveolar macrophages, lymphocytes, T and B cells, angiotensin-converting enzyme, lysozyme, protein, complement and immunoglobulins. The more active the pulmonary disorder, the richer the yield, and the more interesting the differential diagnosis. Findings differ in various interstitial lung disorders[9].

*Lung Function Tests.* Sarcoidosis is a restrictive lung disease with abnormal gas exchange; its pathophysiology is similar to that of other interstitial lung diseases, with decreased lung compliance, volumes and capacities as the main features. There is diminished carbon monoxide diffusing capacity and an increased alveolar-arterial oxygen gradient. The latter may cause hypoxaemia at rest and this worsens with exercise. These tests are helpful in defining the functional impairment and in monitoring progress. However, quite often they do not correlate with the symptoms or signs or with the stage of chest X-ray abnormality, or with the immunological upset.

## Treatment

### Steroids

Corticosteroid therapy constitutes a mainstay of treatment around the world. It is particularly indicated for ocular involvement; an abnormal chest radiograph associated with a significant elevation of SACE, a positive gallium scan, or abnormal bronchoalveolar fluid; troublesome breathlessness; persistent hypercalciuria; disfiguring



ing skin lesions; or involvement of myocardium, nervous system or lacrimal and salivary glands. It may be needed on a long-term basis for troublesome involvement of the upper respiratory tract, or for pain, swelling and deformity associated with bone cysts.

#### *Alternative Regimens*

Steroid therapy may be contra-indicated or need reinforcement. Alternative drugs include indomethacin and oxyphenbutazone for acute exudative disease, methotrexate and chloroquine for chronic fibrotic persistent sarcoidosis.

Cyclosporin A is a fungal metabolite with interesting immunosuppressant properties. It acts selectively on T helper cells, interfering with interleukin 2 production and thereby preventing organ rejection. It exerts profound effects on experimental epithelioid cell granulomas produced in rats by injections of various mycobacteria and then treated with oral cyclosporin in a dose of 20 mg/kg. It prevents the formation of epithelioid cell granulomas or the development of caseous necrosis[10]. Its value in sarcoidosis has not yet been assessed.

#### *Acknowledgements*

This work has been sustained by the E. B. Hutchinson Trust, Roger Gibbs Research Foundation and the Friends of the Royal Northern Hospital.

#### **References**

1. Mishra, B. B., Poulter, L. W., Janossy, G. and James, D. G. (1983) *Clinical and Experimental Immunology*, in press.
2. Modlin, R. L., Hofman, F. M., Meyer, P. R. *et al.* (1983) *ibid.*, **51**, 430.
3. Pinkston, P., Bitterman, P. B. and Crystal, R. G. (1983) *New England Journal of Medicine*, **308**, 793.
4. Farber, H. W., Fairman, R. P. and Glaiser, F. L. (1982) *American Review of Respiratory Disease*, **125**, 258.
5. Abraham, J. L. and Brambilla, C. (1979) *ibid.*, **119**, 196.
6. Trump, D. L., Ettinger, D. S., Feldman, M. J. and Dragon, L. H. (1981) *Archives of Internal Medicine*, **141**, 37.
7. James, D. G., Neville, E., Siltzbach, L. E. *et al.* (1976) *Annals of the New York Academy of Sciences*, **278**, 321.
8. Studdy, P., Bird, R., James, D. G. and Sherlock, S. (1978) *Lancet*, **2**, 1331.
9. Crystal, R. G., Roberts, M. C., Hunninghake, G. W. *et al.* (1981) *Annals of Internal Medicine*, **94**, 73.
10. Muller-Hermelink, H. K., Kaiserling, E. and Sonntag, H. G. (1982) *Pathology Research Practice*, **175**, 80.

---

## **Langerhans and Langhans**

The similarity in the names of Langerhans and Langhans has led to some confusion in the spelling of the eponymous labels attached to the discoveries of these two famous German morbid anatomists.

Paul Langerhans (1847-1888), born in Berlin, was a student of Rudolf Virchow and qualified MD Berlin in 1869. In 1871 he was appointed morbid anatomist at Freiburg where he remained until, for health reasons, he retired early to Madeira and died there. In 1869, he described in rabbits 'clumps of epithelial-like protoplasmic cells lying in the inter-alveolar tissue of the pancreas', for which he was not able to suggest a function. His findings attracted little attention at the time and it was not until 1893 that Gustave Edouard Laguesse of Lille labelled them 'the islets of Langerhans'. Langerhans found similar tissue in the gut wall of lower chordates and these came to be called 'the follicles of Langerhans'. In 1873, Langerhans also described the special cells in the stratum Malpighi of the epidermis, known since then as 'Langerhans' cells'.

Theodor Langhans (1839-1915), born in Usingen, qualified MD Würzburg in 1864; after being assistant to von Recklinghausen, he was in 1872 appointed morbid anatomist at Berne, where he remained for the rest of his life. In 1867 he described large multinucleated cells (of so-called 'foreign-body type') in the tuberculous granuloma. These are usually referred to as 'Langhans' cells', although it is now recognised that they may be found in other granulomata, for instance sarcoid. In 1872 he was the first to describe the presence in Hodgkin's disease of giant cells, to which, thirty years later, attention was drawn in Vienna by Carl Sternberg (1898) and at Johns Hopkins by Dorothy Reed (1902). Finally, in 1870, Langhans described the layer of cells covering the chorionic villi beneath the syncytial layer—the cytotrophoblast—also known as the 'Langhans' layer', the individual cells being called 'Langhans' cells'.

ALEX SAKULA