

Fetal intra abdominal umbilical vein varix: Case series and review of literature

Meenakshi Lallar, Shubha R Phadke

Department of Medical Genetics, Sanjay Gandhi Post Graduate Institute of Medical Sciences, Lucknow, Uttar Pradesh, India

Correspondence: Dr. Shubha R Phadke, Department of Medical Genetics, Sanjay Gandhi Post Graduate Institute of Medical Sciences, Rai Bareilly Road, Lucknow, Uttar Pradesh, India. E-mail: shubharaophadke@gmail.com

Abstract

Fetal intraabdominal umbilical vein varix (FIUV) is focal dilatation of the intrabdominalumbilical vein of the fetus. It appears as a round or fusiform cystic structure in the fetal abdomen, which shows continuity with the umbilical vein on grayscale and color Doppler imaging. The diagnostic criteria include the FIUV varix diameter at least 50% wider than the diameter of the intrahepatic umbilical vein and an intraabdominal umbilical vein diameter exceeding 9 mm or greater than two standard deviations above the mean for gestational age. We report three cases, two cases with isolated FIUV and favorable outcome and the third case with FIUV and atrioventricular septal defect, where trisomy 21 (Down syndrome) was diagnosed.

Key words: Antenatal ultrasound; fetal anomalies; trisomy 21; umbilical vein varix

Introduction

Fetal intraabdominal umbilical vein varix (FIUV) is an uncommon but easily detectable ultrasonographic finding.^[1,2] Counselling for outcome is a challenge because outcomes are variable. Though the outcome may be satisfactory, cases with fetal structural anomalies, chromosomal anomalies, or fetal hydrops with adverse pregnancy outcomes have been reported.

We report our experience with three cases of FIUV varix and review the available literature.

Case Report

Three cases of umbilical vein varix were identified at our referral centre from 2012 to 2015. The first patient was

a 32-year-old, fifth gravida, with 32-week pregnancy who presented with intrauterine growth restriction; she reported three previous intrauterine deaths in late third trimester (cause unknown). FIUV was identified with a diameter of 14.2 mm (normal diameter of umbilical vein: 7–8 mm). Color Doppler analysis showed turbulent flow in the varicose segment. There were no other structural abnormalities in the fetus. The umbilical artery Doppler was normal. Weekly serial sonographic and Doppler monitoring of pregnancy was performed. Patient delivered a healthy female at 37 weeks by elective caesarean section. The child is now 2 years old and is developmentally normal [Table 1; Figure 1].

The second patient was a 28-year-old, 21-week pregnant, second gravida who referred with triple test showing high

This is an open access article distributed under the terms of the Creative Commons Attribution-NonCommercial-ShareAlike 3.0 License, which allows others to remix, tweak, and build upon the work non-commercially, as long as the author is credited and the new creations are licensed under the identical terms.

For reprints contact: reprints@medknow.com

Cite this article as: Lallar M, Phadke SR. Fetal intra abdominal umbilical vein varix: Case series and review of literature. Indian J Radiol Imaging 2017;27:59-61.

Access this article online

Quick Response Code:

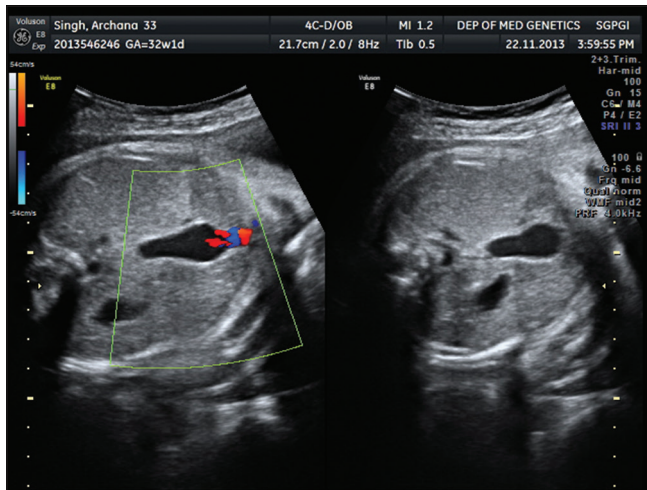


Website:
www.ijri.org

DOI:
10.4103/0971-3026.202964

Table 1: Ultrasonographic findings and neonatal outcome in fetuses with FIUV

Maternal age (years)	Gestational age at diagnosis (weeks)	Gravidity Parity	Indication for US at first diagnosis	Other sonographic findings	FIUV diameter at detection (mm)	Pregnancy Complications, Pregnancy outcome	Follow up, age
32	32	G5P4	IUGR	IUGR	14.2	None, Term LSCS, 2 kg female	Female child developmentally normal at 8 months of age
28	21	G2P1	High risk of neural tube defects on triple test	-	9.7	None, Term LSCS, 2.5 kg Male	Male child developmentally normal at one year of age
26	19	G2P1	High risk of trisomy 21 on triple test	AV canal defect	9	Trisomy 21, pregnancy terminated	

**Figure 1:** FIUV measuring 14.2 mm and showing normal color flow on Doppler

risk for neural tube defects (>1:50 on triple test, AFP of more than 2.5 MoM). On ultrasonography, isolated FIUV varix measuring 9.7 mm was identified with no other abnormalities. Patient did not opt for invasive testing. Follow-up ultrasound at 31 weeks showed varix size of 9.8 mm with normal Doppler study. She delivered a healthy male after elective caesarean section at term. The child is now 8 months of age and is developmentally normal.

The third patient was a 26-year-old, 19-week pregnant, second gravida who referred with high risk of trisomy 21 on triple test (1:214). On ultrasonography, fetus was found to have a FIUV of diameter 9 mm. The FIUV showed turbulent flow on colour Doppler. An atrioventricular canal defect was also detected in the fetus. Amniocentesis was done and trisomy 21 was detected on fetal karyotyping. The pregnancy was terminated.

Discussion

Of the three cases with FIUV, two cases with isolated FIUV had a normal outcome. In the third patient with atrioventricular canal defect and FIUV, fetal karyotyping showed trisomy 21 (Down syndrome). Umbilical vein varix corresponds to approximately 4% of the malformations of the umbilical cord. FIUV represents focal dilatation of the extrahepatic intraabdominal part of the fetal

umbilical vein. It appears as a round or fusiform cystic structure in the fetal abdomen between the inferior part of the liver and the anterior abdominal wall. Among the intraabdominal umbilical vein varices, extrahepatic intraabdominal varices are more common than intrahepatic intraabdominal varices, probably due to lack of liver support in the extrahepatic region. The diameter of the umbilical vein increases linearly from 3 mm at 15 weeks to 8 mm at term. The diameter of most umbilical vein varices is between 6 and 12 standard deviations (SD) above the mean umbilical vein diameter for the patient's gestational age.^[2,3] Extremely large varices of up to 85 mm have been reported.^[4]

Till date more than 200 cases have been reported in the literature [Table 2].^[5-8] The results of four large case series on FIUV by Rahemtullah *et al.*, Byers *et al.*, Fung *et al.*, and Lee *et al.* are compiled in Table 2. Out of 218 FIUV cases, 170 had normal outcome (78%). Eighteen fetuses (8.3%) had major malformations. Five cases with FIUV had trisomy 21 and one had triploidy. Except one case, all fetuses with trisomy 21 had ultrasonographically detected major abnormalities, as was the situation in our case. Intrauterine deaths were reported in 7 cases, one of these was trisomy 21. Approximately 18% of the pregnancies had obstetrical complications. Twin-to-twin transfusion and twin-reversed arterial perfusion (TRAP) and three cases of isoimmunization need special mention because FIUV may be the effect of hemodynamic manifestation of these causes.

The complications of FIUV are rupture, thrombosis, compression of the umbilical artery and other veins, and cardiac failure due to vascular stealing by the varix and increased preload. Hence, close serial ultrasonography and Doppler monitoring is required.^[9]

Conclusion

Detection of FIUV calls for careful screening of malformations by ultrasound. Monitoring for growth and wellbeing is required. The incidence of chromosomal abnormalities is approximately 2.8% in fetuses with FIUV.^[3,5-8] In absence of malformations, usually the prognosis is favorable. Fetal karyotyping needs to be offered if there are other abnormalities observed on ultrasound. Isolated FIUV does not warrant fetal karyotyping.

Table 2: Larger case series of FIUV fetuses and their outcome

Study	Total No. of Cases	Normal outcome	Minor USG findings	Major malformation	Chromosomal abnormality	Obstetrical complication	IUD
Mahony <i>et al.</i> , 1992. ^[3]	9	4 (44.4%)		1-Non Immune Hydrops at 34 weeks -resolved uneventfully	Trisomy 21-1(no other USG abnormalities)		3
Rahemtullh <i>et al.</i> , 2001. ^[5]	23	11 (47.8%)	3 (Umbilical cord cyst, Mild pericardial effusion, Echogenic bowel)	7 (2- Multiple anomalies 2-Isolated cardiac defect, 1-Ellis van crevald syndrome 1-22q11.2 deletion, 1-Diaphragmatic hernia)	Triploidy-1	8 (oligohydramnios-4, polyhydramnios-2, preterm delivery-1 Kellsimmunization- 1)	-
Byers <i>et al.</i> , 2009. ^[7]	52	37 (71.2%)	7 (1-Single umbilical artery, 1-Unilateral club foot, 1-Echogenic dilated bowel, 2-Bilateral moderate pyelectasis, 1-Widened cisterna magna, 1-Unilateral choroid plexus cyst)	4 (1-Beckwith–Wiedemann syndrome 1-Right pelvic kidney and single umbilical artery. 1-Right renal agenesis. 1-Bilateral pyelectasis with right renal cyst)	Trisomy 21 - Total-3 [1]. -IUD- 1(cardiomegaly, shortened left humerus, an absent nasal bone, macroglossia and an atrioventricular canal defect) [2]. significant bilateral renalpyelectasis [3].1 - a ventricular septal defect, hyperechogenic bowel loops, bilateral renal pyelectasis and ventriculomegaly	18 (Oligohydramnios -5, IUGR-1, Pre-eclampsia 2, Pyelonephritis-1, Gestational diabetes mellitus- 4 Complete placenta previa-1, Twin-twin transfusion syndrome-1 Twin Reversed Arterial Perfusion -1. Anti-E isoimmunization-1, Rhesus isoimmunization-1)	1 (Trisomy 21)
Fung <i>et al.</i> , 2005. ^[6]	13	9 (69.2%)	1 (polydactyly)	-	Trisomy 21-1(pleural effusion)	1 (preterm delivery)	2
Lee <i>et al.</i> , 2014. ^[8]	121	109 (90.1%)	6 (2-cryptorchidism, 1-Renal pelvis dilatation, 2-Cerebral mild ventriculomegaly, 1-Single umbilical artery)	5 (1-Hydrops fetalis, 1-Atrial septal defect, 1-Pulmonary sequestration, 1-Incomplete unilateral duplex kidney, 1-Non-lethal skeletal dysplasia)		16 (Oligohydramnios -6, IUGR- 4, Preeclampsia- 1, Gestational diabetes mellitus - 4, Placental previa - 1)	1
Total cases	218	170 (78%)	17 (7.7%)	17 (7.8%)	6 (2.8%)	42 (19.3%)	7 (3.2%)

Financial support and sponsorship

Nil.

Conflicts of interest

There are no conflicts of interest.

References

- Varix of the umbilical vein. In: Nyberg DA, McGahan JP, Pretorius DH, Pilu G, editors. Diagnostic imaging of fetal anomalies. Philadelphia: Lippincott Williams and Wilkins; 2003. p. 114-5.
- Weissman A, Jakobi P, Bronshtein M, Goldstein I. Sonographic measurements of the umbilical cord and vessels during normal pregnancies. J Ultrasound Med 1994;13:11-4.
- Mahony BS, McGahan JP, Nyberg DA, Reisner DP. Varix of the fetal intra-abdominal umbilical vein: Comparison with normal. J Ultrasound Med 1992;11:73-6.
- Fuster JS, Benasco C, Saad I. Giant dilatation of the umbilical vein. J Clin Ultrasound 1985;13:363-5.
- Rahemtullah A, Lieberman E, Benson C, Norton ME. Outcome of pregnancy after prenatal diagnosis of umbilical vein varix. J Ultrasound Med 2001;20:135-9.
- Fung TY, Leung TN, Leung TY, Lau TK. Fetal intra-abdominal vein varix: What is the clinical significance? Ultrasound Obstet Gynecol 2005;25:149-54.
- Byers BD, Goharkhay N, Mateus J, Ward KK, Munn MB, Wen TS. Pregnancy outcome after ultrasound diagnosis of fetal intra-abdominal umbilical vein varix. Ultrasound Obstet Gynecol 2009;33:282-6.
- Lee SW, Kim MY, Kim JE, Chung JH, Lee HJ, Yoon JY. Clinical characteristics and outcomes of antenatal fetal intra-abdominal umbilical vein varix detection. Obstet Gynecol Sci 2014;57:181-6.
- Zalel Y, Lehavi O, Heifetz S, Aizenstein O, Dolitzki M, Lipitz S, *et al.* Varix of the fetal intra-abdominal umbilical vein: Prenatal sonographic diagnosis and suggested in utero management. Ultrasound Obstet Gynecol 2000;16:476-8.