



Rapid firing

Successful pacemaker lead extraction involving an ossified thrombus: A case report

Hideo Okamura, MD^a, John S. Van Arnam, MD^b, Marie Christine Aubry, MD^b, Paul A. Friedman, MD^a, Yong-Mei Cha, MD^{a,*}

^a Division of Cardiovascular Diseases, Mayo Clinic, Rochester, MN, USA

^b Division of Surgical Pathology, Mayo Clinic, Rochester, MN, USA

ARTICLE INFO

Article history:

Received 19 April 2016

Received in revised form

11 June 2016

Accepted 24 June 2016

Available online 30 August 2016

Keywords:

Lead extraction

Calcification

Thrombus

Rotating mechanical sheath

ABSTRACT

A 41-year-old woman who had been fitted with a pacemaker 18 years prior presented for lead extraction because of device infection. First, we tried laser sheath. However, it cannot cross the binding in the innominate vein. Then we switched to the rotating mechanical sheath. Although it crunched through binding tissue, the progress halted. We removed the sheath and found pieces of calcified tissue in the sheath lumen. After removing the calcified tissue, both leads were extracted using the laser sheath, without complications. The pathological examination revealed a diagnosis of ossified thrombus. Venous thromboses associated with implanted leads can ossify with time, causing difficulties in the extraction of long-standing intravascular leads.

© 2016 Japanese Heart Rhythm Society. Published by Elsevier B.V. This is an open access article under the CC BY-NC-ND license (<http://creativecommons.org/licenses/by-nc-nd/4.0/>).

1. Introduction

As the indications for transvenous lead extraction expand and the number of extractions increases, surgeons face greater odds to encounter difficult cases. Several factors can complicate transvenous lead extraction, making it more challenging and dangerous. One of those factors is a longer implantation time [1].

We present a case of difficult lead extraction that revealed a pathological change in the tissues around the lead.

2. Case report

A 41-year-old woman who had been fitted with a pacemaker for bradycardia 18 years prior presented for lead extraction on account of device infection. She had a left pectoral dual chamber pacemaker, with two tined leads: an atrial lead of 5524 M (Medtronic, Dublin, Ireland) and a ventricular lead of 5024 M (Medtronic), both silicone-insulated (Fig. 1). We performed lead extraction under general anesthesia in the operating room. We deployed an LLD EZ (Spectranetics, Colorado Springs, CO) locking stylet for each lead and attempted to advance a 14-French GlideLight (Spectranetics) laser

sheath over the atrial and ventricular leads. However, significant binding in the region between the subclavian vein and the innominate vein precluded the laser sheath advancement. An 11-French TightRail (Spectranetics) rotating mechanical sheath was then deployed to overcome the binding segment. The rotating sheath crunched through the binding tissue and was slowly advanced into the superior vena cava over the ventricular lead, after which progress halted (Fig. 1A). We removed the TightRail from the body and found 1–1.5-cm-long pieces of bone-like calcified tissue lodged in the sheath lumen (Fig. 1B). After removing these ossified tissues, both leads were extracted with the laser sheath, without complications. The photomicrograph showed paucicellular fibrous tissue mainly comprised of eosinophilic material-forming layers (arrow in Fig. 2A). Focal calcification was observed (arrows in Fig. 2B), but no acute thrombus with fibrin or inflammatory cells was detected. These findings were consistent with the diagnostic symptoms of ossified thrombus.

3. Discussion

Lead extraction using a laser sheath is effective in most cases. However, long implant duration is a predictor of failed laser extraction [1,2]. Although calcification is a well-known barrier to laser extraction, its origin has not been sufficiently studied. In the present case, the barrier to the laser extraction was an ossified

* Correspondence to: Mayo Clinic, 200 First St SW, Rochester, MN 55902, USA.
Fax: +1 507 255 2550.

E-mail address: ycha@mayo.edu (Y.-M. Cha).

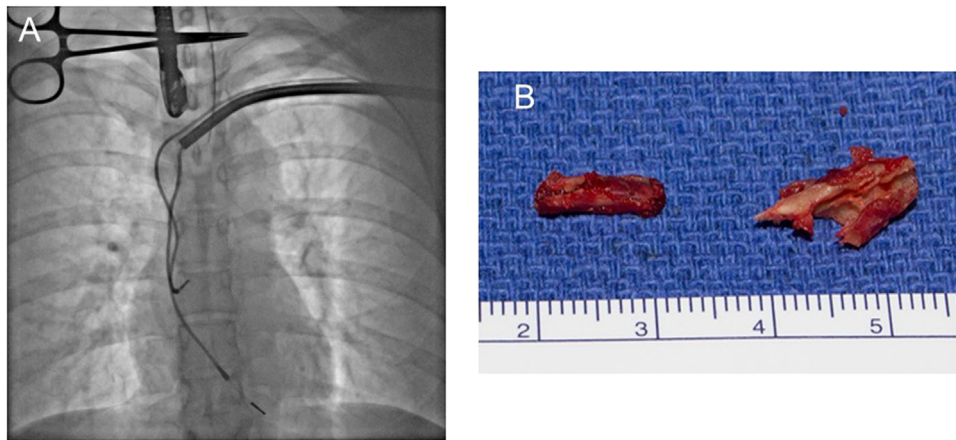


Fig. 1. A: Lead extraction using a rotating mechanical sheath. B: Bone-like tissue lodged in the sheath lumen.

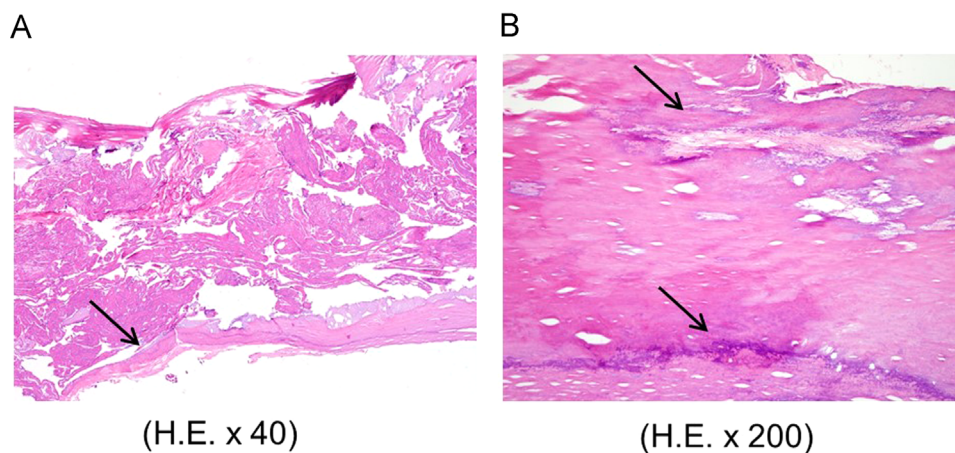


Fig. 2. Photomicrograph of the bone-like tissue stained by hematoxylin & eosin. A: $\times 40$. B: $\times 200$.

thrombus. Encapsulation of the transvenous pacing leads has been reported in canine models [3], and thrombus organization has been found to give rise to a vascularized collagenous capsule. Under continued blood flow perturbation, more thrombi can form and reorganize, causing the collagenous capsules to grow with the implant time. Under certain conditions, such as inflammation from lead insulation, the encapsulating sheath can mutate and split into cartilage, mineralized tissue, and even bone.

In the present case, the severe calcification was overcome with a rotating mechanical sheath rather than with a laser sheath. Although it was not used in this case, a simple mechanical sheath may be less expensive compared to a TightRail sheath and may be effective in overcoming calcification [4]. Although the experience with TightRail has been limited, its efficacy has been reported with positive results, equivalent to those of the laser sheath [5]. A rotating mechanical sheath might allow for transvenous lead extraction in the presence of significant ossification. For a successful procedure, it is mandatory to prepare various types of tools for lead extraction.

Conflict of Interest

Dr. Okamura is a recipient of the Medtronic Japan Fellowship for Young Japanese Investigators granted by the Japanese Heart Rhythm Society.

References

- [1] Roux JF, Page P, Dubuc M, et al. Laser lead extraction: predictors of success and complications. *Pacing Clin Electrophysiol* 2007;30:214–20.
- [2] Wazni O, Epstein LM, Carrillo RG, et al. Lead extraction in the contemporary setting: the LEXiCon study: an observational retrospective study of consecutive laser lead extractions. *J Am Coll Cardiol* 2010;55:579–86.
- [3] Strokes K, Anderson J, McVenes R, et al. The encapsulation of polyurethane-insulated transvenous cardiac pacemaker leads.
- [4] Bongiorno MT, Soldati E, Zucchelli G, et al. Transvenous removal of pacing and implantable cardiac defibrillating leads using single sheath mechanical dilatation and multiple venous approaches; high success rate and safety in more than 2000 leads. *Eur Heart J* 2006;29:2886–93.
- [5] Aytemir K, Yorgun H, Canpolat U, et al. Initial experience with the TightRail Rotating Mechanical Dilator Sheath for transvenous lead extraction. *Europace* 2015. <http://dx.doi.org/10.1093/europace/euv-245>.