



Review

A review of laser and light therapy in melasma

M.K. Trivedi, BS, BA^{a,b,*}, F.C. Yang, MD^c, B.K. Cho, MD, PhD^d^a University of Michigan Medical School, Ann Arbor, Michigan^b Department of Dermatology, University of California San Francisco, San Francisco, California^c Department of Dermatology, Brigham and Women's Hospital, Harvard Medical School, Boston, Massachusetts^d Department of Dermatology, Palo Alto Medical Foundation, Sunnyvale, California

ARTICLE INFO

Article history:

Received 29 November 2016

Received in revised form 18 January 2017

Accepted 19 January 2017

ABSTRACT

Melasma is a dysregulation of the homeostatic mechanisms that control skin pigmentation and excess pigment is produced. Traditional treatment approaches with topical medications and chemical peels are commonly used but due to the refractory and recurrent nature of melasma, patients often seek alternative treatment strategies such as laser and light therapy. Several types of laser and light therapy have been studied in the treatment of melasma. Intense pulsed light, low fluence Q-switched lasers, and non-ablative fractionated lasers are the most common lasers and light treatments that are currently performed. They all appear effective but there is a high level of recurrence with time and some techniques are associated with an increased risk for postinflammatory hyper- or hypopigmentation. The number and frequency of treatments varies by device type but overall, Q-switched lasers require the greatest number of treatment applications to see a benefit. Vascular-specific lasers do not appear to be effective for the treatment of melasma. Ablative fractionated lasers should be used with caution because they have a very high risk for postinflammatory hypo- and hyperpigmentation. The use of nonablative fractionated laser treatments compared with other laser and light options may result in slightly longer remission intervals. Picosecond lasers, fractional radiofrequency, and laser-assisted drug delivery are promising future approaches to treat melasma. The goal of this review is to summarize the efficacy and safety of the most commonly used laser and light therapies to treat melasma, briefly present future laser-based treatment options for patients with melasma, and provide recommendations for treatment on the basis of the reviewed information.

© 2017 Women's Dermatologic Society. Published by Elsevier Inc. This is an open access article under the CC BY-NC-ND license (<http://creativecommons.org/licenses/by-nc-nd/4.0/>).

Introduction

Melasma is a common and well-described dermatological condition that primarily affects female patients. It involves hyperpigmentation that is chronic, relapsing, and characterized by symmetric, brownish-grey macules and patches on the face and sometimes the neck, chest, and forearm. Melasma has also been referred to as chloasma or “the mask of pregnancy” because the condition is often associated with women who are pregnancy (Wong et al., 1984). The condition is otherwise asymptomatic and there is no clear association with a systemic illness but melasma can be psychosocially detrimental to many patients.

There is currently no definite etiology but multiple factors including ultraviolet radiation, hormonal alterations within the estrogen or

progesterone pathways, genetic predisposition, and/or inflammation have all been implicated and recently reviewed (Lee, 2015). Melasma may also have a vascular component as some studies have found melasma-affected skin to have increased vascularity (Kwon et al., 2016). The common outcome from these diverse triggers is an increased synthesis of melanosomes in melanocytes and an increased transfer of melanosomes to keratinocytes. Women with darker skin types (i.e., Fitzpatrick skin type IV–VI) are most commonly affected (Grimes, 1995).

Melasma is classified by both location and depth of involvement. The three most common types of melasma are centrofacial, malar, and mandibular, which describe the patterns of facial involvement. Melasma can be further characterized by the depth of involvement, which is often assessed by Wood's lamp illumination and divided into four categories: epidermal, dermal, mixed, and indeterminate (Grimes et al., 2005). Histologically, increased melanin in epidermal keratinocytes, dermal macrophages, or both are present (Kang et al.,

* Corresponding Author.

E-mail address: mtrivedi41@gmail.com (M.K. Trivedi).

2002). Wood's lamp can help distinguish between these entities because enhancement under the lamp suggests epidermal type and nonenhancement suggests dermal type. However, this assessment does not always correlate with histological findings and melasma that is labeled epidermal is often mixed with areas of dermal involvement (Grimes et al., 2005). Thus, Wood's lamp does not fully differentiate between mixtures of epidermal and dermal melasma but is the best method to demonstrate dermal melasma, which is less likely to respond to topical therapy.

An alternative classification with noninvasive reflectance confocal microscopy (RCM) has been suggested because it uses the ratio of epidermal-to-dermal melanin that involves the whole lesional skin (Ardigo et al., 2010). An advantage of RCM analysis is that it can non-invasively and accurately categorize the subtype of melasma as well as quantitate the response to therapy. However, RCM quantitation of melasma severity is still in its infancy.

Treatment strategy

The treatment regimen of patients with melasma typically starts with the management or elimination of risk factors, strict ultraviolet sun protection, and topical lightening formulations. Topical treatments may temporarily improve the skin but the condition often returns. The principles of therapy include the inhibition of pathways that synthesize melanin, decrease of melanosome transfer from melanocytes to keratinocytes, and acceleration of pathways to remove melanin.

Topical agents

The current first-line treatment for melasma is topical agents. The major group of topical agents to be considered are those that disrupt the enzymatic processes of pigment production within melanocytes. Tyrosinase is the rate-limiting enzyme in the melanin production process that converts L-tyrosine to L-3,4-dihydroxyphenylalanine (L-DOPA) and is the major target for many of these agents. Melanin is synthesized through a series of steps and converts the base precursor tyrosine to DOPA and then to dopaquinone, which is converted to dopachrome and eventually to eumelanin (Hearing, 2011). These types of treatments include hydroquinone (often used in combination with tretinoin and a topical steroid), arbutin, azelaic acid, and kojic acid. Ascorbic acid is also another inhibitor of melanogenesis through its antioxidant effects and interaction with copper ions in the tyrosinase active site (Sarkar et al., 2013).

Other targets for intervention in the melanin synthetic pathway include the interaction between keratinocytes and melanocyte. There are several botanical agents such as niacinamide and soy that act through protease-activated receptor-2 (PAR-2) and inhibit the transfer of melanosomes to the surrounding keratinocytes (Sarkar et al., 2013). Serine protease inhibitors, lecthins, and neoglycoproteins also affect this pathway (Briganti et al., 2003).

Improving skin turnover is another therapeutic route for the treatment of melasma. Agents that accelerate skin turnover include glycolic acid, linoleic acid, lactic acid, liquiritin, retinoic acid, and *Helix aspersa müller*. Certain fatty acids such as linoleic or α -linoleic acid may induce the degradation of tyrosinase (Briganti et al., 2003).

An overview of topical melasma treatments was recently published by Ball Arefiev and Hantash (2012) and Sehgal et al. (2011). Topical treatments may be unsatisfactory due to a lack of response, slow rates of improvement, or adverse events such as pseudo-ochronosis with hydroquinone or skin irritation, erythema, and postinflammatory hyperpigmentation (PIH; Ball Arefiev and Hantash, 2012; Sehgal et al., 2011).

Chemical peels

The addition of chemical peels to a topical treatment regimen is second-line treatment as peels help accelerate the elimination of pathways for melanin. Superficial peels such as glycolic acid, Jessner, and retinoic acid are typically selected because they tend to have the least risk of complications and exacerbation of pigmentation if there is too much inflammation or irritation. Peels have been shown to be effective, especially when used in a series of treatments (Sheth and Pandya, 2011). Chemical peels may cause melasma rebound or PIH due to irritation or inflammation.

Laser- and light-based treatments

Laser and light therapy represent an alternative third-line approach to treat melasma and may be particularly beneficial for patients with melasma that is refractory to topical therapy or chemical peel regimens, or when a patient wishes for an accelerated pace of improvement. Analogous to chemical peels, these modalities accelerate the removal of pathways for melanin but do not target the melanin production itself. One key point of patient counseling prior to laser- and light-based treatment is that these therapies have the potential to speed up the removal of melasma-related hyperpigmentation but they are not cures for melasma. Furthermore, they present a risk for PIH or a rebound melasma flare. Optimal treatment management of difficult cases should include a combination therapy whereby a topical regimen inhibits melanin production and/or melanosome transfer and a procedure accelerates melanin removal.

The lesions of melasma are not the only hyperpigmented lesions that are successfully treated with laser and light therapy. Hori's nevus, which often appears as macular blue-gray lesions in a bilateral facial distribution similar to melasma, has been successfully treated with Q-switched lasers in a handful of studies within the last 2 decades. This suggests that laser and light therapy holds promise as an effective treatment for a variety of hyperpigmentation conditions (Polder et al., 2011).

Overview of laser- and light-based treatment options

The theory of laser therapy to treat cutaneous disorders was first explored by Anderson and Parrish in 1983. They noted that pigmented structures within tissue demonstrated specific thermal and absorptive properties that allowed them to be targets for selective destruction with specific wavelengths of radiation while sparing the surrounding tissue. Therefore, various targets that range from unwanted hair to tattoo ink could be specifically targeted for removal with minimal effect on the surrounding normal skin. Since that time, light and laser therapies have been used for multiple dermatologic and cosmetic conditions including vascular birth marks, telangiectasias, hypertrichosis, tattoos and pigmented lesions, solar lentiginous, lentiginous nevi, café-au-lait macules, and melasma (Patil and Dhami, 2008).

Laser therapy for the treatment of melasma has become an alternative to the more common treatments with topical creams and chemical peels, especially for patients with refractory cases. A multitude of different laser therapies have been studied in numerous clinical trials to date and a vast range of efficacies and adverse events have been demonstrated. Frequently, the outcomes of these studies are reported through physician-graded assessments or changes in the melasma area severity index (MASI). The five broad categories of laser and light therapy include intense pulsed light (IPL), Q-switched lasers, picosecond lasers, nonablative fractionated resurfacing lasers, and ablative fractionated resurfacing lasers. The objective of this review is to comment on both the efficacy and safety of the most commonly used laser and light therapies for the

treatment of melasma as published in the current literature and present new device-based treatment options that are currently in development for patients with melasma.

Intense pulsed light

IPL therapy uses a flash lamp light source that emits noncoherent light with wavelengths between 515 nm and 1200 nm. Filter sets allow for the targeting of selective chromophores (melanin vs. hemoglobin) and has been used to treat various pigmentary disorders. Its potential advantage over laser therapy is that it uses a spectrum of wavelengths that allow for the penetration of various levels of the skin and target both epidermal and dermal melasma simultaneously. The pulse duration of IPL is in the millisecond range and provides greater thermal diffusion and a reduced chance of thermal-related postinflammatory pigmentation. The size of the IPL head is larger than most laser spot sizes, which allows for the rapid treatment of large areas.

Wang et al. (2004) compared the application of a 4%-hydroquinone cream versus 4% hydroquinone plus IPL in a prospective randomized control trial in which 17 patients were treated with four sessions of IPL over a 16-week period. A spectrophotometer was used to measure a relative melanin index, defined as the difference between the melanin index of lesional skin and the melanin index of normal skin. After treatment completion, the group of patients that was treated with IPL plus hydroquinone demonstrated a reduction of 39.8% in relative melanin index compared with 11.6% for the patients in the control, hydroquinone-only treatment group ($p < .05$). Although the study demonstrated the effectiveness of IPL as a potential treatment, two patients developed PIH and 24.2% of the participants who improved with IPL developed recurrent pigmentation within 24 weeks post-treatment (Wang et al., 2004). Side effects of the therapy with IPL included crusting that lasted 1 to 2 weeks.

Goldman et al. showed that IPL could be particularly helpful to treat moderate-to-severe melasma if combined with more aggressive topical maintenance treatment to minimize pathways for pigment recurrence. The researchers completed a 10-week study of 56 patients who were randomized to receive either IPL with a triple combination cream (TCC) or IPL with a placebo cream (PC). The TCC contained 4% hydroquinone, 0.05% tretinoin, and 0.01% fluocinonide acetone. At week 10, 57% of patients in the IPL with TCC group were clear or almost clear in contrast to 23% of patients in the IPL with PC group (Goldman et al., 2011). A similar finding was reported by Figueiredo and Trancoso (2012) who compared outcomes of patients treated with IPL and TCC versus TCC therapy alone. The MASI scores of patients in the IPL/TCC group showed a 49.4% reduction from baseline at 6 months and maintained a 44.9% reduction from baseline at 12 months (Figueiredo and Trancoso, 2012).

The effectiveness of IPL therapy on epidermal versus other mixed melasma was assessed by Li et al. (2008) who found that 77.5% of patients obtained >51% of improvement after four IPL therapy sessions by dermatologist assessment. Mean MASI scores decreased from 15.2 to 4.5. Patients with the epidermal type of melasma responded better to treatment compared with those with the mixed type (Li et al., 2008).

Overall, IPL therapy appears to give modest improvement in patients with melasma that is refractory to topical therapy alone but have a modest recurrence rate unless an aggressive topical therapy is maintained at least 6 to 12 months post-treatment. IPL therapy is best suited to treat patients with Fitzpatrick skin types 1 to 3 because use with patients who have a darker skin type carries an elevated risk to target normal endogenous skin pigment. Patients with epidermal melasma may respond more favorably to IPL therapy compared with those with mixed or dermal melasma.

Q-switched lasers

Q-switched lasers produce high intensity laser beams with very short pulse durations. The speed of a Q-switched laser pulse is approximately one million times that of an IPL pulse. Q-switched lasers that target melanin are available in multiple wavelengths including ruby (694 nm), alexandrite (755 nm), and neodymium-doped yttrium aluminum garnet (Nd:YAG; 532 nm or 1064 nm). Because these lasers are standard therapies for the removal of birthmarks, solar lentigines, and tattoos, they were expected to be effective for the treatment of patients with melasma as well. However, the results from studies on the use of Q-switch lasers were disappointing and treatments were complicated by significant rebound hyperpigmentation. In the publication of the results from one trial that studied the effects of the Q-switched ruby laser to treat patients with melasma and PIH that is refractory to other treatments, the authors noted that there was no improvement and in some cases a deterioration with the laser treatments regardless of the fluence. Several months after the last treatment, epidermal pigmentation was back to baseline levels and dermal melanophages were increased (Taylor and Anderson, 1994). In a split-face trial that studied the effectiveness of the Q-switched ruby laser versus an erbium:yttrium-aluminum-garnet (Er:YAG) laser to treat pigmented lesions, the investigators found that the three study patients who were treated for melasma were the only participants who did not have an improvement in their condition. In fact, the patients with melasma developed PIH and deteriorated as a result of the therapy (Tse et al., 1994). Angsuwarangsee and Polnikorn (2003) conducted a split-face study where half of the patients' face was treated with a Q-switched alexandrite laser and the other half with combined carbon dioxide (CO₂) and Q-switched alexandrite laser therapy. The side that was treated with the Q-switched alexandrite laser did not show a significant benefit and two of six patients who were enrolled in the study developed severe PIH (Angsuwarangsee and Polnikorn, 2003).

A new variant of Q-switched laser use called low fluence or subthermolytic Q-switched treatment is gaining increasing popularity. The lasers are the same but the fluences are lower than those that are traditionally used to treat pigmented lesions. The low-fluence treatments largely utilize the 1064 nm wavelength, which penetrates deeper into the dermis and leaves the epidermis relatively spared. The treatment of patients with melasma with subthermolytic low fluences is based on the theory that the pigment disruption takes place through a photoacoustic mechanism that breaks apart the pigment only and spares the keratinocytes and melanocytes from destruction. However, there is often some degree of damage that accompanies subthermolytic Q-switched treatment but this damage is reported to be less than that from traditional photothermolytic treatment.

A 2010 split-face randomized study by Wattanakrai et al. (2010) treated 22 patients with Fitzpatrick skin types III to V with dermal or mixed type melasma and compared treatment with low-fluence Q-switched Nd:YAG laser and topical 2% hydroquinone versus 2% hydroquinone alone. Each patient was treated with 3.0 J/cm² to 3.8 J/cm², 6 mm spot size at 10 Hz for five sessions at one week intervals. The researchers found that the laser-treated side of the face achieved an average of 92.5 % improvement in relative lightness index versus 19.7 % on the hydroquinone-treated side. There was also a 75.9 % improvement in the modified MASI (mMASI) score on the laser-treated side versus 24 % on the hydroquinone-treated side. However, three of 22 patients (all with Fitzpatrick skin type V) developed mottled hypopigmentation after five laser treatments and eight patients developed confetti type hypopigmentation. Three months after treatment, four patients had developed rebound hyperpigmentation and there was a 100% recurrence rate although the degree of lightening

on the laser-treated side was still greater than or equal to the degree of lightening on the control side (Wattanakrai et al., 2010).

The high melasma recurrence rate despite use of Q-switched treatment at low fluences was also found in a study by Xi and colleagues in which 50 patients were treated with 9 weekly treatments with a 1064 nm Qs Nd:YAG laser. The study results demonstrated a 61.3% mean decrease in MASI score after the ninth treatment but there was a 64% recurrence rate 3 months posttreatment. This study was also interesting because several patients completed RCM imaging throughout the study. These imaging studies showed that the Q-switched laser was effective at removing melanin particles in the basal layer but by the 3-month follow-up examination, melanin levels had largely returned to the baseline level (Xi et al., 2011).

A prospective investigator-blinded study by Hofbauer Parra et al. (2016) in which 20 Brazilian patients received 10 laser treatments demonstrated decreased mMASI scores from 7.85 to 4.33 ($p < .001$) after the final treatment. Recurrence rates were similar to those in previous studies with an 81% recurrence rate at 3-months posttreatment. However, no severe side effects such as hypo- or hyperpigmentation were reported, leading the authors to conclude that low-fluence Q-switched Nd:YAG laser therapy is safe to treat patients with melasma. However, the high recurrence rates suggest poor long-term results when the laser is used as a monotherapy (Hofbauer Parra et al., 2016).

Similar to IPL treatments, the use of topical hydroquinone preparations can help reduce melasma recurrence and one study suggests that pretreatment hydroquinone is more effective than posttreatment hydroquinone (Jeong et al., 2010). Of note, the U.S. Food and Drug Administration (FDA) approved Lutronic's dual-pulsed Q-switched Nd:YAG laser, Spectra, in 2012 for the treatment of patients with melasma. It is the first and only approved Q-switched laser therapy for the treatment of patients with melasma.

In summary, Q-switched laser therapy at the fluences that is used to treat benign pigmented lesions has not been effective. Low-fluence Q-switched laser therapy and in particular Nd:YAG has shown some initial promise but requires multiple treatments over a relatively short treatment interval (weekly) and has extremely high 3-month recurrence rates (64%–81%). The number of required treatments is generally more than those for other light- and laser-based treatment modalities. Several recent studies suggest that fractionating the laser energy (Yue et al., 2016) or combining low-fluence Q-switched lasers with long-pulsed Nd:YAG (laser toning [Kang et al., 2011] or IPL [Vachiramon et al., 2015; Yun et al., 2014]) may reduce the recurrence rate. However, until the recurrence rate is reduced significantly in a reproducible way and the relatively high rates of posttreatment dyspigmentation are resolved, Q-switched laser therapy for patients with melasma is likely reserved for very recalcitrant cases that have failed with other laser modalities first.

Nonablative fractionated resurfacing lasers

Fractional resurfacing, which was introduced in 2004, creates selective columns of microthermal damage in which treated areas are intermixed with untreated ones. Thus, recovery is more rapid and theoretically the resulting inflammation is lower, which lessens the risk for scarring or dyspigmentation (Manstein et al., 2004). Fractional resurfacing can be broadly categorized into nonablative fractional laser (NAFL) and ablative fractional laser (AFL).

NAFL devices target water-containing tissues but create columns of coagulative damage within the dermis that are below the ablative threshold. The stratum corneum is intact throughout the treatment and a visible wound does not occur. The most common affect immediately posttreatment is erythema and swelling. Four NAFL wavelengths are used including 1440 nm, 1540 nm, 1550 nm, and 1927

nm. NAFL at 1440 nm, 1540 nm, and 1550 nm utilizes midinfrared wavelengths that bypass the epidermis and penetrate from the dermal-epidermal junction to the midreticular dermis (maximum depth approximately 1500 microns) to induce neocollagenesis and remodeling. The transepidermal elimination of these microthermal treatment zones in the weeks posttreatment is hypothesized to facilitate the removal of dermal melanophages and be the main mechanism for melasma improvement (Hantash et al., 2006). NAFL at the 1550 nm wavelength has been approved by the FDA since 2005 for the treatment of patients with melasma. There is little published data on the 1440 nm wavelength with regard to melasma treatment although Kouba et al. (2008) suggested that it was beneficial to treat another dermal melanocytic lesion, Nevus of Ota, and may have utility toward dermal melasma (Kouba et al., 2008). Erythema, swelling, and pain are common with NAFL at 1440 nm, 1540 nm, and 1550 nm but these are short-term side effects that typically last for 3 to 10 days and overall, this treatment is considered a low downtime, fast recovery procedure. PIH is a reported side effect in most of the clinical trials. The development of PIH seems to be correlated with the density of the microthermal zones and possibly a byproduct of the heat that is generated during treatment.

The initial studies with the laser of 1550 nm reported that six of 10 female patients with recalcitrant melasma had 75% to 100% clearance at the 3-month interval after four to six treatments on the basis of physician-graded assessments (Rokhsar and Fitzpatrick, 2005). Lee et al. (2009) treated 25 patients with melasma with 1550 nm NAFL monthly for four treatment sessions. Sixty percent of patients were graded by investigators to have improved after completion of the study but the number dropped to 52% at the 6-month posttreatment assessment (Lee et al., 2009).

A direct comparison between NAFL with 1550 nm and triple therapy topical cream to treat melasma was completed in a randomized, controlled, observer-blinded study by Kroon et al. (2011). Twenty female patients with Fitzpatrick skin types II to IV either applied a mixture of 5% hydroquinone, 0.05% tretinoin, and 0.1% triamcinolone acetone cream once daily for 8 weeks or received laser treatment once every 2 weeks for a total of 4 treatments. Improvement as measured by the physician global assessment was equal between both groups but treatment satisfaction and recommendation was higher in the laser group. Recurrence was present in 50% of treated patients in both groups at 6 months. No complications from PIH were reported. The study investigators concluded that therapy with 1550 nm NAFL was safe and comparable in efficacy and recurrence rate with triple topical therapy. It may be a useful alternative treatment option for patients with melasma when topical bleaching is ineffective or not tolerated (Kroon et al., 2011).

Wind et al. (2010) performed a similar randomized study but used a split-face approach where one side of the face was treated with 1550 nm NAFL for four to five sessions and the opposite side of the face received a triple therapy topical melasma cream (i.e., the same cream used by Kroon et al., 2011). The mean physician global assessment and patient satisfaction scores were significantly lower for the side that was treated with the laser and 31% of patients were reported with PIH. The authors concluded that the relatively higher fluence that was used (15 mJ) versus the fluence used in the Kroon study (10 mJ) could be a contributing factor (Wind et al., 2010).

The efficacy of NAFL in combination with triple therapy topical cream to treat melasma was assessed by Tournalaki et al. (2014) who used a 1540-nm device to treat 76 patients with recalcitrant melasma. Changes were assessed with MASI scores. At 1 month, 67.1% of patients had >75% clearing and 21% had 51% to 75% clearing. At 6 months, only 21.1% of patients maintained a marked improvement despite the application of the triple therapy topical cream (Tournalaki et al., 2014).

The 1927-nm NAFL laser was first introduced in 2009 and has been used to provide superficial resurfacing primarily for hyperpigmentation. The thulium fiber 1927-nm laser has an approximate 10-times greater absorption coefficient for water compared with the 1440-, 1540-, and 1550-nm lasers. Because of this, the 1927-nm NAFL laser only penetrates to a maximal depth of approximately 200 microns, which corresponds to the general location of epidermal melasma where melanosome and melanophages localize to the dermo-epidermal junction (DEJ) and superficial dermis. Polder and Bruce (2012) completed the pilot studies on 1927-nm NAFL therapy and melasma. Fourteen patients with melasma were treated at 1-month intervals and completed three to four treatments with fluences of 10 mJ to 20 mJ and total densities of 252 MTZ/cm² to 784 MTZ/cm². Participants had erythema, edema, and microcrust formation that lasted approximately 3 to 7 days. No scarring or postinflammatory hyper- or hypopigmentation was observed. Patient MASI scores improved 51%, 33%, and 34% at 1, 3, and 6 months after completion of the treatment series, respectively (Polder and Bruce, 2012), which suggests that the 1927-NAFL laser may offer safe and effective treatment for patients with melasma.

Lee et al. (2013) completed a split-face single-blinded study of 25 Asian female patients with hyperpigmentation of whom eight patients had melasma. Fluence was set at 10 mJ, density at treatment level 3, and patients received three treatments at 3-week intervals. MASI scores on the treated side of the face improved 33% at 2 months versus 5% on the control side. At 6 months posttreatment, the treated side of the face maintained a 28% improved MASI score compared with 12% on the control side. Histologic studies of the treated skin showed reduced melanin levels but melanocyte density by Melan-A immunostaining was unchanged. The treatment-associated discomfort was less than compared with 1550-nm NAFL treatment (Lee et al., 2013).

The long-term efficacy of 1927-nm NAFL therapy was assessed by Niwa Massaki et al. (2013) who completed a 12-month retrospective review of 20 women with melasma who had completed a single 1927-nm NAFL treatment. Treatment settings ranged from 10 mJ/cm² to 20 mJ/cm² with 60% to 70% surface area coverage, and total energies from 1.72 kJ to 4.42 kJ. After treatment, patients maintained treatment with 4% hydroquinone cream starting 1 month post-laser treatment. Sixty percent of patients had more than 50% clearance of their melasma 1 month after the single laser treatment session. MASI scores continued to be improved 53.8% over baseline at 6 months to 12 months post-laser treatment. However, 33.3% of patients reported at least a partial recurrence and 13% reported full recurrence of melasma on average by 10.2 months after laser treatment. Treatment of two patients was complicated by PIH, which resolved within 3 months of treatment. The investigators concluded that 1927-nm NAFL therapy offered good clearance of melasma in a single treatment in contrast to NAFL therapy with 1440-, 1540-, and 1550-nm lasers, which required four to six treatments to reach similar endpoints (Niwa Massaki et al., 2013).

NAFL treatment in general seems to offer a more durable response in comparison with IPL and Q-switched laser treatments especially when patients maintained treatment with a topical anti-Tyrosinase cream before and after treatment. Although there is recurrence with all NAFL treatments, the data suggests that recurrence occurs between the 3 month to 6 month range whereas IPL and Q-switched laser recurrence tends to occur before 3 months. The number of treatments that are required for a benefit with NAFL seems comparable with those that are reported for IPL (approximately four) and approximately 50% fewer treatments compared with Q-switched laser therapy, which is often done weekly for eight to ten treatments.

NAFL with the 1927-nm device may offer more effective single treatment response compared with all other devices although the

type of melasma (epidermal or dermal) that 1927-nm NAFL is best suited for has yet to be determined. The benefit of NAFL is its ability to treat a wider range of skin types including Fitzpatrick skin types III to VI compared with IPL and Q-switched lasers, which should only be used on skin types I to III. Lastly, because of the fractionated mechanism, NAFL may also be better at blending melasma with the surrounding unaffected skin.

Ablative fractionated resurfacing lasers

Ablative fractionated resurfacing lasers (AFL) such as CO₂ lasers and erbium:YAG lasers have been reported for the treatment of patients with melasma (Morais et al., 2013). The CO₂ laser emits a 10,600-nm wavelength, which is strongly absorbed by water in the skin cells. The penetration depth is dependent on the water content and independent of either melanin or hemoglobin. A fractionated approach decreases the amount of epidermal injury and therefore results in fewer side effects and less risk of dyspigmentation. It has also been suggested that the microscopic injury zones that are caused by fractionated ablation allow for the transport of necrotic epidermal debris including melanin through the DEJ. Early results with a nonfractionated CO₂ laser highlighted the risks for PIH.

Angsuwarangsee and Polnikorn (2003) performed a split-face trial to study the efficacy of a Q-switched alexandrite 755-nm laser with or without one pass of an ultrapulsed CO₂ laser in six female patients with refractory melasma. Three patients developed PIH on both sides of the face 2 to 4 weeks postprocedure and one patient developed hypopigmentation. Given the risk of postoperative dyspigmentation, the authors concluded that neither modality was safe enough to recommend for routine use to treat patients with melasma (Angsuwarangsee and Polnikorn, 2003). Few trials with fractional CO₂ lasers have been completed to date. Trelles et al. (2010) assigned 30 female patients with melasma to one of three treatment groups: topical melasma cream (Kligman's formula), CO₂ ablative fractional resurfacing, and a combination of both treatments. The results of the patients who underwent combined treatment with CO₂ laser and long-term topical lightening cream showed the greatest improvement and were able to maintain the treatment benefits up to the 12-month posttreatment. Patients in the other groups were unable to sustain their initial improvement (Trelles et al., 2010).

The cutaneous absorption of the Er:YAG laser energy by water (2940 nm) is 10-fold more efficient than that of the carbon dioxide laser and allows for more superficial tissue ablation but with minimal thermal damage. There are very few studies on the use of erbium:YAG to treat patients with melasma. Manaloto and Alster (1999) treated 10 female patients with refractory melasma using erbium:YAG laser at energy levels of 5.1 J/cm to 7.6 J/cm. There was a marked improvement of melasma immediately posttreatment. However, between 3 and 6 weeks postoperatively, all patients developed PIH despite the use of oral steroid drugs for 5 days postprocedure (Manaloto and Alster, 1999). Wanitphakdeedecha et al. (2009) treated 20 female patients with epidermal melasma monthly for a total of two treatments with an Er:YAG laser. Both melanin index and MASI score showed a significant improvement at the 2-month but not the 4-month follow-up visit. Furthermore, clinical improvement as assessed by dermatologists who were blinded to the treatment showed that only 15% of patients sustained improvement that was greater than 50% after 4 months of follow-up (Wanitphakdeedecha et al., 2009).

Picosecond lasers

Recent innovations in laser design have introduced a new class of lasers that generate picosecond-domain pulses. Shorter laser pulse durations result in pigment fragmentation that is more a result of

photoacoustic than photothermal effects. Therefore, it may be more efficient at pigment removal without inducing thermal damage to surrounding tissue. This thermal damage seems to be the greatest drawback of conventional Q-switched laser treatment for patients with melasma and likely the cause of the high PIH rates after treatment.

Picosecond lasers are currently available with laser outputs of 532 nm, 755 nm, and 1064 nm. Thus far, however, no data has been published about their efficacy in patients with melasma either using settings for benign pigmented lesions like solar lentigos or at low fluence treatments that are analogous to low fluence Q-switched laser treatment. More recently, fractionated picosecond handpieces have been developed for the purpose of resurfacing and rejuvenation. Only a few clinical studies have been completed with these new devices and thus far, no results with regard to melasma have been reported. Due to the potential of picosecond lasers to work via photoacoustic mechanisms, they may present a new treatment modality that is suitable for patients with melasma.

Other laser treatments

Other types of laser therapy include pulsed dye lasers (PDL; 585 nm) and copper bromide (CuBr; 511–578 nm) lasers, which are thought to work by targeting the vascular component of melasma. Passeron and colleagues published a study in 2011 that combined PDL therapy at purpuric settings with triple combination topical therapy. The combination therapy was beneficial in patients with Fitzpatrick skin types II and III but half of the patients with darker skin developed PIH (Passeron et al., 2011). An early 2010 study by Lee and colleagues of four women who had telangiectatic erythema within their melasma suggested that targeting the vascular component with a CuBr laser led to reduced MASI scores (Lee et al., 2010). However, two follow-up studies, one with CuBr laser only (Eimpunth et al., 2014) and the other with combined CuBr laser/triple combination topical therapy (Hammami Ghorbel et al., 2015) failed to demonstrate effectiveness. Overall, targeting vascularity as a treatment for patients with melasma has not shown a significant benefit.

Future roles of lasers or other devices in the treatment of melasma

In the future, lasers or other devices may contribute to the treatment of patients with melasma not only by targeting pigment

directly but by facilitating the delivery of topical medications, which is a technique that is known as laser-assisted drug delivery (LADD). Currently, most topical therapeutic treatments have poor bioavailability due to the difficulty to penetrate the skin barrier. With LADD, CO₂ or Erb:Yag ablative lasers create a matrix of trans-epidermal channels that provide direct access to deeper layers of the skin and facilitate cutaneous and transcutaneous drug delivery. By manipulating the density and depth of these channels, it appears possible to manipulate the amount of drug that is absorbed, the delivery rate, and the drug biodistribution, which may lead to improved clinical efficacy. LADD with ablative lasers has the largest body of evidence for efficacy and particularly as a pretreatment to enhance the penetration of aminolevulinic acid or methylaminolevulinic acid prior to photodynamic therapy (Haedersdal et al., 2016). However, studies are ongoing to assess the delivery of numerous substances with multiple laser modalities (Haedersdal et al., 2016; Zaleski-Larsen and Fabi, 2016). At least one recent study has shown the potential of nonablative fractional lasers to deliver small- and macro-molecules (Lee et al., 2016). The hope is that LADD may offer a more effective way to deliver medications especially for the dermal type of melasma for which topical delivery seems to be out of reach and has limited success.

Analogous to LADD, microneedle (MN) technology creates micron-sized pores through the epidermis to facilitate the transport of therapeutic molecules into the epidermis. Instead of a laser, microneedling uses a roller device with hundreds of micron-length needles that create an array of pores to act as aqueous transport pathways through the stratum corneum. These micropores are larger than the pores that are created by LADD and may permit the transport of hydrophilic macromolecules, peptides, deoxyribonucleic acid, and small interfering ribonucleic acid constructs (Donnelly et al., 2010). MNs are now exploited in the cosmeceutical industry as a means to disrupt the skin cell architecture and induce elastin and collagen expression and deposition. They are also used as a means to deliver cosmeceutic molecules across the skin (McCrudden et al., 2015).

At least one small retrospective study has suggested that MN may improve melasma. In this study, 22 patients with Fitzpatrick skin types I to III, Wood's lamp testing confirmed melasma that is recalcitrant to sun protection and topical lightening creams completed two MN treatments one month apart. The MN device had needles that were 1.5 mm in length and the technique required back and forth movements approximately ten times in four different directions.

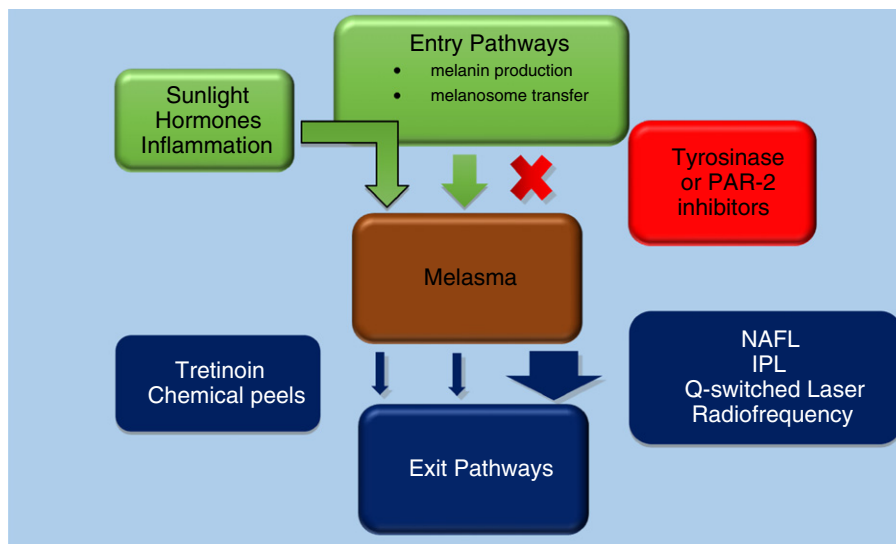


Figure 1. Mechanistic Overview of Melasma Pathology and the Effects of Topical and Laser/Light/Device Procedures

Table 1

Proposed therapeutic ladder for melasma

First-line Therapy	Control of risk factors (sun protection, discontinue hormone treatments or photosensitizing medications) <ul style="list-style-type: none"> - Topical anti-Tyrosinase therapy - Other inhibitors of the melanin synthetic pathway (e.g., protease-activated receptor-2 inhibitor) - Topical exfoliant - Triple combination topical cream, if tolerated
Second-line Therapy	Combination of first-line treatments + series chemical peels
Third-line Therapy	Combination of first-line treatments with: <ul style="list-style-type: none"> - NAFL (1927 nm) - NAFL (1550 nm, 1540 nm, or 1440 nm) - Fractional radiofrequency devices
Fourth-line Therapy	Combination of first line treatments with: <ul style="list-style-type: none"> - Intense pulsed light (test spots) - Q-switch laser

NAFL, nonablative fractional laser.

Within 24 hours of treatment, patients were instructed to apply a combination of 0.05% tretinoin, 4% hydroquinone, and 1% fluocinolone acetonide daily and maintain the topical regimen for at

least 30 days after treatment. Patients were judged subjectively by the investigator who indicated that all 22 patients had some degree of improvement (Lima, 2015).

Radiofrequency (RF) devices have become much more popular in the last few years due to their efficacy in tightening and rejuvenation, high safety profile, and minimal posttreatment recovery time. RF devices create an electrical current that, when in contact with tissue, encounters impedance and creates heat energy that in turn stimulates collagen production. Furthermore, RF technology is independent of pigment; therefore, it is safe to use in patients of all skin types and has a low risk of hyperpigmentation unless too much bulk heating occurs or arc burns are created on the surface of the skin from inadequate contact with the skin.

One study used a monopolar RF device to facilitate the drug delivery of phytocomplex of 1% kojic acid in 50 patients who were treated weekly for 6 weeks and evaluated pretreatment, at 1 month, and at 6 months. There was sustained MASI score improvement after 1 month that seemed to continue without adverse effects until the 6-month follow-up visit (Cameli et al., 2014). Fractional RF is a new development in which pins are inserted into the skin, which results in fractional treatments that range from nonablative to minimally ablative. The pins vary in depth and density and some are even

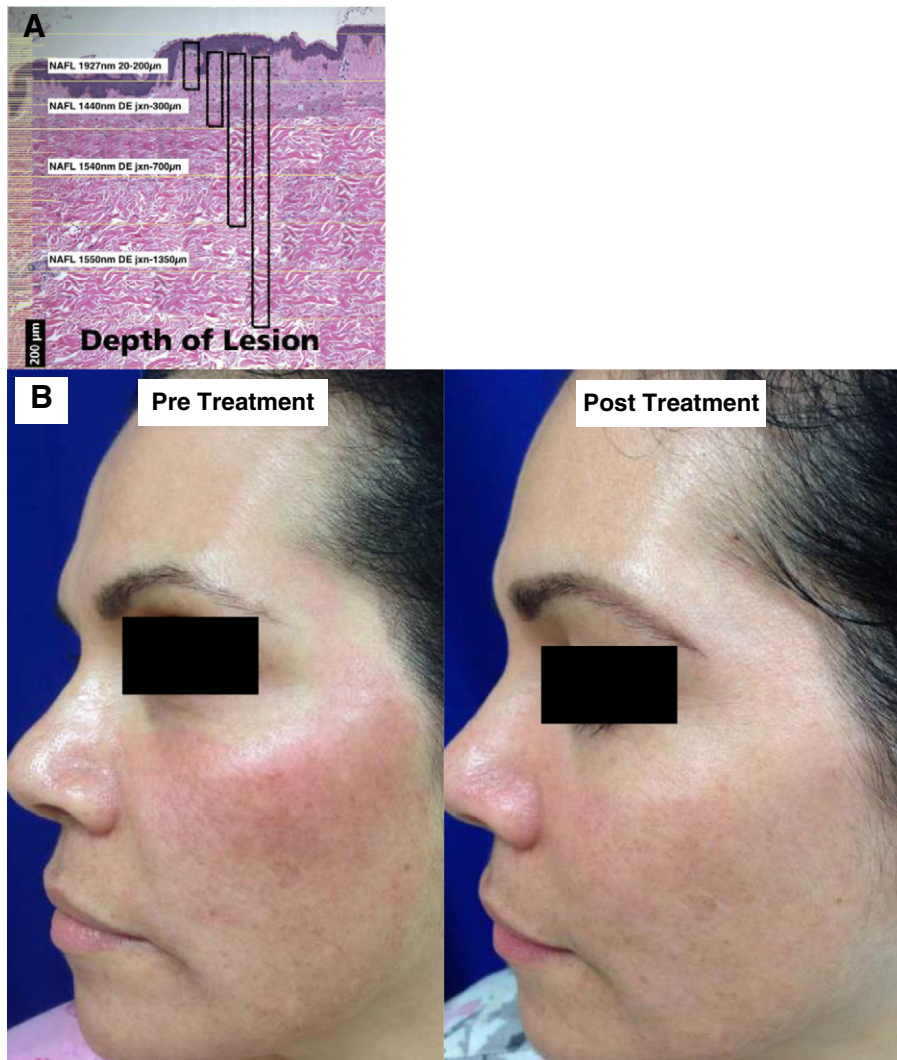

Figure 2. A. Non ablative fractionated laser treatment zones by depth of penetration B. Response to a single treatment of non ablative fractionated 1927 nm laser (Fraxel, Solta, 20mJ/mb, TL 2, Passes 8).

silicone-coated at the base to minimize epidermal damage. Conceptually, this is a promising device for patients with melasma given its ability to create fractionated transepidermal elimination of melanin with minimal risk of postinflammatory hyperpigmentation. Furthermore, we can utilize the technology for LADD similar to MN (Chandrashekar et al., 2014).

Discussion and conclusion

The mechanism of melasma remains to be fully elucidated but current research suggests it is a multifactorial condition where pathways of pigment homeostasis are disrupted in the epidermis, extracellular matrix, and dermis (Kwon et al., 2016). The sum of these changes is that the pathways for pigment production are greater than the sum of the pathways for pigment elimination (Fig. 1). As a result, melanosomes accumulate at the DEJ, the papillary dermis, or deeper.

Laser and light therapy for the treatment of melasma is best suited for patients with refractory melasma who failed with topical treatment or a series of chemical peels. Topical therapy takes at least three months or longer to see skin lightening and those patients who are interested in a more rapid response could consider laser and light therapy. A proposed therapeutic ladder for melasma is indicated in Table 1. Counseling prior to treatment should disclose that procedural treatments are not cures for melasma but studies have shown that lightening of the affected skin can occur after a series of treatments. Patients should also be counseled on the likelihood of recurrence, PIH, and rebound hyperpigmentation. A significant number of patients (approximately 50%) will have recurrence to some degree within three to six months of their laser- and light-based procedure regardless of the type of device used. The longest delay in recurrence seems to be with NAFL treatments, IPL has an intermediate recurrence rate, and Q-switched lasers have the fastest rate of recurrence. However, limitations in interpreting these disparate clinical studies include varied skin phototypes and patient populations, variable grading systems used to assess improvement or recurrence and very few of these studies are randomized controlled studies.

The goal of melasma therapy is to limit the entry pathways and increase the exit pathways so that there is net loss of pigment. Once the desired amount of lightening is achieved, the next step is to find a maintenance regimen that keeps the entry and exit pathways in equilibrium. This may involve control of risk factors, topical treatments, sporadic procedural treatments, or a mixture of these techniques. The proper choice of procedural treatment will have to integrate the patient's melasma-specific medical history, Fitzpatrick skin type, melasma type (epidermal, mixed, or dermal), other forms of hyperpigmentation that may be present within the melasma sites, and pre- and post-procedure topical therapy and maintenance treatments.

The patient's medical history and current and prior procedural treatments for melasma are important. If no preventative treatment or topical lightening regimen is used, a treatment regimen should be initiated at least two to six weeks prior to the procedure treatment. One unifying concept in all the laser and light therapies that

Table 3
Proposed post-treatment regimen

Immediate Posttreatment	Topical Tyrosinase inhibitor immediately posttherapy High potency topical corticosteroid two times daily for 3 days postprocedure
Two Weeks Posttreatment	Control of risk factors (sun protection, discontinue hormone treatments) with: <ul style="list-style-type: none"> - Topical anti-Tyrosinase therapy daily - Other inhibitors of the melanin synthetic pathway (e.g., PAR-2 inhibitor)
Long-term Posttreatment	Control of risk factors (sun protection, discontinue hormone treatments) with: <ul style="list-style-type: none"> - Topical anti-Tyrosinase therapy daily - Other inhibitors of the melanin synthetic pathway (e.g., PAR-2 inhibitor) - Resume topical exfoliant daily, if tolerated - Resume triple combination topical cream, if tolerated

PAR-2, protease-activated receptor-2.

have been tested so far is the synergism between topical anti-Tyrosinase treatment and the laser and light procedure. In general, pretreatment and posttreatment topical regimens in conjunction with laser and light treatment helps reduce the risk for rebound hyperpigmentation, postinflammatory pigmentation, and increases the longevity of the lightening effect on melasma. To control risk factors for melasma by use of avid sun protection and avoidance of hormonal triggers is also important to maintain the benefits from laser treatment. Understanding what prior procedural treatment failures the patient has experienced will generally help narrow the field of alternative options to discuss.

Patients with lighter-colored skin types (Fitzpatrick type I-III) will generally have less risk for PIH or postinflammatory hypopigmentation. They may be more tolerant of any of the laser and light treatment options that are presented above. Patients with darker skin types (Fitzpatrick type IV-V) will likely have a higher risk with Q-switched lasers, and IPL and NAFL treatment options may have a higher benefit-to-risk ratio and be better at blending the melasma-affected areas with normal skin. If Q-switched lasers and IPL treatments are used in patients with darker skin types, pretreatment test spots at the periphery of the affected areas that are completed several weeks before any larger surface areas treatment may be warranted but there is some debate as to whether or not these test spots are truly a good indication of whether someone will have adverse reactions.

Most of the clinical studies for laser- and light-based treatments are not categorized by type of melasma (epidermal, mixed, or dermal). For some procedures such as NAFL, knowing the type of melasma may be beneficial because the different NAFL wavelengths penetrate to different depths within the skin that are more likely to be effective. For instance, NAFL at 1927 nm penetrates just under the stratum corneum to a depth of 200 microns, NAFL at 1440 nm works from the DEJ to a depth of 300 micron, NAFL 1540 nm from the DEJ to 725 microns, and NAFL at 1550 nm from the DEJ to 1350 microns (Fig. 2a). The depth for each device is adjustable by changing the fluence. A Wood's lamp examination is probably sufficient to highlight patients with a significant epidermal melasma component or mainly dermal melasma but provides little information about the depth of pigment within the dermis or the ratio of epidermal or dermal melasma in mixed situations.

Epidermal melasma is likely more responsive to NAFL at 1927 nm (Fig. 2B) whereas dermal melasma is likely more sensitive to NAFL at 1440-nm, 1540-nm, and 1550-nm wavelengths. As noninvasive imaging techniques such as reflectance confocal microscopy, electrical impedance spectroscopy, or optical coherence tomography

Table 2
Proposed pretreatment regimen

Two to Six Weeks Pretreatment	Control of risk factors (sunprotection, discontinue hormone treatments) with: <ul style="list-style-type: none"> - Topical anti-Tyrosinase therapy daily - Other inhibitors of the melanin synthetic pathway (e.g., protease-activated receptor-2 inhibitor)
--------------------------------------	--

improve, a better idea of the depth of treatment needed to treat patients with dermal melasma may become clearer. At this time, most NAFL at 1440 nm, 1540 nm, and 1550 nm is done with settings that are focused on the papillary or mid-dermis. Some of the suggested mechanisms for melasma involve dermal extracellular abnormalities. NAFL affects all the substrates within their microthermal treatment zones, unlike Q-switched lasers or IPL that only target pigment itself. Correction of these dermal abnormalities may be one reason why the recurrence rate seems less with NAFL compared with Q-switched lasers.

Studies of laser- and light-based treatments for patients with melasma have shown that a long-term posttreatment maintenance regimen is necessary to slow the recurrence of melasma and minimize rebound hyperpigmentation or PIH. Also, limited studies have suggested that skin immediately post-NAFL or AFL may be in a state that facilitates the delivery of topical medications. To incorporate these findings plus limit any inflammatory cascade from the laser treatment or thermal injury, the following pre- and posttreatment regimens are recommended prior to laser- and light-based treatments (Tables 2 and 3).

Topical Tyrosinase inhibitors should be applied immediately after the treatment is completed in addition to a high potency topical corticosteroid drug. The topical Tyrosinase inhibitor should be maintained at least daily for 2 weeks and the topical corticosteroid drug should be maintained twice per day for an additional 3 days. After 2 weeks, a topical exfoliant such as tretinoin or a topical triple combination cream (anti-Tyrosinase, tretinoin, low potency steroid drug) should be used daily. To optimize the benefit of topical therapy, other agents that affect the melanin synthetic pathway such as Par-2 inhibitors should be added to the pre- and posttreatment maintenance regimen. Topical lightening agents may be irritating and the risk of this postprocedure treatment is the balance of irritation from the lightening agents that may result in PIH and the ability to deliver the medication to the depth required for lightening, topical steroids might help balance the irritant effect.

Light and laser therapy is an alternative approach to treat patients with recalcitrant melasma. The current methods are limited by recurrence, postinflammatory dyspigmentation, and the need for multiple treatments. However, as the treatments transitioned from Q-switched lasers and IPL to NAFL, the recurrence rate and number of treatments necessary to see benefits have decreased. The treatment will continue to evolve as advances in laser or device technologies emerge. Imaging and drug delivery methods can enhance these technologies, and it will be interesting to see how the picosecond lasers and fractional radiofrequency devices will impact melasma treatments.

References

Anderson RR, Parrish JA. Selective photothermolysis: Precise microsurgery by selective absorption of pulsed radiation. *Science* 1983;220:524–7.

Angsuwarangsee S, Polnikorn N. Combined ultrapulse CO2 laser and Q-switched alexandrite laser compared with Q-switched alexandrite laser alone for refractory melasma: Split-face design. *Dermatol Surg* 2003;29:59–64.

Ardigo M, Cameli N, Berardesca E, Gonzalez S. Characterization and evaluation of pigment distribution and response to therapy in melasma using in vivo reflectance confocal microscopy: A preliminary study. *J Eur Acad Dermatol Venereol* 2010;24:1296–303.

Ball Arefiev KL, Hantash BM. Advances in the treatment of melasma: A review of the recent literature. *Dermatol Surg* 2012;38:971–84.

Briganti S, Camera E, Picardo M. Chemical and instrumental approaches to treat hyperpigmentation. *Pigment Cell Res* 2003;16:101–10.

Cameli N, Abril E, Mariano M, Berardesca E. Combined use of monopolar radiofrequency and transdermal drug delivery in the treatment of melasma. *Dermatol Surg* 2014;40:748–55.

Chandrashekar BS, Sriram R, Mysore R, Bhaskar S, Shetty A. Evaluation of microneedling fractional radiofrequency device for treatment of acne scars. *J Cutan Aesthet Surg* 2014;7:93–7.

Donnelly RF, Raj Singh TR, Woolfson AD. Microneedle-based drug delivery systems: Microfabrication, drug delivery, and safety. *Drug Deliv* 2010;17(4):187–207.

Eimpunth S, Wanitphakdeecha R, Triwongwanat D, Varothai S, Manuskiatti W. Therapeutic outcome of melasma treatment by dual-wavelength (511 and 578 nm) laser in patients with skin phototypes III-V. *Clin Exp Dermatol* 2014;39:292–7.

Figueiredo Souza L, Trancoso Souza S. Single-session intense pulsed light combined with stable fixed-dose triple combination topical therapy for the treatment of refractory melasma. *Dermatol Ther* 2012;25:477–80.

Goldman MP, Gold MH, Palm MD, Colon LE, Preston N, Johnson LA, et al. Sequential treatment with triple combination cream and intense pulsed light is more efficacious than sequential treatment with an inactive (control) cream and intense pulsed light in patients with moderate to severe melasma. *Dermatol Surg* 2011;37:224–33.

Grimes PE. Melasma. Etiologic and therapeutic considerations. *Arch Dermatol* 1995;131:1453–7.

Grimes PE, Yamada N, Bhawan J. Light microscopic, immunohistochemical, and ultrastructural alterations in patients with melasma. *Am J Dermatopathol* 2005;27:96–101.

Haedersdal M, Eriksen AM, Paasch U, Anderson RR. Translational medicine in the field of ablative fractional laser (AFXL)-assisted drug delivery: A critical review from basics to current clinical status. *J Am Acad Dermatol* 2016;74:981–1004.

Hammami Ghorbel H, Boukari F, Fontas E, Montaudie H, Bahadoran P, Lacour JP, et al. Copper Bromide Laser vs Triple-Combination Cream for the Treatment of Melasma: A Randomized Clinical Trial. *JAMA Dermatol* 2015;151(7):791–2.

Hantash BM, Bedi VP, Sudireddy V, Struck SK, Herron GS, Chan KF. Laser-induced transepidermal elimination of dermal content by fractional photothermolysis. *J Biomed Opt* 2006;11:41115.

Hearing VJ. Determination of melanin synthetic pathways. *J Invest Dermatol* 2011;131:E8–11.

Hofbauer Parra CA, Careta MF, Valente NYS, de Sanches Osório NEG, Torezan LAR. Clinical and histopathologic assessment of facial melasma after low fluence Q-switched neodymium-doped yttrium aluminium garnet laser. *Dermatol Surg* 2016;42:507–12.

Jeong SY, Shin J Bin, Yeo UC, Kim WS, Kim IH. Low-fluence Q-switched neodymium-doped yttrium aluminum garnet laser for melasma with pre- or post-treatment triple combination cream. *Dermatol Surg* 2010;36:909–18.

Kang WH, Yoon KH, Lee ES, Kim J, Lee KB, Yim H, et al. Melasma: Histopathological characteristics in 56 Korean patients. *Br J Dermatol* 2002;146:228–37.

Kang H, Kim J, Goo B. The dual toning technique for melasma treatment with the 1064 nm Nd: YAG laser: A preliminary study. *Laser Ther* 2011;20:189–94.

Kouba DJ, Fincher EF, Moy RL. Nevus of Ota successfully treated by fractional photothermolysis using a fractionated 1440-nm Nd: YAG laser. *Arch Dermatol* 2008;144:156–8.

Kron MW, Wind BS, Beek JF, Wietze Van Der Veen JP, Nieuweboer-Krobotová L, Bos JD, et al. Nonablative 1550-nm fractional laser therapy versus triple topical therapy for the treatment of melasma: A randomized controlled pilot study. *J Am Acad Dermatol* 2011;64:516–23.

Kwon SH, Hwang YJ, Lee SK, Park KC. Heterogeneous pathology of melasma and its clinical implications. *Int J Mol Sci* 2016;17:E824.

Lee AY. Recent progress in melasma pathogenesis. *Pigment Cell Melanoma Res* 2015;28:648–60.

Lee HS, Won CH, Lee DH, An JS, Chang HW, Lee JH, et al. Treatment of melasma in Asian skin using a fractional 1,550-nm laser: an open clinical study. *Dermatol Surg* 2009;35:1499–504.

Lee HI, Lim YY, Kim BJ, Kim MN, Min HJ, Hwang JH, et al. Clinicopathologic efficacy of copper bromide plus/yellow laser (578 nm with 511 nm) for treatment of melasma in Asian patients. *Dermatol Surg* 2010;36:885–93.

Lee HM, Haw S, Kim JK, Chang SE, Lee MW. Split-face study using a 1,927-nm thulium fiber fractional laser to treat photoaging and melasma in Asian skin. *Dermatol Surg* 2013;39:879–88.

Lee WR, Shen SC, Aljuffali IA, Lin YK, Huang CW, Fang JY. Non-ablative fractional laser assists cutaneous delivery of small- and macro-molecules with minimal bacterial infection risk. *Eur J Pharm Sci* 2016;92:1–10.

Li YH, Chen JZS, Wei HC, Wu Y, Liu M, Xu YY, et al. Efficacy and safety of intense pulsed light in treatment of melasma in Chinese patients. *Dermatol Surg* 2008;34:693–701.

Lima Ede A. Microneedling in facial recalcitrant melasma: Report of a series of 22 cases. *An Bras Dermatol* 2015;90:919–21.

Manaloto RMP, Alster T. Erbium:YAG laser resurfacing for refractory melasma. *Dermatol Surg* 1999;25:121–3.

Manstein D, Herron GS, Sink RK, Tanner H, Anderson RR. Fractional photothermolysis: A new concept for cutaneous remodeling using microscopic patterns of thermal injury. *Lasers Surg Med* 2004;34:426–38.

McCrudden MT, McAlister E, Courtenay AJ, González-Vázquez P, Singh TR, Donnelly RF. Microneedle applications in improving skin appearance. *Exp Dermatol* 2015;24:561–6.

Morais OO, Lemos ÉF, Sousa MC, Gomes CM, Costa IM, Paula CD. The use of ablative lasers in the treatment of facial melasma. *An Bras Dermatol* 2013;88:238–42.

Niwa Massaki AB, Eimpunth S, Fabi SG, Guilha I, Groff W, Fitzpatrick R. Treatment of melasma with the 1,927-nm fractional thulium fiber laser: A retrospective analysis of 20 cases with long-term follow-up. *Lasers Surg Med* 2013;45:95–101.

Passeron T, Fontas E, Kang HY, Bahadoran P, Lacour JP, Ortonne JP. Melasma treatment with pulsed-dye laser and triple combination cream: A prospective, randomized, single-blind, split-face study. *Arch Dermatol* 2011;147:1106–8.

Patil UA, Dhani LD. Overview of lasers. *Indian J Plast Surg* 2008;41:101–13.

Polder KD, Bruce S. Treatment of melasma using a novel 1,927-nm fractional thulium fiber laser: A pilot study. *Dermatol Surg* 2012;38:199–206.

- Polder KD, Landau JM, Vergilis-Kalner IJ, Goldberg LH, Friedman PM, Bruce S. Laser eradication of pigmented lesions: A review. *Dermatol Surg* 2011;37:572–95.
- Rokhsar CK, Fitzpatrick RE. The treatment of melasma with fractional photothermolysis: A pilot study. *Dermatol Surg* 2005;31:1645–50.
- Sarkar R, Arora P, Garg KV. Cosmeceuticals for hyperpigmentation: What is available? *J Cutan Aesthet Surg* 2013;6:4–11.
- Sehgal VN, Verma P, Srivastava G, Aggarwal AK, Verma S. Melasma: Treatment strategy. *J Cosmet Laser Ther* 2011;13:265–79.
- Sheth VM, Pandya AG. Melasma: A comprehensive update: Part II. *J Am Acad Dermatol* 2011;65:699–714.
- Taylor CR, Anderson RR. Ineffective treatment of refractory melasma and postinflammatory hyperpigmentation by Q-switched ruby laser. *J Dermatol Surg Oncol* 1994;20:592–7.
- Tourlaki A, Galimberti MG, Pellacani G, Bencini PL. Combination of fractional erbium-glass laser and topical therapy in melasma resistant to triple-combination cream. *J Dermatolog Treat* 2014;25:218–22.
- Trelles MA, Velez M, Gold MH. The treatment of melasma with topical creams alone, CO2 fractional ablative resurfacing alone, or a combination of the two: A comparative study. *J Drugs Dermatol* 2010;9:315–22.
- Tse Y, Levine VJ, McClain SA, Ashinoff R. The removal of cutaneous pigmented lesions with the Q-switched ruby laser and the Q-switched neodymium: Yttrium-aluminum-garnet laser. *J Dermatol Surg Oncol* 1994;20:795–800.
- Vachiramon V, Sirithanabadeekul P, Sahawatwong S. Low-fluence Q-switched Nd: YAG 1064-nm laser and intense pulsed light for the treatment of melasma. *J Eur Acad Dermatol Venereol* 2015;29:1339–46.
- Wang CC, Hui CY, Sue YM, Wong WR, Hong HS. Intense pulsed light for the treatment of refractory melasma in Asian persons. *Dermatol Surg* 2004;30:1196–200.
- Wanitphakdeedecha R, Manuskiatti W, Siriphukpong S, Chen TM. Treatment of melasma using variable square pulse Er: Yag laser resurfacing. *Dermatol Surg* 2009;35:475–81.
- Wattanakrai P, Mornchan R, Eimpunth S. Low-fluence q-switched neodymium-doped yttrium aluminum garnet (1,064 nm) laser for the treatment of facial melasma in Asians. *Dermatol Surg* 2010;36:76–87.
- Wind BS, Kroon MW, Meesters AA, Beek JF, van der Veen JPW, Nieuweboer-Krobotová L, et al. Non-ablative 1,550 nm fractional laser therapy versus triple topical therapy for the treatment of melasma: A randomized controlled split-face study. *Lasers Surg Med* 2010;42:607–12.
- Wong RC, Ellis CN, Arbor A. Physiologic skin changes in pregnancy. *J Am Acad Dermatol* 1984;10:929–40.
- Xi Z, Gold MH, Zhong L, Ying L. Efficacy and safety of Q-switched 1,064-nm neodymium-doped yttrium aluminum garnet laser treatment of melasma. *Dermatol Surg* 2011;37:962–70.
- Yue B, Yang Q, Xu J, Lu Z. Efficacy and safety of fractional Q-switched 1064-nm neodymium-doped yttrium aluminum garnet laser in the treatment of melasma in Chinese patients. *Lasers Med Sci* 2016;31:1657–63.
- Yun WJ, Moon HR, Lee MW, Choi JH, Chang SE. Combination treatment of low-fluence 1,064-nm Q-switched Nd: YAG laser with novel intense pulse light in Korean melasma patients: A prospective, randomized, controlled trial. *Dermatol Surg* 2014;40:842–50.
- Zaleski-Larsen LA, Fabi SG. Laser-assisted drug delivery. *Dermatol Surg* 2016;42:919–31.