



Published in final edited form as:

Ann Neurol. 2017 March ; 81(3): 430–443. doi:10.1002/ana.24885.

Typical and atypical pathology in primary progressive aphasia variants

Edoardo G Spinelli, MD^{1,2}, Maria Luisa Mandelli, PhD¹, Zachary A Miller, MD¹, Miguel A Santos-Santos, MD¹, Stephen M Wilson, PhD^{1,3}, Federica Agosta, MD, PhD², Lea T Grinberg, MD, PhD¹, Eric J Huang, MD¹, John Q Trojanowski, MD, PhD⁴, Marita Meyer, BS¹, Maya L Henry, PhD⁵, Giancarlo Comi, MD², Gil Rabinovici, MD¹, Howard J Rosen, MD¹, Massimo Filippi, MD, FEAN², Bruce L Miller, MD¹, William W Seeley, MD¹, and Maria Luisa Gorno-Tempini, MD, PhD¹

¹Memory and Aging Center, University of California, San Francisco, CA, USA

²Neuroimaging Research Unit, Institute of Experimental Neurology, Division of Neuroscience, San Raffaele Scientific Institute, Vita-Salute San Raffaele University, Milan, Italy

³Department of Speech, Language, and Hearing Sciences, University of Arizona, Tucson, AZ, USA

⁴Department of Pathology and Laboratory Medicine, University of Pennsylvania, Philadelphia, PA, USA

⁵Department of Communication Sciences and Disorders, University of Texas, Austin, TX, USA

Abstract

Objective—To characterize *in vivo* signatures of pathological diagnosis in a large cohort of patients with primary progressive aphasia (PPA) variants defined by current diagnostic classification.

Methods—Extensive clinical, cognitive, neuroimaging, and neuropathological data were collected from 69 patients with sporadic PPA, divided into 29 semantic (svPPA), 25 non-fluent (nfvPPA), 11 logopenic (lvPPA), and 4 mixed PPA. Patterns of grey matter (GM) and white matter (WM) atrophy at presentation were assessed and tested as predictors of pathological diagnosis using support vector machine (SVM) algorithms.

Results—A clinical diagnosis of PPA was associated with frontotemporal lobar degeneration (FTLD) with TDP inclusions in 40.5%, FTLD-tau in 40.5%, and Alzheimer's disease (AD) pathology in 19% of cases. Each variant was associated with one typical pathology: 24/29 (83%)

Corresponding author contact information: Maria Luisa Gorno-Tempini, UCSF Memory and Aging Center, 675 Nelson Rising Lane, Suite 190, San Francisco CA 94158, marialuisa.gornotempini@ucsf.edu.

Author contributions

E.G.S., W.W.S., B.L.M., and M.L.G.T. were responsible for study conception and design. E.G.S., M.L.M., Z.A.M, M.A.S., S.M.W., F.A., L.T.G., E.J.H., J.Q.T., M.M., M.L.H., G.R., H.J.R., W.W.S., and M.L.G.T. were responsible for acquisition and analyses of data. E.G.S., M.L.M., Z.A.M, M.A.S., F.A., M.M., G.C., M.F., B.L.M., and M.L.G.T. were responsible for drafting the text or preparing the figures.

Potential conflicts of interest

Nothing to report.

svPPA showed FTLD-TDP type C, 22/25 (88%) nfvPPA showed FTLD-tau, and all 11 lvPPA had AD. Within FTLD-tau, 4R-tau pathology was commonly associated with nfvPPA, whereas Pick's disease was observed in a minority of subjects across all variants except for lvPPA. Compared with pathologically typical cases, svPPA-tau showed significant extrapyramidal signs, greater executive impairment, and severe striatal and frontal GM and WM atrophy. nfvPPA-TDP patients lacked general motor symptoms or significant WM atrophy. Combining GM and WM volumes, SVM analysis showed 92.7% accuracy to distinguish FTLD-tau and FTLD-TDP pathologies across variants.

Interpretation—Each PPA clinical variant is associated with a typical and most frequent cognitive, neuroimaging, and neuropathological profile. Specific clinical and early anatomical features may suggest rare and atypical pathological diagnosis *in vivo*.

Introduction

Primary progressive aphasia (PPA) defines a group of neurodegenerative syndromes characterized by progressive, selective decline in speech and language functions. Current diagnostic classification¹ identifies three main clinical variants: semantic (svPPA), nonfluent/agrammatic (nfvPPA), and logopenic (lvPPA). Previous clinicopathological series^{2–11} have shown associations between PPA variants and most probable pathological substrates. svPPA and nfvPPA are generally included in the spectrum of frontotemporal lobar degeneration (FTLD), with abnormal deposition of either transactive response DNA-binding protein of 43 kD (TDP-43) or microtubule-associated protein tau, whereas lvPPA is most often associated with Alzheimer's disease (AD) pathology. Nevertheless, there is no absolute association between each PPA variant and a single pathological entity. Furthermore, the relative frequency of specific molecular alterations in each variant differs greatly across studies. FTLD-tau is reported in cases classified as “non-fluent” with a frequency ranging from 50 to 100%, with most of the remainder having FTLD-TDP or, less frequently, AD pathology^{2,5–9} (Supplementary Table 1). Similarly, studies that included the most recently described logopenic variant report a frequency of AD pathology between 50 and 100% in this clinical subtype, with FTLD-TDP (often associated with *GRN* mutations) as the second most common cause^{3–6,12–14}. By contrast, FTLD-TDP is reported in up to 90% of svPPA cases, with FTLD-tau or AD as less common pathological findings^{2,7,15–17}. Inconsistencies across studies likely arise from use of different diagnostic approaches (many patients were diagnosed before the current classification was published), inclusion of familial cases, lack of comprehensive cognitive and neuroimaging data and small sample sizes. The identification of *in vivo* features that predict a pathological diagnosis is becoming important, as pharmacological trials targeting specific molecular substrates of AD and FTLD pathologies are emerging. CSF and PET biomarkers have proven useful in the identification of AD pathology in PPA patients^{18–20}, whereas no similar tools have been validated so far for FTLD subtypes. To date, automated classification algorithms, recently used to identify neuroimaging biomarkers of several neurodegenerative diseases^{21–23}, have not been applied to pathological series.

This study provides a comprehensive analysis of clinical, cognitive, and neuroimaging features at clinical presentation in a large, well-characterized cohort of sporadic PPA patients

with pathological diagnosis, who were evaluated at the same clinic and diagnosed using the state-of-the-art classification system. The primary aim of the study was to identify clinicopathological correlates in each PPA variant. A secondary analysis investigated whether an automated classification algorithm based on MRI variables alone could be a valid predictor of pathological diagnosis in PPA.

Methods

Subjects

Patients with a clinical diagnosis of PPA^{1,24} and *postmortem* neuropathological diagnosis were included. Clinical diagnosis was based on history, neurological evaluation performed at the Memory and Aging Center at University of California, San Francisco (UCSF), and review of neuroimaging findings (i.e., conventional MRI, CT, and/or PET scans). All included patients had at least a clinical neuroimaging evaluation, allowing for an “imaging-supported” diagnosis, based on current classification¹. Seventy-five patients recruited between November 1, 1998 and August 31, 2013 met these criteria. Since this study aimed to identify hallmarks of pathological features related to sporadic and otherwise unidentifiable molecular alterations, we excluded patients with a family history of dominant inherited dementia, presence of a known genetic mutation, or clinical signs/symptoms of motor neuron disease (MND) at presentation. Three patients were excluded due to the presence of autosomal dominant *GRN* mutation (nfvPPA clinically) or *C9ORF72* expansion (svPPA clinically), and three because clinical signs of MND were found (Figure 1). Therefore, the final cohort included 69 PPA patients classified as having svPPA (n=29), nfvPPA (n=25), or lvPPA (n=11). Four patients showed symptoms of more than one variant and were, therefore, classified as ‘mixed’ (i.e., “unclassifiable”) PPA patients. Although current classification was applied retrospectively in 58 subjects presenting before 2011, these patients had been previously classified using the corresponding 2004 guidelines²⁴. Note that 18 cases included here were reported in the original description of PPA clinical variants²⁴.

Patients were included in the neuroimaging analysis if an MRI scan was performed within 6 months from presentation and Clinical Dementia Rating (CDR) Scale score was ≥ 2 . Ten subjects were excluded due to the lack of a suitable scan, whereas one patient had a CDR score of 3. Therefore, 58 patients were included in the neuroimaging study, namely 23 svPPA, 23 nfvPPA, 9 lvPPA, and 3 mixed PPA.

All participants signed informed consent. The study was approved by the UCSF human research committee.

Genetic analysis

Blood samples were collected from 58/75 recruited patients and screened for known pathogenic mutations using optimized protocols²⁵ in the following genes: *GRN*, *MAPT*, *TARDBP*, *C9ORF72*, *APP*, *PSEN1*, *PSEN2*, *FUS*. Apolipoprotein E (*APOE*) and *MAPT* H1/H2 haplotypes were also assessed²⁶.

Clinical and cognitive assessment

Detailed history and neurologic examination were obtained from all patients at presentation. Screening cognitive testing²⁷ was available from 64 patients, 53 of whom had comprehensive speech and language evaluations²⁴. Five patients could not undergo formal testing due to disease severity at presentation (CDR = 2), and thus, core features of PPA variants were assessed qualitatively by history and neurologic evaluation. Ten age- and gender-matched healthy controls also underwent general cognitive and language assessments (7 females, mean age 69.0±8.1).

Demographic, clinical, and cognitive features of patients and controls were compared using Kruskal-Wallis or Pearson's χ^2 tests followed by pairwise post-hoc analyses (Supplementary Tables 2–3). Within each clinical group, Mann-Whitney U or Fisher's exact tests were performed to compare scores of subjects with "atypical" pathological diagnoses with those obtained by the main pathological subgroup (Tables 1–2), excluding patients with a mixed primary pathology.

Neuropathological assessment

Autopsies were performed at UCSF (n=58), University of Pennsylvania (n=9), UC Davis (n=1), and Vancouver General Hospital (n=1). Pathological diagnosis was based on consensus criteria for FTLT²⁸, AD²⁹, and Lewy body disease (LBD)³⁰. Primary and secondary pathological changes were established by the pathologist in charge (W.S., L.G., E.H., J.T., I.M., W.E.). Cases were defined as having "mixed pathology" if one single primary etiological contribution could not be established.

MRI acquisition and voxel-based morphometry (VBM) analysis

For the neuroimaging analysis, an additional set of 30 healthy controls (18 females, mean age 65.1±8.7) matched with patients for age, gender, and scanner type was recruited. 3D T1-weighted images with a magnetization-prepared rapid gradient echo sequence (MPRAGE) were obtained from patients and controls using either a 1.5³¹, 3³¹, or 4 Tesla³² scanner.

VBM assessed volume differences in grey matter (GM) and white matter (WM)³³. Image processing was performed in SPM12 using the DARTEL toolbox³⁴ running under MATLAB 2014a (MathWorks). Whole-brain differences in GM and WM were investigated using ANOVA models including age, gender, total intracranial volume, and scanner type as covariates. We compared each clinical group (i.e., svPPA, nfvPPA, lvPPA, mixed PPA) and each pathological subgroup (e.g., svPPA-TDP, svPPA-tau, etc.) with controls. Within svPPA and nfvPPA, we also tested a comparison between FTLT-tau and FTLT-TDP subjects, excluding patients with a mixed primary pathology. Threshold of significance was set at $p < 0.05$ corrected for family-wise error (FWE). Subsequently, a more liberal threshold at $p < 0.001$, uncorrected, was tested to avoid false negatives that can occur in small groups.

Support vector machine (SVM) analysis

To test neuroimaging variables as predictors of pathological diagnosis, we entered whole-brain GM and WM probability maps in a linear support vector machine (SVM) algorithm. We adopted the LIBSVM³⁵ pipeline by Wilson et al.²³ to distinguish FTLT-tau (n=26) and

FTLD-TDP (n=20) patients with PPA from each other and from healthy controls (n=30). Classification accuracy of AD pathology could not be tested due to the small number of subjects (n=11). Feature selection was based on principal component analysis, and a two-level cross-validation procedure was performed²³.

Results

Neuropathological classification

The whole cohort of PPA patients showed FTLD-TDP in 40.5%, FTLD-tau in 40.5%, and AD pathology in 19% of cases. We identified a prevalent (i.e., “typical”) pathology for each variant (Figure 2). Differences in distribution of FTLD subtypes and AD pathology were highly significant among PPA clinical variants ($p<0.001$).

All 29 svPPA patients showed primary FTLD pathology. FTLD-TDP type C (TDP-C) was found in 24 cases (83%), whereas 4 patients had FTLD-tau (2 Pick’s disease [PiD] and 2 globular glial tauopathy [GGT]). One svPPA patient had mixed FTLD-TDP type B (TDP-B) and unclassifiable FTLD-tau pathology, as it was not possible to establish a single primary pathological contribution. Of the TDP-C patients, 2 also showed secondary progressive supranuclear palsy (PSP) and 2 had secondary AD pathology.

Out of 25 nvPPA patients, 22 (88%) had a pathological diagnosis of FTLD-tau. Specifically, 18 subjects showed FTLD 4R-tau (11 corticobasal degeneration [CBD], 6 PSP, and 1 unclassifiable 4R-tauopathy), and 4 had PiD. Two subjects showed FTLD-TDP type A (TDP-A), and one, who died at age 80, had mixed AD and CBD pathology. Secondary AD pathology was found in 1 nvPPA-CBD and 1 nvPPA-PiD case.

All 11 lvPPA patients showed primary AD pathology. Of these, 2 cases showed secondary LBD, and 1 had secondary PSP pathology.

Of the 4 mixed PPA, 2 had PiD, 1 had TDP-A, and 1 had AD pathology.

Clinicopathological, genetic and neuroanatomical findings

svPPA

Demographic data: Overall, svPPA patients showed mean age at onset of 60 and survival of 12 years (Table 1). svPPA patients with different pathological diagnoses showed no significant differences in terms of education, gender, or age (Table 2, Supplementary Table 2). Four of the 5 svPPA patients with pathology other than TDP-C lived on average 3 years less than svPPA-TDP-C. One svPPA-GGT patient showed an exceptionally long disease duration and died 19 years after onset.

Genetic data: The *ApoE4* allele was present in 29% of svPPA patients, whereas the H1/H1 *MAPT* haplotype was found in 54%, with no significant differences between pathological subtypes (Table 2, Supplementary Table 2). Both svPPA-TDP-C patients with secondary AD pathology had the E3/E4 genotype.

Clinical and cognitive data: All 29 svPPA patients presented with word-finding difficulties as the main cause of limitation in daily activities. Nineteen patients also had significant behavioral symptoms at onset (loss of empathy, irritability, obsessive/ritualistic behavior, altered eating habits), although these did not dominate the clinical presentation. Cognitive evaluation showed mild to moderate memory and executive impairment with spared visuospatial functions (Table 1). The most impaired linguistic domains were naming, single-word comprehension and semantic knowledge.

Clinical, cognitive, and linguistic features of svPPA-TDP-C patients reflected the profile of the whole svPPA group (Supplementary Tables 2–3). Four out of 5 svPPA subjects with pathology other than TDP-C showed particularly severe behavioral symptoms (i.e., obsessive-compulsive behavior, disinhibition, apathy). The 2 svPPA-GGT patients also presented with severe global cognitive impairment. All svPPA-tau patients shared prominent executive impairment, performing worse than svPPA-TDP-C at digit span backward (Table 3, $p=0.01$), modified trails ($p=0.04$), and phonemic fluency tasks ($p=0.03$). Neurologic examination was unremarkable for all svPPA-TDP-C patients, except for one with secondary PSP pathology showing mild vertical gaze limitation and bilateral bradykinesia. By contrast, 3 svPPA-tau and the svPPA patient with mixed TDP-B/unclassifiable FTLT-tau showed mild to moderate extrapyramidal rigidity in the right upper limb. UPDRS motor scores were significantly higher in svPPA-tau than svPPA-TDP-C (Table 2, $p=0.004$).

Neuroimaging data: Compared with healthy controls, svPPA-TDP-C patients showed GM atrophy involving the anterior temporal lobes (ATLs), medial orbitofrontal cortex (OFC), and fusiform gyri bilaterally, as well as the left middle and superior temporal gyri (Figure 3-a, $p<0.05$ FWE). WM atrophy involved the temporal portions of the inferior longitudinal fasciculus (ILF), inferior fronto-occipital fasciculus (IFOF), and uncinate fasciculus bilaterally ($p<0.05$ FWE).

The svPPA subject with mixed TDP-B/unclassifiable FTLT-tau showed GM atrophy in the left temporal pole (mostly medial) and bilateral OFC and WM atrophy in the left uncinate fasciculus ($p<0.001$ uncorrected).

svPPA-PiD patients showed widespread GM atrophy involving the ATL bilaterally (medial>lateral), frontal regions (i.e., bilateral OFC, inferior, middle and superior frontal gyri, right anterior cingulate cortex [ACC]), insula, basal ganglia (bilateral putamen, left caudate nucleus), and the left middle temporal and fusiform gyri ($p<0.001$ uncorrected). Extensive WM atrophy was also found, involving the ILF, IFOF, uncinate fasciculus, forceps minor, and anterior corona radiata bilaterally ($p<0.001$ uncorrected).

The svPPA-GGT subject included in the neuroimaging study (P28) showed left-lateralized GM atrophy, involving the ATL (medial>lateral), middle frontal gyrus, ACC, putamen, and caudate ($p<0.001$ uncorrected). WM atrophy involved extensive temporal and frontal regions bilaterally with left prevalence ($p<0.001$ uncorrected).

When svPPA-TDP-C and all three svPPA-tau patients were compared directly, svPPA-tau patients showed more severe GM atrophy in bilateral ACC and in the left striatum (putamen,

head of the caudate nucleus), as well as more prominent WM atrophy in the forceps minor, genu and body of the corpus callosum, and left anterior corona radiata (Figure 3-b, $p < 0.001$ uncorrected).

nfvPPA

Demographic data: nfvPPA patients were mostly women (18/25) and showed a mean age at onset of 64 and survival of 8 years (Table 1). No significant differences in gender, education, age, disease duration at presentation, and survival between pathological subgroups were found (Table 2, Supplementary Table 2).

Genetic data: *ApoE4* was infrequent in nfvPPA patients (Table 1) and was found only in one CBD case with secondary AD pathology. All tested patients with FTLD-tau showed the H1/H1 haplotype.

Clinical and cognitive data: All 25 nfvPPA patients presented with apraxia of speech (AOS) and/or dysarthria with mixed but prevalently hypokinetic features. Twenty-three patients also had impaired grammar production or comprehension. No patient showed isolated agrammatism, and only 2 presented with prevalent agrammatism and mild AOS. Although 20 nfvPPA patients showed neuropsychiatric symptoms, these were generally milder relative to svPPA. Extrapyramidal signs at motor examination were found in 19 nfvPPA patients. Neuropsychological testing showed executive impairment with relative sparing of memory and visuospatial abilities.

Compared with nfvPPA patients with 4R-tau pathology, nfvPPA-PiD subjects did not show consistent clinical or cognitive differences (Supplementary Tables 2–3). However, one case (P50) showed a peculiar clinico-anatomical syndrome consistent with a diagnosis of crossed nfvPPA³⁶, with AOS and agrammatism accompanied by clearly right more than left inferior frontal atrophy (see “Neuroimaging data”) in a strongly right-handed patient with no family history of left-handedness.

The one nfvPPA patient with mixed AD/CBD pathology also showed a typical nfvPPA syndrome but was older than other patients (74 years old).

nfvPPA patients with FTLD-TDP did show some distinguishing features when compared with nfvPPA-tau. One nfvPPA-TDP-A subject (P52) showed severe, isolated motor speech deficits with spastic dysarthria, early mutism, and mild agrammatism and has been previously described in detail³⁷. The second subject (P53) presented with a 5-year history of motor speech difficulties and likely severe agrammatism, although detailed description of her language profile was not feasible due to disease severity at presentation (MMSE=8). Despite the severity of speech and language deficits, all nfvPPA-TDP-A subjects showed spared motor functions and behavior at presentation (Table 2, p ranging 0.04–0.05) relative to nfvPPA-tau.

Neuroimaging data: Compared with healthy controls, nfvPPA-4R-tau patients showed GM atrophy in the left precentral gyrus, inferior frontal gyrus pars opercularis (IFG-po), supplementary motor area (SMA), superior and middle frontal gyri, insula, and putamen

(Figure 4-a, $p < 0.05$ FWE). nfvPPA-4R-tau patients also showed extensive frontal WM atrophy involving the left superior longitudinal fasciculus (SLF) and the body of the corpus callosum as well as bilateral anterior corona radiata ($p < 0.05$ FWE). The pattern of left frontal WM atrophy traces the “frontal aslant tract”³⁸.

In 2 of the 3 nfvPPA-PiD patients included in the neuroimaging analysis (P48–P49), GM atrophy was found in the left IFG-po, insula, middle frontal gyrus, and SMA, as well as in the precentral gyrus and OFC bilaterally. WM atrophy involved the SLF and anterior corona radiata bilaterally with prevalence in the left hemisphere ($p < 0.001$ uncorrected). The case with crossed nfvPPA and PiD pathology (P50) showed selective right-sided GM atrophy involving the precentral gyrus, SMA, insula, and superior temporal pole ($p < 0.001$ uncorrected).

The nfvPPA patient with TDP-A pathology and neuroimaging data (P52), as previously reported³⁷, showed selective GM atrophy involving the left IFG-po, precentral gyrus, insula, and inferior parietal lobule ($p < 0.001$ uncorrected).

The nfvPPA case with mixed AD/CBD pathology showed mild, selective GM atrophy in the left anterior IFG and inferior parietal lobule ($p < 0.001$ uncorrected).

When nfvPPA-tau patients were directly compared with nfvPPA-TDP, VBM analysis did not show any significant differences.

lvPPA—Demographic, clinical, cognitive and genetic features of lvPPA patients – all diagnosed with AD pathology – are consistent with reports that first described this variant^{24,39} (Table 1). ApoE4 allele incidence was high (56%), reflecting the constant presence of AD pathology in this cohort.

VBM analysis showed atrophy involving mainly the GM (left middle temporal gyrus, angular gyrus, precuneus, and hippocampus) but also the left parahippocampal and anterior temporal WM (Figure 4-b, $p < 0.05$ FWE).

Mixed PPA—Supplementary Tables 2–3 report features of patients with a mixed PPA phenotype.

Clinical and cognitive data: Both mixed PPA patients with PiD presented with word-finding difficulties and impaired speech fluency. P55 showed severe AOS leading to functional mutism, whereas P56 had prominent phonological impairment. Both cases also showed severe semantic deficits, non-linguistic cognitive impairment (memory, executive), and right-sided hemiparkinsonism. P55 also showed severe behavioral symptoms (agitation, irritability).

The mixed PPA patient with AD pathology showed moderate AOS, severe agrammatism, and impaired repetition. He also showed moderate global cognitive impairment with prominent memory deficits. Motor functions were intact.

The mixed PPA patient with TDP-A presented with severe word-finding difficulties associated with effortful speech, grammatical comprehension deficits, and impaired repetition. Non-linguistic domains were relatively intact. Neurologic examination showed right limb apraxia but no rigidity.

Neuroimaging data: Patients with mixed PPA and PiD showed widespread GM atrophy involving the IFG, insula, superior frontal gyrus, SMA, OFC and precuneus bilaterally, as well as the left temporal pole, inferior temporal gyrus, and striatum (Figure 4-c, $p < 0.001$ uncorrected). WM atrophy was found in the left SLF, uncinate fasciculus and anterior corona radiata ($p < 0.001$ uncorrected).

The mixed PPA patient with AD pathology showed selective left hippocampal and parahippocampal atrophy ($p < 0.001$ uncorrected).

Support vector machine (SVM) MRI analysis

Supplementary Table 4 displays the statistical measures (i.e., sensitivity, specificity, accuracy, area under the ROC curve [AUC]) that describe SVM classification of healthy controls and PPA patients with FTLD-tau and FTLD-TDP based on VBM probability maps. A combination of GM and WM measures showed the best performance (accuracy 92.7%, AUC 96.4%) in distinguishing PPA patients with FTLD-tau from those with FTLD-TDP regardless of their clinical diagnoses. Figure 5 shows SVM classification at a single-patient level. It is noteworthy that when WM measures were included, all four patients with “atypical” pathology were classified correctly.

Discussion

This study provides a comprehensive analysis of clinical, cognitive and neuroimaging features of the largest reported cohort of sporadic PPA patients with pathological confirmation, diagnosed using modern clinical classification. Our aim was to determine *in vivo* signatures of neuropathological alterations within the spectrum of PPA clinical variants in the absence of known genetic mutations. Each clinical variant was associated with a highly typical (83–100%) pathological correlate, demonstrating the utility of the modern classification system for prediction of pathological findings. Specific clinical and neuroimaging features suggested the presence of “atypical” pathology. Automated machine learning analyses highlighted the power of MRI variables in predicting pathology.

The most typical pathology of svPPA was FTLD-TDP type C (found in 83% of cases), while nvfPPA was typically associated with FTLD-tau (88%). “Atypical” neuropathological diagnoses in svPPA included FTLD-TDP type B and tauopathies such as PiD and GGT, whereas alternative pathological substrates of nvfPPA included FTLD-TDP type A and AD (in one case with co-primary 4R-tau). In our cohort, no case of svPPA or nvfPPA had pure AD pathology, although AD changes co-occurred with FTLD in three cases. These findings highlight how, in the presence of specific clinical and neuroimaging features, a diagnosis of svPPA and nvfPPA consistently predicts underlying FTLD pathology. Instead, all lvPPA patients showed primary AD pathology, in keeping with a selective vulnerability of posterior brain networks to AD^{18,19,40}. Interestingly, clinicopathological correspondence was

complete, indicating lvPPA clinical and neuroimaging syndrome as an important *in vivo* predictor of AD pathology in sporadic PPA. However, neuronal vulnerability to molecular changes is not absolute, and our lvPPA cohort was relatively small. Therefore, some FTLN cases are likely to emerge in larger cohorts⁴¹. Indeed, our finding is in contrast with previous studies showing FTLN-TDP-A pathology in 15–25% of lvPPA cases^{2,4,6}. Finally, three out of four patients with a mixed PPA phenotype showed FTLN pathology and were most probably later, more severe presentations of one the three main variants. Overall, our findings demonstrate that the current clinical classification system of PPA variants allows for strong, but not absolute, clinicopathological predictions in each the three main subtypes. Furthermore, detailed analysis of the case series with “atypical” pathological diagnoses suggests that early clinical and anatomical features might predict less frequent molecular correlates.

Typical FTLN-TDP pathology in svPPA was associated with the characteristic semantic memory impairment and selective ATL atrophy, accompanied by mild to moderate neuropsychiatric abnormalities in 40% of patients. The “atypical” svPPA-tau cases showed greater executive and motor involvement and a trend toward more severe behavioral symptoms (apathy and/or disinhibition), likely in relation to greater atrophy of frontotemporal cortex (i.e., medial ATL, OFC, ACC), basal ganglia, and connecting WM structures^{15,42}. Although disease duration might be a factor in determining these differences, atypical symptoms were also present in svPPA-tau cases with comparable age and disease duration relative to svPPA-TDP. Interestingly, frontal WM damage was particularly widespread in svPPA-tau, whereas WM atrophy in the svPPA-TDP group was confined to the ATL. This finding is consistent with previous imaging studies showing greater WM diffusion changes in FTLN-tau relative to FTLN-TDP regardless of clinical presentation^{43,44}. Furthermore, evidence that WM is more susceptible to early damage in FTLN-tau comes from cellular and animal models suggesting that tau aggregates primarily impair axonal transport^{45,46}. By contrast, although trans-synaptic spreading of TDP-43 depositions has been reported⁴⁷, FTLN-TDP primarily affects the GM, involving the WM at later stages of disease⁴⁸. Taken together, our results suggest that the focal cognitive and neuroanatomical syndrome of svPPA is highly predictive of FTLN-TDP pathology, particularly type C, whereas an early clinical and anatomical involvement of frontostriatal structures might suggest FTLN-tau.

In our study, an imaging-supported diagnosis of nfPPA was associated with FTLN-tau pathology in nearly 90% of cases, with 4R-tau being the most common subtype. Sporadic FTLN-TDP-A was rare (8%), and AD was never present in isolation. The lack of pure AD pathology in our nfPPA cohort is likely related to the reliable differential diagnosis with lvPPA, as will be discussed in the next paragraph. The strong association of nfPPA clinical and neuroanatomical syndrome with FTLN-tau pathology is consistent but even stronger than in other previous studies in which FTLN-TDP was more frequently reported^{2,4,5,8}. Indeed, even the inclusion of two cases with *GRN* mutations, which were excluded from our analysis, would have increased FTLN-TDP-A frequency to only 14%. The consistent association between nfPPA and FTLN-tau has important clinical implications, indicating that these patients should be included in tau-targeting pharmacological trials. Comparing features of nfPPA-4R-tau patients with those with nfPPA-TDP, current results also

confirm our previous findings³⁷, showing greater motor speech abnormalities than agrammatism in all but two patients and earlier general motor abnormalities and greater WM changes in nfvPPA-tau cases. These findings are consistent with the biological features of FTLT-tau and FTLT-TDP mentioned previously. We also describe four nfvPPA patients with PiD (a 3R tauopathy). They did not show distinguishing clinical or cognitive traits relative to 4R-tau patients, although we did observe some additional right fronto-insular atrophy (possibly explained by the more liberal threshold adopted for small-group VBM analyses). One right-handed nfvPPA-PiD case presented with selective right-sided atrophy, similarly to a recent case report of “crossed” nfvPPA³⁶. Of note, PiD occurred across all variants except for lvPPA. This supports the hypothesis that PiD presents with a variable frontotemporal pattern of atrophy, leading to different clinical correlates within the spectrum of FTD disorders⁷. The extensive involvement of multiple functional networks might also explain the early global impairment observed in some patients with PiD here reported⁴⁹.

In our cohort, lvPPA was the variant showing the most consistent clinicopathological association, namely with AD pathology. In early reports lvPPA might have been included in the “non-fluent” category, explaining the high prevalence of AD reported by some of these studies in non-fluent cases^{10,11}. More recently, FTLT-TDP-A was also found in few lvPPA cases^{2,4,6} who might have been *GRN* mutation carriers and thus excluded here. In our study, conventional neuroimaging was also reviewed at the time of clinical diagnosis, allowing for an “imaging-supported” diagnosis, which is likely to be more consistent with pathology. The fact that our cohort of pathologically-proven lvPPA is smaller than the other two main groups may be partially explained by the longer survival we found in lvPPA patients, in keeping with studies showing a more aggressive clinical course of FTLT-related disorders compared with AD⁵⁰. Although we do not expect that larger cohorts will show a 100% association between lvPPA and AD pathology, large biomarker studies do indicate that AD is the most typical pathology in lvPPA^{18–20}. In summary, our findings, together with previous evidence, suggest that the clinical and neuroimaging diagnostic features of lvPPA are highly predictive of underlying AD.

A secondary aim of the present study was to quantify the extent to which neuroimaging may help in classifying individual PPA patients according to the specific FTLT subtype. Machine learning has been recently applied to identify early MRI-based diagnostic markers of neurodegenerative diseases^{21,22}, including PPA variants²³. However, this is the first study testing this approach for the pathological diagnosis of PPA syndromes. SVM analysis of differential patterns of GM and WM damage across variants did prove useful in the identification of FTLT-tau and FTLT-TDP in this cohort, since a combination of both parameters showed the best accuracy (92.7%) classifying FTLT subtypes. Compared with the approximate 85% probability of patients diagnosed with svPPA and nfvPPA to have, respectively, underlying FTLT-TDP or FTLT-tau, this approach showed to be partially helpful in atypical cases. Particularly, the pattern of WM atrophy provided higher accuracy than GM alone in the correct classification of svPPA-tau and nfvPPA-TDP patients. These results strengthen the hypothesis that the differential involvement of WM shown by neuroimaging may constitute a key biomarker to discriminate FTLT subtypes.

This study has some limitations. Despite the robust size of the overall cohort, some subgroups were small, reflecting the rarity of atypical pathological diagnoses within an uncommon disease. Therefore, the degree to which the clinical and neuroimaging features of these cases can be generalized to other populations is unclear. For the same reason, the SVM analysis had to be cross-validated within the cohort itself – a commonly adopted approach when limited samples are available^{22,23} – and could not be applied reliably to patients with AD pathology. Finally, diffusion tensor imaging (DTI) data were unavailable for most included subjects. Nevertheless, VBM proved sufficiently sensitive to WM damage, even in small groups.

In conclusion, our findings suggest that current clinical classification criteria can be used to predict a most probable pathological diagnosis within each PPA clinical variant. Early, unusual clinical, cognitive and neuroanatomical distinctive traits may suggest atypical pathological correlates. We also showed that automated methods processing multimodal neuroimaging features may assist in the discrimination of FTLD subtypes in PPA. As therapies targeting specific disease mechanisms emerge, clinical and neuroimaging techniques detecting early pathological alterations may constitute a crucial diagnostic tool.

Supplementary Material

Refer to Web version on PubMed Central for supplementary material.

Acknowledgments

Study Supported by: National Institutes of Health (NINDS R01 NS050915, NIDCD K24 DC015544, NIA P50 AG03006, NIA P50 AG023501, NIA P01 AG019724); State of California (DHS04-35516); Alzheimer's Disease Center of California (03-75271 DHS/ADP/ARCC); Larry L. Hillblom Foundation; John Douglas French Alzheimer's Foundation; Koret Family Foundation; Consortium for Frontotemporal Dementia Research; and McBean Family Foundation.

The authors thank the patients and their families for the time and effort they dedicated to the research. We thank Dr. Ian Mackenzie (Department of Pathology, University of British Columbia, Vancouver, Canada) and Dr. William Ellis (Department of Pathology, University of California, Davis, CA, USA) for assistance with two of the autopsies. We also thank Dr. Peter Pressman and Dr. Christa Watson for their help in reviewing draft and tables, and Dr. Giovanni Coppola for assistance with genetic data.

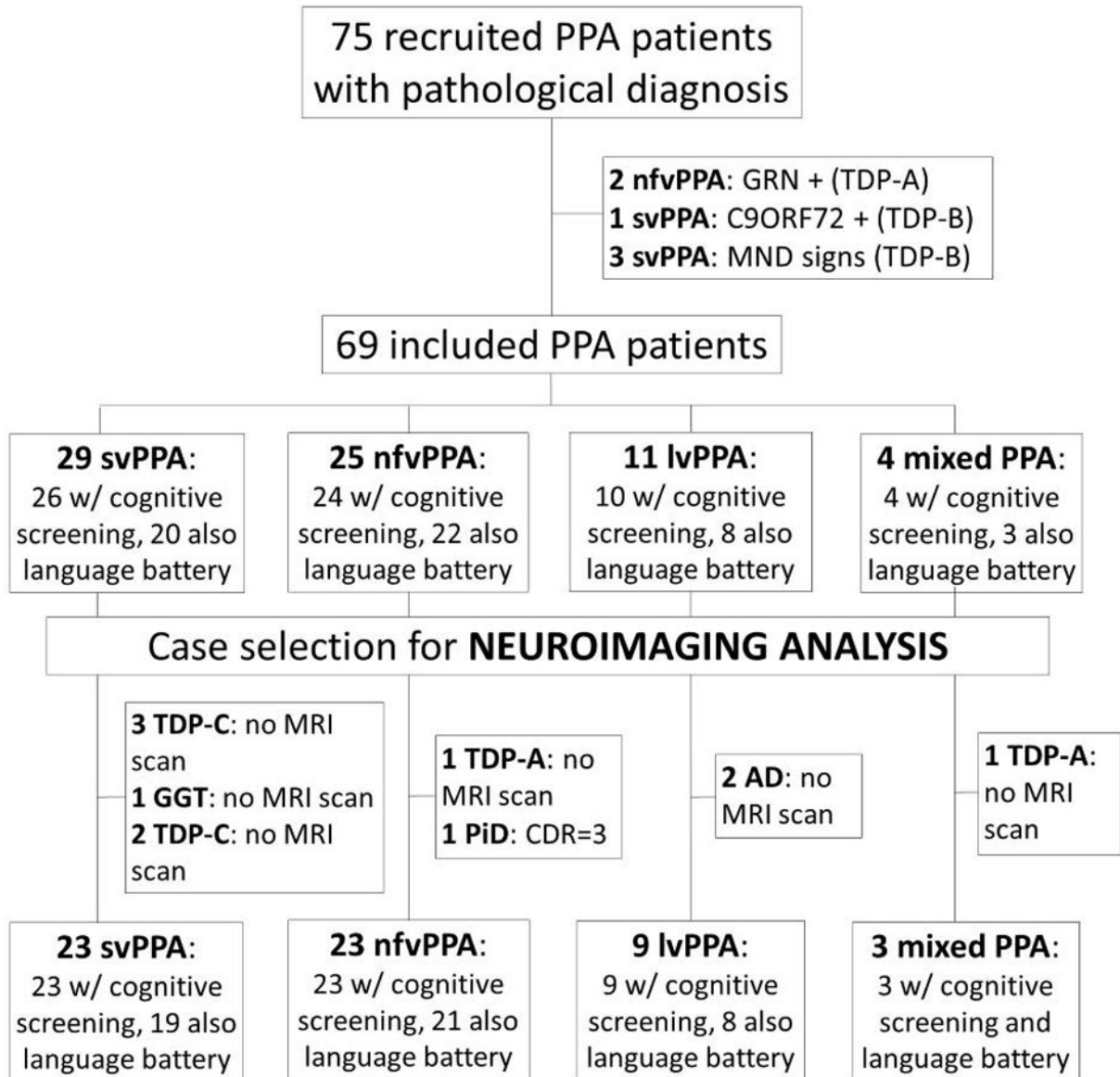
References

1. Gorno-Tempini ML, Hillis AE, Weintraub S, et al. Classification of primary progressive aphasia and its variants. *Neurology*. 2011 Mar 15; 76(11):1006–14. [PubMed: 21325651]
2. Chare L, Hodges JR, Leyton CE, et al. New criteria for frontotemporal dementia syndromes: clinical and pathological diagnostic implications. *Journal of neurology, neurosurgery, and psychiatry*. 2014 Aug; 85(8):865–70.
3. Mesulam M, Wicklund A, Johnson N, et al. Alzheimer and frontotemporal pathology in subsets of primary progressive aphasia. *Annals of neurology*. 2008 Jun; 63(6):709–19. [PubMed: 18412267]
4. Mesulam MM, Weintraub S, Rogalski EJ, Wieneke C, Geula C, Bigio EH. Asymmetry and heterogeneity of Alzheimer's and frontotemporal pathology in primary progressive aphasia. *Brain: a journal of neurology*. 2014 Apr; 137(Pt 4):1176–92. [PubMed: 24574501]
5. Grossman M. Primary progressive aphasia: clinicopathological correlations. *Nature reviews Neurology*. 2010 Feb; 6(2):88–97. [PubMed: 20139998]
6. Harris JM, Gall C, Thompson JC, et al. Classification and pathology of primary progressive aphasia. *Neurology*. 2013 Nov 19; 81(21):1832–9. [PubMed: 24142474]

7. Rohrer JD, Lashley T, Schott JM, et al. Clinical and neuroanatomical signatures of tissue pathology in frontotemporal lobar degeneration. *Brain: a journal of neurology*. 2011 Sep; 134(Pt 9):2565–81. [PubMed: 21908872]
8. Deramecourt V, Lebert F, Debachy B, et al. Prediction of pathology in primary progressive language and speech disorders. *Neurology*. 2010 Jan 5; 74(1):42–9. [PubMed: 19940270]
9. Josephs KA, Duffy JR, Strand EA, et al. Clinicopathological and imaging correlates of progressive aphasia and apraxia of speech. *Brain: a journal of neurology*. 2006 Jun; 129(Pt 6):1385–98. [PubMed: 16613895]
10. Knibb JA, Xuereb JH, Patterson K, Hodges JR. Clinical and pathological characterization of progressive aphasia. *Annals of neurology*. 2006 Jan; 59(1):156–65. [PubMed: 16374817]
11. Kertesz A, McMonagle P, Blair M, Davidson W, Munoz DG. The evolution and pathology of frontotemporal dementia. *Brain: a journal of neurology*. 2005 Sep; 128(Pt 9):1996–2005. [PubMed: 16033782]
12. Josephs KA, Dickson DW, Murray ME, et al. Quantitative neurofibrillary tangle density and brain volumetric MRI analyses in Alzheimer's disease presenting as logopenic progressive aphasia. *Brain and language*. 2013 Nov; 127(2):127–34. [PubMed: 23541297]
13. Rohrer JD, Rossor MN, Warren JD. Alzheimer's pathology in primary progressive aphasia. *Neurobiology of aging*. 2012 Apr; 33(4):744–52. [PubMed: 20580129]
14. Leyton CE, Britton AK, Hodges JR, Halliday GM, Kril JJ. Distinctive pathological mechanisms involved in primary progressive aphasias. *Neurobiology of aging*. 2016 Feb; 38:82–92. [PubMed: 26827646]
15. Clark CN, Lashley T, Mahoney CJ, Warren JD, Revesz T, Rohrer JD. Temporal Variant Frontotemporal Dementia is Associated with Globular Glial Tauopathy. *Cognitive and behavioral neurology: official journal of the Society for Behavioral and Cognitive Neurology*. 2015 Jun; 28(2):92–7. [PubMed: 26102999]
16. Rohrer JD, Geser F, Zhou J, et al. TDP-43 subtypes are associated with distinct atrophy patterns in frontotemporal dementia. *Neurology*. 2010 Dec 14; 75(24):2204–11. [PubMed: 21172843]
17. Hodges JR, Mitchell J, Dawson K, et al. Semantic dementia: demography, familial factors and survival in a consecutive series of 100 cases. *Brain: a journal of neurology*. 2010 Jan; 133(Pt 1):300–6. [PubMed: 19805492]
18. Rabinovici GD, Jagust WJ, Furst AJ, et al. Abeta amyloid and glucose metabolism in three variants of primary progressive aphasia. *Annals of neurology*. 2008 Oct; 64(4):388–401. [PubMed: 18991338]
19. Leyton CE, Villemagne VL, Savage S, et al. Subtypes of progressive aphasia: application of the International Consensus Criteria and validation using beta-amyloid imaging. *Brain: a journal of neurology*. 2011 Oct; 134(Pt 10):3030–43. [PubMed: 21908392]
20. Teichmann M, Kas A, Boutet C, et al. Deciphering logopenic primary progressive aphasia: a clinical, imaging and biomarker investigation. *Brain: a journal of neurology*. 2013 Nov; 136(Pt 11):3474–88. [PubMed: 24108322]
21. Kloppel S, Peter J, Ludl A, et al. Applying Automated MR-Based Diagnostic Methods to the Memory Clinic: A Prospective Study. *Journal of Alzheimer's disease: JAD*. 2015; 47(4):939–54. [PubMed: 26401773]
22. Cherubini A, Morelli M, Nistico R, et al. Magnetic resonance support vector machine discriminates between Parkinson disease and progressive supranuclear palsy. *Movement disorders: official journal of the Movement Disorder Society*. 2014 Feb; 29(2):266–9. [PubMed: 24323617]
23. Wilson SM, Ogar JM, Laluz V, et al. Automated MRI-based classification of primary progressive aphasia variants. *NeuroImage*. 2009 Oct 1; 47(4):1558–67. [PubMed: 19501654]
24. Gorno-Tempini ML, Dronkers NF, Rankin KP, et al. Cognition and anatomy in three variants of primary progressive aphasia. *Annals of neurology*. 2004 Mar; 55(3):335–46. [PubMed: 14991811]
25. Moreno F, Rabinovici GD, Karydas A, et al. A novel mutation P112H in the TARDBP gene associated with frontotemporal lobar degeneration without motor neuron disease and abundant neuritic amyloid plaques. *Acta neuropathologica communications*. 2015; 3:19. [PubMed: 25853458]

26. Li Y, Chen JA, Sears RL, et al. An epigenetic signature in peripheral blood associated with the haplotype on 17q21.31, a risk factor for neurodegenerative tauopathy. *PLoS genetics*. 2014 Mar; 10(3):e1004211. [PubMed: 24603599]
27. Kramer JH, Jurik J, Sha SJ, et al. Distinctive neuropsychological patterns in frontotemporal dementia, semantic dementia, and Alzheimer disease. *Cognitive and behavioral neurology: official journal of the Society for Behavioral and Cognitive Neurology*. 2003 Dec; 16(4):211–8. [PubMed: 14665820]
28. Mackenzie IR, Neumann M, Bigio EH, et al. Nomenclature and nosology for neuropathologic subtypes of frontotemporal lobar degeneration: an update. *Acta neuropathologica*. 2010 Jan; 119(1):1–4. [PubMed: 19924424]
29. The National Institute on Aging, and Reagan Institute Working Group on Diagnostic Criteria for the Neuropathological Assessment of Alzheimer's Disease. Consensus recommendations for the postmortem diagnosis of Alzheimer's disease. *Neurobiology of aging*. 1997 Jul-Aug; 18(4 Suppl):S1–2. [PubMed: 9330978]
30. McKeith IG, Galasko D, Kosaka K, et al. Consensus guidelines for the clinical and pathologic diagnosis of dementia with Lewy bodies (DLB): report of the consortium on DLB international workshop. *Neurology*. 1996 Nov; 47(5):1113–24. [PubMed: 8909416]
31. Mandelli ML, Vitali P, Santos M, et al. Two insular regions are differentially involved in behavioral variant FTLD and nonfluent/agrammatic variant PPA. *Cortex; a journal devoted to the study of the nervous system and behavior*. 2015 Nov 14; 74:149–57. [PubMed: 26673947]
32. Zhang Y, Schuff N, Ching C, et al. Joint assessment of structural, perfusion, and diffusion MRI in Alzheimer's disease and frontotemporal dementia. *International journal of Alzheimer's disease*. 2011; 2011:546871.
33. Ashburner J, Friston KJ. Unified segmentation. *NeuroImage*. 2005 Jul 1; 26(3):839–51. [PubMed: 15955494]
34. Ashburner J. A fast diffeomorphic image registration algorithm. *NeuroImage*. 2007 Oct 15; 38(1):95–113. [PubMed: 17761438]
35. Chang CC, Lin CJ. LIBSVM: A Library for Support Vector Machines. *Acm T Intel Syst Tec*. 2011; 2(3)
36. Spinelli EG, Caso F, Agosta F, et al. A multimodal neuroimaging study of a case of crossed nonfluent/agrammatic primary progressive aphasia. *Journal of neurology*. 2015 Oct; 262(10):2336–45. [PubMed: 26194195]
37. Caso F, Mandelli ML, Henry M, et al. In vivo signatures of nonfluent/agrammatic primary progressive aphasia caused by FTLN pathology. *Neurology*. 2014 Jan 21; 82(3):239–47. [PubMed: 24353332]
38. Catani M, Mesulam MM, Jakobsen E, et al. A novel frontal pathway underlies verbal fluency in primary progressive aphasia. *Brain: a journal of neurology*. 2013 Aug; 136(Pt 8):2619–28. [PubMed: 23820597]
39. Gorno-Tempini ML, Brambati SM, Ginex V, et al. The logopenic/phonological variant of primary progressive aphasia. *Neurology*. 2008 Oct 14; 71(16):1227–34. [PubMed: 18633132]
40. Rabinovici GD, Rosen HJ, Alkalay A, et al. Amyloid vs FDG-PET in the differential diagnosis of AD and FTLN. *Neurology*. 2011 Dec 6; 77(23):2034–42. [PubMed: 22131541]
41. Leyton CE, Hodges JR, McLean CA, Kril JJ, Piguet O, Ballard KJ. Is the logopenic-variant of primary progressive aphasia a unitary disorder? *Cortex; a journal devoted to the study of the nervous system and behavior*. 2015 Jun; 67:122–33. [PubMed: 25955499]
42. Rosen HJ, Allison SC, Schauer GF, Gorno-Tempini ML, Weiner MW, Miller BL. Neuroanatomical correlates of behavioural disorders in dementia. *Brain: a journal of neurology*. 2005 Nov; 128(Pt 11):2612–25. [PubMed: 16195246]
43. McMillan CT, Irwin DJ, Avants BB, et al. White matter imaging helps dissociate tau from TDP-43 in frontotemporal lobar degeneration. *Journal of neurology, neurosurgery, and psychiatry*. 2013 Sep; 84(9):949–55.
44. Agosta F, Galantucci S, Magnani G, et al. MRI signatures of the frontotemporal lobar degeneration continuum. *Human brain mapping*. 2015 Jul; 36(7):2602–14. [PubMed: 25821176]

45. Liu L, Drouet V, Wu JW, et al. Trans-synaptic spread of tau pathology in vivo. *PLoS one*. 2012; 7(2):e31302. [PubMed: 22312444]
46. Clavaguera F, Akatsu H, Fraser G, et al. Brain homogenates from human tauopathies induce tau inclusions in mouse brain. *Proceedings of the National Academy of Sciences of the United States of America*. 2013 Jun 4; 110(23):9535–40. [PubMed: 23690619]
47. Nonaka T, Masuda-Suzukake M, Arai T, et al. Prion-like properties of pathological TDP-43 aggregates from diseased brains. *Cell reports*. 2013 Jul 11; 4(1):124–34. [PubMed: 23831027]
48. Brettschneider J, Del Tredici K, Irwin DJ, et al. Sequential distribution of pTDP-43 pathology in behavioral variant frontotemporal dementia (bvFTD). *Acta neuropathologica*. 2014 Mar; 127(3): 423–39. [PubMed: 24407427]
49. Seeley WW, Crawford RK, Zhou J, Miller BL, Greicius MD. Neurodegenerative diseases target large-scale human brain networks. *Neuron*. 2009 Apr 16; 62(1):42–52. [PubMed: 19376066]
50. Staekenborg SS, Pijnenburg YA, Lemstra AW, Scheltens P, Vd Flier WM. Dementia and Rapid Mortality: Who is at Risk? *Journal of Alzheimer's disease: JAD*. 2016 Apr 19.

**Figure 1.**

Flow chart showing inclusion/exclusion process of patients for the present study. Numbers of patients who underwent general cognitive, language and neuroimaging assessments are specified for each group. Abbreviations: AD= Alzheimer's disease; GGT= globular glial tauopathy; lvPPA= logopenic variant PPA; MND= motor neuron disease; nfvPPA= non-fluent/agrammatic variant PPA; PiD= Pick's disease; PSP= progressive supranuclear palsy; svPPA= semantic variant PPA; TDP-A, TDP-B, TDP-C= frontotemporal lobar degeneration with TDP-43 depositions type A, type B or type C.

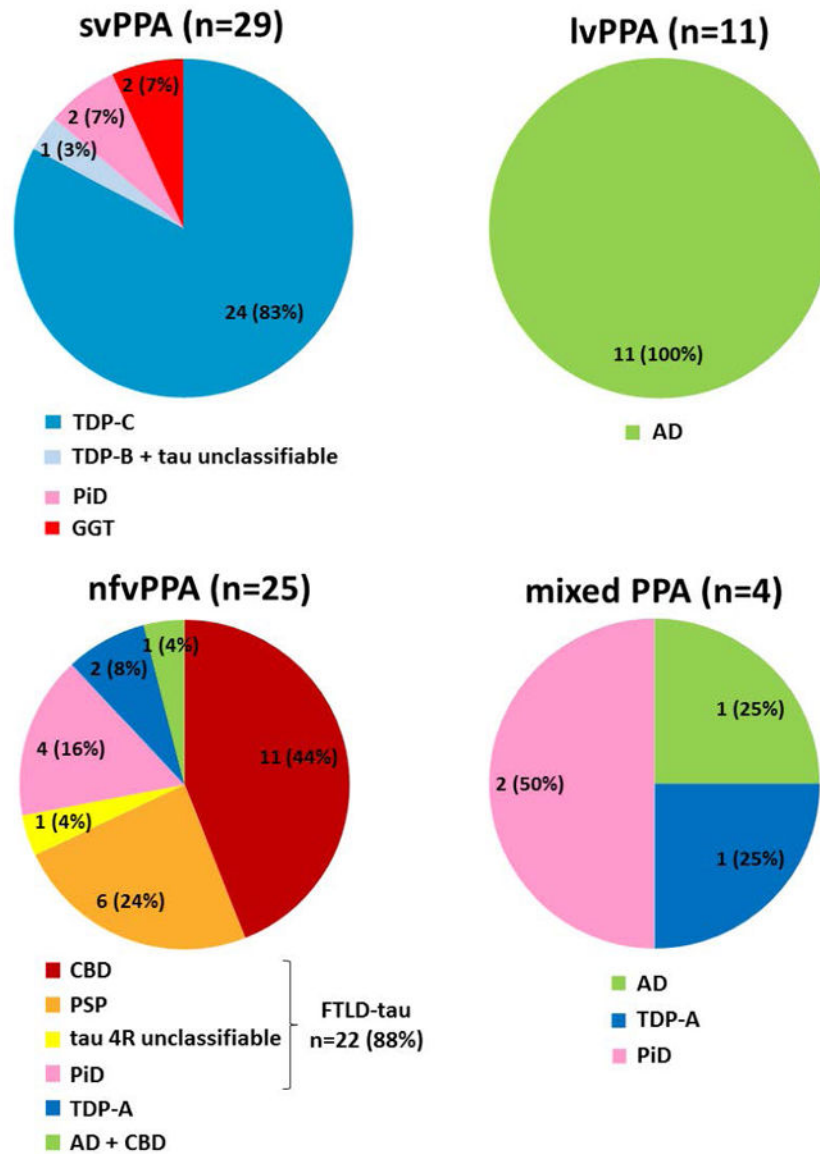


Figure 2. Primary neuropathological diagnosis in primary progressive aphasia (PPA) clinical variants. Values are frequencies (percentages). Abbreviations: AD= Alzheimer's disease; CBD= corticobasal degeneration; FTLD= frontotemporal lobar degeneration; GGT= globular glial tauopathy; lvPPA= logopenic variant PPA; nfvPPA= non-fluent/agrammatic variant PPA; PiD= Pick's disease; PSP= progressive supranuclear palsy; svPPA= semantic variant PPA; tau 4R= FTLD-tau with 4 repeats.

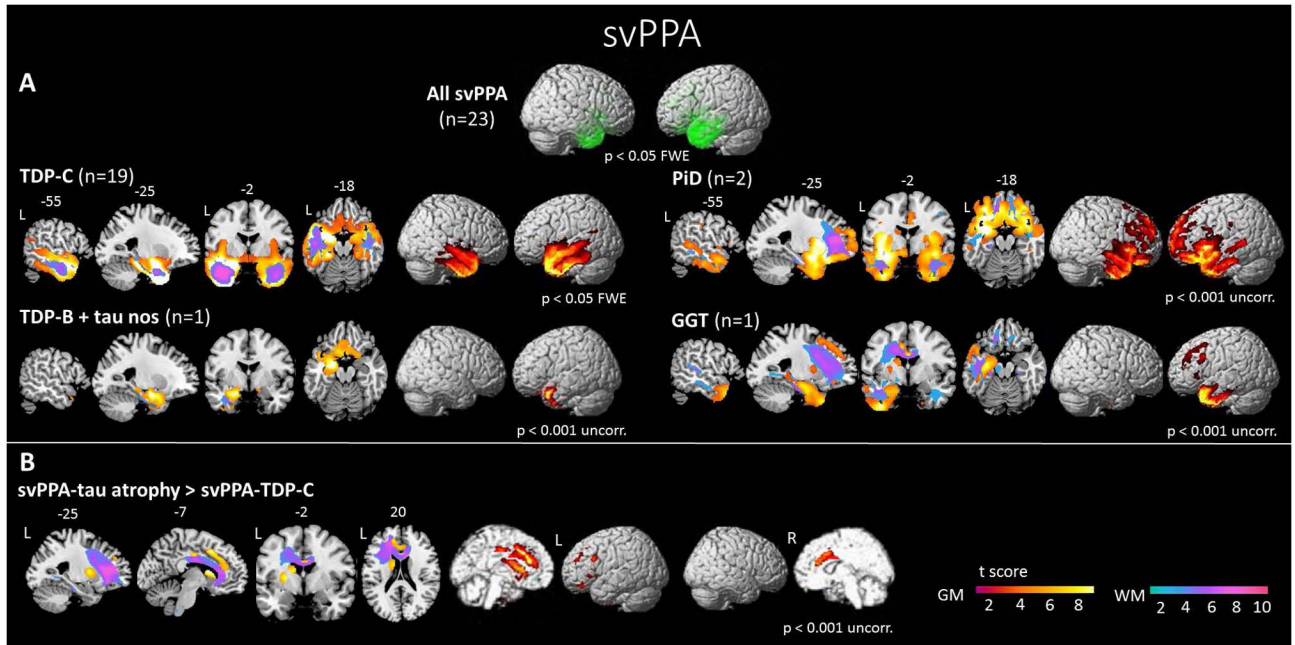


Figure 3.

Voxel-based morphometry analysis in patients with semantic variant of primary progressive aphasia (svPPA). Patterns of (A) cortical atrophy in all svPPA patients relative to healthy controls; (B) grey and white matter atrophy in each pathological subgroup relative to healthy controls; and (C) grey and white matter atrophy in svPPA patients with frontotemporal lobar degeneration due to tau (FTLD-tau) relative to those with TDP-43 depositions (FTLD-TDP) are shown, overlaid on sections or a three-dimensional rendering of a standard Montreal Neurologic Institute (MNI) brain. Slice labels refer to MNI coordinates. Abbreviations: FTLT= frontotemporal lobar degeneration; GGT= globular glial tauopathy; L= left; PiD= Pick's disease; R= right; svPPA= semantic variant PPA; TDP-B= frontotemporal lobar degeneration with TDP-43 depositions type B; TDP-C= frontotemporal lobar degeneration with TDP-43 depositions type C.

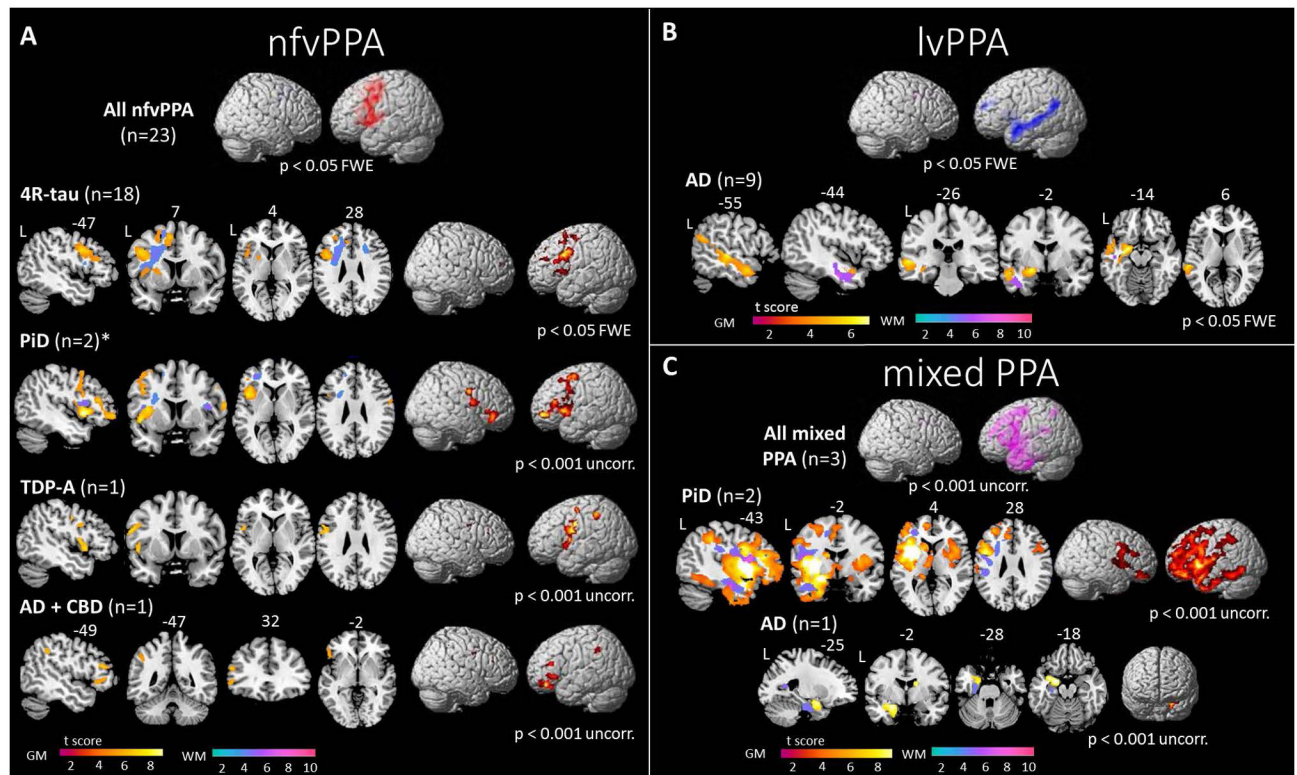


Figure 4.

Voxel-based morphometry analysis showing patterns of grey and white matter atrophy in patients with (A) non-fluent/agrammatic variant of primary progressive aphasia (nfvPPA), (B) logopenic variant of primary progressive aphasia (lvPPA) and (C) mixed PPA patients relative to healthy controls, according to pathological subgroups. All contrasts are overlaid on sections or a three-dimensional rendering of a standard Montreal Neurologic Institute (MNI) brain. Slice labels refer to MNI coordinates. *= a third nfvPPA patient with Pick's disease showed selective right-sided atrophy (not displayed, see description in body text). Abbreviations: 4R-tau= frontotemporal lobar degeneration with 4-repeat tau depositions; AD= Alzheimer's disease; FTL= frontotemporal lobar degeneration; L= left; nfvPPA= non-fluent/agrammatic variant PPA; PiD= Pick's disease; R= right; TDP-A= frontotemporal lobar degeneration with TDP-43 depositions type A.

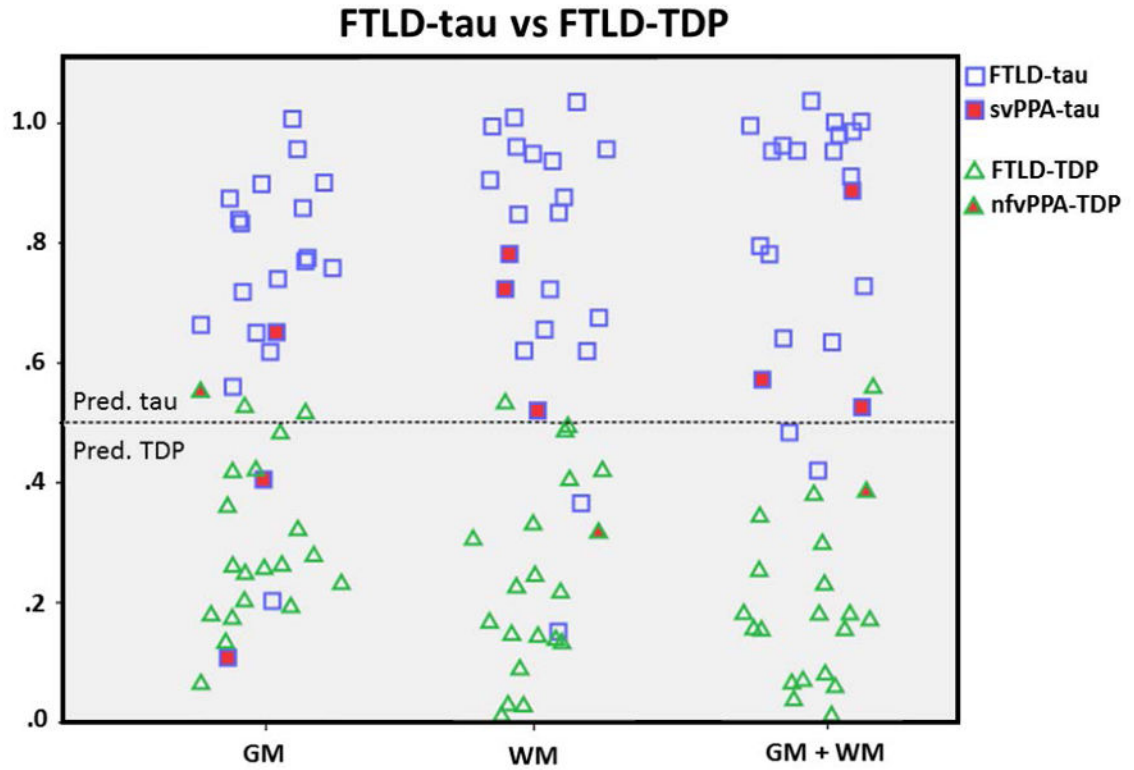


Figure 5.

Performance of support vector machine classification at a single-patient level is represented for patterns of grey matter (GM, first column), white matter (WM, second column) and a relative combination (GM+WM, third column). Colors and shapes indicate the pathological diagnosis (blue squares, PPA patients with FTLD-tau; green triangles, PPA with FTLD-TDP). Patients with “atypical” pathologies (i.e., svPPA-tau and nfvPPA-TDP) are filled in red. Patients are distributed along a vertical axis according to the probability of belonging to the FTLD-tau group (threshold >0.5) or the FTLD-TDP group (threshold <0.5).

Abbreviations: FTLD= frontotemporal lobar degeneration; FTLD-tau= FTLD with tau depositions; FTLD-TDP= FTLD with TDP-43 depositions; nfvPPA= non-fluent/agrammatic variant PPA; svPPA= semantic variant PPA.

Table 1

Demographic, clinical, genetic, and cognitive features of patients with PPA clinical variants. Values are means \pm standard deviations.

	svPPA (n=29)	nvPPA (n=25)	lvPPA (n=11)	mixed PPA (n=4)
Gender [F/M]	14/15	18/7	6/5	1/3
Handedness [RH/nRH]	25/4	24/1	9/2	3/1
Education [y]	16.8 \pm 3.1	16.3 \pm 3.2	16.5 \pm 2.9	15.5 \pm 3.4
Age at onset [y]	59.6 \pm 7.2	64.4 \pm 7.5	63.0 \pm 7.9	61.8 \pm 4.5
Age at first evaluation [y]	64.7 \pm 6.7	68.6 \pm 7.6	66.8 \pm 8.6	65.7 \pm 4.4
Survival [y]	11.6 \pm 4.3 ^a	8.0 \pm 2.5 ^{b,c}	11.0 \pm 4.1 ^a	9.3 \pm 2.5
CDR total	1.0 \pm 0.7	0.5 \pm 0.5	0.9 \pm 0.9	0.6 \pm 0.3
NPI total	23.7 \pm 14.1 ^c	16.6 \pm 14.7	5.0 \pm 5.3 ^b	14.3 \pm 15.9
UPDRS motor score	0.7 \pm 1.4 ^{a,d}	12.1 \pm 9.8 ^{b,c}	1.9 \pm 4.9 ^a	17.3 \pm 15.8 ^b
<i>ApoE4</i> allelic frequency	29% ^a	5% ^{b,c}	56% ^a	25%
<i>MAPTH1/H1</i> haplotype	54% ^a	95% ^{b,c}	44% ^a	75%
COGNITIVE DATA				
MMSE	20.2 \pm 9.0	23.9 \pm 7.2 ^d	20.1 \pm 6.1	14.8 \pm 5.4 ^a
CVLT-MS total learning (36 items)	14.3 \pm 7.2 ^a	24.0 \pm 6.2 ^{b,c}	14.2 \pm 6.5 ^a	16.3 \pm 5.0
CVLT-MS 10'-free recall (9)	1.3 \pm 2.2 ^a	6.1 \pm 2.2 ^b	3.0 \pm 2.9	2.3 \pm 4.0
Benson figure copy (17)	14.6 \pm 2.6	14.8 \pm 1.8	13.7 \pm 5.4	12.5 \pm 1.0
Benson figure recall (17)	6.1 \pm 4.2	9.8 \pm 3.6 ^c	7.8 \pm 4.6	3.0 \pm 6.0
Calculations (5)	4.2 \pm 1.2	4.4 \pm 1.0 ^c	2.9 \pm 1.8 ^a	2.7 \pm 2.5
Digit Span backward	4.0 \pm 1.7 ^{a,c,d}	2.9 \pm 1.3 ^b	2.9 \pm 1.1 ^b	2.3 \pm 1.5 ^b
Modified trails (correct lines/min)	17.0 \pm 14.1 ^c	10.2 \pm 9.7	6.3 \pm 6.7 ^b	7.8 \pm 10.3
Phonemic fluency (D words/minute)	6.2 \pm 4.0	4.1 \pm 2.9	6.6 \pm 5.1	2.7 \pm 2.5
Semantic fluency (Animals/minute)	5.7 \pm 3.8 ^a	9.3 \pm 4.2 ^b	9.1 \pm 5.4	7.3 \pm 6.4
Modified Boston Naming Test (15)	3.8 \pm 3.2 ^{a,c,d}	12.4 \pm 2.9 ^{b,c}	8.7 \pm 4.1 ^{a,b}	10.0 \pm 5.0 ^b
Word recognition (WAB, 60)	50.8 \pm 9.6 ^{a,c}	59.4 \pm 1.4 ^{b,d}	58.4 \pm 1.9 ^{b,d}	51.7 \pm 5.0 ^{a,c}
Pyramid and Palm Trees (52)	36.5 \pm 7.8 ^{a,c}	48.4 \pm 4.3 ^b	46.1 \pm 6.0 ^b	39.0 \pm 8.5
Spontaneous speech fluency (WAB, 10)	9.0 \pm 1.0 ^{a,d}	6.6 \pm 2.8 ^b	7.9 \pm 1.5	5.7 \pm 3.5 ^b
Apraxia of speech (MSE, 7)	0 ^{a,d}	2.4 \pm 2.0 ^b	1.3 \pm 1.3	3.3 \pm 3.5 ^b
Dysarthria (MSE, 7)	0 ^a	2.7 \pm 2.7 ^{b,c}	0 ^a	2.0 \pm 2.8
Repetition (WAB, 100)	86.7 \pm 11.3 ^{c,d}	85.5 \pm 14.8 ^{c,d}	71.4 \pm 7.1 ^{a,b}	55.0 \pm 34.4 ^{a,b}
Sequential commands (WAB, 80)	71.8 \pm 8.6	69.7 \pm 16.1	60.8 \pm 14.9	61.0 \pm 10.6
Syntax Comprehension (CYCLE) % correct	91.3 \pm 7.4 ^{c,d}	83.9 \pm 5.3 ^b	87.6 \pm 12.6	76.7 \pm 6.7 ^b

P values refer to Kruskal-Wallis or Pearson's chi square test, as appropriate.

^a = $p < 0.05$ vs nfvPPA;

^b = $p < 0.05$ vs svPPA;

^c = $p < 0.05$ vs lvPPA;

^d = $p < 0.05$ vs mixed PPA;

italicized = $p < 0.05$ vs controls at post-hoc pairwise comparisons.

CDR= Clinical Dementia Rating scale; CVLT-MS: California Verbal Learning Test-Mental Status version; CYCLE= Curtiss-Yamada Comprehensive Language Evaluation; F= females; L= left-handed; M= males; MMSE= Mini Mental State Examination; MSE= Motor Speech Evaluation; NPI= Neuropsychiatric Inventory; nRH= non-right-handed; RH= right-handed; UPDRS= Unified Parkinson's Disease Rating Scale; WAB= Western Aphasia Battery; y= years.

Table 2

Demographic and clinical features at first evaluation of svPPA and nfvPPA patients according to FTLD pathological subtypes. Patients with a mixed primary pathology are not shown. Values are means \pm standard deviations. For details regarding other pathological subgroups and individual scores see Supplementary Table 2.

PPA clinical variant	svPPA		nfvPPA		p
	svPPA-TDP (n=24)	svPPA-tau (n=4)	nfvPPA-tau (n=22)	nfvPPA-TDP (n=2)	
Pathology					
Gender [F/M]	10/14	3/1	15/7	F	1.00
Handedness [RH/nRH]	21/3	3/1	21/1	RH	1.00
Education [y]	16.5 \pm 3.3	18.0 \pm 8.4	16.0 \pm 3.2	19	0.38
Age at onset [y]	59.2 \pm 7.1	60.5 \pm 8.7	63.7 \pm 7.7	68	0.37
Age at first evaluation [y]	64.2 \pm 6.6	67.0 \pm 8.5	67.9 \pm 7.8	71	0.53
Age at death [y]	71.2 \pm 5.6	71.3 \pm 8.4	71.7 \pm 7.6	78	0.37
Disease duration at first evaluation [y]	4.8 \pm 1.9	6.4 \pm 3.8	4.1 \pm 1.7	3	0.92
Disease duration at death [y]	12.0 \pm 3.9	10.8 \pm 5.9	8.0 \pm 2.6	10	0.52
CDR total	0.9 \pm 0.7	1.5 \pm 0.6	0.5 \pm 0.4	0	0.81
Behavioral symptoms [+/-]	14/10	4/0	19/3	-	0.04
NPI total	20.4 \pm 13.8	30.0 \pm 12.1	16.5 \pm 14.3	0	0.16
Extrapyramidal motor signs [+/-]	1/23	3/1	18/4	-	0.05
UPDRS motor score	0.3 \pm 0.8	2.5 \pm 1.9	11.4 \pm 9.6	0	0.04
<i>ApoE4</i> allele [+/- in tested subjects]	3/16	3/1	1/17	-	NA
<i>MAPTH1/H1</i> [+/- in tested subjects]	9/10	3/1	18/0	-	NA

P values refer to Mann-Whitney U test of Fisher's exact tests between patient groups, as appropriate.

Abbreviations: CDR= Clinical Dementia Rating scale; F= females; L= left-handed; M= males; nfvPPA= non-fluent/agrammatic variant PPA; NPI= Neuropsychiatric Inventory; nRH= non-right-handed; PPA= primary progressive aphasia; RH= right-handed; svPPA= semantic variant PPA; TDP= TDP-43 inclusions; UPDRS= Unified Parkinson's Disease Rating Scale; y= years; "+," = positive; "-," = negative.

Table 3

General cognitive and language features at first evaluation of svPPA and nfvPPA patients according to FTLD pathological subtypes. Patients with a mixed primary pathology and/or who were unable to undergo formal testing are not shown. Values are means \pm standard deviations. For details regarding other pathological subgroups and individual scores see Supplementary Table 3.

PPA clinical variant	svPPA		nfvPPA		p	
	svPPA-TDP (n=22)	svPPA-tau (n=3)	nfvPPA-tau (n=21)	nfvPPA-TDP (n=2)		
Pathology					p	
GENERAL COGNITIVE DATA						
MMSE	23.2 \pm 5.9	17.0 \pm 7.0	25.7 \pm 4.0	27	8	0.33
CVLT-MS total learning (36 items)	14.4 \pm 7.1	10.0 \pm 11.3	23.8 \pm 6.4	29	NA	NA
CVLT-MS 10'-free recall (9)	1.5 \pm 2.3	0.5 \pm 0.7	6.1 \pm 2.2	8	NA	NA
Benson figure copy (17)	14.9 \pm 3.2	12.3 \pm 2.1	14.6 \pm 1.9	17	15	0.29
Benson figure recall (17)	6.1 \pm 4.4	3.0 \pm 3.6	9.9 \pm 3.8	9	6	0.33
Calculations (5)	4.4 \pm 1.1	3.0 \pm 1.7	4.5 \pm 1.0	5	3	0.50
Digit Span backward	4.5 \pm 1.3	1.7 \pm 1.5	3.0 \pm 1.4	3	2	0.44
Modified trails (correct lines/min)	16.9 \pm 14.4	3.4 \pm 4.3	10.3 \pm 9.6	23	4	0.86
SPEECH AND LANGUAGE DATA						
Phonemic fluency (D words/minute)	6.6 \pm 3.7	1.3 \pm 2.3	4.3 \pm 3.0	4	0	0.33
Semantic fluency (Animals/minute)	5.9 \pm 3.6	4.7 \pm 6.4	9.4 \pm 4.4	12	5	0.79
Modified Boston Naming Test (15)	3.8 \pm 3.1	5.5 \pm 6.4	12.7 \pm 2.1	15	3	0.79
Word recognition (WAB, 60)	50.9 \pm 9.5	48.0 \pm 17.0	59.4 \pm 1.5	60	NA	NA
Pyramid and Palm Trees (52)	36.4 \pm 7.9	39.5 \pm 10.6	48.5 \pm 4.5	49	NA	NA
Spontaneous speech fluency (WAB, 10)	8.9 \pm 1.1	9.5 \pm 0.7	7.0 \pm 2.5	0	NA	NA
Apraxia of speech (MSE, 7)	0	0	2.1 \pm 1.9	7	NA	NA
Dysarthria (MSE, 7)	0	0	2.6 \pm 2.9	NA	NA	NA
Repetition (WAB, 100)	86.3 \pm 11.2	83.0 \pm 14.1	85.3 \pm 15.1	NA	NA	NA
Seq. commands (WAB, 80)	71.0 \pm 7.7	73.0 \pm 9.9	71.5 \pm 9.0	70	NA	NA
Syntax Compr. (CYCLE) % correct	90.7 \pm 8.1	94.0 \pm 1.4	46.6 \pm 6.3	96	NA	NA

P values refer to Mann-Whitney U test of Fisher's exact tests between patient groups, as appropriate.

Italicized = abnormal scores in reference to control group data ($p < 0.05$ vs. controls at Mann-Whitney U test for groups, \pm standard deviations below control data for individual scores), when applicable.

Author Manuscript

Author Manuscript

Author Manuscript

Author Manuscript

Abbreviations: CVLT-MS: California Verbal Learning Test-Mental Status version; CYCLE= Curtiss-Yamada Comprehensive Language Evaluation; MMSE= Mini Mental State Examination; MSE= Motor Speech Evaluation; NA= not applicable; nvPPA= non-fluent/agrammatic variant PPA; PPA= primary progressive aphasia; svPPA= semantic variant PPA; TDP= TDP-43 inclusions; WAB= Western Aphasia Battery.