

This article is licensed under the Creative Commons Attribution-NonCommercial 4.0 International License (CC BY-NC) (<http://www.karger.com/Services/OpenAccessLicense>). Usage and distribution for commercial purposes requires written permission.

Case Report

Refined Internal Limiting Membrane Inverted Flap Technique for Intractable Macular Detachment with Optic Disc Pit

Rumiko Hara Yasutomo Tsukahara Tsuyoshi Simoyama
Soutarou Mori

Department of Ophthalmology, Kakogawa Central City Hospital, Kakogawa, Japan

Keywords

Optic disc pits · Retinal detachment · Internal limiting membrane flap · Vitrectomy

Abstract

Purpose: To report a surgical technique for retinal detachment associated with optic disc pit (ODP) by using an internal limiting membrane (ILM) inverted flap as an obstacle between the vitreous cavity and subretinal space. **Case Presentation:** A 43-year-old man presented with decreased visual acuity in the right eye for 1 week due to macular detachment associated with ODP. After 2 unsuccessful surgeries, the retina was reattached by vitrectomy with an ILM inverted flap onto the ODP. **Conclusion:** Covering the pit with an inverted ILM flap is a reliable method for intercepting fluid from the vitreous cavity. Immediate absorption of subretinal fluid may lead to early macular attachment. This technique would be effective in managing ODP.

© 2017 The Author(s)
Published by S. Karger AG, Basel

Introduction

Optic disc pit (ODP) is a rare congenital anomaly, and 25–75% of patients with ODP develop a serous macular detachment in early adulthood. The origin of subretinal fluid (SRF) remains controversial. Hence, multiple treatments have been reported. The removal of vit-

reous traction is essential for the treatment of ODP-maculopathy (ODP-M) [1], so vitrectomy with or without various options, such as laser photocoagulation, intravitreal gas tamponade, and internal limiting membrane (ILM) peeling, is the standard treatment for the management of ODP-M. However, surgical failure is sometimes experienced. Here, we describe a case of intractable macular detachment with ODP that was successfully treated by obstructing the vitreous fluid flow into the pit by using an ILM inverted flap.

Case Presentation

A 43-year-old Japanese man presented with decreased vision in his right eye that had lasted for 7 days prior to the hospital visit. His ocular history consisted of the diagnosis of ODP at another hospital several years ago. The best-corrected visual acuity was 20/150 and intraocular pressure was 16 mm Hg in the right eye. Slit-lamp examination was unremarkable in both eyes, but funduscopy disclosed a bullous retinal detachment involving the macula and superotemporal area in his right eye. Optical coherence tomography (Spectralis OCT-Heidelberg Engineering, Heidelberg, Germany) revealed retinal detachment without retinoschisis connected to the ODP (Fig. 1).

After informed consent was received from the patient, he underwent combined phacoemulsification with in-the-bag implantation of an intraocular lens and a 25-gauge pars plana vitrectomy. After the core vitrectomy, posterior vitreous detachment was initiated by suction over the optic disc using a vitreous cutter. Triamcinolone acetonide was used during surgery to visualize the vitreous. Fluid-gas exchange was performed with aspiration of SRF through an intentional drainage hole at the superotemporal quadrant. Finally, intravitreal air was exchanged with 20% sulfur hexafluoride gas. Neither ILM peeling nor laser photocoagulation temporal to the disc was performed. The patient was instructed to remain in the prone position. Two days postoperatively, the migration of a small amount of gas in the subretinal space between the optic disc and the central macula was noted. The migrated gas resolved spontaneously in several days. OCT revealed an apparent connection between the ODP and the vitreous cavity (Fig. 1).

Fifteen days after the initial surgery, macular detachment recurred and a second surgery was planned. The surgery consisted of removal of residual intraocular gas, SRF drainage with another intentional retinal hole near the first one, endophotocoagulation to the temporal peripapillary retina, and silicone oil tamponade. The patient was kept in the prone position. Five days after the second surgery, numerous silicon oil droplets were noted in the subretinal space associated with retinal re-detachment.

Nine days after the second surgery, an additional procedure was planned. Subretinal silicon oil was removed through the inferior peripheral retinotomy. The ILM was stained with ILM-Blue (DORC International), and a temporal optic disc edge-based 1.5-DD sized ILM flap excluding the foveal area was made to cover the optic disc including the ODP (Fig. 2). Finally, the vitreous cavity was filled with 12% octafluoropropane gas, and the patient was instructed to remain in the prone position. SRF was rapidly absorbed, and the retina remained attached at 3 months, which was the patient's final postoperative visit. Postoperative OCT revealed the inverted ILM flap lying over the ODP (Fig. 3). The best-corrected visual acuity was 20/200 in the right eye. It did not improve from the preoperative acuity because of preexisting extensive retinal pigmented epithelial atrophy involving the macula.

Discussion

ODP is a congenital anomaly of the optic nerve that occurs in approximately 1 in 10,000 eyes. In 25–75% of patients, serous macular detachment occurs in early adulthood. Although spontaneous resolution of OPD maculopathy after posterior vitreous detachment has been reported [2], visual acuity in ODP maculopathy cases usually decreases to less than 20/70, and it deteriorates to less than 20/200 in 80% of eyes with a mean follow-up period of 9 years in its natural course [3]. Surgical management is usually performed at the time of diagnosis, but there is no established method for the surgical approach.

Evaluation of the SRF source plays a key role in the management of ODP maculopathy. Several theories have been proposed for the source of SRF, but the 2 primary theories are cerebral spinal fluid (CSF) and vitreous fluid. CSF from the subarachnoid space as a source of SRF was supported by Kuhn et al. [4] who reported a case of intracranial migration of silicon oil after surgery for ODP. Vitreous fluid as a source of SRF was supported by Brown et al. [5] who reported an experiment on Collie dogs. They showed that India ink injected into the vitreous cavity flowed into the subretinal space, and they evaluated the connection between the vitreous and subretinal space. Dithmar et al. [6] reported the migration of perfluorodecalin and silicon oil to the subretinal space after a patient received surgery for ODP maculopathy. Katome et al. [7] reported that both hypotheses can be supported by swept source OCT. Theoretically, the 2 hypotheses are possible, but only the vitreous fluid hypothesis is supported by clinical findings. Kuhn et al. [4] noted communication between the pit and subarachnoid space, but did not show the CSF flow into the subretinal space. To the best of our knowledge, there are no reports that demonstrate the direct flow of CSF into the subretinal space. In our case as well as previous reports [6], gas and silicon oil migrated into the subretinal space after surgery, which suggests that fluid flows from the vitreous cavity to the subretinal space.

Although several successful therapeutic approaches have been reported, there is no consensus on the treatment of maculopathy with ODP. Laser therapy was reported to produce a barrier between the pit and subretinal space, but currently its success is considered dubious. Lincoff et al. [8] concluded that the effect of monotherapy with intravitreal gas injection was only temporary.

In recent years, vitreous traction has been considered an important factor in the pathogenesis of ODP-M [1], and vitrectomy is a widespread treatment method. Hirakata et al. [1, 9] reported 2 series of studies in which complete posterior vitreous detachment was made during vitrectomy to eliminate the vitreous traction to the pit. Complete retinal reattachment was achieved in 10 of 11 eyes after 1 year with gas tamponade [9] and in 7 of 8 eyes within 16 months without gas [1]. Teke et al. [10] reported no difference in visual acuity and foveal thickness between 7 eyes treated with vitrectomy monotherapy and 10 eyes treated with vitrectomy and gas tamponade. They concluded that additional therapies beyond vitrectomy are unnecessary for a successful result.

ILM peeling is a valid method to remove the adhesion between the vitreous and retina, but it carries the risk of iatrogenic macular hole formation. Moon et al. [11] noted that artificial inner retinal fenestration was useful to redirect the fluid from the subretinal or interretinal space to the vitreous cavity, regardless of the source of the fluid.

Recently, several investigators have performed new procedures to seal the pit directly. Travassos et al. [12] reported that autologous sclera successfully sealed the pit in 3 eyes, 1 of which was a re-operation. Mohammed and Pai [13] reported a case in which the pit was covered with an autologous ILM flap, which led to the anatomical occlusion of the pit and a

successful outcome. In our case, the ILM flap worked as an effective plug after the third operation.

Coca et al. [14] reported a case of ODP-M that recurred 16 years after vitrectomy, and they suggested that vitreous traction did not cause the recurrent maculopathy. We suppose that the complete removal of vitreous traction is an unreliable method to cure ODP-M in not only recurrent cases but also primary cases. Interception of fluid from the vitreous cavity to the subretinal space by closing the ODP seems to be a certain remedy for ODP-M.

The ILM inverted flap method is technically feasible because the ILM peeling procedure has recently become a standard technique in vitrectomy. In addition, ILM is easy to prepare as a material for sealing. Our small-sized ILM flap is enough to cover the pit. Large-sized flaps that include the fovea might lead to a macular hole, as Mohammed and Pai reported [13]. An additional benefit of the small-sized ILM flap is that it is easier to make for surgeons. Hirakata et al. [9] reported that it took approximately 1 year to achieve the desired results even when vitrectomy was successful. Mohammed and Pai [13] described that the macula was completely reattached after 1 month without SRF drainage. Although SRF drainage might contribute to early reattachment in our case, closure of the ODP would play an important role in rapid absorption of SRF.

In summary, covering the pit with an inverted ILM flap is a reliable method to intercept fluid from the vitreous. Immediate absorption of SRF may lead to early macular reattachment and subsequent improvement in visual acuity. This technique would be effective for retinal detachment with ODP, as occurred in the present case, and it might also be effective for ordinary ODP-M complicated with retinoschisis. Further cases are needed to evaluate this technique.

Statement of Ethics

The authors have no ethical conflicts to declare.

Disclosure Statement

The authors declare that there are no conflicts of interest regarding the publication of this case report.

References

- 1 Hirakata A, Inoue M, Hiraoka T, McCuen BW 2nd: Vitrectomy without laser treatment or gas tamponade for macular detachment associated with an optic disc pit. *Ophthalmology* 2012;119:810–818.
- 2 Gupta RR, Choudhry N: Spontaneous resolution of optic disc pit maculopathy after posterior vitreous detachment. *Can J Ophthalmol* 2016;51:e24–e27.
- 3 Rayat JS, Rudnisky CJ, Waire C, Huang P, Sheidow TG, Kherani A, Tennant MT: Long-term outcomes for optic disc pit maculopathy after vitrectomy. *Retina* 2015;35:2011–2017.
- 4 Kuhn F, Kover F, Szabo I, Mester V: Intracranial migration of silicon oil from an eye with optic pit. *Graefes Arch Clin Exp Ophthalmol* 2006;244:1360–1362.
- 5 Brown GC, Shields JA, Patty BE, Goldberg RE: Congenital pits of the optic nerve head. I. Experimental studies in collie dogs. *Arch Ophthalmol* 1979;97:1341–1344.
- 6 Dithmar S, Schuett F, Voelcker HE, Holz FG: Delayed sequential occurrence of perfluorodecalin and silicon oil in the subretinal space following retinal detachment surgery in the presence of an optic disc pit. *Arch Ophthalmol* 2004;122:409–411.

- 7 Katome T, Mutamura Y, Hotta F, Mino A, Naito T: Swept-source optical coherence tomography identifies connection between vitreous cavity and retrobulbar subarachnoid space in patient with optic disc pit. *Eye (Lond)* 2013;27:1325–1326.
- 8 Lincoff H, Schiff W, Krivoy D, Ritch R: Optic coherence tomography of optic disc pit maculopathy. *Am J Ophthalmol* 1996;122:264–266.
- 9 Hirakata A, Okada AA, Hida T: Long-term results of vitrectomy without laser treatment for macular detachment associated with an optic disc pit. *Ophthalmology* 2005;112:1430–1435.
- 10 Teke MY, Citirik M: 23 gauge vitrectomy, endolaser, and gas tamponade versus vitrectomy alone for serous macular detachment associated with optic disc pit. *Am J Ophthalmol* 2015;160:779–785e2.
- 11 Moon S, Kim J, Spaide R: Optic pit maculopathy without inner retinal schisis cavity. *Retina* 2006;26:113–116.
- 12 Travassos AS, Regadas I, Alfaiate M, Silva ED, Proenca R, Travassos A: Optic pit: novel surgical management of complicated cases. *Retina* 2013;33:1708–1714.
- 13 Mohammed OM, Pai A: Inverted autologous internal limiting membrane for management of optic disc pit with macular detachment. *Middle East Afr J Ophthalmol* 2013;20:357–359.
- 14 Coca MN, Tofigh S, Elkeeb A, Godley BF: Optic disc pit maculopathy recurring in the absence of vitreous gel. *JAMA Ophthalmology* 2014;132:1375–1376.

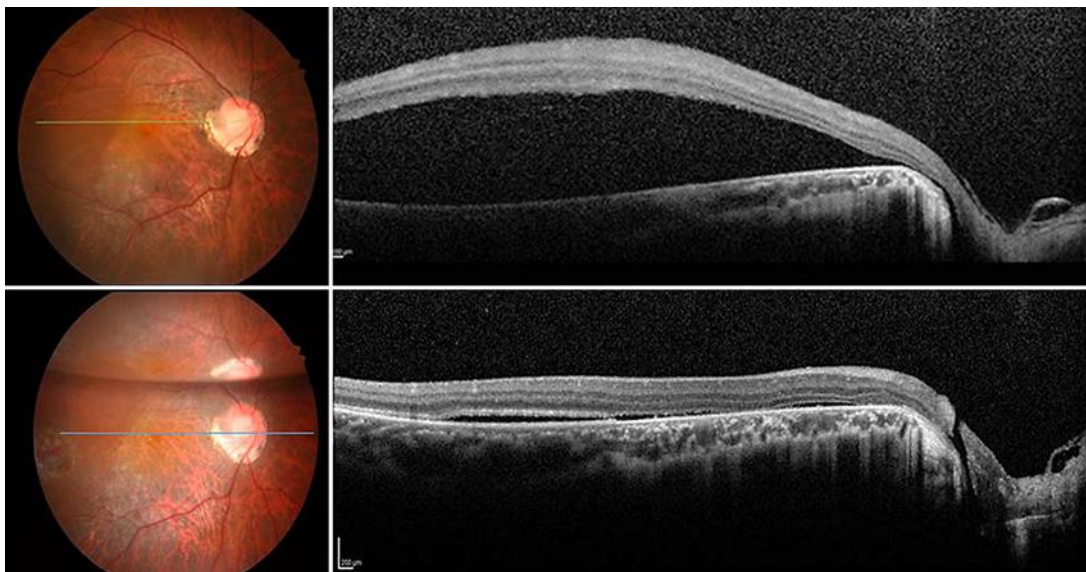


Fig. 1. Preoperative fundus photograph and OCT show macular detachment without retinoschisis connected to the ODP (top). After initial surgery, fundus photograph and OCT show the connection between the ODP and vitreous cavity (bottom). ODP, optic disc pit.

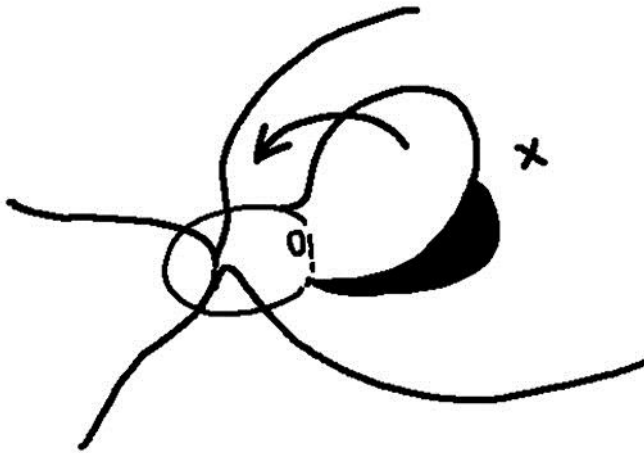


Fig. 2. Surgical procedure of the inverted ILM flap technique. The arrow indicates the direction of the inverted ILM flap. ILM, internal limiting membrane.

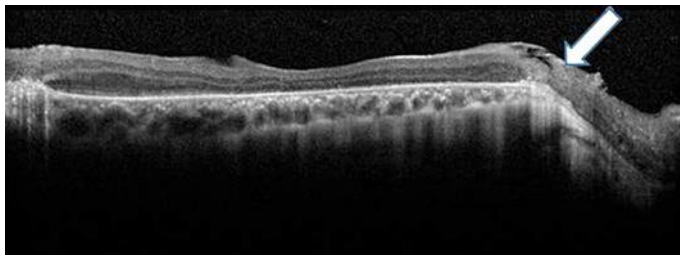


Fig. 3. OCT performed 3 months after the last surgery reveals reattached retina and the ODP overlaid with ILM flap (arrow). ODP, optic disc pit; ILM, internal limiting membrane.