

Images in medicine

Giant subdural empyema following ventriculo-peritoneal shunt in a child



Prastiya Indra Gunawan^{1&}, Wihasto Suryaningtyas²

¹Department Of Child Health, Airlangga University, College of Medicine, Dr Soetomo Hospital, Surabaya, Indonesia, ²Pediatric Neurosurgeon, Department Of Neurosurgery, Airlangga University, College of Medicine, Dr Soetomo Hospital, Surabaya, Indonesia

[&]Corresponding author: Prastiya Indra Gunawan, Department Of Child Health, Airlangga University, College of Medicine, Dr Soetomo Hospital, Surabaya, Indonesia

Key words: Giant subdural empyema, child, ventriculo-peritoneal shunt

Received: 31/01/2017 - Accepted: 09/02/2017 - Published: 02/03/2017

Pan African Medical Journal. 2017; 26:120 doi:10.11604/pamj.2017.26.120.11866

This article is available online at: <http://www.panafrican-med-journal.com/content/article/26/120/full/>

© Prastiya Indra Gunawan et al. The Pan African Medical Journal - ISSN 1937-8688. This is an Open Access article distributed under the terms of the Creative Commons Attribution License (<http://creativecommons.org/licenses/by/2.0>), which permits unrestricted use, distribution, and reproduction in any medium, provided the original work is properly cited.

Image in medicine

Subdural empyema is an intracranial focal collection of purulent material located between the dura mater and the arachnoid mater. It developed from varied sources, but the paranasal sinuses, the ears, and the mastoids processes were predominantly affected. Giant subdural empyema secondary to cerebrospinal fluid shunt placement has been extremely unusual. A 9-years-old girl presented with prolonged low-grade fever, vomiting, local wound infection in frontal area and general weakness. She was previously hydrocephalic with large head size since birth. A ventriculo-peritoneal shunt was already inserted for 7 years. Neurological examination showed the patient fully conscious and left hemiparesis. Routine hematological investigation revealed leukocytosis and high C-reactive protein (CRP). A contrast-enhanced CT scan showed an hypodense fluid collection with peripheral ring enhancement on the right of the midline supporting a giant subdural empyema. Emergency surgery was performed to drainage the pus. Pus culture resulted no growth of bacteria. Ceftriaxone and metronidazole were administered for 6 weeks. Follow-up CT Scan

showed reduction of mass effect. The patient was improved leaving neurological sequelae.

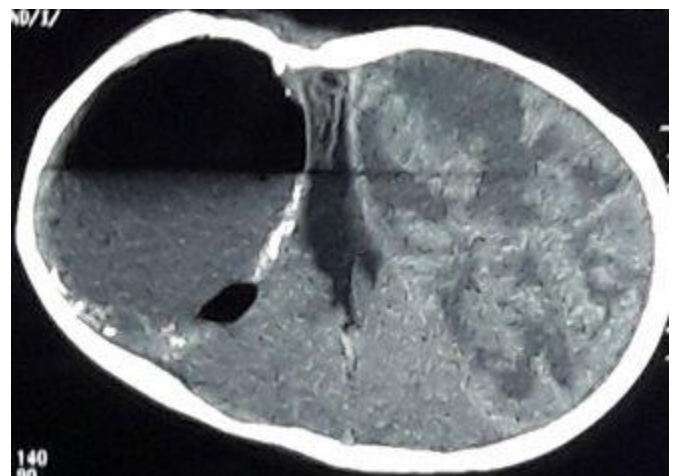


Figure 1: giant subdural empyema