



Phenotype-genotype correlation with Sanger sequencing identified retinol dehydrogenase 12 (*RDH12*) compound heterozygous variants in a Chinese family with Leber congenital amaurosis*

Yun LI^{§1}, Qing PAN^{§2}, Yang-shun GU^{†‡1}

(¹Department of Ophthalmology, the First Affiliated Hospital, College of Medicine, Zhejiang University, Hangzhou 310003, China)

(²Department of Ophthalmology, Zhejiang Provincial People's Hospital, Hangzhou 310014, China)

[†]E-mail: guyangshun_1@hotmail.com

Received Apr. 8, 2016; Revision accepted Aug. 26, 2016; Crosschecked Apr. 18, 2017

Abstract: Background: Leber congenital amaurosis (LCA) is a group of clinically and genetically heterogeneous retinal dystrophy. To date, 22 genes are known to be responsible for LCA, and some specific phenotypic features could provide significant prognostic information for a potential genetic etiology. This study is to identify gene variants responsible for LCA in a Chinese family using direct Sanger sequencing, with the help of phenotype-genotype correlations. Methods: A Chinese family with six members including two individuals affected with LCA was studied. All patients underwent a complete ophthalmic examination. Based on phenotype-genotype correlation, direct Sanger sequencing was performed to identify the candidate gene on all family members and normal controls. Targeted next-generation sequencing was used to exclude other known LCA genes. Results: By Sanger sequencing, we identified two novel missense variants in the retinol dehydrogenase 12 (*RDH12*) gene: a c.164C>A transversion predicting a p.T55K substitution, and a c.535C>G transversion predicting a p.H179D substitution. The two affected subjects carried both *RDH12* variants, while their parents and offspring carried only one of heterozygous variants, showing complete cosegregation of the variants. The compound heterozygous variants were not present in 600 normal controls. Besides, the *RDH12* variants were confirmed by targeted next-generation sequencing. Conclusions: The *RDH12* compound heterozygous variants might be the cause of the LCA family. Our study adds to the molecular spectrum of *RDH12*-related retinopathy and offers an effective example of the power of phenotype-genotype correlations in molecular diagnosis of LCA.

Key words: Leber congenital amaurosis; Phenotype-genotype correlation; *RDH12*; Compound heterozygosity
<http://dx.doi.org/10.1631/jzus.B1600156>

CLC number: R774

1 Introduction

Leber congenital amaurosis (LCA) is a group of severe hereditary retinal neurodegenerative diseases resulting in congenital blindness, and is characterized by the following clinical features: severe visual impairment, sensory nystagmus, amaurotic pupils, and

unrecordable electroretinographic response (den Hollander *et al.*, 2008). In LCA patients, the oscillations of the eyes or the absence of fixation is present as early as the age of 6 weeks, and electroretinogram (ERG) recordings are usually severely subnormal or extinguished (Chacon-Camacho and Zenteno, 2015). It is a rare congenital retinal dystrophy with an incidence between 1/30000 (Koenekoop, 2004) and 1/81000 (Stone, 2007), although it may be much more frequent in consanguineous populations or genetically isolated communities (Sherwin *et al.*, 2008).

LCA is a genetically heterogeneous disorder typically transmitted as autosomal recessive inheritance,

[‡] Corresponding author

[§] The two authors contributed equally to this work

* Project supported by the National Natural Science Foundation of China (No. 81300741)

ORCID: Yun LI, <http://orcid.org/0000-0001-7144-9102>

© Zhejiang University and Springer-Verlag Berlin Heidelberg 2017

although several families with autosomal dominant inheritance have been reported (den Hollander *et al.*, 2008). To date, 22 causative genes (Wang *et al.*, 2015; Xu *et al.*, 2016), namely *GUCY2D*, *CEP290*, *CRB1*, *CRX*, *AIPL1*, *RPE65*, *RPGRIP1*, *RDH12*, *LCA5*, *SPATA7*, *LRAT*, *IQCBI*, *KCNJ13*, *NMNAT1*, *RD3*, *TULP1*, *CABP4*, *CLUAP1*, *DTHD1*, *GDF6*, *IFT140*, and *PRPH2*, have been identified from the RetNet (<https://sph.uth.edu/retnet>). Mutations in these genes have been recognized as the cause of 70% of LCA cases (Yucel-Yilmaz *et al.*, 2014).

The phenotypic variability of LCA is striking, and clinical heterogeneity could be found in visual acuity, refractive errors, retinal appearance, photoversion, nyctalopia, and other associated features such as keratoconus and cataracts (den Hollander *et al.*, 2008). Characteristic phenotypic findings may narrow the differential diagnosis and lend clues to the underlying genotypic etiology. Some studies have established phenotype-genotype correlations for several LCA genes, and gene-specific phenotypic features are useful in guiding the clinician to a potential genetic etiology (Perrault *et al.*, 2004; Chung and Traboulsi, 2009; Traboulsi, 2010; Mackay *et al.*, 2011; Chacon-Camacho and Zenteno, 2015).

LCA 13, caused by retinol dehydrogenase 12 (*RDH12*) mutations, is characterized by progressive decline of visual function in early adulthood, absent rod and cone responses on the ERG, marked pigmentary retinopathy, and pronounced maculopathy (Schuster *et al.*, 2007). Posterior subcapsular cataracts or cortical cataracts could be present in LCA 13 patients with the absence of photophobia and hyperopia. In this work, we analyzed the ocular phenotype of LCA patients in a Chinese family, of which two showed typical clinical symptoms of LCA 13. Based on phenotype-genotype correlation, *RDH12* was chosen as the candidate gene. Successfully we identified novel *RDH12* compound heterozygous variants with Sanger sequencing in this LCA family, which was confirmed by targeted next-generation sequencing.

2 Materials and methods

2.1 Subjects

The research protocol was approved by the Institutional Review Board of the First Affiliated Hos-

pital of Zhejiang University (Hangzhou, China). Written informed consent was obtained from all the adults and the children's parents involved in the study, and all clinical investigations were conducted in accordance with the tenets of the Declaration of Helsinki. Control subjects were recruited from the First Affiliated Hospital of Zhejiang University.

2.2 Clinical evaluation

A third-generation Chinese family with LCA was studied. Complete ophthalmic examination of each family member was performed, including acquisition of a thorough ophthalmic history, best corrected visual acuity (BCVA), slit-lamp biomicroscopy, fundus photography (CR-2 Retinal Imaging, Canon, Japan), visual field tests (Humphrey Field Analyzer 3, Carl Zeiss Meditec, Germany), optical coherence tomography (OCT) (Spectralis OCT BluePeak, Heidelberg Engineering, Heidelberg, Germany), fluorescein fundus angiography (FFA) (Heidelberg Retina Angiograph 2 (HRA2), Heidelberg Engineering, Heidelberg, Germany), and ERG (RETI-PORT21, Roland Consult, Germany). All clinical tests were performed in the First Affiliated Hospital of Zhejiang University.

2.3 Analysis of the ocular phenotype of LCA patients

We analyzed the ocular phenotype of LCA patients, including a thorough ophthalmic history, visual acuity, refractive errors, retinal appearance, photoversion, nyctalopia, and cataracts. The identified gene-specific phenotypic features provided significant prognostic information for determining which gene may be responsible.

2.4 DNA extraction

Peripheral blood samples from each family member were collected in ethylene diamine tetraacetic acid (EDTA) tubes. Genomic DNA was extracted using a blood DNA extraction kit (QIAamp DNA Blood Midi Kit, Qiagen, Hilden, Germany) following the manufacturer's protocol. DNA samples were stored at -20°C until use.

2.5 Sanger sequencing and familial segregation analysis of *RDH12* variants

The proband of this family (II:1) was initially analyzed with all the seven coding exons and

intron-exon boundaries of *RDH12* by Sanger sequencing provided by Sangon Biotech (Shanghai, China). The identified *RDH12* variants were further confirmed bidirectionally and then checked in family members for segregation by direct Sanger sequencing. Novel variants were checked in 600 unrelated healthy Chinese controls with normal corrected visual acuity and no symptoms or family history of retinal degeneration. Primers flanking the variant were designed based on genomic sequences of Human Genome Database and synthesized by Sangon Biotech (Shanghai, China): exon 4 Fwd: 5'-GCTGGTGGAGTGTGTAGAACA-3', Rev: 5'-TTGGAGGCCACAGTGTAAGTT-3'; and exon 7 Fwd: 5'-AACACTGAA GTCCTCTTGGCTC-3', Rev: 5'-GGGCAAGCACTCTGTTTTTATTC-3'. All polymerase chain reactions (PCRs) were performed with a PCR amplification kit (TaKaRa) according to the manufacturer's instructions. PCR products were analyzed by 2% (0.02 g/ml) agarose gel electrophoresis and subsequently purified with a gel extraction kit (QIAEX II Gel Extraction Kit; Qiagen, Hilden, Germany). Direct automated sequencing was performed with the ABI BigDye Terminator V3.1 Cycle Sequencing Kit. All samples were analyzed on an ABI 3730XL Genetic Analyzer (Applied Biosystems). Wild-type and mutated *RDH12* sequences were compared manually.

2.6 Target gene sequence capture and next generation sequencing analysis

Targeted next-generation sequencing was performed on the two affected siblings by BGI Health (Shenzhen, China) with a capture panel that enriches the exonic DNA of 146 known genes associated with genetic retinal disease including 22 known LCA-causative genes. Genomic DNA was sheared into fragments of 200–300 bp and added an A-residue, and then amplified by ligation-mediated PCR. Captured libraries were quantified and sequenced on Illumina HiSeq 2000 platform as 90 bp paired-end reads. Sequence reads were aligned to the Human Genome Reference version hg by Burrows Wheeler Aligner (Li and Durbin, 2009). The Genome Analysis Toolkit (GATK) was used for base quality score recalibration and local realignment (McKenna *et al.*, 2010). The SAMtools (<http://samtools.sourceforge.net>) was used for single nucleotide polymorphism (SNP) calling (Li,

2011), while the Pindel (<http://gmt.genome.wustl.edu/packages/pindel>) was used for Indel calling (Ye *et al.*, 2009). All changes were filtered against 1000 Genomes database, dbSNP, HapMap database, ESP6500, and ExAC.

2.7 Analysis of novel variants

Novel variants were analyzed in silico using the SIFT (Sorting Intolerant from Tolerant, <http://sift.jcvi.org>) (Ng and Henikoff, 2003) and PolyPhen-2 (Polymorphism Phenotyping v2, <http://genetics.bwh.harvard.edu/pph2>) (Adzhubei *et al.*, 2010) programs to predict their possible impact on the structure and function of the protein. Detected variants were also checked in the 1000 Genomes database and Exome Variant Server (EVS) for excluding them as common polymorphisms (Hong *et al.*, 2014; Lin *et al.*, 2016).

3 Results

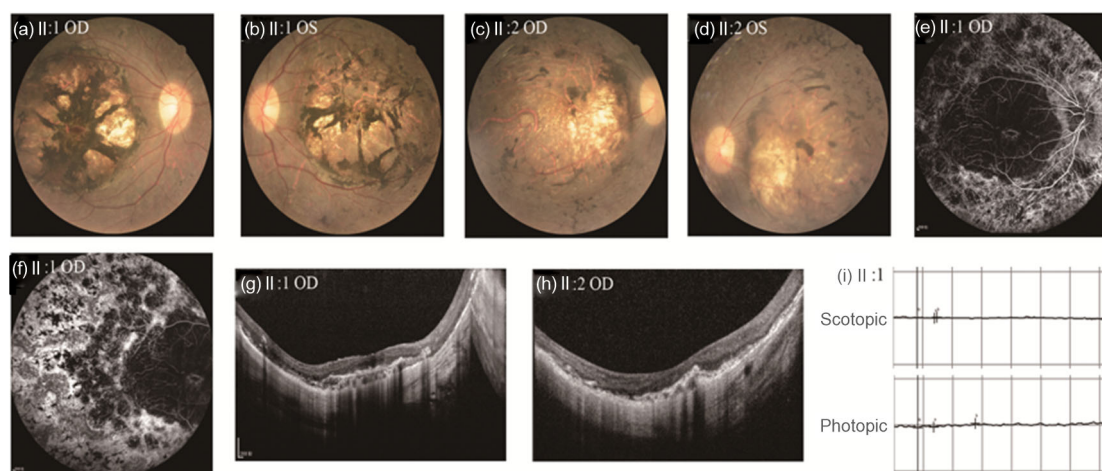
3.1 Clinical assessment of the family

A three-generation family from Zhejiang Province of China was recruited (Table 1). Since the parents and offspring of two affected subjects had no apparent LCA symptoms, the disease exhibited autosomal recessive inheritance pattern in this family. The affected subjects exhibited similar clinical features (Fig. 1). Patients shared poor, yet useful visual function in early childhood followed by a progressive and severe decline before the second decade. They had nyctalopia, visual field constriction, sensory nystagmus, but photophobia and hypermetropia. Anterior segment examination found delayed pupillary light reflex and mild posterior subcapsular or a spot of peripheral cortical lens opacity. Fundus examination showed pronounced maculopathy, peripheral hyperpigmentation, and retinal vascular attenuation. OCT imaging revealed a thick retina with loss of the foveal laminar architecture. ERG showed undetectable responses under scotopic and photopic conditions, indicating severe generalized loss of rod and cone photoreceptor function. All these clinical characteristics were consistent with LCA 13, as reported earlier (Schuster *et al.*, 2007; Mackay *et al.*, 2011). Based on phenotype-genotype correlation, *RDH12* was chosen as the first candidate gene.

Table 1 Clinical characteristics of family members

Family member	Age (year)/sex	Onset age (year)	BCVA (OD/OS)	Nystagmus and nyctalopia	Fundus appearance	ERG
I:1	50/M		1.00/1.00	–	Normal	Normal
I:2	46/F		1.00/1.00	–	Normal	Normal
II:1	24/M	2	0.30/0.06	+	PM, PH, RVA	Extinguished
II:2	25/F	2	0.04/0.12	+	PM, PH, RVA	Extinguished
III:1	1/M		OPM	–	Normal	Normal

BCVA: best corrected visual acuity; OD: oculus dexter; OS: oculus sinister; OPM: ocular pursuit movements; PM: pronounced maculopathy; PH: peripheral hyperpigmentation; RVA: retinal vascular attenuation; ERG: electroretinogram

**Fig. 1 Ocular phenotypes of affected patients**

(a–f) Funduscopy features include pronounced maculopathy, peripheral hyperpigmentation, and retinal vascular attenuation. (g, h) Optical coherence tomography (OCT) demonstrates thick retina with loss of the foveal laminar architecture. (i) Electroretinogram (ERG) shows undetectable rod and cone responses. II:1 and II:2: family members; OD: oculus dexter; OS: oculus sinister

3.2 Sanger sequencing results and verification of familial segregation of *RDH12* variants

By Sanger sequencing of the proband (II:1), we identified novel *RDH12* compound heterozygous variants (Fig. 2), which were further confirmed on patient II:2. The first *RDH12* variant was a c.164C>A transversion at exon 4, predicting a novel p.T55K substitution; the second variant was a c.535C>G transversion at exon 7, which predicts a novel p.H179D substitution. Other family members were then screened for the two *RDH12* variants. We found that the proband's father (I:1) was unaffected heterozygous carrier of c.535C>G and his mother (I:2) as well as his sister's offspring (III:1) were unaffected heterozygous carriers of c.164C>A, showing complete cosegregation of the variants with LCA (Fig. 3). Neither of the *RDH12* variants was detected in family member II:3 or in the 600 normal controls by direct Sanger sequencing.

3.3 Targeted next-generation sequencing

About 218 SNPs and Indels were identified by targeted next-generation sequencing. Since LCA is a rare disease, all common variants were removed by filtering against the following variation databases: 1000 Genomes database, dbSNP, HapMap database, ESP6500, and ExAC. As a result, five rare variants that may result in protein coding change were identified as candidate variants (Table 2). Given that the disease exhibited autosomal recessive inheritance pattern in this family, a homozygous variant or compound heterozygous variants should be shared by both affected siblings, and the heterozygous variant should be verified on their unaffected parents respectively. Finally, only the compound heterozygous variants c.164C>A and c.535C>G in *RDH12* were identified. The result of targeted next-generation sequencing was consistent with that of candidate gene sequencing indicated by phenotype-genotype correlation.

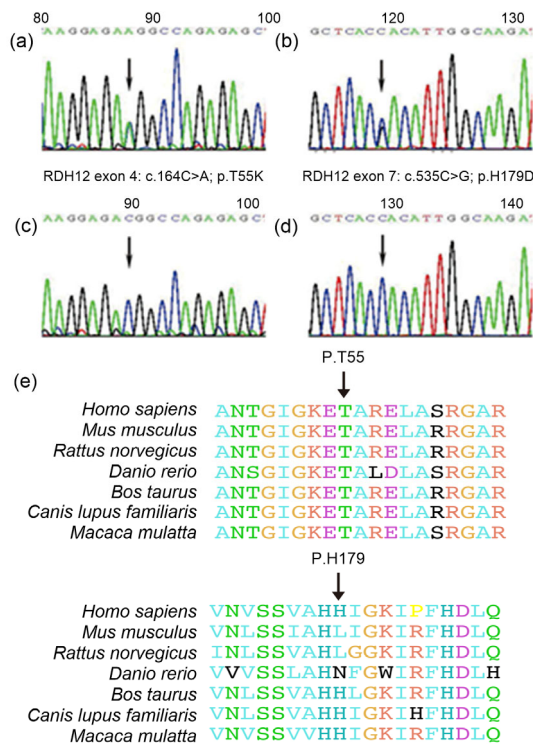


Fig. 2 RDH12 mutational analysis by Sanger sequencing
 (a) A novel heterozygous c.164C>A transversion (arrow) was demonstrated in *RDH12* exon 4 in DNA from two LCA patients (II:1, II:2) and two unaffected family members (I:2, III:1). (b) A novel heterozygous c.535C>G transition (arrow) was identified in exon 7 in DNA from two LCA patients (II:1, II:2) and their father (I:1). (c, d) Normal *RDH12* sequences are shown for comparison. (e) Protein sequence alignment of *RDH12* from different species

3.4 Novel *RDH12* variant analysis

The novel p.T55K *RDH12* variant was predicted to be probably damaging by both SIFT and PolyPhen-2 programs with scores of 0 and 1, respectively. The novel p.H179D *RDH12* variant was predicted to be benign by both SIFT and PolyPhen-2 programs with scores of 0.36 and 0.188, respectively. Both novel variants were not annotated at 1000 Genomes or EVS databases.

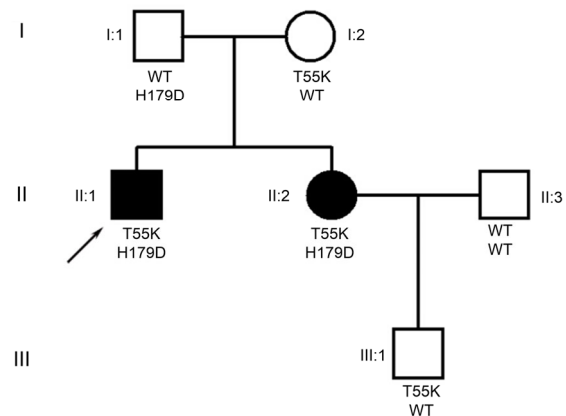


Fig. 3 Pedigree of the LCA family showing the segregation of the p.T55K and p.H179D *RDH12* mutations

Solid symbols designate affected individuals. Open symbols indicate unaffected individuals. Square indicates male, and circle indicates female. Arrow indicates the proband. WT indicates wild-type sequence

4 Discussion

LCA is a group of congenital retinal dystrophy with clinical and genetic heterogeneity. The number of identified LCA-associated genes has been increasing, and now 22 genes are known to harbor mutations responsible for LCA. These genes encode proteins involved in a wide variety of retinal functions such as phototransduction, photoreceptor morphogenesis, retinoid cycling, ciliary transport, and guanine synthesis (den Hollander *et al.*, 2006; 2008; Estrada-Cuzcano *et al.*, 2011; Sergouniotis *et al.*, 2011; Perrault *et al.*, 2012; Kolandaivelu and Ramamurthy, 2014; Yucel-Yilmaz *et al.*, 2014).

Although phenotypic variability could be found in the complete ophthalmic examinations of LCA patients, some specific clinical features could provide significant prognostic information for determining which gene may be responsible and thereby significantly reducing the involved cost.

Table 2 Candidate variants identified through databases

Chromosome	Gene	NM	Variants	Position	Het/Hom	II:1	II:2
Chr14	<i>RDH12</i>	NM_152443	p.T55K	EX4	Het	+	+
Chr14	<i>RDH12</i>	NM_152443	p.H179D	EX7	Het	+	+
Chr3	<i>CLRN1</i>	NM_174878	p.G136E	EX2	Het	+	+
Chr3	<i>MITF</i>	NM_198159	p.D491Y	EX10	Het	+	+
Chr4	<i>PROM1</i>	NM_001145848	p.E728K	EX20	Het	-	+

Het: heterozygous mutation; Hom: homozygous mutation; EX: exon; II:1 and II:2: family members

LCA 13, the characteristic phenotype associated with *RDH12* mutations, exhibits severe and homogeneous clinical features characterized by onset of symptoms in early childhood and progression to legal blindness in early adulthood due to significant loss of the function of both rods and cones (Janecke et al., 2004), with fundi showing marked pigmentary retinopathy with bone spicules in the peripheral retina and pronounced maculopathy (Jacobson et al., 2007; Valverde et al., 2009; Sodi et al., 2010; Kuniyoshi et al., 2014). Nyctalopia is the predominant symptom of LCA 13. Most LCA 13 patients have no photophobia, hyperopia, or keratoconus, while mild posterior subcapsular cataract can occur. OCT shows thick retinas with loss of the foveal laminar architecture (Jacobson et al., 2007). ERG is extinguished under scotopic and photopic conditions. In our study, the clinical examinations of two affected subjects were consistent with the characteristics mentioned above, showing typical clinical symptoms of LCA 13.

For the ophthalmologist, the clinical presentation of LCA represents a complex dilemma, as the clinical overlap among different genetic phenotypes could be striking and confusing. Similar phenotypic trends could be observed in other LCA genes, such as *RPE65*, *GUCY2D*, *AIPL1*, *CRB1*, and *CEP290*. The following clinical differences could be useful to separate these overlapping phenotypes from LCA 13. Patients with *RPE65* mutations show preservation of visual acuity in early life followed by severe yet progressive decline in adulthood, which is similar to patients with *RDH12* mutations. However, transient visual function improvement in patients with *RPE65* mutations could last through teenage years and visual acuity deteriorates in their third to fifth decade (Trauboulsi, 2010; Chacon-Camacho and Zenteno, 2015), while visual function in patients with *RDH12* mutations could progress to legal blindness in early adulthood (18–25 years) (Janecke et al., 2004). OCT scan shows that the retina is significantly thinner in patients with *RPE65* mutations (Pasadhika et al., 2010). Patients with *GUCY2D* mutations have a severe, congenital stationary visual function with a relatively preserved retinal appearance. Meanwhile, cataract and nyctalopia usually do not occur (Dharmaraj et al., 2000; Milam et al., 2003; Jacobson et al., 2013). The phenotype of LCA patients with *AIPL1* mutations is characterized by nystagmus, nyctalopia,

maculopathy, and pigmentary retinopathy from young ages (Tan et al., 2012). In addition, there is a high frequency of keratoconus, hyperopia, and photophobia (Testa et al., 2011). In patients with *CRB1* mutations, the retina exhibits nummular pigment clumps at early ages, and most patients have high hypermetropia and keratoconus (Bujakowska et al., 2012). Patients carrying *CEP290* mutations exhibit a severe yet progressive visual function. Moreover, photophobia, hyperopia, enophthalmos, and keratoconus are frequently observed (Yzer et al., 2012), which are usually not present in patients with *RDH12* mutations.

In our study, with great awareness of potential correlations with clinical characteristics and specific genotypes, we successfully identified novel *RDH12* compound heterozygous variants in LCA patients by Sanger sequencing: c.164C>A (p.T55K) at exon 4 and c.535C>G (p.H179D) at exon 7. Their unaffected parents and offspring carried only one of heterozygous variants, showing complete cosegregation of the variants. The variant p.T55K was predicted to be probably damaging to protein function, and the variant p.H179D was predicted to be benign by both SIFT and PolyPhen-2. The two heterozygous variants were absent in 600 normal controls and public databases such as 1000 Genomes or EVS, excluding them as common polymorphisms. These findings indicated that the *RDH12* compound heterozygous variants confirmed by targeted next-generation sequencing might be responsible for LCA in the two affected patients.

Mutations in *RDH12* were first described as a cause of LCA in 2004 (Janecke et al., 2004; Perrault et al., 2004). To date, over 70 different *RDH12* mutations have been reported predominantly in LCA patients (Chacon-Camacho and Zenteno, 2015; Gong et al., 2015). *RDH12* is located at human chromosome 14q24.1 (Kiser et al., 2012). The protein product, a member of the short-chain dehydrogenase/reductase (SDR) family, is predominantly localized to the photoreceptor inner segments and the outer nuclear layer (Haeseleer et al., 2002; Kurth et al., 2007), playing a crucial role in the interconversion of vitamin A (all-*trans* retinal) to 11-*cis* retinal (Schuster et al., 2007; Chrispell et al., 2009). Deletion of the *RDH12* in mice increases the susceptibility to light-induced retinal apoptosis in both cone and rod

photoreceptors (Maeda *et al.*, 2006). Another study suggests that *RDH12* may be the key component in clearance of free all-*trans* retinal, thereby preventing accumulation of *N*-retinylidene-*N*-retinylethanolamine (A2E), a toxic substance responsible for the retinal degeneration (Maeda *et al.*, 2007). To date, the mechanism of retinal degeneration associated with mutations in *RDH12* is unclear, and the specific role of *RDH12* in the visual cycle remains to be studied further.

In conclusion, we identified novel compound heterozygous variants c.164C>A (p.T55K) and c.535C>G (p.H179D) in *RDH12* as a possible cause of LCA in a Chinese family by Sanger sequencing. Our study demonstrates that phenotype-genotype correlations do exist and provide significant prognostic information of causative genes, guiding clinicians to molecular diagnosis of LCA.

Compliance with ethics guidelines

Yun LI, Qing PAN, and Yang-shun GU declare that they have no conflict of interest.

All procedures followed were in accordance with the ethical standards of the responsible committee on human experimentation (institutional and national) and with the Helsinki Declaration of 1975, as revised in 2008 (5). Informed consent was obtained from all patients for being included in the study.

References

- Adzhubei, I.A., Schmidt, S., Peshkin, L., *et al.*, 2010. A method and server for predicting damaging missense mutations. *Nat. Methods*, **7**(4):248-249.
<http://dx.doi.org/10.1038/nmeth0410-248>
- Bujakowska, K., Audo, I., Mohand-Said, S., *et al.*, 2012. CRB1 mutations in inherited retinal dystrophies. *Hum. Mutat.*, **33**(2):306-315.
<http://dx.doi.org/10.1002/humu.21653>
- Chacon-Camacho, O.F., Zenteno, J.C., 2015. Review and update on the molecular basis of Leber congenital amaurosis. *World J. Clin. Cases*, **3**(2):112-124.
<http://dx.doi.org/10.12998/wjcc.v3.i2.112>
- Chrispell, J.D., Feathers, K.L., Kane, M.A., *et al.*, 2009. Rdh12 activity and effects on retinoid processing in the murine retina. *J. Biol. Chem.*, **284**(32):21468-21477.
<http://dx.doi.org/10.1074/jbc.M109.020966>
- Chung, D.C., Traboulsi, E.I., 2009. Leber congenital amaurosis: clinical correlations with genotypes, gene therapy trials update, and future directions. *J. AAPOS*, **13**(6):587-592.
<http://dx.doi.org/10.1016/j.jaapos.2009.10.004>
- den Hollander, A.I., Koenekoop, R.K., Yzer, S., *et al.*, 2006. Mutations in the *CEP290* (*NPHP6*) gene are a frequent cause of Leber congenital amaurosis. *Am. J. Hum. Genet.*, **79**(3):556-561.
<http://dx.doi.org/10.1086/507318>
- den Hollander, A.I., Roepman, R., Koenekoop, R.K., *et al.*, 2008. Leber congenital amaurosis: genes, proteins and disease mechanisms. *Prog. Retin. Eye Res.*, **27**(4):391-419.
<http://dx.doi.org/10.1016/j.preteyeres.2008.05.003>
- Dharmaraj, S.R., Silva, E.R., Pina, A.L., *et al.*, 2000. Mutational analysis and clinical correlation in Leber congenital amaurosis. *Ophthalmic Genet.*, **21**(3):135-150.
[http://dx.doi.org/10.1076/1381-6810\(200009\)21:3;1-z;ft135](http://dx.doi.org/10.1076/1381-6810(200009)21:3;1-z;ft135)
- Estrada-Cuzcano, A., Koenekoop, R.K., Coppiteters, F., *et al.*, 2011. *IQCB1* mutations in patients with Leber congenital amaurosis. *Invest. Ophthalmol. Vis. Sci.*, **52**(2):834-839.
<http://dx.doi.org/10.1167/iovs.10-5221>
- Gong, B., Wei, B., Huang, L., *et al.*, 2015. Exome sequencing identified a recessive *RDH12* mutation in a family with severe early-onset retinitis pigmentosa. *J. Ophthalmol.*, **2015**:942740.
<http://dx.doi.org/10.1155/2015/942740>
- Haeseleer, F., Jang, G.F., Imanishi, Y., *et al.*, 2002. Dual-substrate specificity short chain retinol dehydrogenases from the vertebrate retina. *J. Biol. Chem.*, **277**(47):45537-45546.
<http://dx.doi.org/10.1074/jbc.M208882200>
- Hong, N., Chen, Y., Xie, C., *et al.*, 2014. Identification of a novel mutation in a Chinese family with Nance-Horan syndrome by whole exome sequencing. *J. Zhejiang Univ.-Sci. B (Biomed. & Biotechnol.)*, **15**(8):727-734.
<http://dx.doi.org/10.1631/jzus.B1300321>
- Jacobson, S.G., Cideciyan, A.V., Aleman, T.S., *et al.*, 2007. *RDH12* and *RPE65*, visual cycle genes causing Leber congenital amaurosis, differ in disease expression. *Invest. Ophthalmol. Vis. Sci.*, **48**(1):332-338.
<http://dx.doi.org/10.1167/iovs.06-0599>
- Jacobson, S.G., Cideciyan, A.V., Peshenko, I.V., *et al.*, 2013. Determining consequences of retinal membrane guanylyl cyclase (RetGC1) deficiency in human Leber congenital amaurosis en route to therapy: residual cone-photoreceptor vision correlates with biochemical properties of the mutants. *Hum. Mol. Genet.*, **22**(1):168-183.
<http://dx.doi.org/10.1093/hmg/ddt421>
- Janecke, A.R., Thompson, D.A., Utermann, G., *et al.*, 2004. Mutations in *RDH12* encoding a photoreceptor cell retinol dehydrogenase cause childhood-onset severe retinal dystrophy. *Nat. Genet.*, **36**(8):850-854.
<http://dx.doi.org/10.1038/ng1394>
- Kiser, P.D., Golczak, M., Maeda, A., *et al.*, 2012. Key enzymes of the retinoid (visual) cycle in vertebrate retina. *Biochim. Biophys. Acta*, **1821**(1):137-151.
<http://dx.doi.org/10.1016/j.bbali.2011.03.005>
- Koenekoop, R.K., 2004. An overview of Leber congenital amaurosis: a model to understand human retinal development. *Surv. Ophthalmol.*, **49**(4):379-398.
<http://dx.doi.org/10.1016/j.survophthal.2004.04.003>

- Kolandaivelu, S., Ramamurthy, V., 2014. AIPL1 protein and its indispensable role in cone photoreceptor function and survival. *Adv. Exp. Med. Biol.*, **801**:43-48.
http://dx.doi.org/10.1007/978-1-4614-3209-8_6
- Kuniyoshi, K., Sakuramoto, H., Yoshitake, K., et al., 2014. Longitudinal clinical course of three Japanese patients with Leber congenital amaurosis/early-onset retinal dystrophy with *RDH12* mutation. *Doc. Ophthalmol.*, **128**(3): 219-228.
<http://dx.doi.org/10.1007/s10633-014-9436-z>
- Kurth, I., Thompson, D.A., Ruther, K., et al., 2007. Targeted disruption of the murine retinal dehydrogenase gene *Rdh12* does not limit visual cycle function. *Mol. Cell. Biol.*, **27**(4):1370-1379.
<http://dx.doi.org/10.1128/MCB.01486-06>
- Li, H., 2011. A statistical framework for SNP calling, mutation discovery, association mapping and population genetical parameter estimation from sequencing data. *Bioinformatics*, **27**(21):2987-2993.
<http://dx.doi.org/10.1093/bioinformatics/btr509>
- Li, H., Durbin, R., 2009. Fast and accurate short read alignment with Burrows-Wheeler transform. *Bioinformatics*, **25**(14):1754-1760.
<http://dx.doi.org/10.1093/bioinformatics/btp324>
- Lin, F., Huang, Z., Lu, N., et al., 2014. Controversial opinion: evaluation of *EGR1* and *LAMA2* loci for high myopia in Chinese populations. *J. Zhejiang Univ. Sci.-B (Biomed. & Biotechnol.)*, **17**(3):225-235.
<http://dx.doi.org/10.1631/jzus.B1500233>
- Mackay, D.S., Dev, B.A., Moradi, P., et al., 2011. *RDH12* retinopathy: novel mutations and phenotypic description. *Mol. Vis.*, **17**:2706-2716.
- Maeda, A., Maeda, T., Imanishi, Y., et al., 2006. Retinol dehydrogenase (*RDH12*) protects photoreceptors from light-induced degeneration in mice. *J. Biol. Chem.*, **281**(49):37697-37704.
<http://dx.doi.org/10.1074/jbc.M608375200>
- Maeda, A., Maeda, T., Sun, W., et al., 2007. Redundant and unique roles of retinol dehydrogenases in the mouse retina. *Proc. Natl. Acad. Sci. USA*, **104**(49):19565-19570.
<http://dx.doi.org/10.1073/pnas.0707477104>
- McKenna, A., Hanna, M., Banks, E., et al., 2010. The Genome Analysis Toolkit: a MapReduce framework for analyzing next-generation DNA sequencing data. *Genome Res.*, **20**(9):1297-1303.
<http://dx.doi.org/10.1101/gr.107524.110>
- Milam, A.H., Barakat, M.R., Gupta, N., et al., 2003. Clinicopathologic effects of mutant *GUCY2D* in Leber congenital amaurosis. *Ophthalmology*, **110**(3):549-558.
[http://dx.doi.org/10.1016/S0161-6420\(02\)01757-8](http://dx.doi.org/10.1016/S0161-6420(02)01757-8)
- Ng, P.C., Henikoff, S., 2003. SIFT: predicting amino acid changes that affect protein function. *Nucleic Acids Res.*, **31**(13):3812-3814.
- Pasadhika, S., Fishman, G.A., Stone, E.M., et al., 2010. Differential macular morphology in patients with RPE65-, CEP290-, *GUCY2D*-, and *AIPL1*-related Leber congenital amaurosis. *Invest. Ophthalmol. Vis. Sci.*, **51**(5):2608-2614.
<http://dx.doi.org/10.1167/iovs.09-3734>
- Perrault, I., Hanein, S., Gerber, S., et al., 2004. Retinal dehydrogenase 12 (*RDH12*) mutations in Leber congenital amaurosis. *Am. J. Hum. Genet.*, **75**(4):639-646.
<http://dx.doi.org/10.1086/424889>
- Perrault, I., Hanein, S., Zanlonghi, X., et al., 2012. Mutations in *NMNAT1* cause Leber congenital amaurosis with early-onset severe macular and optic atrophy. *Nat. Genet.*, **44**(9):975-977.
<http://dx.doi.org/10.1038/ng.2357>
- Schuster, A., Janecke, A.R., Wilke, R., et al., 2007. The phenotype of early-onset retinal degeneration in persons with *RDH12* mutations. *Invest. Ophthalmol. Vis. Sci.*, **48**(4): 1824-1831.
<http://dx.doi.org/10.1167/iovs.06-0628>
- Sergouniotis, P.I., Davidson, A.E., Mackay, D.S., et al., 2011. Recessive mutations in *KCNJ13*, encoding an inwardly rectifying potassium channel subunit, cause Leber congenital amaurosis. *Am. J. Hum. Genet.*, **89**(1):183-190.
<http://dx.doi.org/10.1016/j.ajhg.2011.06.002>
- Sherwin, J.C., Hewitt, A.W., Ruddle, J.B., et al., 2008. Genetic isolates in ophthalmic diseases. *Ophthalmic Genet.*, **29**(4): 149-161.
<http://dx.doi.org/10.1080/13816810802334341>
- Sodi, A., Caputo, R., Passerini, I., et al., 2010. Novel *RDH12* sequence variations in Leber congenital amaurosis. *J. AAPOS*, **14**(4):349-351.
<http://dx.doi.org/10.1016/j.jaapos.2010.04.010>
- Stone, E.M., 2007. Leber congenital amaurosis—a model for efficient genetic testing of heterogeneous disorders: LXIV Edward Jackson Memorial Lecture. *Am. J. Ophthalmol.*, **144**(6):791-811.
<http://dx.doi.org/10.1016/j.ajo.2007.08.022>
- Tan, M.H., Mackay, D.S., Cowing, J., et al., 2012. Leber congenital amaurosis associated with *AIPL1*: challenges in ascribing disease causation, clinical findings, and implications for gene therapy. *PLoS ONE*, **7**(3):e32330.
<http://dx.doi.org/10.1371/journal.pone.0032330>
- Testa, F., Surace, E.M., Rossi, S., et al., 2011. Evaluation of Italian patients with Leber congenital amaurosis due to *AIPL1* mutations highlights the potential applicability of gene therapy. *Invest. Ophthalmol. Vis. Sci.*, **52**(8):5618-5624.
<http://dx.doi.org/10.1167/iovs.10-6543>
- Traboulsi, E.I., 2010. The Marshall M. Parks memorial lecture: making sense of early-onset childhood retinal dystrophies—the clinical phenotype of Leber congenital amaurosis. *Br. J. Ophthalmol.*, **94**(10):1281-1287.
<http://dx.doi.org/10.1136/bjo.2009.165654>
- Valverde, D., Pereiro, I., Vallespin, E., et al., 2009. Complexity of phenotype-genotype correlations in Spanish patients with *RDH12* mutations. *Invest. Ophthalmol. Vis. Sci.*, **50**(3):1065-1068.
<http://dx.doi.org/10.1167/iovs.08-2083>

- Wang, H., Wang, X., Zou, X., et al., 2015. Comprehensive molecular diagnosis of a large Chinese Leber congenital amaurosis cohort. *Invest. Ophthalmol. Vis. Sci.*, **56**(6): 3642-3655.
<http://dx.doi.org/10.1167/iovs.14-15972>
- Xu, Y., Xiao, X., Li, S., et al., 2016. Molecular genetics of Leber congenital amaurosis in Chinese: new data from 66 probands and mutation overview of 159 probands. *Exp. Eye Res.*, **149**:93-99.
<http://dx.doi.org/10.1016/j.exer.2016.06.019>
- Ye, K., Schulz, M.H., Long, Q., et al., 2009. Pindel: a pattern growth approach to detect break points of large deletions and medium sized insertions from paired-end short reads. *Bioinformatics*, **25**(21):2865-2871.
<http://dx.doi.org/10.1093/bioinformatics/btp394>
- Yucel-Yilmaz, D., Tarlan, B., Kiratli, H., et al., 2014. Genome-wide homozygosity mapping in families with Leber congenital amaurosis identifies mutations in *AIP1* and *RDH12* genes. *DNA Cell Biol.*, **33**(12):876-883.
<http://dx.doi.org/10.1089/dna.2014.2554>
- Yzer, S., Hollander, A.I., Lopez, I., et al., 2012. Ocular and extra-ocular features of patients with Leber congenital amaurosis and mutations in *CEP290*. *Mol. Vis.*, **18**:412-425.

中文概要

- 题目:** 临床表型-基因型关联发现Leber先天性黑矇(LCA)家系新的*RDH12*基因复合杂合突变
- 目的:** 临床表型-基因型关联分析筛查Leber先天性黑矇(LCA)家系候选基因, 确定其分子遗传病因。
- 创新点:** 成功应用临床表型-基因型关联分析鉴定LCA家系致病基因, 并发现新的*RDH12*基因复合杂合突变。
- 方法:** 收集一个中国常染色体隐性遗传三代LCA家系, 详细分析该家系眼部表型特征(图1和表1), 经临床表型-基因型关联分析确定*RDH12*为候选基因。Sanger测序发现新的*RDH12*基因复合杂合突变(图2), 目标序列捕获高通量测序技术排除其他已知LCA相关基因(表2)。该家系成员基因型显示完整的共分离(图3), 同时在600例普通人群中未发现该突变。
- 结论:** *RDH12*基因复合杂合突变可能为该LCA家系的致病基因, 临床表型-基因型关联分析在LCA分子遗传学诊断中有重要价值。
- 关键词:** Leber先天性黑矇; 临床表型-基因型关联; *RDH12*; 复合杂合突变