



# Platelet-rich plasma (PRP) for knee disorders

Mohammad Shahid  
Rik Kundra

- Platelet-rich plasma (PRP) is an autologous blood product with platelet concentrations above baseline values. The process involves the extraction of blood from the patient which is then centrifuged to obtain a concentrated suspension of platelets by plasmapheresis. It then undergoes a two-stage centrifugation process to separate the solid and liquid components of the anticoagulated blood. PRP owes its therapeutic use to the growth factors released by the platelets which are claimed to possess multiple regenerative properties.
- In the knee, PRP has been used in patients with articular cartilage pathology, ligamentous and meniscal injuries.
- There is a growing body of evidence to support its use in selected indications and this review looks at the most recent evidence. We also look at the current UK National Institute of Health & Clinical Excellence (NICE) guidelines with respect to osteoarthritis and the use of PRP in the knee.

**Keywords:** platelet-rich plasma (PRP); osteoarthritis; meniscal injury; ligamentous injury; articular cartilage

Cite this article: *EFORT Open Rev* 2017;2:28–34.

DOI: 10.1302/2058-5241.2.160004.

## Introduction

Platelet-rich plasma (PRP) has been used since the 1950s to manage maxillofacial and dermatological conditions.<sup>1,2</sup> The use of biological agents including PRP and mesenchymal stem cells (MSCs) in orthopaedics has increased exponentially over the last few years due to its autologous nature, supposed effectiveness and lack of side-effects.<sup>3,4</sup>

This review article will look at the use of PRP for treatment of knee disorders.

PRP is an autologous blood product with platelet concentrations above baseline values.<sup>5</sup> The preparation process involves the extraction of blood from the patient which is then centrifuged to obtain a concentrated suspension of platelets by plasmapheresis. It then undergoes a two-stage centrifugation process to separate the solid

and liquid components of the anticoagulated blood.<sup>6</sup> The initial phase separates the plasma and platelets from the erythrocytes and leucocytes. The second stage uses a hard spin to concentrate the platelets further into platelet-rich and platelet-poor plasma components. The final PRP product is then injected into the knee joint space (Fig. 1). There is also debate on the potential benefits of platelet-poor plasma on healing and some formulations do not incorporate this step.<sup>7</sup>

As well as platelets, PRP contains white blood cells and some proteins.

The neutrophils and monocytes may instigate a localised inflammatory effect which some authors claim can facilitate tissue healing.<sup>8</sup>

PRP owes its therapeutic use to the limited evidence that growth factors released by the platelets possess multiple regenerative properties.<sup>9</sup> Tissue repair is a complex process comprising chemotaxis, angiogenesis, cell proliferation and matrix formation.<sup>10</sup> Platelets are involved in all of these functions by the release of growth factors.

High concentrations of proteins such as platelet-derived growth factor (PDGF), vascular endothelial growth factor (VEGF), endothelial cell growth factor and fibroblast growth factor have led to suggestions that PRP may be useful in conditions requiring tissue healing.<sup>9,10</sup> Conversely, the other protein in PRP, transforming growth factor (TG)F- $\beta$ 1, has an inhibitory effect and can lead to non-predictable results.<sup>11</sup>

## Preparation and delivery techniques

There are essentially three different methods for PRP production.<sup>12</sup>

1. Blood filtration and plateletpheresis. These result in high concentrations of human platelets and PDGFs and low numbers of contaminating leucocytes;
2. Single-spinning centrifugation which results in platelets up to three times that of baseline level;
3. Double-spinning centrifugation which results in platelets up to eight times the baseline level with a high leucocyte content.

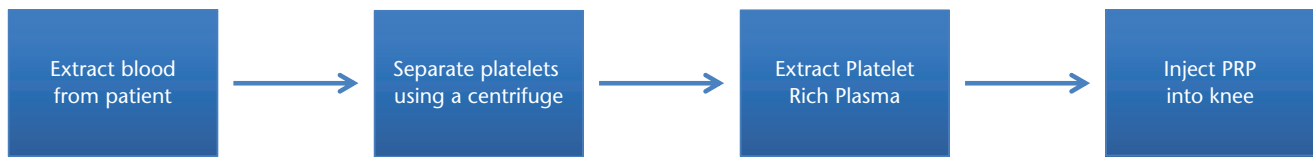


Fig. 1. Platelet-rich plasma (PRP) procedure.

Table 1. Platelet and WBC concentrations vary between preparations<sup>69</sup>

Study	Centrifugations (n)	Mean concentrations (per mL)	
		Platelets	WBC
Cerza et al <sup>20</sup>	Single	3-5 (10 <sup>8</sup> )	Not reported
Kon et al <sup>12</sup>	Double	>6 (10 <sup>7</sup> )	Not reported
Filardo et al <sup>67</sup>	Double	5 × WB	1.2 × WB
Patel et al <sup>23</sup>	Single	3.1 (10 <sup>8</sup> )	0
Spakova et al <sup>24</sup>	Double	6.8 (10 <sup>8</sup> )	2.3 (10 <sup>7</sup> )

WBC, white blood cells; WB, whole blood.

These result in four categories of products.<sup>13</sup>

1. Pure PRP (P-PRP) with a low content of leucocytes. This can be injected as a liquid or a gel.
2. Leucocyte-rich PRP (L-PRP) has a greater concentration of platelets than P-PRP. Similarly to P-PRP, it can be used as an activated gel or in a liquid form to be injected intra-articularly.
3. Pure platelet-rich fibrin (P-PRF). This is obtained by double-spinning centrifugation. The end product is a platelet-rich fibrin scaffold, which is stiffer than the conventional PRP and takes the form of a gel.
4. Leucocyte- and platelet-rich fibrin (L-PRF) which is a leucocyte-rich gel which is non-injectable and is applied locally.

The activation of PRP also varies between studies. Some add calcium chloride while others prefer inactivated PRP.<sup>14-19</sup>

However, there is a variation between final platelet concentrations between techniques and even within a given technique (Table 1).<sup>20-24</sup>

A higher concentration of platelets is not necessarily more efficacious with one study suggesting that the ideal concentration is  $1.5 \times 10^6$  platelets per microlitre.<sup>25</sup>

The final platelet concentration is influenced by a number of factors, such as the initial volume of whole blood, concentration of other cells, the preparation technique, age and co-morbidities of the patient.<sup>26</sup>

There are a number of delivery techniques ranging from direct injection into the knee<sup>18-19,21-22,24</sup> to application via a collagen membrane giving a gel-like consistency.<sup>27</sup>

Adverse events have been reported. One study reported 19 adverse events including dizziness, headaches, nausea, gastritis, sweating and tachycardia. These were all

self-limiting.<sup>23</sup> Another group reported 31 adverse events in those receiving PRP injections including post-injection pain, swelling at the site of injection and limitation in activities. These resolved by day four in all patients.<sup>28</sup>

In terms of contra-indications, one study suggested that patients undergo a minor haematological evaluation to exclude blood disorders or platelet dysfunction. They suggest the relative contra-indications for PRP are: a platelet count less than  $10^5/\mu\text{L}$ ; a haemoglobin level less than 10 g/dL; presence of a tumour in the wound bed or metastatic disease; and other active infections.<sup>29</sup>

The therapeutic schedule used by the lead author is a course of three injections which are two weeks apart with 3 mL of PRP injected on each occasion.

## Knee ligament injuries

Ligaments connect bones and are important for joint stability and proprioception. They comprise 70% water and 30% solid material with the latter being extracellular matrix and fibroblasts. The most abundant collagen is type 1 which is arranged in a haphazard manner to cope with the different directions of pull.<sup>30</sup>

Ligament healing undergoes four indistinct phases. The inflammatory phase occurs in the first week with an increase in growth factors (TGF- $\beta$ 1, IGF, PDGF, BMPs). The proliferation phase occurs at days 7 to 21 where type 3 collagen is replaced by type 1. The final stages of remodelling and maturation begin at two weeks. PRP can increase growth factors and so may be of benefit in the initial inflammatory phase.<sup>30</sup>

### Anterior cruciate ligament reconstruction

Anterior cruciate ligament (ACL) reconstruction is a successful procedure with very good outcomes and patient satisfaction.<sup>31</sup> Maturation of the graft is important for biomechanical strength and return to activity. This may be facilitated by PDGF, TGF- $\beta$ 1 and IGF-1.<sup>31</sup> Studies have shown PRP has the capacity to improve ACL cell viability and function and may be given to hasten ACL graft healing.<sup>32</sup>

A prospective single-blind study with 50 participants who were treated with and without PRP after their ACL autograft found that those who had PRP gel at the time of surgery had quicker biological maturation on MRI scanning at one year ( $p < 0.001$ ).<sup>31</sup>

Another level 1 study where platelet concentrate was added to the semitendinosus graft and to the femoral tunnel led to a higher rate of graft maturation at six months as demonstrated on MRI scans.<sup>33</sup>

Another group administered PRP to the femoral tunnels in 30 patients and at three months found no difference in MRI findings pertaining to graft maturation.<sup>34</sup> This may be due to the shorter follow-up and fewer participants than the previous studies.

A systematic review looking at eight trials concluded that ACL maturation after reconstruction can show 20% to 30% improvement with the addition of PRP.<sup>35</sup>

Other studies assessed structural changes of the ACL graft after PRP administration. One study looked at 37 patients who had ACL reconstruction using hamstring grafts with and without PRP. Second-look arthroscopies showed those who had PRP had improved graft remodeling with connective tissue enveloping the graft and the grafts were thicker. They postulated that the PRP may enhance the 'ligamentisation' process in tendon grafts.<sup>36</sup>

On the contrary, a level 1 study with 100 patients were randomised to either receive or not receive platelet-enriched gel during ACL reconstruction. At two-year follow-up, there was no difference in any of the functional and radiological outcome scores. The authors attributed these findings to several factors; PRP preparation/centrifugation, graft choice, rehabilitation protocols and application technique.<sup>37</sup> The outcome of this study was mirrored by another group who showed that the use of PRP in ACL allograft reconstruction produced no discernible difference at two-year follow-up.<sup>38</sup>

PRP has also been used at the patellar and tibial bone plug harvest site. In a level 1 study involving 40 participants, PRP gel was added to these sites. At one-year follow-up, knee function was significantly higher in those who had received PRP ( $p = 0.041$ ).<sup>39</sup>

In a further study, 12 patients received PRP in the patellar tendon defect after harvesting for ACL reconstruction compared with 15 who did not. A six-month MRI scan demonstrated that those who received PRP had a smaller patellar tendon gap.<sup>40</sup>

## Tendon and muscle

In the early stages of tendon healing, there is an upregulation of PDGF and TGF- $\beta$  resulting in new vessel formation and collagen synthesis. These factors are present in high concentrations in PRP and may be beneficial in the early stages of tendon repair.<sup>41</sup>

A prospective level III study looked at the efficacy of PRP injections in chronic refractory patellar tendinopathy. The 15 patients were treated with multiple PRP injections and physiotherapy while 16 were treated exclusively with physiotherapy. Those who received PRP had a statistically

significant better activity level after a short follow-up at six months. All other outcomes, such as pain, showed no difference between the two groups.<sup>42</sup>

Another study evaluated the outcome of patients with patellar tendinopathy treated with PRP injections.<sup>43</sup> Additionally, they examined whether certain characteristics, such as activity level or previous treatment influenced the results. After PRP treatment, patients with patellar tendinopathy showed a statistically significant improvement in pain during activities of daily life, work and sport. However, patients who were not treated before with ethoxysclerol, cortisone and/or surgical treatment showed the improvement.<sup>43</sup>

These limited studies are encouraging and indicate that PRP injections have the potential to promote the achievement of a satisfactory clinical outcome, even in difficult cases with chronic refractory tendinopathy after previous classical treatments have failed.

## Meniscus injuries

The meniscus is an intra-articular structure composed primarily of type 1 collagen. Its main functions are shock absorption, proprioception, lubrication and joint stability.<sup>30</sup> It is vulnerable to repetitive injury which can predispose to osteoarthritis. Repair depends on the site and extent of damage. The periphery is vascular and has greater scope for healing compared with the avascular inner portion.<sup>44,45</sup>

Laboratory experiments have shown that PRP has a positive effect on meniscal cells. PRP may provide growth factors that enhance the meniscus healing through cell proliferation and vascularisation. For the meniscus to heal there needs to be a blood supply. The inner white-white zone is devoid of this and so the vascularisation induced by PRP may be important.<sup>46,47</sup>

A level III study found that PRP augmentation at the time of meniscal repair showed no difference in reoperation rate, function and return to sports. However, there were only 15 patients who had PRP augmentation *versus* 20 who did not. These small numbers may not have adequately highlighted noticeable differences.<sup>48</sup> On the contrary, a French group performed a case-control study looking at the addition of PRP following meniscal repair. They found that open meniscal repair of horizontal tears extending into the avascular zone was effective at mid-term follow-up in younger patients. Clinical outcomes were slightly improved with the addition of PRP.<sup>49</sup>

## Osteoarthritis

Osteoarthritis is a degenerative disease of synovial joints resulting in the progressive loss of articular cartilage. The aetiology can be primary (intrinsic defect) or secondary

(trauma, infection). It starts with a loss of the weight-bearing articular cartilage surface followed by osteophyte development. Late disease is characterised by cartilage disintegration exposing the bony surface.<sup>50</sup>

Biochemically, there is an increased water content (decreased in aging), alterations in proteoglycans (decreased content and increased chondroitin/keratin sulphate ratio).<sup>50</sup> There is also an increase in metalloproteinases and IL-1 which may have a catabolic effect leading to cartilage degeneration.<sup>50</sup>

Histologically, there is a loss of superficial chondrocytes, breakdown of the tidemark, fissuring and cartilage destruction with eburnation of subchondral bone.<sup>50</sup>

Normal cartilage is avascular which accounts for its lack of inherent healing potential.<sup>51-53</sup>

Radiographic findings include subchondral cysts/sclerosis, marginal osteophyte formation and joint-space narrowing.

Non-operative treatment comprises analgesia increasing as per the World Health Organization (WHO) analgesic ladder. Weight management and physical therapy are also beneficial. Varus/valgus unloading bracing, tibial osteotomy or unicompartment replacement prosthesis can be used in unicompartmental disease in patients who wish to delay total knee arthroplasty.

Intra-articular corticosteroid injections reduce synovitis and it is assumed that their analgesic action in osteoarthritis is in some way related to this.<sup>54</sup>

Surgical treatment includes microfracture, autologous chondrocyte implantation and osteochondral implantation.<sup>55</sup> However, despite good short- and medium-term results, these treatments may not prevent the long-term development of osteoarthritis.<sup>56</sup>

The United Kingdom National Institute of Health & Clinical Excellence (NICE) recommends that intra-articular corticosteroid injections should be considered as an adjunct to core treatments for the relief of moderate to severe pain in people with osteoarthritis for a limited period.<sup>57</sup>

Endogenous hyaluronan (previously known as hyaluronic acid) is a large, linear glycosaminoglycan and is a major non-structural component of both the synovial and cartilage extracellular matrix. It is also found in synovial fluid and is produced by the lining layer cells of the joint. Its key functions in the joint are to confer visco-elasticity, lubrication and help maintain tissue hydration and protein homeostasis by preventing large fluid movements and by acting as an osmotic buffer.<sup>30</sup>

*In vitro* studies have shown that chondrocytes stimulated with PRP increase proteoglycan and collagen synthesis which have similar histological and biochemical qualities to normal hyaline cartilage.<sup>58-63</sup> PRP also contains factors such as TGF- $\beta$ 1, thrombospondin-1 and insulin-like growth factor which are proposed to be useful in

treating symptomatic cartilage lesions or osteochondral defects.<sup>64</sup>

A retrospective cohort study examining the use of PRP in the knee looked at 60 patients with unilateral Ahlback grades 1 to 4 osteoarthritis. The first 30 patients were treated with three injections of PRP and the remainder had hyaluronic acid injections. At five-week follow-up, those injected with PRP had significantly higher WOMAC (Western Ontario and McMaster Universities Arthritis Index) scores. These results were invalidated by the short follow-up.<sup>65</sup>

An earlier study with similar findings had a larger cohort of 150 patients with six-monthly follow-up.<sup>66</sup> There were three treatment arms: activated PRP (infiltration every 21 days), single dose high molecular weight hyaluronic acid (HMWHA) and low molecular weight hyaluronic acid (LMWHA). Outcome measures used were visual analogue scale, quality of life related to health status (EQ VAS) and knee function using the International Knee Documentation Committee index (IKDC). The authors reported better response rates in PRP-treated patients than any treated with hyaluronic acid ( $p < 0.005$ ). In all groups, the response was better in younger patients and in those who had recent onset osteoarthritis.<sup>66</sup>

A randomised control trial (RCT) with 120 participants demonstrated significantly superior outcomes up to 24 weeks after local PRP injection compared with hyaluronic acid ( $p < 0.001$ ).<sup>20</sup> A double-blind prospective RCT in which 78 patients with bilateral osteoarthritis were randomised to receive PRP, two PRP injections three weeks apart or a single saline injection. Both the PRP groups had significantly better six-month outcomes.<sup>23</sup>

An Italian level 1 study demonstrated that PRP injections, compared with hyaluronic acid injections, showed a significant improvement up to one year. However, for middle-aged patients with moderate signs of osteoarthritis, PRP results were no better than those who had HA injections.<sup>67</sup>

A systematic review looked at a total of ten studies in the final analysis, with the majority of studies looking at the use of PRP in degenerative osteoarthritis of the hip or knee. Most patients reported improvement in pain and functional outcome scores at six months with no studies reporting worsening scores. However, none reported any long-term follow-up. They concluded that PRP may be beneficial in the short term but that there is a poverty of long-term high quality data.<sup>68</sup>

Another systematic review looked at six level 1 and 2 studies overall. They found improved function in adult patients with mild or moderate knee osteoarthritis at six months who had PRP injections compared with hyaluronic acid or normal saline.<sup>69</sup> Four of the studies reported an increase in adverse non-specific events in those treated with PRP including pain, stiffness, syncope, dizziness,

nausea, gastritis, sweating and tachycardia which were all self-limiting.<sup>22-24,28</sup>

A Taiwanese group carried out a meta-analysis of single-arm studies, quasi-experimental studies and RCTs. This equated to 1543 participants. They concluded that PRP improves function for 12 months in patients with knee joint cartilage pathology and is more effective than hyaluronic acid administration.<sup>70</sup>

There have been a number of case series which demonstrate the use of PRP in those with knee osteoarthritis. One study described the results in 261 patients injected three times at fortnightly intervals. At six-month follow-up, there were significant improvements in the WOMAC, SF-36 and functional scores compared with baseline. There were no adverse effects.<sup>19</sup> Another series with 65 patients who received a single PRP injection showed pain scores were reduced at six months. However, at nine and 12 months, the scores had started to increase.<sup>71</sup> A study in 2011 had the longest follow-up with 91 patients with a minimum follow-up of one year. They demonstrated a decrease in pain and improvement in function compared with baseline.<sup>72</sup>

These studies may provide evidence with respect to the safety of PRP but they lacked a control group. Nevertheless, they did provide pre-PRP pain, function and quality of life scores in the same patients.<sup>19,71,72</sup>

Radiological changes have also been reported with PRP in osteoarthritis of the knee. A prospective cohort study with one-year follow-up of patients after PRP for early knee osteoarthritis had 22 participants. All received a 6 mL PRP injection. A total of 15 participants underwent clinical assessments at baseline, week 1, and months 1, 3, 6 and 12, and MRI at one year. Pain scores decreased, whereas functional and clinical scores increased at six months and one year from baseline significantly. Qualitative MRIs demonstrated no change per compartment in at least 73% of cases at one year.<sup>73</sup>

In the United Kingdom, NICE published guidelines in May 2014 ('Platelet-rich plasma injections for osteoarthritis of the knee').<sup>74</sup> These state that current evidence on PRP injections for osteoarthritis of the knee raises no major safety concerns. Nevertheless, the evidence on efficacy is inadequate in quality. NICE recommends that this procedure should only be used with special arrangements for clinical governance, consent, and audit or research.<sup>74</sup>

They also suggest that any further research into PRP injections for treating osteoarthritis of the knee should categorically describe patient selection and take the form of well-designed studies that compare the procedure against other methods of management. Outcomes should include knee function scores, patient-reported outcome measures and the timing of subsequent interventions.<sup>74</sup>

PRP has been used since the 1950s to manage maxillofacial and dermatological conditions and applications

have now been extended to the knee. There is a growing body of evidence to support its use for selected indications in osteoarthritis, ligament, tendon and meniscal injuries of the knee. The evidence is of variable quality and concerns include the heterogeneous nature of the patients, variations in treatment techniques and inconsistencies in the findings of these studies. However, there is no hard evidence for its effects and before widespread use can be recommended, high quality prospective randomised studies are required.

#### AUTHOR INFORMATION

St Michael's Hospital, 30 Bond Street, Toronto, M5B1W8, Canada  
Walsall Manor Hospital, Moat Road, Walsall, WS2 9PS, UK

Correspondence should be sent to: Mohammad Shahid, St Michael's Hospital, 30 Bond Street, Toronto M5B1W8, Canada.  
Email: shahidm99@doctors.org.uk

#### ICMJE CONFLICT OF INTEREST STATEMENT

None

#### FUNDING STATEMENT

No benefits in any form have been received or will be received from a commercial party related directly or indirectly to the subject of this article.

#### LICENCE

© 2017 The author(s)

This article is distributed under the terms of the Creative Commons Attribution-Non Commercial 4.0 International (CC BY-NC 4.0) licence (<https://creativecommons.org/licenses/by-nc/4.0/>) which permits non-commercial use, reproduction and distribution of the work without further permission provided the original work is attributed.

#### REFERENCES

1. Marx RE. Platelet-rich plasma (PRP): what is PRP and what is not PRP? *Implant Dent* 2001;10:225-228.
2. Tayapongsak P, O'Brien DA, Monteiro CB, Arceo-Diaz LY. Autologous fibrin adhesive in mandibular reconstruction with particulate cancellous bone and marrow. *J Oral Maxillofac Surg* 1994;52:161-165; discussion 166.
3. Lee KS, Wilson JJ, Rabago DP, et al. Musculoskeletal applications of platelet-rich plasma: fad or future? *AJR Am J Roentgenol* 2011;196:628-636.
4. LaPrade CM, James EW, LaPrade RF, Engebretsen L. How should we evaluate outcomes for use of biologics in the knee? *J Knee Surg* 2015;28:35-44.
5. Hall MP, Band PA, Meislin RJ, Jazrawi LM, Cardone DA. Platelet-rich plasma: current concepts and application in sports medicine. *J Am Acad Orthop Surg* 2009;17:602-608.
6. Hsu WK, Mishra A, Rodeo SR, et al. Platelet-rich plasma in orthopaedic applications: evidence-based recommendations for treatment. *J Am Acad Orthop Surg* 2013;21:739-748.
7. Mazzocca AD, McCarthy MB, Chowaniec DM, et al. The positive effects of different platelet-rich plasma methods on human muscle, bone, and tendon cells. *Am J Sports Med* 2012;40:1742-1749.
8. DeLong JM, Russell RP, Mazzocca AD. Platelet-rich plasma: the PAW classification system. *Arthroscopy* 2012;28:998-1009.

9. **Hall MP, Band PA, Meislin RJ, Jazrawi LM, Cardone DA.** Platelet-rich plasma: current concepts and application in sports medicine. *J Am Acad Orthop Surg* 2009;17:602-608.
10. **Wasterlain AS, Braun HJ, Harris AH, Kim HJ, Dragoo JL.** The systemic effects of platelet-rich plasma injection. *Am J Sports Med* 2013;41:186-193.
11. **Harris SE, Bonewald LF, Harris MA, et al.** Effects of transforming growth factor beta on bone nodule formation and expression of bone morphogenetic protein 2, osteocalcin, osteopontin, alkaline phosphatase, and type I collagen mRNA in long-term cultures of fetal rat calvarial osteoblasts. *J Bone Miner Res* 1994;9:855-863.
12. **Marmotti A, Rossi R, Castoldi F, et al.** PRP and articular cartilage: a clinical update. *Biomed Res Int* 2015;2015:542502.
13. **Dohan Ehrenfest DM, Andia I, Zumstein MA, et al.** Classification of platelet concentrates (Platelet-Rich Plasma-PRP, Platelet-Rich Fibrin-PRF) for topical and infiltrative use in orthopedic and sports medicine: current consensus, clinical implications and perspectives. *Muscles Ligaments Tendons J* 2014;4:3-9.
14. **Filardo G, Kon E, Buda R, et al.** Platelet-rich plasma intra-articular knee injections for the treatment of degenerative cartilage lesions and osteoarthritis. *Knee Surg Sports Traumatol Arthrosc* 2011;19:528-535.
15. **Kon E, Buda R, Filardo G, et al.** Platelet-rich plasma: intra-articular knee injections produced favorable results on degenerative cartilage lesions. *Knee Surg Sports Traumatol Arthrosc* 2010;18:472-479.
16. **Mei-Dan O, Carmont MR, Laver L, et al.** Platelet-rich plasma or hyaluronate in the management of osteochondral lesions of the talus. *Am J Sports Med* 2012;40:534-541.
17. **Sánchez M, Anitua E, Azofra J, Aguirre JJ, Andia I.** Intra-articular injection of an autologous preparation rich in growth factors for the treatment of knee OA: a retrospective cohort study. *Clin Exp Rheumatol* 2008;26:910-913.
18. **Sánchez M, Guadilla J, Fiz N, Andia I.** Ultrasound-guided platelet-rich plasma injections for the treatment of osteoarthritis of the hip. *Rheumatology (Oxford)* 2012;51:144-150.
19. **Wang-Saegusa A, Cugat R, Ares O, et al.** Infiltration of plasma rich in growth factors for osteoarthritis of the knee short-term effects on function and quality of life. *Arch Orthop Trauma Surg* 2011;131:311-317.
20. **Cerza F, Carni S, Carcangiu A, et al.** Comparison between hyaluronic acid and platelet-rich plasma, intra-articular infiltration in the treatment of gonarthrosis. *Am J Sports Med* 2012;40:2822-2827.
21. **Kon E, Mandelbaum B, Buda R, et al.** Platelet-rich plasma intra-articular injection versus hyaluronic acid viscosupplementation as treatments for cartilage pathology: from early degeneration to osteoarthritis. *Arthroscopy* 2011;27:1490-1501.
22. **Filardo G, Kon E.** PRP: more words than facts... *Knee Surg Sports Traumatol Arthrosc* 2012;20:1655-1656.
23. **Patel S, Dhillon MS, Aggarwal S, Marwaha N, Jain A.** Treatment with platelet-rich plasma is more effective than placebo for knee osteoarthritis: a prospective, double-blind, randomized trial. *Am J Sports Med* 2013;41:356-364.
24. **Spaková T, Rosocha J, Lacko M, Harvanová D, Gharaibeh A.** Treatment of knee joint osteoarthritis with autologous platelet-rich plasma in comparison with hyaluronic acid. *Am J Phys Med Rehabil* 2012;91:411-417.
25. **Giusti I, Rughetti A, D'Ascenzo S, et al.** Identification of an optimal concentration of platelet gel for promoting angiogenesis in human endothelial cells. *Transfusion* 2009;49:771-778.
26. **Mazucco L, Balbo V, Cattana E, Guaschino R, Borzini P.** Not every PRP-gel is born equal. Evaluation of growth factor availability for tissues through four PRP-gel preparations: Fibrinet, RegenPRP-Kit, Plateletex and one manual procedure. *Vox Sang* 2009;97:110-118.
27. **Dhollander AAM, De Neve F, Almqvist KF, et al.** Autologous matrix-induced chondrogenesis combined with platelet-rich plasma gel: technical description and a five pilot patients report. *Knee Surg Sports Traumatol Arthrosc* 2011;19:536-542.
28. **Li M, Zhang C, Ai Z, et al.** [Therapeutic effectiveness of intra-knee-articular injection of platelet-rich plasma on knee articular cartilage degeneration]. *Zhongguo Xiu Fu Chong Jian Wai Ke Za Zhi* 2011;25:1192-1196. (In Chinese)
29. **Everts PA, Knape JT, Weibrich G, et al.** Platelet-rich plasma and platelet gel: a review. *J Extra Corpor Technol* 2006;38:174-187.
30. **Miller M, Thompson SR, Hart JA.** *Review of Orthopedics*. Sixth Edition. Philadelphia, PA: Elsevier, 2012:39-62.
31. **Radice F, Yáñez R, Gutiérrez V, et al.** Comparison of magnetic resonance imaging findings in anterior cruciate ligament grafts with and without autologous platelet-derived growth factors. *Arthroscopy* 2010;26:50-57.
32. **Sánchez M, Anitua E, Lopez-Vidriero E, Andia I.** The future: optimizing the healing environment in anterior cruciate ligament reconstruction. *Sports Med Arthrosc* 2010;18:48-53.
33. **Orrego M, Larrain C, Rosales J, et al.** Effects of platelet concentrate and a bone plug on the healing of hamstring tendons in a bone tunnel. *Arthroscopy* 2008;24:1373-1380.
34. **Silva A, Sampaio R.** Anatomic ACL reconstruction: does the platelet-rich plasma accelerate tendon healing? *Knee Surg Sports Traumatol Arthrosc* 2009;17:676-682.
35. **Figuerola D, Figuerola F, Calvo R, et al.** Platelet-rich plasma use in anterior cruciate ligament surgery: systematic review of the literature. *Arthroscopy* 2015;31:981-988.
36. **Sánchez M, Anitua E, Azofra J, et al.** Ligamentization of tendon grafts treated with an endogenous preparation rich in growth factors: gross morphology and histology. *Arthroscopy* 2010;26:470-480.
37. **Nin JR, Gasque GM, Azcárate AV, Beola JD, Gonzalez MH.** Has platelet-rich plasma any role in anterior cruciate ligament allograft healing? *Arthroscopy* 2009;25:1206-1213.
38. **Magnussen RA, Flanigan DC, Pedroza AD, Heinlein KA, Kaeding CC.** Platelet rich plasma use in allograft ACL reconstructions: two-year clinical results of a MOON cohort study. *Knee* 2013;20:277-280.
39. **Cervellin M, de Girolamo L, Bait C, Denti M, Volpi P.** Autologous platelet-rich plasma gel to reduce donor-site morbidity after patellar tendon graft harvesting for anterior cruciate ligament reconstruction: a randomized, controlled clinical study. *Knee Surg Sports Traumatol Arthrosc* 2012;20:114-120.
40. **de Almeida AM, Demange MK, Sobrado MF, et al.** Patellar tendon healing with platelet-rich plasma: a prospective randomized controlled trial. *Am J Sports Med* 2012;40:1282-1288.
41. **Jeong DU, Lee CR, Lee JH, et al.** Clinical applications of platelet-rich plasma in patellar tendinopathy. *Biomed Res Int* 2014;2014:249498
42. **Filardo G, Kon E, Della Villa S, et al.** Use of platelet-rich plasma for the treatment of refractory jumper's knee. *Int Orthop* 2010;34:909-915.
43. **Gosens T, Den Oudsten BL, Fievez E, van't, Spijker P, Fievez A.** Pain and activity levels before and after platelet-rich plasma injection treatment of patellar tendinopathy: a prospective cohort study and the influence of previous treatments. *Int Orthop* 2012;36:1941-1946.

- 44. Arnoczky SP, McDevitt CA.** The meniscus: structure, function, repair, and replacement. In: Buckwalter JA, Einhorn TA, Simon SR, eds. *Orthopaedic Basic Science: Biology and Biomechanics of the Musculoskeletal System*. Second ed. Rosemont, IL: American Academy of Orthopaedic Surgeons, 2000:531-545.
- 45. Rodeo SA, Kawamura S.** Form and function of the meniscus. In: Buckwalter JA, Einhorn TA, Okeefe RJ, eds. *Orthopaedic Basic Science: Biology and Biomechanics of the Musculoskeletal System*. Second ed. Rosemont, IL: American Academy of Orthopaedic Surgeon, 2000:175-190.
- 46. Wei LC, Gao SG, Xu M, et al.** A novel hypothesis: the application of platelet-rich plasma can promote the clinical healing of white-white meniscal tears. *Med Sci Monit* 2012;18:HY47-HY50.
- 47. King D.** The healing of semilunar cartilages. 1936. *Clin Orthop Relat Res* 1990;252:4-7.
- 48. Griffin JW, Hadeed MM, Werner BC, et al.** Platelet-rich plasma in meniscal repair: does augmentation improve surgical outcomes? *Clin Orthop Relat Res* 2015;473:1665-1672.
- 49. Pujol N, Salle De Chou E, Boisrenoult P, Beauvils P.** Platelet-rich plasma for open meniscal repair in young patients: any benefit? *Knee Surg Sports Traumatol Arthrosc* 2015;23:51-58.
- 50. Miller MD, Thompson SR, Hart JA.** *Review of Orthopedics*. Sixth edition. Philadelphia, PA: Elsevier, 2012:1-38.
- 51. Buckwalter JA, Saltzman C, Brown T.** The impact of osteoarthritis: implications for research. *Clin Orthop Relat Res* 2004;427:S6-S15.
- 52. Ochi M, Uchio Y, Kawasaki K, Wakitani S, Iwasa J.** Transplantation of cartilage-like tissue made by tissue engineering in the treatment of cartilage defects of the knee. *J Bone Joint Surg [Br]* 2002;84-B:571-578.
- 53. Mankin HJ.** The response of articular cartilage to mechanical injury. *J Bone Joint Surg [Am]* 1982;64-A:460-466.
- 54. Ostergaard M, Stoltenberg M, Gideon P, et al.** Changes in synovial membrane and joint effusion volumes after intraarticular methylprednisolone. Quantitative assessment of inflammatory and destructive changes in arthritis by MRI. *J Rheumatol* 1996;23:1151-1161.
- 55. Detterline AJ, Goldstein JL, Rue JP, Bach BR Jr.** Evaluation and treatment of osteochondritis dissecans lesions of the knee. *J Knee Surg* 2008;21:106-115.
- 56. Kellett CF, Boscainos PJ, Gross AE.** Surgical options for articular defects of the knee. *Expert Rev Med Devices* 2006;3:585-593.
- 57. No authors listed.** NICE Osteoarthritis: care and management NICE guidelines [CG177]. <https://www.nice.org.uk/guidance/cg177> (date last accessed 10 January 2017).
- 58. Sun Y, Feng Y, Zhang CQ, Chen SB, Cheng XG.** The regenerative effect of platelet-rich plasma on healing in large osteochondral defects. *Int Orthop* 2010;34:589-597.
- 59. Saito M, Takahashi KA, Arai Y, et al.** Intraarticular administration of platelet-rich plasma with biodegradable gelatin hydrogel microspheres prevents osteoarthritis progression in the rabbit knee. *Clin Exp Rheumatol* 2009;27:201-207.
- 60. Milano G, Sanna Passino E, Deriu L, et al.** The effect of platelet rich plasma combined with microfractures on the treatment of chondral defects: an experimental study in a sheep model. *Osteoarthritis Cartilage* 2010;18:971-980.
- 61. Kon E, Buda R, Filardo G, et al.** Platelet-rich plasma: intra-articular knee injections produced favorable results on degenerative cartilage lesions. *Knee Surg Sports Traumatol Arthrosc* 2010;18:472-479.
- 62. Krüger JP, Hondke S, Endres M, et al.** Human platelet-rich plasma stimulates migration and chondrogenic differentiation of human subchondral progenitor cells. *J Orthop Res* 2012;30:845-852.
- 63. Lee HR, Park KM, Joung YK, Park KD, Do SH.** Platelet-rich plasma loaded in situ-formed hydrogel enhances hyaline cartilage regeneration by CB1 upregulation. *J Biomed Mater Res A* 2012;100:3099-3107.
- 64. Leitner GC, Gruber R, Neumüller J, et al.** Platelet content and growth factor release in platelet-rich plasma: a comparison of four different systems. *Vox Sang* 2006;91:135-139.
- 65. Sánchez M, Anitua E, Azofra J, Aguirre JJ, Andia I.** Intra-articular injection of an autologous preparation rich in growth factors for the treatment of knee OA: a retrospective cohort study. *Clin Exp Rheumatol* 2008;26:910-913.
- 66. Petrella RJ, Petrella M.** A prospective, randomized, double-blind, placebo controlled study to evaluate the efficacy of intraarticular hyaluronic acid for osteoarthritis of the knee. *J Rheumatol* 2006;33:951-956.
- 67. Filardo G, Kon E, Di Martino A, et al.** Platelet-rich plasma vs hyaluronic acid to treat knee degenerative pathology: study design and preliminary results of a randomized controlled trial. *BMC Musculoskelet Disord* 2012;13:229.
- 68. Dold AP, Zywiell MG, Taylor DW, Dwyer T, Theodoropoulos J.** Platelet-rich plasma in the management of articular cartilage pathology: a systematic review. *Clin J Sport Med* 2014;24:31-43.
- 69. Khoshbin A, Leroux T, Wasserstein D, et al.** The efficacy of platelet-rich plasma in the treatment of symptomatic knee osteoarthritis: a systematic review with quantitative synthesis. *Arthroscopy* 2013;29:2037-2048.
- 70. Chang KV, Hung CY, Aliwarga F, et al.** Comparative effectiveness of platelet-rich plasma injections for treating knee joint cartilage degenerative pathology: a systematic review and meta-analysis. *Arch Phys Med Rehabil* 2014;95:562-575.
- 71. Jang SJ, Kim JD, Cha SS.** Platelet-rich plasma (PRP) injections as an effective treatment for early osteoarthritis. *Eur J Orthop Surg Traumatol* 2013;23:573-580.
- 72. Filardo G, Kon E, Buda R, et al.** Platelet-rich plasma intra-articular knee injections for the treatment of degenerative cartilage lesions and osteoarthritis. *Knee Surg Sports Traumatol Arthrosc* 2011;19:528-535.
- 73. Halpern B, Chaudhury S, Rodeo SA, et al.** Clinical and MRI outcomes after platelet-rich plasma treatment for knee osteoarthritis. *Clin J Sport Med* 2013;23:238-239.
- 74. No authors listed.** NICE Platelet-rich plasma injections for osteoarthritis of the knee NICE interventional procedure guidance [IPG491]. <https://www.nice.org.uk/guidance/ipg491> (date last accessed 10 January 2017).