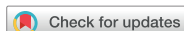

Original Article



Risk factors for unrecognized invasive carcinoma in patients with vulvar high-grade squamous intraepithelial lesion at vulvoscopy-directed biopsy

Mario Preti,¹ Lauro Bucchi,² Bruno Ghiringhello,³ Silvana Privitera,³
Valentina Frau,¹ Elisabetta Corvetto,¹ Chiara Benedetto,¹ Leonardo Micheletti¹

¹Department of Obstetrics and Gynecology, University of Torino, Torino, Italy

²Romagna Cancer Registry, Romagna Cancer Institute (IRST) IRCCS, Meldola, Forlì, Italy

³Department of Pathology and Cytology of Female Cancer, Childhood Cancer, and Rare Cancers, AOU Città della Salute e della Scienza, Torino, Italy

OPEN ACCESS

Received: May 29, 2016

Revised: Dec 22, 2016

Accepted: Jan 5, 2017

Correspondence to

Mario Preti

Department of Obstetrics and Gynecology,
University of Torino, Via Ventimiglia 3, Torino
10128, Italy.

E-mail: mpreti@cittadellasalute.to.it

Copyright © 2017. Asian Society of
Gynecologic Oncology, Korean Society of
Gynecologic Oncology
This is an Open Access article distributed
under the terms of the Creative Commons
Attribution Non-Commercial License ([https://
creativecommons.org/licenses/by-nc/4.0/](https://creativecommons.org/licenses/by-nc/4.0/))
which permits unrestricted non-commercial
use, distribution, and reproduction in any
medium, provided the original work is properly
cited.

ORCID

Mario Preti

<https://orcid.org/0000-0002-1573-3114>

Lauro Bucchi

<https://orcid.org/0000-0002-6771-8119>

Bruno Ghiringhello

<https://orcid.org/0000-0003-1357-3660>

Silvana Privitera

<https://orcid.org/0000-0003-2753-1314>

Valentina Frau

<https://orcid.org/0000-0002-1868-5066>

Elisabetta Corvetto

<https://orcid.org/0000-0001-8661-2902>

Chiara Benedetto

<https://orcid.org/0000-0003-1514-4771>

ABSTRACT

Objective: To evaluate the prevalence and risk factors for unrecognized invasive carcinoma in a series of patients undergoing surgical excision after an office biopsy of vulvar high-grade squamous intraepithelial lesion (VHSIL).

Methods: Two hundred and sixteen consecutive patients treated in a tertiary-level referral center for vulvar disease in north-western Italy were recruited. Patients' records were reviewed by trained personnel. Factors showing a statistically significant ($p < 0.05$) association with detection of stromal invasion at excisional surgery in univariate analysis were further examined in a backward stepwise multiple logistic regression model.

Results: The median patient age was 50 years (range, 19–88). More than 25% patients with VHSIL at biopsy had associated cervical/vaginal intraepithelial neoplasia, and more than 35% had a multifocal lesion. Invasive carcinoma was detected in surgical specimens from 24 patients (11%). The depth of stromal invasion varied between 0.1 mm and 3.0 mm with a median of 0.5 mm. In multivariate analysis, the risk of invasive carcinoma detection was greater for patients in the highest tertile of age ($p = 0.008$), for patients with a lesion ≥ 20 mm in size ($p = 0.013$) and with clitoral involvement ($p < 0.001$), and for patients presenting with a nodular lesion ($p = 0.078$).

Conclusion: Our study suggests that patient age, lesion size, clitoral involvement and nodular appearance in patients with VHSIL at vulvoscopy-directed biopsy are independently associated with the risk of unrecognized invasive carcinoma.

Keywords: Biopsy; Vulvar Neoplasms; Vulvar High-grade Squamous Intraepithelial Lesion; Vulvoscopy

INTRODUCTION

In the treatment of vulvar high-grade squamous intraepithelial lesion (VHSIL) [1], cold knife, radiofrequency or laser excision, and vaporization may result in different degrees of disfiguring effects. In consideration of the risk of adverse somatic and psychosexual sequelae [2-4], less invasive treatments have been developed. These include photodynamic therapy and topical use of immunomodulators [2-6].

Leonardo Micheletti

<https://orcid.org/0000-0002-0337-8637>
Conflict of Interest

No potential conflict of interest relevant to this article was reported.

Author Contributions

Conceptualization: P.M., B.L., B.C., M.L.;
 Data curation: B.L., F.V., C.E.; Formal
 analysis: P.M., B.L.; Funding acquisition:
 B.C., M.L.; Investigation: P.M., G.B., P.S.,
 M.L.; Methodology: P.M., B.L.; Project
 administration: P.M.; Resources: G.B., P.S.,
 B.C., M.L.; Software: F.V., C.E.; Supervision:
 P.M., B.L., B.C., M.L.; Validation: P.M., B.L., F.V.,
 C.E.; Visualization: P.M., B.L.; Writing - original
 draft: P.M., B.L.; Writing - review & editing:
 P.M., B.L., B.C., M.L.

In conservative treatments of VHSIL, it is of utmost importance to exclude the presence of foci of stromal invasion, which conveys an increased risk of metastatic spread to lymph nodes. If biopsy fails to detect the presence of invasive disease, the therapeutic approach and follow-up schedule may be suboptimal and survival rates will dramatically decrease [7]. By implication, biopsy should be directed—under vulvoscopic guidance—to the area at highest risk of invasion in order to obtain representative specimens for histologic evaluation [8-10]. Vulvoscopy aims at detecting macroscopic changes in color, thickness and morphology of vulvar skin and mucosa. However, while cervical disease can be graded according to opacity, margins, contour, vasculature, and staining reactions of potentially abnormal epithelium, there is no grading system that helps differentiate vulvar lesions. This contributes to explaining why, in the clinical practice, the prevalence of clinically unrecognized stromal invasion in VHSIL varies up to over 20% of patients [8,11-14].

These problems call for a research effort to identify clues on how to decrease the risk that vulvoscopy-directed biopsy of VHSIL will fail to detect areas of invasive carcinoma. This involves identifying the patient and disease characteristics associated with stromal invasion, on which physicians could base their decisions for biopsy and subsequent treatment. Current knowledge about these characteristics is poor. Patient age is considered a risk factor, but the supporting evidence is circumstantial [15]. Moreover, no clinical risk factor has ever been identified [16].

The current article reports an analytical study of the prevalence and determinants of stromal invasion undetected at biopsy in a series of VHSIL patients from Italy.

MATERIALS AND METHODS

1. Setting

The study is part of a larger retrospective investigation of clinical presentation, diagnosis, treatment, and post-treatment outcomes of vulvar low-grade squamous intraepithelial lesion (VLSIL), VHSIL, differentiated-type vulvar intraepithelial neoplasia (dVIN), and invasive vulvar carcinoma at a tertiary-level referral center for vulvar disease in north-western Italy. All patients are seen on an outpatient basis. The policy for referral and admittance to the center has remained unchanged since its establishment in 1981.

2. Diagnosis and treatment

The examination of the vulva was performed under adequate lightening by naked eyes. A magnifying lens or a colposcope was used to better evaluate, if deemed necessary, the margins of lesions. Routine application of acetic acid was not used because of the previously reported high rate of false-positive results [10]. The clinical aspects of vulvar squamous intraepithelial lesion were described using the general principles of dermatology, defining location, focality, size, color, surface, thickness, and margination of the lesion [17]. Subsequently, in the most of suspicious areas, local anesthesia of the biopsy site was performed and a cold knife biopsy was taken. A standard diagram and digital images (when available) of the lesion were taken. Once the histological diagnosis of VHSIL was established, patients were submitted to excisional treatment. Biopsy and surgical specimens were processed according to a standard institutional procedure as previously described [18,19].

Ten gynecologists, 6 pathologists, 3 dermatologists and hundreds of residents attended the center during the 35 years after its creation. In order to minimize the variability of clinical

approaches, the diagnosis and treatment of all suspected cases of VHSIL and invasive carcinoma were only performed by 2 gynecologists (MP, LM), and all biopsy and surgical specimens were evaluated by 2 dedicated gynecologic pathologists (BG, SP).

3. Patients

The clinical and pathological records of patients histologically diagnosed with VLSIL, VHSIL, and dVIN between 1981 and 2014 were reviewed by trained personnel using a structured set of items of information. All available data were coded by the principal investigator. For patients with multiple diagnoses of vulvar squamous intraepithelial lesion, the index lesion was identified. Data from 302 consecutive patients were evaluated. Patients who were diagnosed with VLSIL (n=52) and dVIN (n=21), who refused treatment (n=7), and who received imiquimod as primary treatment (n=5) were excluded. There remained 216 eligible women.

4. Data analysis

Patient age was categorized into tertiles in order to detect a trend in the risk of unrecognized invasive carcinoma (if any) with the highest possible statistical power. The years of treatment were grouped into quartiles because of the unpredictable changes in disease care potentially associated with the long time span of the study. Lesion size was categorized in 2 groups only (<20 mm and ≥20 mm) in order to minimize the mismeasurement bias.

Differences in proportions were tested for significance with the chi-square tests for heterogeneity and trend, and the Fisher exact test. Differences in distributions were tested with the nonparametric Mann-Whitney test. Statistical significance was set at $p < 0.05$. A p -value > 0.05 and < 0.10 was considered to indicate a borderline level of significance. Explanatory factors showing a statistically significant association with invasive carcinoma detection in univariate analysis were further examined in a multiple logistic regression model with backward stepwise selection of variables. The level of significance for removal of variables was set at $p = 0.10$.

RESULTS

1. Patient characteristics

The yellow curve in **Fig. 1** shows the frequency distribution of the 216 eligible patients according to 5-year age group. Although the pattern was not clearly bimodal, a peak was observed at age 40–44 years followed by a second frequency increase between 60–64 years and 70–74 years. **Table 1** gives a summary overview of other major patient and disease characteristics. Noteworthy, more than 25% patients had an associated cervical intraepithelial neoplasia (CIN) and/or vaginal intraepithelial neoplasia (VAIN), and more than one third of lesions were multifocal.

2. Prevalence of unrecognized invasive carcinoma

Invasive carcinoma unrecognized at biopsy was detected in surgical specimens from 24 patients (11.1%). The depth of stromal invasion varied between 0.1 mm and 3.0 mm with a median of 0.5 mm. In 4 of the 24 patients (16.7%), the depth of stromal invasion was > 1.0 mm. The blue curve in **Fig. 1** shows the frequency distribution of patients according to age group. Two peaks were observed at age 40–44 years and 70–74 years. Patients with unrecognized invasive carcinoma were older than patients free of invasion (median age, 64 vs. 48 years; $p = 0.005$).

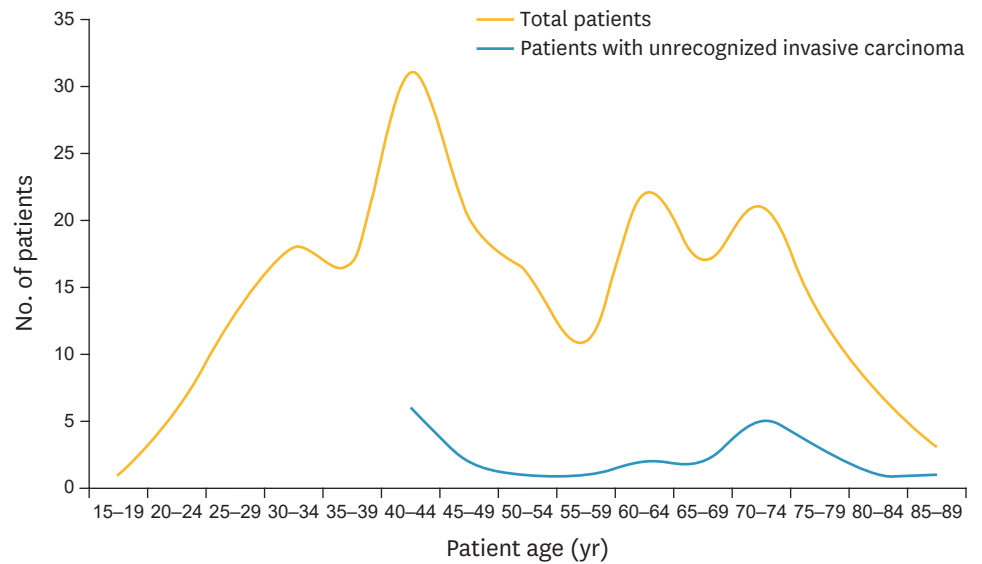


Fig. 1. Frequency distribution of the 216 study patients according to 5-year age group and unrecognized invasive vulvar carcinoma detection at biopsy.

Table 1. Patient and disease characteristics of study cases of VHSIL

Characteristic	No.*	%
BMI ≥ 25	53/131	40.5
HIV positivity	14/216	6.5
Associated lesions		
CIN and/or VAIN	56/216	25.9
Lichen sclerosus	16/216	7.4
Squamous hyperplasia	17/216	7.9
Other dermatoses [†]	11/216	5.1
Presence of symptoms	88/216	40.7
Vulvar thirds involved		
Upper third	29/128	22.7
Middle third	25/128	19.5
Lower third	60/128	46.9
Multiple	14/128	10.9
Lesion size ≥ 20 mm	74/135	54.8
Multifocality	76/212	35.8
Vulvar regions involved		
Clitoris	41/214	19.2
Labia majora	85/214	39.7
Labia minora	97/214	45.3
Vestibule	39/214	18.2
Posterior fourchette	73/214	34.1
Perineum	20/214	9.3
Lesion appearance		
Macule	28/177	15.8
Nodule	26/177	14.7
Papule	54/177	30.5
Plaque	49/177	27.7
Ulcer	20/177	11.3
Lesion color		
Reddish	58/186	31.2
Whitish	120/186	64.5
Hyperpigmentation	69/186	37.1

BMI, body mass index; CIN, cervical intraepithelial neoplasia; HIV, human immunodeficiency virus; VAIN, vaginal intraepithelial neoplasia; VHSIL, vulvar high-grade squamous intraepithelial lesion.

*Patients with missing information on each characteristic were excluded from the denominator; [†]Including lichen planus.

3. Risk factors for unrecognized invasive carcinoma

Table 2 shows the factors significantly associated with the prevalence of unrecognized invasive carcinoma in univariate analysis. The highest prevalence was observed in the subgroup of patients with involvement of 2 or 3 vulvar thirds (35.7%). Nonsignificant risk factors are listed in a footnote. A risk increase of borderline significance ($p=0.072$) was observed among VHSILs involving labia minora (16.5% vs. 6.8%).

Factors listed in **Table 2** were examined further in a multiple logistic regression model, and 4 of them were demonstrated to be independently associated with the risk of invasive carcinoma detection in surgical specimens. As shown in **Table 3**, this was significantly increased for patients in the highest tertile of age, for patients with a lesion size ≥ 20 mm,

Table 2. Significant univariate risk factors for clinically unrecognized invasive vulvar carcinoma detection in VHSIL (n=216)

Risk factor	Patients		p
	Total No.	No. (%) with invasive carcinoma	
Patient age (tertiles, yr)			0.008*
19–42	71	3 (4.2)	
43–62	74	8 (10.8)	
63–88	71	13 (18.3)	
Year of treatment (quartiles)			0.029*
1981–1994	51	2 (3.9)	
1995–2003	59	5 (8.5)	
2004–2008	54	9 (16.7)	
2009–2014	52	8 (15.4)	
Vulvar thirds involved			0.020
Upper third	29	5 (17.2)	
Middle third	25	2 (8.0)	
Lower third	60	6 (10.0)	
Two or three thirds	14	5 (35.7)	
Unknown	88	6 (6.8)	
Lesion size (largest diameter, mm)			0.007
<20	61	5 (8.2)	
≥ 20	74	15 (20.3)	
Unknown	81	4 (4.9)	
Multifocality			0.022
No	136	9 (6.6)	
Yes	76	14 (18.4)	
Unknown	4	1 (25.0)	
Involvement of clitoris			0.002
No	173	13 (7.5)	
Yes	41	11 (26.8)	
Unknown	2	0 (0.0)	
Lesion appearance			0.022
Macule	28	1 (3.6)	
Nodule	26	5 (19.2)	
Papule	54	7 (13.0)	
Plaque	49	10 (20.4)	
Ulcer	20	0 (0.0)	
Unknown	39	1 (2.6)	
Reddish color			0.025
No	128	10 (7.8)	
Yes	58	12 (20.7)	
Unknown	30	2 (6.7)	

The following were not significantly ($p < 0.05$) associated with the prevalence of clinically unrecognized invasive carcinoma detection: BMI (<25, ≥ 25 , unknown); comorbidity (no, human immunodeficiency virus positivity, other); associated cervical and/or vaginal intraepithelial neoplasia; associated lichen sclerosus, squamous hyperplasia, and other dermatoses; symptoms; involvement of labia majora, of labia minora, of vestibule, of posterior fourchette, and of perineum; whitish color; hyperpigmentation; unless otherwise indicated, variables were coded as: no, yes, unknown.

BMI, body mass index; VHSIL, vulvar high-grade squamous intraepithelial lesion.

*Test for trend.

Table 3. Significant multivariate risk factors for clinically unrecognized invasive vulvar carcinoma detection in VHSIL (n=216)

Risk factor	OR	95% CI	p
Patient age (tertiles, yr)			0.028
19–42	1.00	reference	
43–62	3.67	0.75–18.00	
63–88	8.11	1.71–38.50	
Lesion size (mm)			0.003
<20	1.00	reference	
≥20	6.78	1.50–30.60	
Unknown	0.37	0.07–1.89	
Involvement of clitoris			0.001
No	1.00	reference	
Yes	18.00	4.01–80.90	
Unknown	-	-	
Lesion appearance			0.250
Macule	1.00	reference	
Nodule	8.28	0.79–86.50	
Papule	4.92	0.48–50.30	
Plaque	6.17	0.69–57.00	
Ulcer	-	-	
Unknown	0.71	0.04–12.90	

Year of treatment, vulvar thirds involved, multifocality, and reddish color were removed from the model as nonsignificantly contributing to its likelihood ($p>0.10$). CI, confidence interval; OR, odds ratio; VHSIL, vulvar high-grade squamous intraepithelial lesion.

and for patients with clitoral involvement. The risk increase for patients presenting with a nodular lesion was of borderline statistical significance. The univariate association of multifocality with the dependent variable was not confirmed by multivariate analysis.

DISCUSSION

The finding of an unanticipated stromal invasion in a VHSIL confirms that the disease has a potential to progress [20] and that it is necessary to raise awareness about the limitations of vulvoscopy-directed biopsy in detecting early invasive carcinoma. Vulvoscopy serves two distinct functions: the estimation of severity of the lesion and the selection of biopsy site(s). Failure to ascertain the presence of stromal invasion may cause the patient to be undertreated and may have a strongly adverse impact on prognosis. In turn, this may lead the clinician to lose confidence in conservative treatments of VHSIL. According to previously reported case series, the biopsy site may be incorrectly selected in as many as 20% of patients [8,12]. The proportion was lower in our data, but it must be considered that our institution is a tertiary-level referral center for vulvar disease and that all diagnostic and treatment procedures were performed by the most experienced ones of us.

The rationale of this study is that an improved knowledge of the patient and disease characteristics associated with the presence of undetected foci of invasive carcinoma may assist the decision making for biopsy and treatment. First, in our data, the prevalence of stromal invasion increased regularly with increasing patient age, although a significant excess was demonstrated only when comparing the highest tertile of the variable with the lowest one. This observation is compatible with the univariate finding of van de Nieuwenhof et al. [21] that the risk of subsequent diagnosis of invasive vulvar carcinoma increases with the age at diagnosis of usual type vulvar intraepithelial neoplasia. Our observation also lends support to another previous study reporting an increased risk of invasive carcinoma detection among aged patients specifically presenting with a raised lesion [15]. It must be noted that our result

was adjusted for the clinical features of VHSIL, which suggests that patient age predicts the presence of stromal invasion independently of these. In any case, we can confirm that excisional therapies are indicated for postmenopausal women [22].

The second key observation in this study was that the risk of unrecognized invasive carcinoma was greater among large-sized lesions. To interpret this finding, it should be noted that multivariate analysis did not confirm the causal role of multifocality that previous data had indirectly suggested [23]. We believe that lesion size is a confounder of the association between multifocality and the risk of invasive carcinoma detection. In other words, the univariate risk increase that is apparently due to multifocality is probably accounted for by the associated enlargement of the lesion, which indicates more rapid cell growth and spread and a greater amount of neoplastic epithelium at risk of progressing to invasive carcinoma. This hypothesis is in keeping with the evidence for a relationship between lesion size and disease recurrence [24].

The third, and most interesting, finding of this study was that the clitoral involvement conveyed a many-fold higher likelihood of clinically unrecognized stromal invasion. The incidence of invasive vulvar carcinoma with clitoral involvement has increased at a particularly rapid pace in recent decades, probably because the non-keratinized squamous cell epithelium covering the clitoris is less protected from human papillomavirus (HPV) infection [25]. In addition, the clitoral location of invasive vulvar carcinoma is associated with larger tumor size, deeper stromal invasion, and more frequent spread to lymph nodes. These unfavorable features have been related to patients' and physicians' delay in diagnosis [26], and this is a plausible explanation for our own observation. Patients' concerns regarding clitoral functionality and the hesitation to perform biopsies in order to avoid injury to the clitoral region do probably suggest a prolonged expectant management of VHSIL, with delayed diagnosis and clinically unrecognized disease progression. This attitude toward biopsy needs careful reflection. Although it is reasonable to balance the potential incremental benefit of taking a biopsy against functional and psychosexual contraindications, a more liberal biopsy of any suspicious areas is necessary to ascertain progression to invasive disease [3] and is especially indicated in patients undergoing an expectant management [9]. It is important that the peri-clitoral region be carefully inspected moving up the clitoral hood, so that the correct site for biopsy or biopsies be identified, and that the size of samples be adequate.

The risk of unrecognized invasive carcinoma detection was also found to be greater in nodular lesions, albeit at a weaker level of significance. An interesting analogy exists between this association and the well-documented clinical and prognostic significance of nodulation in pigmented skin lesions, in which this pattern of clinical presentation predicts rapid cell growth, local aggression, and vertical spread [27].

Among negative results, it is of note that human immunodeficiency virus (HIV) positivity did not predict the presence of invasive carcinoma. HIV-positive patients were more often diagnosed with unrecognized stromal invasion but not to a significant extent (2/14 or 14% vs. 22/202 or 11%, $p=0.48$, data not shown) and less than expected [28]. This was probably caused by their limited number and by the resulting random variability. In general, HIV-positive patients in the study area attend dedicated clinics.

There are several methodological issues in this study that need to be considered. First, we cannot completely rule out a selection bias in this single-institution case series. The prevalence of some patient characteristics differed from previous studies.

Second, the long time-span of patient accrual involves the risk that unpredictable time changes in disease behavior have introduced a bias in the results. Statistical adjustment for the year of diagnosis may be insufficient to control for this problem.

Third, the lack of information on patient HPV status is a limitation of the current study. Since HPV DNA is detectable in 87% patients with VIN vs. 29% patients with invasive vulvar carcinoma [29], it would be of interest to determine its prevalence among those VHSILs in which an early and clinically unrecognized stromal invasion has occurred. In the clinical practice, however, HPV DNA testing of specimens from VHSIL is not recommended [1]. In addition, during the first decade (1981–1990) of the study period, the specimens were fixed in Bouin's solution which prevents DNA analysis.

Last, but not less important, we wish to make a point on our treatment protocol. Since the risk of stromal invasion in patients with a biopsy diagnosis of VHSIL has always been a concern in our clinical practice, we have exceptionally used topical imiquimod (off-label use) as first line therapy, i.e., in 5 patients who have been excluded from this series. More often, although in selected patients, imiquimod has been used as adjuvant therapy after surgical excision. For the same reason, we do not use laser or radiofrequency vaporization of mucosal VHSIL in young patients. According to current practice guidelines [2,3], wide local excision is the treatment of choice if a patient with a biopsy diagnosis of VHSIL is suspected to have an occult cancer. In this study, we have considered the risk of clinically unsuspected stromal invasion, and we have identified some independent determinants. More data are needed before we can develop an appropriate statistical algorithm designed to predict the patient's individual risk. The ultimate objective is to personalize treatment based on the individual disease status, in order to avoid both under- and over-treatment.

We can conclude that patient age, lesion size and appearance, and clitoral involvement were independently associated with unrecognized invasive carcinoma detection. The clinical correlates of VHSIL progression and the accuracy of vulvoscopy in selecting biopsy sites warrant further investigations, possibly on a multicenter basis. In the interim, data currently available suggest that aged patients, patients with large and nodular lesions, and patients with clitoral involvement require special attention, with a timely, correct, and more liberal use of vulvar biopsy and the width of excision precisely tailored to the extent of disease.

ACKNOWLEDGMENTS

The authors thank Ignazio Stanganelli, Skin Cancer Unit, IRST, Meldola, Italy, for his help in the interpretation of results.

REFERENCES

1. Bornstein J, Bogliatto F, Haefner HK, Stockdale CK, Preti M, Bohl TG, et al.. The 2015 International Society for the Study of Vulvovaginal Disease (ISSVD) terminology of vulvar squamous intraepithelial lesions. *J Low Genit Tract Dis* 2016;20:11-4.
[PUBMED](#) | [CROSSREF](#)
2. Lawrie TA, Nordin A, Chakrabarti M, Bryant A, Kaushik S, Pepas L. Medical and surgical interventions for the treatment of usual-type vulval intraepithelial neoplasia. *Cochrane Database Syst Rev* 2016:CD011837.
[PUBMED](#)

3. Committee Opinion No. 675 summary: management of vulvar intraepithelial neoplasia. *Obstet Gynecol* 2016;128:937-8.
[PUBMED](#) | [CROSSREF](#)
4. Lockhart J, Gray NM, Cruickshank ME. The development and evaluation of a questionnaire to assess the impact of vulval intraepithelial neoplasia: a questionnaire study. *BJOG* 2013;120:1133-42.
[PUBMED](#) | [CROSSREF](#)
5. de Witte CJ, van de Sande AJ, van Beekhuizen HJ, Koeneman MM, Kruse AJ, Gerestein CG. Imiquimod in cervical, vaginal and vulvar intraepithelial neoplasia: a review. *Gynecol Oncol* 2015;139:377-84.
[PUBMED](#) | [CROSSREF](#)
6. Tristram A, Hurt CN, Madden T, Powell N, Man S, Hibbitts S, et al. Activity, safety, and feasibility of cidofovir and imiquimod for treatment of vulvar intraepithelial neoplasia (RT³VIN): a multicentre, open-label, randomised, phase 2 trial. *Lancet Oncol* 2014;15:1361-8.
[PUBMED](#) | [CROSSREF](#)
7. Slomovitz BM, Coleman RL, Oonk MH, van der Zee A, Levenback C. Update on sentinel lymph node biopsy for early-stage vulvar cancer. *Gynecol Oncol* 2015;138:472-7.
[PUBMED](#) | [CROSSREF](#)
8. Husseinzadeh N, Recinto C. Frequency of invasive cancer in surgically excised vulvar lesions with intraepithelial neoplasia (VIN 3). *Gynecol Oncol* 1999;73:119-20.
[PUBMED](#) | [CROSSREF](#)
9. van Beurden M, van Der Vange N, ten Kate FJ, de Craen AJ, Schilthuis MS, Lammes FB. Restricted surgical management of vulvar intraepithelial neoplasia 3: focus on exclusion of invasion and on relief of symptoms. *Int J Gynecol Cancer* 1998;8:73-7.
[PUBMED](#) | [CROSSREF](#)
10. Micheletti L, Preti M, Bogliatto F, Lynch PJ. Vulvology. A proposal for a multidisciplinary subspecialty. *J Reprod Med* 2002;47:715-7.
[PUBMED](#)
11. Powell LC Jr, Dinh TV, Rajaraman S, Hannigan EV, Dillard EA Jr, Yandell RB, et al. Carcinoma in situ of the vulva. A clinicopathologic study of 50 cases. *J Reprod Med* 1986;31:808-14.
[PUBMED](#)
12. Modesitt SC, Waters AB, Walton L, Fowler WC Jr, Van Le L. Vulvar intraepithelial neoplasia III: occult cancer and the impact of margin status on recurrence. *Obstet Gynecol* 1998;92:962-6.
[PUBMED](#)
13. Jones RW, Rowan DM, Stewart AW. Vulvar intraepithelial neoplasia: aspects of the natural history and outcome in 405 women. *Obstet Gynecol* 2005;106:1319-26.
[PUBMED](#) | [CROSSREF](#)
14. Polterauer S, Catharina Dressler A, Grimm C, Seebacher V, Tempfer C, Reinthaller A, et al. Accuracy of preoperative vulva biopsy and the outcome of surgery in vulvar intraepithelial neoplasia 2 and 3. *Int J Gynecol Pathol* 2009;28:559-62.
[PUBMED](#) | [CROSSREF](#)
15. Chafe W, Richards A, Morgan L, Wilkinson E. Unrecognized invasive carcinoma in vulvar intraepithelial neoplasia (VIN). *Gynecol Oncol* 1988;31:154-65.
[PUBMED](#) | [CROSSREF](#)
16. Preti M, Igdbashian S, Costa S, Cristoforoni P, Mariani L, Origoni M, et al. VIN usual type—from the past to the future. *Ecancermedicalscience* 2015;9:531.
[PUBMED](#) | [CROSSREF](#)
17. Lynch PJ, Moyal-Barracco M, Scurry J, Stockdale C. 2011 ISSVD Terminology and classification of vulvar dermatological disorders: an approach to clinical diagnosis. *J Low Genit Tract Dis* 2012;16:339-44.
[PUBMED](#) | [CROSSREF](#)
18. Barbero M, Micheletti L, Preti M, Valentino MC, Nicolaci P, Canni M, et al. Biologic behavior of vulvar intraepithelial neoplasia. Histologic and clinical parameters. *J Reprod Med* 1993;38:108-12.
[PUBMED](#)
19. Preti M, Ronco G, Ghiringhello B, Micheletti L. Recurrent squamous cell carcinoma of the vulva: clinicopathologic determinants identifying low risk patients. *Cancer* 2000;88:1869-76.
[PUBMED](#) | [CROSSREF](#)
20. Heller DS, van Seters M, Marchitelli C, Moyal-Barracco M, Preti M, van Beurden M. Update on intraepithelial neoplasia of the vulva: proceedings of a Workshop at the 2009 World Congress of the International Society for the Study of Vulvovaginal Diseases, Edinburgh, Scotland, September 2009. *J Low Genit Tract Dis* 2010;14:363-73.
[PUBMED](#) | [CROSSREF](#)

21. van de Nieuwenhof HP, Massuger LF, van der Avoort IA, Bekkers RL, Casparie M, Abma W, et al. Vulvar squamous cell carcinoma development after diagnosis of VIN increases with age. *Eur J Cancer* 2009;45:851-6.
[PUBMED](#) | [CROSSREF](#)
22. Nugent EK, Brooks RA, Barr CD, Case AS, Mutch DG, Massad LS. Clinical and pathologic features of vulvar intraepithelial neoplasia in premenopausal and postmenopausal women. *J Low Genit Tract Dis* 2011;15:15-9.
[PUBMED](#) | [CROSSREF](#)
23. Hillemanns P, Wang X, Staehle S, Michels W, Dannecker C. Evaluation of different treatment modalities for vulvar intraepithelial neoplasia (VIN): CO(2) laser vaporization, photodynamic therapy, excision and vulvectomy. *Gynecol Oncol* 2006;100:271-5.
[PUBMED](#) | [CROSSREF](#)
24. Wallbillich JJ, Rhodes HE, Milbourne AM, Munsell MF, Frumovitz M, Brown J, et al. Vulvar intraepithelial neoplasia (VIN 2/3): comparing clinical outcomes and evaluating risk factors for recurrence. *Gynecol Oncol* 2012;127:312-5.
[PUBMED](#) | [CROSSREF](#)
25. Hampl M, Deckers-Figiel S, Hampl JA, Rein D, Bender HG. New aspects of vulvar cancer: changes in localization and age of onset. *Gynecol Oncol* 2008;109:340-5.
[PUBMED](#) | [CROSSREF](#)
26. Hinten F, van den Einden LC, Cissen M, IntHout J, Massuger LF, de Hullu JA. Clitoral involvement of squamous cell carcinoma of the vulva: localization with the worst prognosis. *Eur J Surg Oncol* 2015;41:592-8.
[PUBMED](#) | [CROSSREF](#)
27. Greenwald HS, Friedman EB, Osman I. Superficial spreading and nodular melanoma are distinct biological entities: a challenge to the linear progression model. *Melanoma Res* 2012;22:1-8.
[PUBMED](#) | [CROSSREF](#)
28. Bradbury M, Cabrera S, García-Jiménez A, Franco-Camps S, Sánchez-Iglesias JL, Díaz-Feijoo B, et al. Vulvar intraepithelial neoplasia: clinical presentation, management and outcomes in women infected with HIV. *AIDS* 2016;30:859-68.
[PUBMED](#) | [CROSSREF](#)
29. de Sanjosé S, Alemany L, Ordi J, Tous S, Alejo M, Bigby SM, et al. Worldwide human papillomavirus genotype attribution in over 2000 cases of intraepithelial and invasive lesions of the vulva. *Eur J Cancer* 2013;49:3450-61.
[PUBMED](#) | [CROSSREF](#)