

Body to Scalp: Evolving Trends in Body Hair Transplantation

Abstract

Follicular unit extraction (FUE) is becoming an increasingly popular method for hair restoration. As FUE leaves behind no linear scars, it is more suitable to harvest from various body areas including beard, chest, and extremities in hirsute individuals. Body hair characteristics such as thickness, length, and hair cycle may not completely match to that of the scalp hair. The techniques of harvesting body hairs are more time consuming, requiring higher degree of skill than regular scalp FUE. Body hair transplantation can be successfully used either alone or in combination with scalp hair in advanced grades of baldness, for improving the cosmetic appearance of hairlines and in scarring alopecia when there is paucity of donor scalp hair. Harvesting of body hairs opens up a new viable donor source for hair restoration surgeons, especially in cases of advanced Norwood grades five and above of androgenetic alopecia.

Keywords: *Androgenetic alopecia, body hair transplant and follicular unit extraction, limited scalp donor hair*

Introduction

Hair transplantation is a rapidly evolving field where hair restoration surgeons are trying to find newer methods to improve the graft yield and improve the overall final aesthetic result of hair restoration procedure. Traditionally, hair transplantation utilizes harvesting of follicles from safe donor area of the scalp and transplantation of these follicles in to the balding areas on the scalp. There is a limited supply of follicles to be harvested from the safe donor area zone; approximately up to a maximum of 6000 hair follicular units in best of donor area density.^[1] This is inadequate to provide appropriate coverage, especially in advanced grades VI and VII of Norwood scale in androgenetic alopecia. In such cases, hair follicles from other parts of body inclusive of beard, chest, arms, and legs in hirsute individuals can be utilized as source of additional donor supply.

While conventional follicular unit transplant (FUT) is a suitable procedure for harvesting from the scalp, it may be problematic and leave cosmetically unacceptable scarring if used for harvesting body hairs. Follicular unit extraction (FUE) on the other hand is much more suitable for harvesting body hairs, which instead of removing a strip of hair bearing skin, uses

punches to individually extract the follicular units. The circular punch wounds heal with secondary intention in a few days.^[2] In FUE, individual follicular units from the donor site (body or scalp) are harvested one graft at a time using circular punches. FUE involves use of sharp or dull punches of various diameters ranging from 0.7 to 1.3 mm. It is unlike FUT because a linear donor strip is not excised, and postoperative wound healing is quicker and less traumatic for patients.^[3]

History

Woods was the first to successfully harvest FUE grafts using 1-mm circular punches in 1995. A similar technique was described by Inaba in his textbook in 1996.^[4] In 2002, the term 'Follicular Unit Extraction' (FUE) method was coined by Rassman and Bernstein to describe this procedure.^[5]

While body hair transplant with FUE is being utilized in hair restoration only recently, Okuda in 1939 first described in principle body hair transplants where he used hairs from scalp, brow, axillary, and pubic areas to restore hairs in cicatricial and congenital alopecia of scalp and pubic areas.^[6] Hirai *et al.* in 2001 recorded first successful body hair transplant with the use of modified 18-gauge hypodermic needles to harvest small amounts of beard hair

This is an open access article distributed under the terms of the Creative Commons Attribution-NonCommercial-ShareAlike 3.0 License, which allows others to remix, tweak, and build upon the work non-commercially, as long as the author is credited and the new creations are licensed under the identical terms.

For reprints contact: reprints@medknow.com

How to cite this article: Saxena K, Savant SS. Body to scalp: Evolving trends in body hair transplantation. *Indian Dermatol Online J* 2017;8:167-75.

Received: August, 2016. **Accepted:** March, 2017.

**Kuldeep Saxena,
Sandeep S. Savant**

*Cosmazone Hair Restoration
Clinics, Mumbai-Gwalior-Delhi,
India*

Address for correspondence:

*Dr. Sandeep S. Savant,
Cosmazone, 413, Neo Corporate
Plaza, Malad West,
Mumbai - 400 064, Maharashtra,
India.
E-mail: sandeepsavant@gmail.
com*

Access this article online

Website: www.idoj.in

DOI: 10.4103/idoj.IDOJ_283_16

Quick Response Code:



by cutting around single follicles to the level of the sub dermis.^[7]

Indications for harvesting body or non-scalp hair for hair transplant

1. Hirsute individuals with adequate terminal hairs over beard, chest, legs, arms, and other body parts
2. Advanced grades of androgenetic alopecia, e.g., Norwood grades 6 or 7, where donor scalp hair is inadequate to provide complete or adequate coverage^[8]
3. Exhaustion of available scalp donor hair due to previous restoration surgeries, with inadequate coverage of existing bald areas requiring more follicular units for aesthetic restoration result
4. Combining with scalp donor hair to improve recipient area density to improve the final cosmetic result^[9]
5. To camouflage or seal a low density thinned out post-FUE harvest safe donor area zone in the scalp, to camouflage linear FUT scar in donor area^[10]
6. Fine caliber body hair can be utilized for softening of hairline and in temporal area restoration
7. Lack of adequate donor scalp hair in cases of cicatricial alopecia where scarring process is so extensive that there is lack of donor hair from scalp to provide adequate coverage in scarring patches.^[11,12]

Body hair characteristics

Most of the hair on human body is vellus hair, which cannot be used for hair restoration. The androgen sensitive hair in beard, trunk, axillae, and pubis develops into terminal hair with the onset of puberty; this is suitable for body hair transplant. Between 30% and 85% of body hairs are in the telogen phase. The anagen phase of body hair is much shorter; a few months compared with several years for scalp hair. Consequently, body hair grows shorter and thinner as compared to scalp hair.^[13-15] It is only the beard hair that grows thicker in comparison to the scalp hair.^[16] Body hair is often curled and post-transplant almost always curls as it grows beyond a certain length. However, with grooming and straightening the curliness of body hair can be reduced for better match with the native scalp hair.^[17] Body hair lie more superficially in the dermis than the scalp hair, which are anchored at the level of deep reticular dermis or subcutaneous tissue. Body hairs emerge from the skin surface at a more acute angle in comparison to the scalp hair. Generally, body hair grows singly, at times follicular units having two or three follicles are found and harvested from beard and chest areas [Figure 1a-d].

Table 1 provides details about hair cycle duration and follicle depth at different body sites.^[18,19]

Preoperative phase planning and donor hair preparation

Planning should include identification of the donor hair sources, understanding approximately how many grafts are

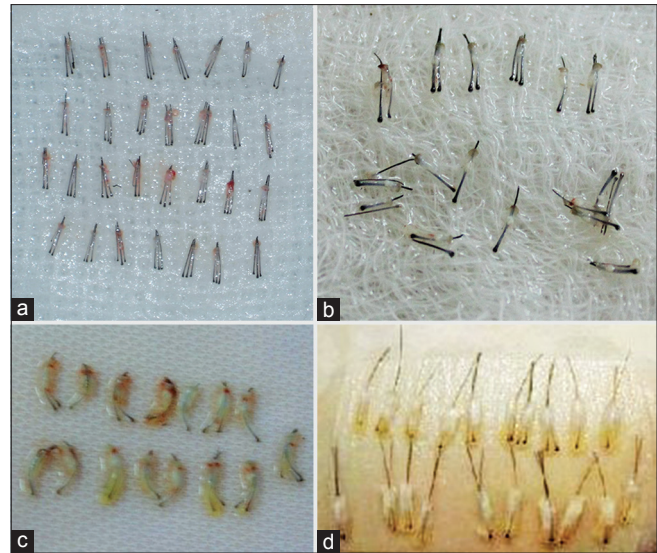


Figure 1: (a) Scalp hair grafts have longer intradermal course and one can easily harvest follicular units having three or four follicles to enhance the optical density. (b) Beard hair grafts are thicker with shorter intradermal course as compared to scalp hairs. Note few follicular units have two or three follicles per unit. (c) Pubic hair grafts appear thick and have a short, curved intradermal course compared to scalp hair grafts. Such grafts require a wider punch or manual needle follicular unit extraction (FUE) to reduce graft transection. (note a few follicular units having two follicles per graft). (d) Axillary hair grafts harvested by follicular unit transplant (FUT) method. (FUT is easier for axillary hairs because of the difficult to access location for doing FUE and resultant scar can be hidden in the axillary folds)

Table 1: Details about hair cycle duration and follicle depth at different body sites^[18,19]

Art	Anagen duration weeks	Anagen percentage	Telogen duration	Telogen percentage	Follicle depth
Scalp	2-6 years	85	3-4 months	15	3-5 mm
Beard chin	1 year	70	10 weeks	30	2-4 mm
Moustache	16 weeks	65	6 weeks	35	1-2 mm
Trunk	16 weeks	30	12 weeks	70	
Axillae	16 weeks	30	12 weeks	70	3-4 mm
Pubic	16 weeks	30	12 weeks	70	3-4 mm
Legs	16 weeks	20	24 weeks	80	2-4 mm

needed from each source, and knowing where and how the donor source hair will be transplanted. It is generally preferable to mix hair from different donor sources in the recipient site to create a blended look, which is aesthetically more pleasing than look that could result from grafting islands of non-mixed body hairs.^[8] The characteristics of the recipient body hair have to be matched to the donor hair, taking into account hair diameter, color, curliness, typical rate of growth, and shaft angle.

Early phase anagen and telogen hair are unsuitable for transplantation (being much more fragile and susceptible to transection during the extraction processes). Most body hairs are in telogen phase and their anagen phase is also shorter; a few months compared with several years for scalp hair. Therefore before harvesting, it will be beneficial

if the anagen: telogen ratio of the body hair can be changed to increase the number of anagen hair for harvesting and if late anagen phase body hair can be identified for harvesting. Pretreatment with minoxidil and wet shaving of body hair 7 days and beard for two days before transplant helps in this regard.^[20,21] Minoxidil causes lengthening of the hair follicle linear growth rate, increases the hair follicle diameter, and alters the hair cycle by shortening the telogen and prolonging the anagen phase.^[22] Minoxidil pretreatment is from two to six months or longer.

Anesthesia

Infiltration anesthesia with anesthetic mixture of 1% lidocaine with adrenaline (1:100,000) can be used, after defining the donor area in the body. Tumescence mixture used is with 30 ml normal saline with 0.25 ml adrenaline (1:2000000) to achieve the necessary tissue turgor.^[23] Body hair grows over thicker soft tissue with no bony prominences underneath as compared to scalp hair, hence more tumescence may be required to produce adequate tissue turgor. Use of tumescent anesthesia helps in harvesting from a larger body area without exceeding the permissible limit.^[24,25] Some surgeons also use bupivacaine due to its longer duration of action. While adverse reactions with bupivacaine are rare, at higher dosages or if accidentally injected in blood vessels it has the potential to cause ventricular tachycardia or fibrillation, which may be refractory to treatment. Authors prefer to use lidocaine with adrenaline and divide the procedure into shorter sessions, if needed.

Procedure and instruments

Motorized or manual FUE punches, either sharp or dull, in sizes 0.75 to 0.9 mm in diameter are suitable for body hair transplant; hypodermic large bore 18-G needles for needle FUE, forceps, petri dishes, tensioner's (KD's spreader), magnification (loops and visors) with cold light sources for adequate visualization and height with tilt adjustable operation table are primary requirements for the procedure.

FUE method with either motorized or manual punches is suitable for harvesting of body hairs. Most body hair follicular units with exception of beard hairs have single follicles and are thinner than scalp hair; punches sized 0.75 to 0.9 mm diameter are adequate for body hair harvesting.^[9] Smaller the punch diameter, smaller will be resultant scars, which are less visible and cosmetically more acceptable. Body hairs emerge at more acute angle to the surface of skin, lie shallower in the dermis, and change directions or patterns within a small area as compared to scalp hair. Accordingly, the operating physician should match the angle, direction, and depth to reduce graft transection. Both sharp and dull punches can be used for harvesting of grafts, as per operators' preference. Author personally prefers sharp punches as appears faster and more useful for body hair transplant.

For beard hair harvesting, the patient is kept in supine position with neck extended to adequately expose the face and submandibular region. In the beard area; hair follicles from cheeks, sub mandibular area, and along the mandibular region are harvested first. The beard in moustache and chin areas defines the secondary sexual characteristics of males, hence should be harvested last along with the side locks.^[26] Such an approach gives a more defined look to the patient, that is if the patient wishes to maintain a beard after transplant. However, harvesting can be done from the moustache, chin, and side lock region, if there is additional requirements of grafts as these areas are excellent source of beard grafts. The patient should be counseled that maintaining a beard may not be possible and instead a permanent clean shaven look will be more suitable after transplant. After matching the angle and direction of the beard hair, punches 0.75 to 0.9 mm in diameter are inserted to approximate 2 mm deep to the skin surface to score the grafts. To reduce transection during extraction hypodermic needle can be used for scoring of grafts. The needle tip is used to cut circumferentially around the follicular unit. Then exposed dermal tissue is grasped with the holding forceps and the tip of the needle is used to cut the adhesions of the follicular unit from surrounding dermal tissues under direct magnified vision; following the angle and direction of hair.^[27] Compared to scalp, at places the body tissue is softer or more fluid and manual stretching may not provide the necessary traction before scoring of grafts. To remedy this, the author has developed a unique instrument the KD's spreader that provides adequate stretch with minimal fatigue.^[28]

Other sources of body hair harvesting are the chest, back, legs, thighs, arms, and even axilla and pubic region. Supine, lateral recumbent, and prone positions are suitable for harvesting from chest and back, with change of patients position according to direction of emerging hair follicles and surgeons' preferences. Arm board can be utilized for harvesting from arms [Figures 2-6].

Post procedure

Immediately post procedure the sites of donor hair harvesting on the body are covered with mupirocin skin ointment for up to 7 days; no bandaging is required. Antibiotic cover for upto seven days can be given. After 7 to 10 days post procedure, minoxidil 5% twice daily application has to be started in the recipient scalp area and should be continued for at least one year.

Complications

Hypopigmentation at the extraction site of beard hair may occur especially in darker skin patients; harvesting from under the chin or submandibular region makes this effect less visible [Figure 7]. Keloid formation can occur especially around the sternal area. By avoiding harvesting of follicles from sternal area and ruling out

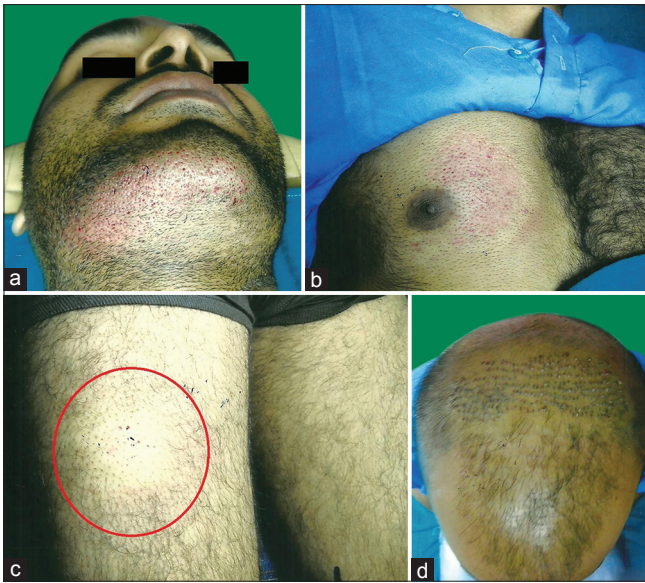

Figure 2: (a) Grafts have been harvested from beard area. (b) Chest area immediately after graft harvesting. (c) Body hair grafts have been harvested from thigh. (d) Body hair grafts harvested from beard, chest, and thighs (a-c) have been implanted into the mid scalp

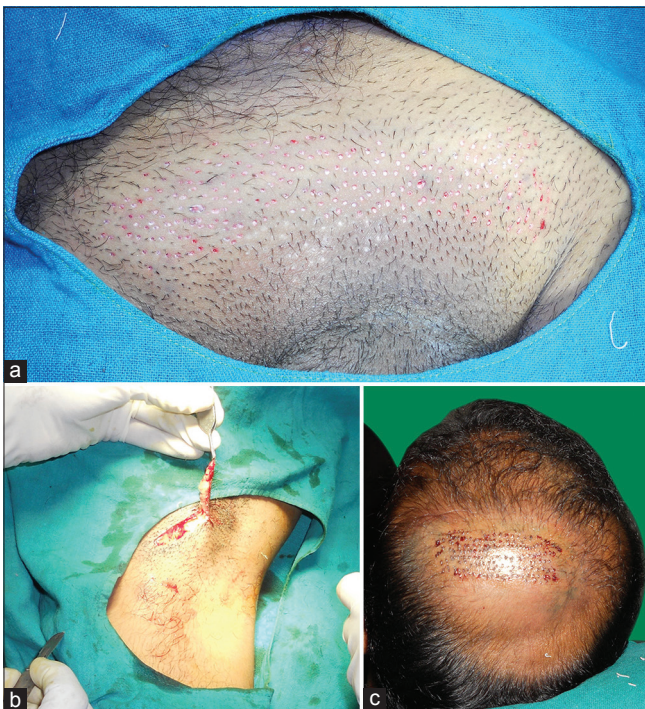


Figure 4: (a) Body hair grafts have been harvested from pubic region. (b) Strip dissection of axillary hair by FUT method, (scar is camouflaged in axillary folds). (c) Harvested pubic and axillary hair grafts implanted in the mid scalp region

keloidal tendencies in history helps in avoiding keloid formation. Often patients who have keloidal tendencies do not present with keloids. Alternately, if planning for chest hair extraction, one can perform few test punches and wait for few weeks to see if keloid develops or not. Other complications that are likely to occur are folliculitis and ingrowing hair due to buried grafts [Figure 8]. Awareness

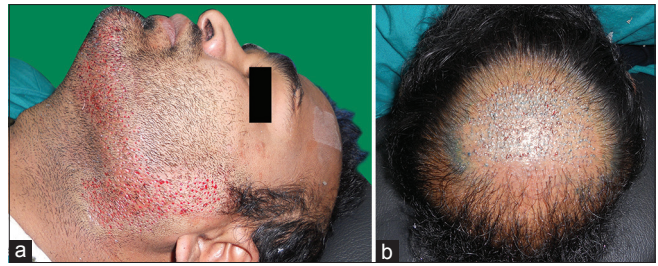


Figure 3: (a) Beard hair grafts have been harvested from mandibular and submandibular area. (b) Beard hair grafts harvested from mandibular and submandibular area implanted in mid scalp and vertex region

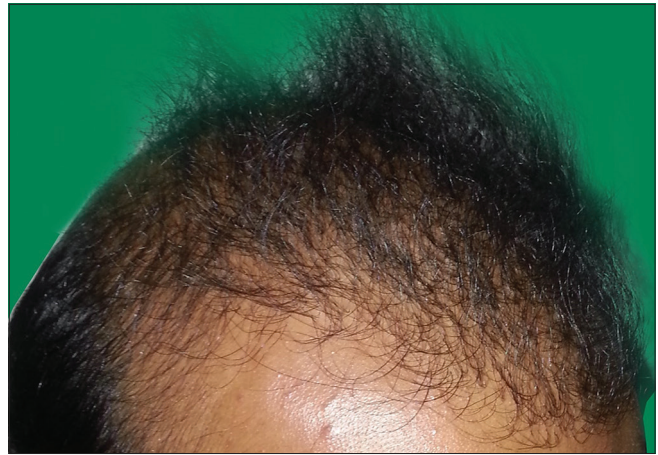

Figure 5: Body hair curls when grows long

of local anatomy especially facial anatomy to avoid motor nerve damage and loss is essential during harvesting in beard areas.

Discussion

Body hair transplant can serve as viable option for hair restoration in select hirsute individuals in advanced cases of androgenetic alopecia who have a limited supply of scalp donor hair.

Harvesting of body hair grafts is slower due to their placement and rapidly changing orientation in different body areas as compared to scalp hair and higher transection rates are observed while harvesting for the same reasons. Body hair transplant requires higher degree of skill to achieve satisfactory results. Lower density of body hair follicles, slower harvesting times, operators' fatigue due to demanding nature of the procedure, anesthesia requirements, and patient discomfort limits the total number of body hair grafts that can be harvested per session. Compared to scalp hair, body hair with the exception of beard is thinner and mostly occurring as singular hair follicles in individual follicular units; consequently more body hair follicular units are required to give a similar density, volume, and coverage in the balding scalp versus scalp hairs. Increased surgeon fatigue due to longer duration and higher skill requirement may also contribute to poor graft yield. In body hair transplant, final yields are lower as compared to

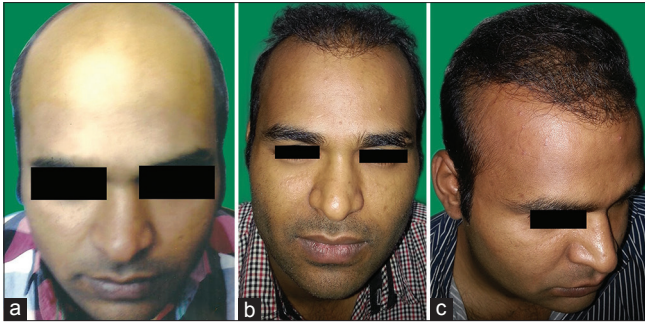

Figure 6: (a) Grade six of Norwood class of androgenic alopecia with poor donor scalp area. (b) & (c) Final result with total of 3500 grafts, (1900 body hair and 1600 scalp grafts) after two years

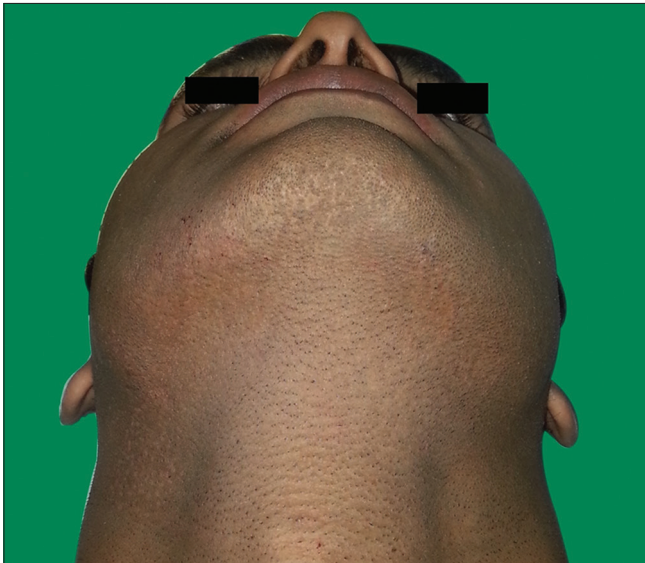

Figure 7: Hypo pigmented scars in the submandibular region at sites of beard hair extraction

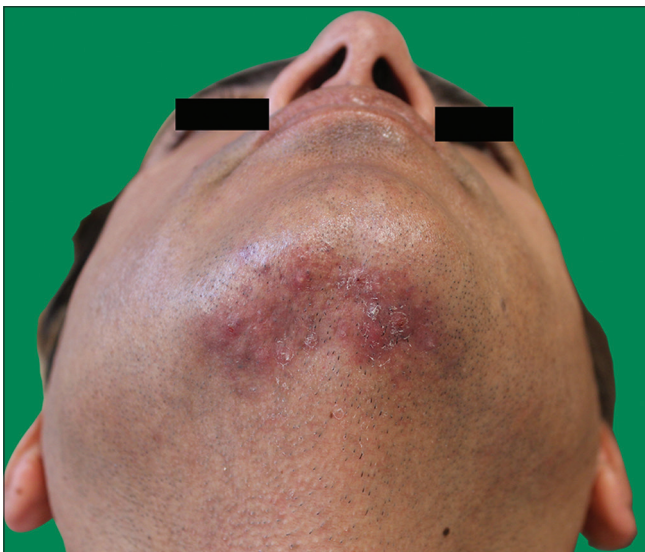

Figure 8: Folliculitis at beard hair extraction sites

scalp hairs.^[8,10] Umar S found that the graft uptake in case of body hairs is between 75–80%, while others mention the

yield between 60 to 80%.^[10,29] In author's experience, while harvesting from beard areas the transection rate is between 10 to 20%, while from chest, pubic region, and legs the transection rates increase to about 20–30%. The author prefers strip dissection with FUT technique in axillary area to improve graft yield, as the resultant scar can be easily camouflaged in the axillary folds. Being a surgical procedure there is always an individual difference in efficacy; however, with more practice the yields are likely to improve. Well counseled patients generally are satisfied with the outcome of this surgical procedure. Umar S in an extensive study of more than 122 patients, found all patients completing the study (63.1%) reported a good assessment of healing, hair growth and high overall satisfaction with the surgical outcome.^[8] The highest scores were given by the patients who in addition to body hairs also utilized head and nape of neck and periauricular hair as donor sources. When beard hair was utilized the patients reported similar degree of satisfaction with result and hair growth when compared to patients in whom scalp hair and hairs from nape and periauricular area were combined. Whereas in the patients where body hairs from areas other than scalp and beard were used (trunk, limbs, axilla, and pubic hair) reported marginally lower scores in terms of donor area healing and growth rates.^[29] There is a requirement of more controlled studies to understand the long-term efficacy and side effects of body hair transplant; with respect to yields, effects of recipient influence on anagen duration, growth rates, and characteristics like length, density, and long-term survival of these transplanted body hairs. There is a need for a scoring system for patient selection based on total graft requirements, availability of quality as well as quantity of donor hair from different body sources to predict a successful outcome. Robert True has presented a scoring system termed Torso Donor Index (TDI) [Table 2].^[30] This evaluates five key patient characteristics of chest hairs: Density, which may be more than 40FU/cm², similarity between scalp and torso hair, proportion of 2–3 hair follicular units, size of the hair bearing area, and length of the torso hair. Where the Torso Donor Index is less than 4, the patient is deemed unsuitable for a body hair transplant, whereas patients with a TDI score of 5–7 may be suitable under certain circumstances. Patients with a score of 8 or more have more body hair than scalp hair suitable as donor material and are therefore suitable candidates for a body hair transplant.

Donor dominance vs recipient influence

The conventional scalp-to-scalp hair transplantation is based on the principle of donor dominance theory as described by Orentreich.^[31] This defines donor dominance as the ability of the transplanted autografts to maintain the integrity and characteristics of donor site after transplantation, independent of the recipient site.^[31] This is beneficial for harvesting donor hair from permanent zone of scalp and transplanting into balding patches in the scalp where the transplanted follicles would grow and continue to provide coverage even if

Table 2: Torso donor index^[30]

	0	1	2	Score
Density	<20 fu/cm ²	20-40 fu/cm ²	>40 fu/cm ²	0-2
Texture	Very different	Somewhat similar	Very similar	0-2
2-3 hair follicular units	<20%	20-30%	>30%	0-2
Surface area	<50 cm ²	50-100 cm ²	>101-200 cm ²	0-2
Hair length	<2 cm	2-5 cm	>5 cm	0-2
Total				0-10

surrounding native follicles undergo miniaturization and fall as the balding process continues. But the hair from different sources of body have different growth cycles, much shorter than the hair cycles of the scalp hair. Accordingly, the body hair transplanted to the scalp will retain their dominant characteristics growing for shorter duration, will be of shorter length producing a mismatch with the scalp hair with respect to characteristics like length, thickness, curls producing a compromised restoration result. However, with regard to body hair transplant it was observed that the recipient dermis influences the body hair growth rate and hair cycle duration to mimic the growth characteristics of the native recipient site hair. This is the concept of recipient influence. According to Hwang *et al.* hair follicles transplanted from the occipital scalp to lower leg took on the hair characteristics of leg hair and partially the same hair reversed their characteristics when transplanted to the nape of the neck.^[32] This is supported by Woods and Campbell, who using chest hair micro grafts transplanted to the scalp showed extended growth and almost 4 times increase in their length to mimic growth characteristics of the native scalp hairs in the crown region.^[33]

In our experience, recipient site influence on body hair is minimal; which concurs with opinion of other surgeons who found no change in the color, curl, or caliber of the transplanted body or beard hair.^[8,34,35] Despite recipient influence of the scalp, these body hairs do not comprehensively match the native scalp hairs in hair cycles and growth characteristics producing a lesser result in comparison to hair restoration utilizing only scalp hair. Being a newer modality the long-term effect of body hair transplant is unpredictable. The patient should be counseled about the likelihood of results being inferior to a conventional scalp-to-scalp hair restoration procedure and a need to have shorter hair styles post-transplant to achieve better cosmetic look. A test patch with limited grafts 200–300 can help the patient to understand these limitations and make a more informed decision before undergoing a complete restoration. It also takes a long time; from one to up to two years to fully appreciate the results of body to scalp hair restoration. Table 3 illustrates limitations of body hair transplant.

Role of platelet-rich plasma

Use of platelet rich plasma (PRP) during and after hair transplant surgery has the potential to act as a bio stimulus to the transplanted hair. PRP is a rich source of anagen-maintaining factors, such as insulin-like growth

Table 3: Limitations of body hair transplant

Limitations of body hair transplant vs conventional scalp FUE

Slower than scalp FUE
 Higher transection rates as compared to scalp FUE
 Higher operator fatigue
 Smaller graft yield per procedure compared to scalp FUE.
 With exception of beard, body hairs are thinner and occur mostly as single hair follicles, hence more grafts are required to achieve the desired density as compared to scalp follicles
 Body hairs do not comprehensively match the native scalp hairs in hair cycles and growth characteristics, producing a lesser result in comparison to hair restoration utilizing only scalp hair

factor 1 (IGF-1), basic fibroblast growth factor (bFGF), and vascular endothelial growth factor (VEGF). Injection of PRP has been demonstrated to improve cutaneous ischemic conditions and to increase vascular structures around hair follicles.^[36] During a study using PRP during hair transplant in 20 male pattern baldness patients, Uebel *et al.* found a considerably significant effect of platelet growth factors on the yield of follicular units over non-PRP used conventional hair transplants.^[37] Such PRP may help to improve yield and achieve quicker results.

Body to scalp hair transplant can also be done in cases of scarring alopecia, to cover cicatricial patches when there is shortage of scalp donor grafts [Figure 9a-d], [Figure 10a and b]. Both secondary as well as primary stable cases of cicatricial alopecia can be selected for hair restoration. While secondary cicatricial alopecia is stable, the primary cicatricial alopecia due to inflammatory conditions like lichen planus, discoid lupus erythematosus, and pseudopelade de Brocq can be unstable. Hence, in case of primary cicatricial alopecia a biopsy along with clinical evaluation is done to confirm diagnosis and check for evidence of disease activity. In primary cicatricial alopecia, the risk of disease reactivation must be counseled to the patient before considering a restoration procedure. Ensure that the disease process has burnt out before the transplant is attempted in all cases of primary cicatricial alopecia; a repeat biopsy to check for inflammatory activity can be done and compared with the previous biopsy. It is generally recommended to wait at least for a period of one year or more with the patient off medications and no signs of disease activity.^[38] One of the precautions to be taken into account when performing a hair transplant on scarred tissue is that the density in units/cm² should be

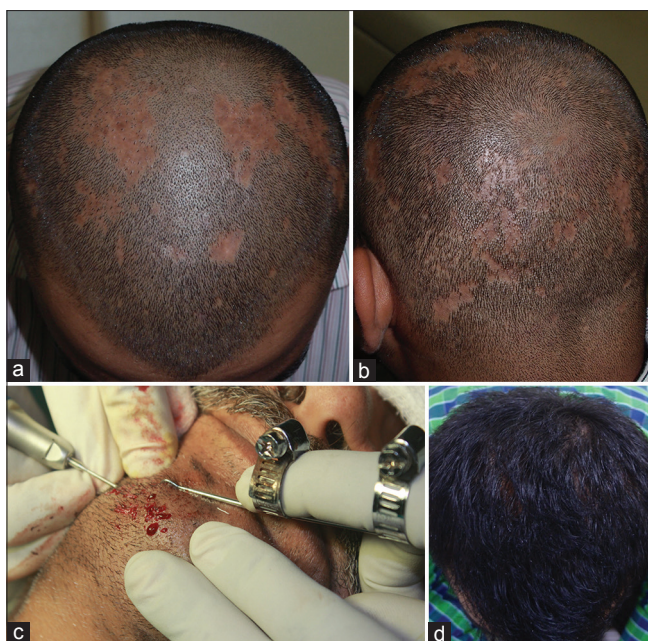

Figure 9: (a) Case of scarring alopecia (lichen planopilaris) with patches involving vertex, temporal, parietal areas. (b) Case of scarring alopecia (lichen planopilaris) with patches involving vertex, occipital areas. (note extensive involvement in safe donor area zone). (c) Harvesting from beard area (lack of adequate scalp donor hair) using KD's spreader for traction. (d) Two years post-transplant grafts from beard as well as scalp at 18 sq. cm² density blend to provide adequate coverage and satisfactory cosmetic result. (total 900 follicular units; 550 from scalp and 350 from beard approximately)

less than that of normal scalp transplant (30–40 units/cm²), because of the risk of follicles competing for the reduced blood flow through the scar tissue.^[39] The success of hair transplantation in cicatricial alopecia is limited by various reasons like disproportionate donor-recipient area ratio, decreased survival of hair grafts in scarred area due to compromised vascular supply, and relapses of the disease process leading to new areas of scarring alopecia.^[40] Pretreatment with minoxidil 5% started at least 15 days prior and continued up to a year afterwards can be done with the aim to improve vascularity and improve graft yield. It is prudent to do a test grafting in a limited area in cicatricial alopecia to check for successful uptake and survival of grafts; as well as disease activity in case of primary cicatricial alopecia before undertaking the complete restoration procedure. Multiple procedures may be required to achieve cosmetically acceptable results in cases of cicatricial alopecia. Cases of cicatricial alopecia with extensive large patches and near complete absence of surrounding normal scalp hair to provide camouflage are poor candidates for hair restoration as it is difficult to achieve the required density due to unpredictable nature of vascularity in scarred tissue.

Practical consideration and tips

Initially, while harvesting from the body, each scoring incision must be followed by extraction for the first

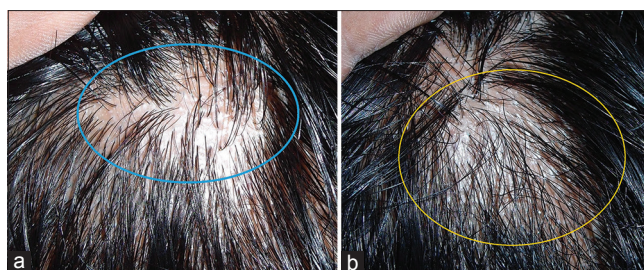


Figure 10: (a) Two years post-transplant patch of scarring alopecia (same patient as figure 9) with transplanted scalp hairs; observe that transplanted scalp hairs grow straight and resemble the surrounding native scalp hair. (b) Two years post-transplant patch of scarring alopecia with transplanted beard hairs; observe that beard hairs are thicker, curlier, and are distinguishable from the native scalp hair

few grafts; this enables the operating physician to determine the body hair characteristics like depth, angle, and intradermal course (curl) of the follicle and make appropriate adjustments to the scoring method to minimize trauma and transection. It is prudent to follow this practice at regular intervals even while harvesting from the same body region as body hairs have a tendency to frequently change their orientation. Transplanted body hair has a tendency to curl after growing to a certain length and will not completely match the native scalp hair in thickness, growth rate, and hair cycle. When such body hair is transplanted in symmetric grouped pattern on the scalp, it produces a mosaic unnatural look which can be easily distinguished from native scalp hair. Body hair should be mixed with existing scalp hair to produce a more blended cosmetically acceptable look. Mixing body hairs from different sources like beard, chest, and extremities helps to achieve this blended natural look when transplanting completely bald areas on scalp. As the transplanted body hair grows shorter than scalp hair with exception of beard hair, which has a tendency to curl, the patient can opt for shorter hairstyles to produce a better cosmetic result.^[29] Alternatively, if the patient desires longer hair styles then grooming of body hair and straightening of body hair using iron and straighteners can be done to try and match the scalp hair.^[17] Avoid transplanting thick beard hair grafts in hairline and temple region to avoid an unnatural appearance in these fine hair regions. Body hairs from legs and arms are finer and shorter compared with hair from the scalp donor area, and these are suitable for hairlines and temple areas producing a softer and natural final appearance. They are also suitable for the repair of previously transplanted harsh hairlines. Planning should include identification of the donor hair sources, approximately how many grafts are needed from each source and plotting where the donor hair will be transplanted. A team effort with surgeon and assistants working in co-ordination, taking breaks at frequent intervals with stretching exercises helps in reducing surgeon fatigue. Practical tips for body hair transplant are listed in Table 4.

Table 4: Practical tips for body hair transplant**Tips**

Transplant a mixture of hair from different body sites as well as scalp donor sources to create a more blended natural look.
 Shorter hairstyles or grooming of transplanted body hair if desirous of longer hairstyles.
 Beard hair being thicker is excellent to create optical density
 Finer and shorter hair from arms and legs is suitable for hairlines and temples.
 Check at periodic intervals for body hair graft transection and adjust method accordingly.

Conclusion

Harvesting of body hairs is more time consuming and requires a higher level of skill in comparison with conventional FUE done for scalp hairs. While yields from body hair transplant are lower compared to conventional scalp transplants, body hair offers a viable source of donor hair follicles in hirsute individuals for hair restoration. Beard hair is easiest to harvest and provides high optical density in the transplanted area. Body hair transplant tends to produce a inferior result as compared to the conventional scalp FUE, and this should be counseled to the patient along with the need for shorter hairstyles or grooming for better results. If used judiciously, either alone or in combination with scalp hair, it can produce aesthetically acceptable results especially in advanced grades of alopecia with lack of adequate scalp grafts. Body hair can also be utilized for softening the hairlines and camouflage scars from previous surgeries or disease process. As recipient influence on body hairs is minimal and they retain most of their native characteristics, implant body hairs in planned manner mixing with scalp hairs in the implanted area to produce a more cosmetically acceptable result. FUE using body hair can be an effective hair transplantation method for select hirsute individuals who suffer from severe baldness or have inadequate scalp donor reserve.^[29]

Declaration of patient consent

The authors certify that they have obtained all appropriate patient consent forms. In the form the patient(s) has/have given his/her/their consent for his/her/their images and other clinical information to be reported in the journal. The patients understand that their names and initials will not be published and due efforts will be made to conceal their identity, but anonymity cannot be guaranteed

Financial support and sponsorship

Nil.

Conflicts of interest

There are no conflicts of interest.

References

1. Unger W, Solish N, Giguere D, Bertucci V, Coleman W, Loukas M, *et al.* Delineating the safe donor area for hair transplanting. *J Am Acad Cosmet Surg* 1994;4:239-43.
2. Rassman WR, Harris JA, Bernstein RM. Follicular Unit Extraction. In: Haber RS, Stough DB, editors. *Hair Transplantation*. Philadelphia USA: Elsevier Saunders; 2006. pp. 133-7.
3. Williams KL. Current Practices and Controversies in Cosmetic Hair Restoration. *Dermatol Surg* 2013;39:797-801.
4. Inaba M. Androgenetic alopecia: Modern concepts of pathogenesis and treatment. *Jpn J Dermatol Urol* 1996;238-45.
5. Rassman WR, Bernstein RM, McClellan R, Jones R, Worton E, Uyttendaele H. Follicular unit extraction: Minimally invasive surgery for hair transplantation. *Dermatol Surg* 2002;28:720-8.
6. Okuda S. Clinical and experimental studies of transplantation of living hairs. *Jpn J Dermatol Urol* 1939;46:135-8.
7. Hirai T, Inoue N, Nagamoto K. Potential use of beards for single-follicle micrografts: Convenient follicle-harvesting technique using an injection needle. *Ann Plast Surg* 2001;47:37-40.
8. Umar S. Use of body hair and beard hair in hair restoration. *Facial Plast Surg Clin North Am* 2013;21:469-77.
9. Saxena K. Body Hair FUE. In: Saxena K, Saxena D, editors. *FUE hair restoration major procedures minor incisions*. Gwalior India: Cosmazone Pvt Limited; 2012. pp. 169-73.
10. Mahadevia B. Donors Other Than Scalp: Beard and Chest. In: Mysore V, editors. *Hair Transplantation*. New Delhi India. Jaypee Brothers Medical Publishers (P) Ltd; 2016. pp. 307-12.
11. Saxena K, Saxena DK, Savant SS. Successful Hair Transplant Outcome in Cicatricial Lichen Planus of the Scalp by Combining Scalp and Beard Hair Along With Platelet Rich Plasma. *J Cutan Aesthet Surg* 2016;9:51-5.
12. Meyer-Gonzalez T, Bisanga C. Body-hair transplant for cicatricial alopecia. *Actas Dermosifiliogr* 2012;103:163-5.
13. Paus R, Cotsarelis G. The biology of hair follicles. *N Engl J Med* 1999;341:491-7.
14. Saitoh M, Uzuka M, Sakamoto M. Human hair cycle. *J Invest Dermatol* 1970;54:65-81.
15. Randall VA. Androgens and human hair growth. *Clin Endocrinol (Oxf)* 1994;40:439-57.
16. Tolgyesi E, Coble DW, Fang FS, Kairinen EO. A comparative study of beard and scalp hair. *J Soc Cosmet Chem* 1983;34:361-82.
17. Saxena K. Body hair mismatch. *ISHRS annual scientific meet*. Malaysia: 2014.
18. Richards RN, Uy M, Meharg G. Temporary hair removal in patients with hirsutism: A clinical study. *Cutis* 1990;45:199-202.
19. Lepselter J, Elman M. Biological and clinical aspects in laser hair removal. *J Dermatolog Treat* 2004;15:72-83.
20. Umar S. The transplanted hairline: Leg room for improvement. *Arch Dermatol* 2012;148:239-42.
21. Poswal A. The preshaving protocol in body hair-to-scalp transplant to identify hair in anagen phase. *Indian J Dermatol* 2010;55:50-2.
22. Messenger AG, Rundegren J. Minoxidil: Mechanisms of action on hair growth. *Br J Dermatol* 2004;150:186-94.
23. Nurein H, Mohanty S. Anesthesia in FUE. In: Saxena K, Saxena D, editors. *FUE hair restoration major procedures minor incisions*. Gwalior India: Cosmazone Pvt Limited; 2012. pp. 47-52.
24. Behroozan DS, Goldberg LH. Dermal tumescent local anesthesia in cutaneous surgery. *J Am Acad Dermatol* 2005;53:828-30.
25. Mysore V. Body hair transplantation: Case report of successful

- outcome. *J Cutan Aesthet Surg* 2013;6:113-6.
26. Yu J, Yu A. Beard to scalp. In: Unger W, Shapiro R, Unger R, Unger M, editors. *Hair transplantation*. 5th ed. New York:Informa Healthcare; 2011. pp. 299-303.
 27. Poswal A. Expanding needle concept for better extraction of body hair grafts. *Indian J Dermatol* 2013;58:240.
 28. Saxena K. KD Spreader a slit dilating device. 24th ISHRS world congress of hair restoration surgery, LasVegas, USA; 2016.
 29. Umar S. Body Hair Transplant by Follicular Unit Extraction: My Experience With 122 Patients. *Aesthet Surg J* 2016;36:1101-10.
 30. True R. FUE from the Beard and Body. In: Lam S, Williams K, editors. *Hair Transplant: Follicular Unit Extraction*. 11th ed. Vol. 4. New Delhi India Jaypee Brothers Medical Publishers (P) Ltd; 2016. pp. 417-34.
 31. Orentreich N. Autografts in alopecias and other selected dermatological conditions. *Ann N Y Acad Sci* 1959;83:463-79.
 32. Hwang S, Kim JC, Ryu HS, Cha YC, Lee SJ, Na GY, *et al.* Does the recipient site influence the hair growth characteristics in hair transplantation? *Dermatol Surg* 2002;28:795-8.
 33. Woods R, Campbell AW. Chest hair micrografts display extended growth in scalp tissue: A case report. *Br J Plast Surg* 2004;57:789-91.
 34. Poswal A. Use of body and beard donor hair in surgical treatment of androgenic alopecia. *Indian J Plast Surg* 2013;46:117-20.
 35. Harris JA. Follicular unit extraction. *Facial Plast Surg* 2008;24:404-13.
 36. Li ZJ, Choi HI, Choi DK, Sohn KC, Im M, Seo YJ, *et al.* Autologous platelet-rich plasma: A potential therapeutic tool for promoting hair growth. *Dermatol Surg* 2012;38:1040-6.
 37. Uebel CO, da Silva JB, Cantarelli D, Martins P. The role of platelet plasma growth factors in male pattern baldness surgery. *Plast Reconstr Surg* 2006;118:1458-66.
 38. Unger W, Unger R, Wesley C. The surgical treatment of cicatricial alopecia. *Dermatol Ther* 2008;21:295-311.
 39. Kutlubay Z, Murat K, Engin B. Hair transplantation in the cicatricial alopecias. *Hair Ther Transplant* 2013;3:2167-951.
 40. Dogra S, Sarangal R. What's new in cicatricial alopecia? *Indian J Dermatol Venereol Leprol* 2013;79:576-90.