



Contents lists available at ScienceDirect

International Journal of Surgery Case Reports

journal homepage: www.casereports.com

Giant epidermoid cyst in the breast: A common benign lesion at a rare site—A case report



Mayin Uddin Mahmud*, Sayera Banu Sheuly, Nur Hossain Bhuiyan, Rana Chowdhury, Ramjan Ali

Chittagong Medical College Hospital, Bangladesh

ARTICLE INFO

Article history:

Received 3 March 2017

Received in revised form 6 May 2017

Accepted 7 May 2017

Available online 22 May 2017

Keywords:

Giant epidermoid cyst

Breast lump

Case report

ABSTRACT

INTRODUCTION: Epidermoid cyst is a common clinical entity and it can occur anywhere in the body. But its occurrence and huge size in the breast is very rare and more liable to develop complications, including malignant transformation.

PRESENTATION OF CASE: We present here an unusual case of a giant epidermoid cyst in the breast, which is about 7 cm in greatest dimension. After proper preoperative diagnosis by clinical, imaging and histopathological findings, it was managed by total excision.

DISCUSSION: Imaging and fine needle aspiration cytology is essential for accurate preoperative diagnosis. However, it is often very difficult to differentiate it from other benign and malignant conditions of breast. Infection and malignant transformation are its potential complications. Total excision along with its capsule is the treatment of an epidermoid cyst.

CONCLUSION: Epidermoid cyst is an important differential diagnosis while managing benign breast disease.

© 2017 The Author(s). Published by Elsevier Ltd on behalf of IJS Publishing Group Ltd. This is an open access article under the CC BY-NC-ND license (<http://creativecommons.org/licenses/by-nc-nd/4.0/>).

1. Introduction

Epidermoid cyst (also known as epidermal inclusion cyst, keratin cyst) is a retention cyst of sebaceous gland, derived from the infundibulum of the hair follicle or traumatic inclusion. These are lined with true stratified squamous epithelium. They are often found on hairy areas of the body such as scalp, trunk and face. Epidermoid cysts >5 cm in diameter are called giant epidermoid cysts, which are rare and more prone to develop complications like malignant transformation.

Epidermoid cyst in the breast is very rare. It poses a clinical dilemma to differentiate it from other benign breast conditions. Imaging and fine needle aspiration cytology is therefore essential for accurate preoperative diagnosis. Excision of the cyst in its entirety is recommended to avoid potential complications. We present here a case of giant epidermoid cyst in the breast, which is the largest epidermoid cyst in the breast reported so far. This patient was diagnosed and managed in Chittagong Medical College Hospital, a tertiary academic hospital in Bangladesh. This case report is compiled and adopted according to the Surgery Case Report (SCARE) guidelines [1].

2. Case Report

A 35 year old lady presented in the Surgery Outpatient Department of Chittagong Medical College Hospital with complains of painless swelling in her left breast. She noticed a small swelling in her left breast 3 years back, which gradually increased in size to reach the present size. There was no history of trauma, fever, nipple discharge or any surgery in the breast. Her menstrual history is normal. She has three children and all the children were habituated in breastfeeding. The patient does not take hormonal contraceptive and any other drug relevant to this disease. Family history and personal history were insignificant.

On examination, all her vital signs were found within normal limit. A large lump was palpable in lower outer quadrant of her left breast. The surface of the lump was smooth and it was soft in consistency. Fluctuation was negative. The lump was not fixed to overlying skin or underlying tissues and did not have any punctum. The left nipple was normal. Axillary and Supraclavicular lymph nodes on both sides were not palpable. Right breast was normal.

Ultrasonogram of the left breast showed a well circumscribed hypoechoic solid mass, measuring about 6.19 × 5.46 cm in 3–5 O'clock position of left breast (Fig. 1). Fine needle aspiration cytology (FNAC) revealed scattered anucleated squamous cells in a necrotic background and no Epitheloid or malignant cell was seen. As ultrasonogram findings and cytology reports were indicative of epidermoid cyst, mammogram was not done.

* Corresponding author.

E-mail address: Hospitaldr.mayin@gmail.com (M.U. Mahmud).

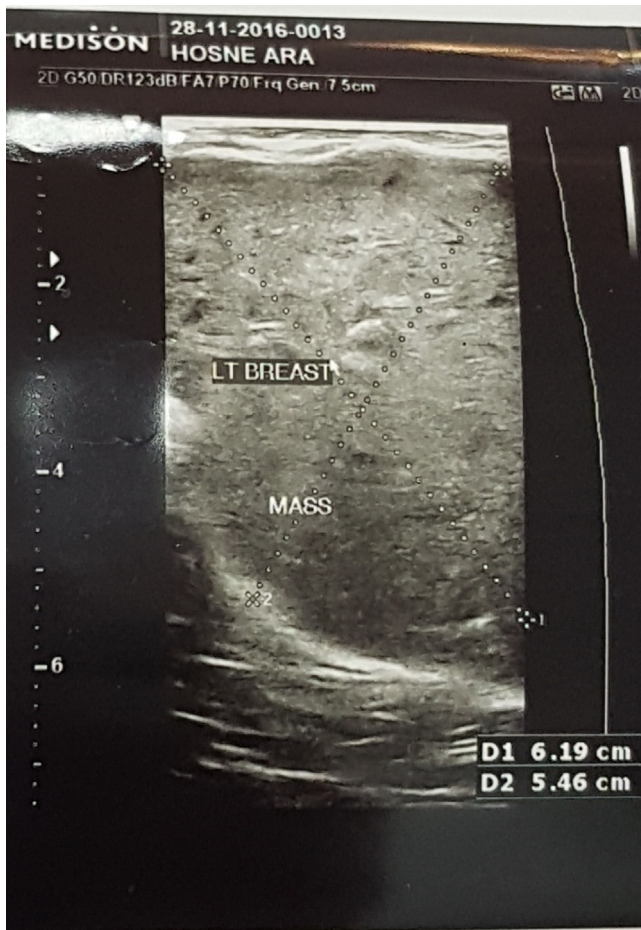


Fig. 1. USG image of the breast lump showing a large solid mass in left breast (Attached).

Thorough preoperative check up was normal. A provisional diagnosis of epidermoid cyst in the left breast was made and the patient was prepared for excisional biopsy under local anaesthesia on the next available date as day care surgery. It took 14 days after the patient presented in the outpatient department to operation.

An elliptical incision was given at the maximum bulging and total excision of lump along with its capsule was done (Figs. 2 and 3). Skin was closed with interrupted stitches by 4-0 Polypropylene suture for better infra-mammary scar. Post operative period was uneventful. Histopathological examination confirmed its nature as epidermoid Cyst. The patient was followed up after 1 month and 3 months. The scar was healthy and there was no recurrence. She is scheduled for further follow up after 6 months.

3. Discussion

Epidermoid cyst refers to the cysts that result from proliferation and implantation of epidermal elements within a circumscribed space in the dermis [2]. Such cysts can occur anywhere in the body, though they are more common in head and neck region, trunk and extremities [3].

Epidermoid cyst in the breast is an uncommon benign condition [4]. To the date, very few reports of epidermal cysts in the breasts are published in the literature [4–6]. Fewer than 40 cases of epidermal inclusion cyst in the breast have been reported [7].

The exact pathogenesis of the cyst arising in the breast is poorly understood. Few theories regarding their aetiology have

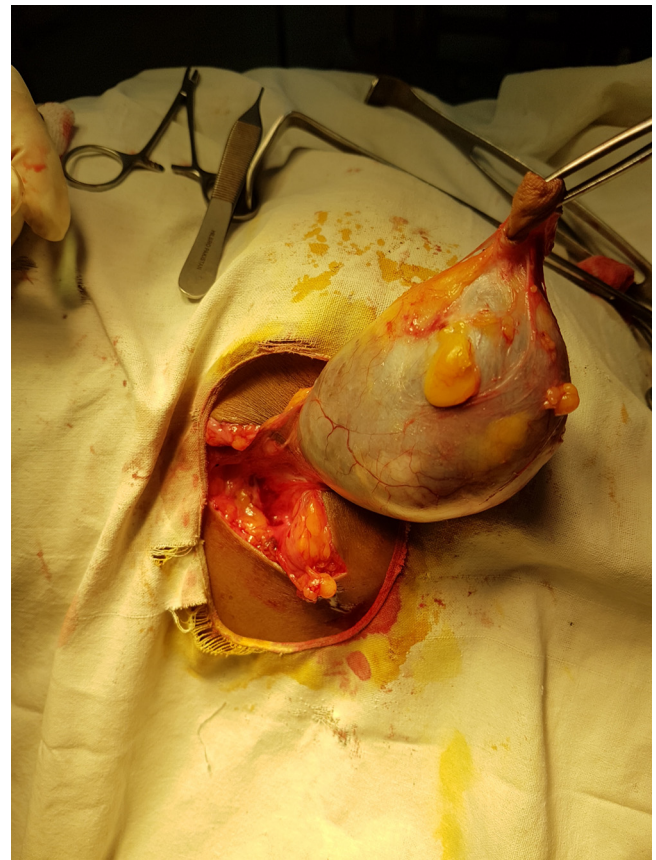


Fig. 2. Per operative image showing excision of the cyst along with its capsule (Attached).

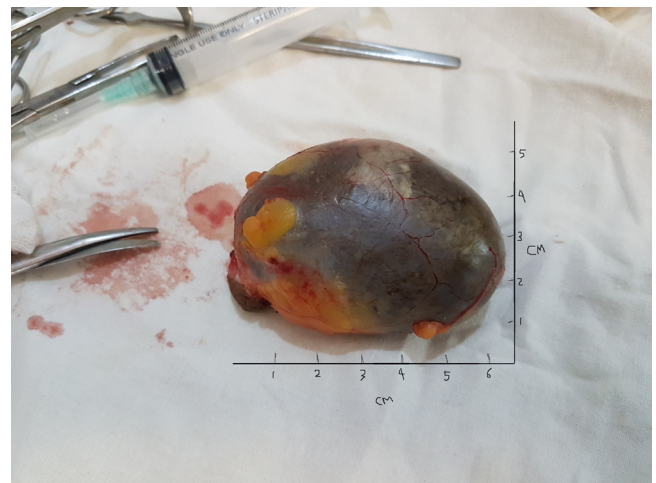


Fig. 3. Excised cyst, measuring about 7 × 5 cm (Attached).

been reported: (i) Damage to epidermis which gets implanted deep within the breast tissue and it may occur after trauma, reduction mammoplasty and needle biopsy. (ii) Progressive cystic ectasia of the infundibulum of hair follicles. (iii) Squamous metaplasia of normal columnar cells within a duct in fibroadenoma, fibrocystic change or Phyllodes tumor. (iv) Congenital inclusions along the lines of embryonic closure [8]. In our study, the mechanism appears to be obstruction of hair follicle or congenital inclusions along the lines of embryonic closure, as there was no history of previous trauma, surgery or lump in the breast.

Clinically, epidermoid cyst at other sites present as firm nodular protrusion from the skin. But in case of breast, the lesion often grows deep inside the subcutaneous tissue of the breast because it has flexible fat and mammary gland tissue under the skin. On Ultrasonography, it appears as solid, circumscribed and complex mass [9]. Epidermoid cysts in the breast are often confused clinically and radiologically with different benign and malignant lesions of the breast and accurate preoperative diagnosis may be difficult [4,9]. On histopathological examination, epidermal inclusion cysts are characterized by a lining of stratified squamous epithelium containing agranular layer [3].

Giant epidermoid cysts are rarely seen in surgical practice [10]. The largest epidermoid cyst of size 17.8 × 13.8 × 5.8 cm on gluteal region is reported [3]. While in breast the largest epidermoid cyst reported was 3.1 × 2.3 cm [4]. In another case series, the range of epidermoid cyst in the breast was reported as 0.5–1.5 cm [2]. In our case, the size of the epidermoid cyst in the breast was 6.19 × 5.46 cm.

Infection and malignant transformation are the potential risk in epidermoid cyst. Infection may lead to pain and spontaneous rupture. Malignant transformation of the cyst wall epithelium occurs very rarely (0.045%) [11].

Treatment of uncomplicated epidermoid cyst is total excision along with its capsule by an elliptical incision, encircling the punctum [3].

Therefore, excision of all epidermoid cysts in the breast is usually recommended for definitive histopathological diagnosis and so to exclude a malignant lesion with benign features and to prevent the potential complications like infection and malignant transformation [4].

4. Conclusion

Giant epidermoid cyst in the breast is rare clinical entity and is more prone to develop into complications including malignancy. We have presented here a giant epidermoid cyst in the breast, where its successful excision was done, one of the few cases presented till date.

Author contribution

1. Dr. Mayin Uddin Mahmud—Chief operating surgeon, writer of the paper.
2. Dr. Sayera Banu Sheuly—Surgery Assistant.
3. Dr. Nur Hossain Bhuiyan—Study design.
4. Dr. Rana Chowdhury—Surgery Assistant.
5. Dr. Md. Ramjan Ali—contributors.

Funding

None.

Ethical approval

No ethical approval.

Conflicts of interest

No conflict of interest.

Consent

Written informed consent was obtained from the patient for publication of this case report and accompanying images. A copy of the written consent is available for review by the Editor-in-Chief of this journal on request.

Guarantor

Dr. Mayin Uddin Mahmud.

References

- [1] R.A. Agha, A.J. Fowler, A. Saetta, I. Barai, S. Rajmohan, D.P. Orgill, for the SCARE group, The SCARE statement: consensus-based surgical case report guidelines, *Int. J. Surg.* 34 (2016) 180–186.
- [2] S. Meeta, M. Barkha, J. Shyama, Epidermal inclusion cyst in breast: is it so rare? *J. Cytol.* 29 (3) (2012) 169–172.
- [3] M.T. Houdek, J.A. Warneke, C.M. Pollard, E.A. Lindgreen, M.S. Taljanovic, Giant epidermal cyst of the gluteal region, *Radiol. Case Rep. (online)* 5 (2010) 476.
- [4] S.Y. Lam, J.J. Kasthoori, K.S. Mun, K. Rahmat, Epidermal inclusion cyst of the breast: a rare benign entity, *Singapore Med. J.* 51 (12) (2010) 191–194.
- [5] K. Kapila, K. Verma, Fine needle aspiration cytology of epidermal inclusion cysts in the male breast, *Acta Cytol.* 47 (2003) 315–317.
- [6] D.K. Das, T.A. Junaid, S.B. Mathews, et al., Fine needle aspiration cytology diagnosis of male breast lesions. A study of 185 cases, *Acta Cytol.* 39 (1995) 870–876.
- [7] N. Taira, K. Aoji, S. Ohsumi, et al., Epidermal inclusion cyst of the Breast, *Breast Cancer* 14 (2007) 434–437.
- [8] S.S. Chandanwale, A.C. Buch, H. Kumar, N. Mishra, Epidermoid cyst in the breast: a common benign lesion at a rare site, *Clin. Cancer Investig. J.* 4 (2015) 99–101.
- [9] P. Crystal, R. Shaco-Levy, Concentric rings within a breast mass on sonography: lamellated keratin in an epidermoid inclusion cyst, *Am. J. Roentgenol.* 184 (2005) s47–8.
- [10] O. Solak, K. Tunay, N.T. Haktanir, K. Ocalan, H. Esme, C. Tokyo, Giant epidermoid cyst in the sternum region, *Thorac. Cardiovasc. Surg.* 56 (4) (2008, Jun) 243–245.
- [11] D.S. Cameron, R.L. Hilsinger, Squamous cell carcinoma in an epidermal inclusion cyst: case report, *Otolaryngol. Head Neck Surg.* 129 (2003) 141–143.

Open Access

This article is published Open Access at sciedirect.com. It is distributed under the [IJSCR Supplemental terms and conditions](#), which permits unrestricted non commercial use, distribution, and reproduction in any medium, provided the original authors and source are credited.