

Letters to the Editor

Liquoral liquid biopsy in neoplastic meningitis enables molecular diagnosis and mutation tracking: a proof of concept

Key words: cell-free DNA | cerebrospinal fluid | liquid biopsy | metastasis | neoplastic meningitis | plasma

Cerebrospinal fluid (CSF) is a potential source of tumor-derived DNA in patients with primary or secondary CNS tumors. Selected mutations in CSF circulating tumoral cell-free DNA (cfDNA) have been identified by PCR detection techniques, and more recently panels of genes have been assessed by targeted next-generation sequencing.^{1,2}

As a matter of fact, different clinically validated platforms for mutational analysis with distinct analytical sensitivities are currently available in routine diagnostic practice. In our study we tracked the mutational repertoire in 2 cases of leptomeningeal metastatic disease in synchronous samples of circulating cfDNA derived from plasma and CSF using the mass spectrometry technology Sequenom MassARRAY and fast COLD-PCR followed by Sanger sequencing.

In Case 1, a 58-year-old male presenting with progressive hearing loss was diagnosed with a multifocal moderately differentiated lung adenocarcinoma with a right temporal brain metastatic lesion. Following metastasis resection and whole-brain radiation therapy, pulmonary lobectomy with lymphadenectomy was performed. Before further treatments the patient developed neoplastic meningitis with nodular lumbar enhancement on MRI without recurrence at the previous supratentorial metastatic site. CSF and plasma samples were obtained from the patient, and intrathecal chemotherapy with liposomal cytarabine was started. In the following weeks the patient's performance status quickly deteriorated and death occurred 7 months after the initial diagnosis.

The patient in Case 2 was a 64-year-old female who presented with headache, vertigo, and drowsiness. CT and MRI demonstrated a right hemispheric cerebellar contrast-enhancing lesion diagnosed after resection as a lung adenocarcinoma metastasis. Staging assessments identified a lung neoplasm in the superior left lobe associated with mediastinal lymphadenopathies. Following neoadjuvant chemotherapy, pulmonary lobectomy with lymphadenectomy was performed, thus

confirming a poorly differentiated lung adenocarcinoma. After 6 months, multiple cerebellar metastases developed and were treated with radiotherapy, obtaining a partial response. Three months later, symptoms suggestive for neoplastic meningitis were confirmed by MRI (infratentorial leptomeningeal nodules). Intrathecal chemotherapy with liposomal cytarabine was started; however, due to poor patient performance this treatment was stopped in favor of palliative care.

In both cases, DNA was extracted from the tumor resection specimen and from synchronous samples of plasma obtained from peripheral blood and of CSF obtained from a lumbar puncture performed before starting intrathecal chemotherapy.

First, we carried out Sequenom using the Lung Status kit, which identifies the main nucleotide substitutions affecting *EGFR* and *KRAS* in lung adenocarcinoma and explores mutations at multiple codons of other relevant genes. The primary tumors of Case 1 and Case 2 harbored a p.G13C (c.37G>T, Fig. 1A) and a p.G12F (c.34_35delGGinsTT, Supplementary Fig. 1A) *KRAS* mutation, respectively. These *KRAS* mutations were absent in plasma but detectable in CSF cfDNA (0.02% vs 66.4% for Case 1, Fig. 1B–C; 0.02% vs 45% for Case 2, Supplementary Fig. 1B–C).

To explore the G>A or G>T *KRAS* mutations at codons 12/13 with higher analytical sensitivity than Sequenom, we then assessed all samples by fast COLD-PCR followed by Sanger sequencing. The DNA quantities were all comprised in a range of absolute reproducibility to detect a heterozygous mutation.³ The p.G13C as well as the p.G12F *KRAS* mutations identified by Sequenom were detected by fast COLD-PCR in tissue and in CSF-derived DNA (Fig. 1D, F; Supplementary Fig. 1D, 1F), while no *KRAS* mutations were identified in plasma (Fig. 1E and Supplementary Fig. 1E).

Finally, we measured the extent of DNA fragmentation by calculating a ratio between the concentrations of 247/115 bp real-time PCR-amplified products, suggestive of apoptosis or necrosis for ratios tending to 1 or 0, respectively.⁴ The ratios observed in plasma and CSF samples (51% vs 35% for Case 1 and 100% for both in Case 2) indicate a heterogeneous degree of apoptosis in the samples, confirming there is no consensus on the origin of the cfDNA (necrosis vs apoptosis).^{5,6}

One may argue that we could not detect the *KRAS* mutation in plasma cfDNA due to the analytical sensitivity of our sequencing platform. For *KRAS* mutations the limit of detection estimated for Sequenom is near 5%, provided that a DNA input not below 1 ng is available. Notably, only the DNA inputs from CSF were below the cutoff (0.8 ng for Case 1 and 0.022 ng for Case 2), nevertheless we detected the mutation in these samples with a mutant allele frequency much higher than the sensitivity cutoff of 5% (ie, 66% for Case 1 and 45% for Case 2). Most importantly, no *KRAS* mutations were identified in plasma cfDNA even when analyzed with a 50-fold more sensitive detection method (fast COLD-PCR).

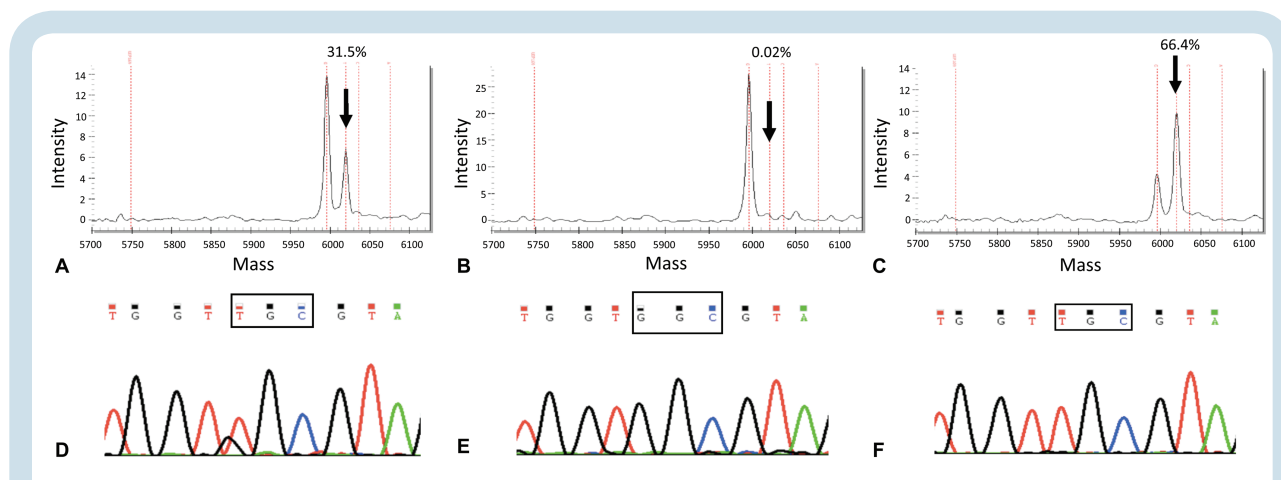


Fig. 1 Detection of DNA alterations in the tumor tissue and in liquid biopsies of Case 1. The *KRAS* mutation c.37G>T, pG13C was diagnosed by Sequenom (Myriapod Lung Cancer kit, Diatech Pharmacogenetics) in the tumor resection sample (A); the estimated mutant allele frequency was 30% (arrow), suggesting a homozygous *KRAS* mutation, since the tumor cell content in the selected tumor area accounted for about 30%. The same driver mutation was not detected in plasma cfDNA samples (B), but was identified in CSF (C). The mutant allele frequency of >50% found in the CSF sample (arrow) suggested a likely homozygous pattern, in a way akin to the primary tumor. The highly sensitive fast COLD-PCR assay detected the same mutation in the tissue sample (D), confirming also the negativity of plasma (E) and positivity of CSF (F), using DNA input comprised in the range of absolute assay reproducibility.³

Our results provide another line of evidence that cfDNA derived from metastatic deposits in the brain with clinical features of meningeal carcinomatosis is more abundant in CSF compared with plasma. This is a phenomenon likely mediated by the intimate contact of CSF with tumor cells and by the compartmentalization of CSF from plasma due to the blood–brain barrier. Although accrued only in 2 patients, our data are the first to suggest that the relative enrichment of CSF in tumoral cfDNA compared with plasma can reliably allow for comprehensive sequencing of a panel of genes by Sequenom MassARRAY in a way akin to targeted panels of massively parallel sequencing. In addition, a second-level analysis of specific *KRAS* mutations by fast COLD-PCR followed by Sanger sequencing can be employed to guarantee a higher enrichment of specific mutant alleles with G>T or G>A substitutions.

Taken together, these results corroborate the notion that CSF likely represents a preferable source of representative liquid biopsy in brain metastatic lesions featuring meningeal carcinomatosis, at least when no extra-CNS localizations are evident. Liquoral liquid biopsies can help monitor changes in metastatic deposits in the CNS and may complement the diagnosis of meningeal carcinomatosis.² Although a lumbar puncture is a more invasive procedure than a blood draw, the possible lack of representative tumoral cfDNA in the plasma may delay molecular diagnosis or lead to nonconclusive results in this delicate subset of patients. Otherwise, liquoral liquid biopsy can allow the identification of either actionable genetic alterations or a mutation correlated to resistance to targeted therapies leading to crucial changes in the treatment decision making.

In both of the presented cases the detected mutations were not strictly propaedeutic to tailor patient treatment (ie, not actionable); however, in lung cancer patients *KRAS* mutations have been (i) repeatedly implicated as markers of poor prognosis^{7,8} and (ii) shown to significantly correlate with brain metastatic disease.⁹ Finally, since preclinical

evidence suggests the existence of at least 2 subgroups of mutant *KRAS* lung tumors with distinct genetic/metabolic signatures and unique therapeutic susceptibilities assessable on the basis of their relative mutant allelic content,¹⁰ combined quantitative and qualitative *KRAS* locus assessment may hold both prognostic and therapeutic usefulness.

Supplementary Material

Supplementary material is available online at *Neuro-Oncology* (<http://neuro-oncology.oxfordjournals.org/>).

Funding

This work was supported by the Italian Association of Cancer Research (AIRC, MFAG13310 to C.M.), the Ministry of University (ex 60% and 2015HAJH8E to C.M. and ex-60% P.C.) and Rete Oncologica Piemonte e Valle d'Aosta (to P.C.).

Conflict of interest statement. None to declare.

Caterina Marchiò, Sara Mariani, Luca Bertero, Cristiana Di Bello, Paola Francia Di Celle, Mauro Papotti, Roberta Rudà, Riccardo Soffietti, and Paola Cassoni

Department of Medical Sciences, University of Turin, Turin, Italy (C.M., S.M., L.B., P.C.); Pathology Division,

Azienda Ospedaliera Universitaria Città della Salute e della Scienza di Torino, Turin, Italy (C.M., S.M., C.D.B., P.F.D.C., M.P., P.C); Department of Oncology, University of Turin, Turin, Italy (M.P.); Department of Neuro-Oncology, Azienda Ospedaliera Universitaria Città della Salute e della Scienza di Torino, Turin, Italy (R.R., R.S.); Department of Neurosciences, University of Turin, Turin, Italy (R.S.)

Corresponding Author: Dr. Caterina Marchiò, Department of Medical Sciences, University of Turin, Via Santena 7, 10126, Turin, Italy; (caterina.marchio@unito.it).

References

1. Pentsova EI, Shah RH, Tang J, et al. Evaluating cancer of the central nervous system through next-generation sequencing of cerebrospinal fluid. *J Clin Oncol*. 2016;34(20):2404–2415.
2. De Mattos-Arruda L, Mayor R, Ng CK, et al. Cerebrospinal fluid-derived circulating tumour DNA better represents the genomic alterations of brain tumours than plasma. *Nat Commun*. 2015;6:8839.
3. Mariani S, Di Bello C, Bonello L, et al. Flexible lab-tailored cut-offs for suitability of formalin-fixed tumor samples for diagnostic mutational analyses. *PLoS One*. 2015;10(4):e0121815.
4. Umetani N, Giuliano AE, Hiramatsu SH, et al. Prediction of breast tumor progression by integrity of free circulating DNA in serum. *J Clin Oncol*. 2006;24(26):4270–4276.
5. Giacona MB, Ruben GC, Iczkowski KA, et al. Cell-free DNA in human blood plasma: length measurements in patients with pancreatic cancer and healthy controls. *Pancreas*. 1998;17(1):89–97.
6. Yörüker EE, Özgür E, Keskin M, et al. Assessment of circulating serum DNA integrity in colorectal cancer patients. *Anticancer Res*. 2015;35(4):2435–2440.
7. Lococo F, Gandolfi G, Rossi G, et al. Deep sequencing analysis reveals that KRAS mutation is a marker of poor prognosis in patients with pulmonary sarcomatoid carcinoma. *J Thorac Oncol*. 2016;11(8):1282–1292.
8. Pan W, Yang Y, Zhu H, et al. KRAS mutation is a weak, but valid predictor for poor prognosis and treatment outcomes in NSCLC: a meta-analysis of 41 studies. *Oncotarget*. 2016;7(7):8373–8388.
9. Zhao N, Wilkerson MD, Shah U, et al. Alterations of LKB1 and KRAS and risk of brain metastasis: comprehensive characterization by mutation analysis, copy number, and gene expression in non-small-cell lung carcinoma. *Lung Cancer*. 2014;86(2):255–261.
10. Kerr EM, Gaude E, Turrell FK, et al. Mutant Kras copy number defines metabolic reprogramming and therapeutic susceptibilities. *Nature*. 2016;531(7592):110–113.

© The Author(s) 2016. Published by Oxford University Press on behalf of the Society for Neuro-Oncology.

This is an Open Access article distributed under the terms of the Creative Commons Attribution Non-Commercial License (<http://creativecommons.org/licenses/by-nc/4.0/>), which permits non-commercial re-use, distribution, and reproduction in any medium, provided the original work is properly cited. For commercial re-use, please contact journals.permissions@oup.com
doi:10.1093/neuonc/now244

Advance Access date 12 November 2016

Atypical meningioma—is it time to standardize surgical sampling techniques?

Key words: atypical meningioma | pathology | surgery

The World Health Organization (WHO) Classification of Tumours of the Central Nervous System has recently been updated.¹ While dramatic changes have been made to gliomas with the inclusion of molecular markers, a more subtle change has been made to meningiomas that may have implications for clinical trials. The brain tumor community is focusing collaborative research on grades II and III meningiomas through an international consortium (<http://www.soc-neuro-onc.org/events/172/>). There are several international clinical trials for atypical meningiomas, including ROAM/EORTC 1308,² EORTC 1320 (<https://clinicaltrials.gov/ct2/show/NCT02234050>), RTOG 0593 (<https://www.rtog.org/ClinicalTrials/ProtocolTable/StudyDetails.aspx?study=0539>), and NRG-BN003 (personal communication, L. Rogers). Trial entry is contingent upon accurate histopathological diagnosis. The updated WHO classification includes an important change, namely that brain invasion in addition to mitotic count of 4–20 mitoses per 10 high power microscopic fields is now diagnostic for atypical meningioma. While the new WHO change is unlikely to lead to increased reporting, as previously observed,³ it has potential implications for neurosurgeons. The surgical technique for meningioma resection is internal tumor decompression or “piecemeal” resection, followed by microsurgical dissection of the tumor–brain interface. The process of tumor debulking leads to sample loss in the suction and only rarely can the neurosurgeon perform en bloc resection and provide the neuropathologist with the “perfect” specimen. The impact of surgical sampling on glioma grading is well recognized but perhaps underappreciated and little discussed in meningiomas.⁴ Although neuropathologists often work with limited surgical samples, the neurosurgeon should provide the best possible specimens for diagnosis and research. Accurate assessment of brain invasion is important for meningioma prognostication,^{5,6} and sampling limitations may miss a brain-invasive meningioma, leading to undergrading and a potentially different management course than the one most suitable, including participation in clinical trials.

The updated WHO classification places an emphasis on accurate assessment of brain invasion. Meningiomas broadly fall into 2 categories: the minority that do not invade the pial surface and can be resected without disruption of the brain, and the majority where parenchymal disruption occurs during surgery.⁴ In the former, sampling of the resection cavity would not be appropriate; however, in the latter, the neurosurgeon may observe macroscopic brain invasion, and this raises an important question: “should sampling of the tumor–brain interface be made to specifically address the issue of microscopic brain invasion?” This would involve a paradigm shift in surgical practice, but one that should be considered. As a corollary, an absence of brain tissue in