

Natural course and prognosis of anaplastic gangliogliomas: a multicenter retrospective study of 43 cases from the French Brain Tumor Database

Louis-Marie Terrier, Luc Bauchet, Valérie Rigau, Aymeric Amelot, Sonia Zouaoui, Isabelle Filipiak, Agnès Caille, Fabien Almairac, Marie-Hélène Aubriot-Lorton, Anne-Marie Bergemer-Fouquet, Eric Bord, Philippe Comu, Alain Czorny, Phong Dam Hieu, Bertrand Debono, Marie-Bernadette Delisle, Evelyne Emery, Walid Farah, Guillaume Gauchotte, Catherine Godfraind, Jacques Guyotat, Bernard Irthum, Kevin Janot, Pierre-Jean Le Reste, Dominique Liguoro, Hugues Loiseau, Guillaume Lot, Vincent Lubrano, Emmanuel Mandonnet, Philippe Menei, Philippe Metellus, Serge Milin, Bertrand Muckenstrum, Pierre-Hugues Roche, Audrey Rousseau, Emmanuelle Uro-Coste, Anne Vital, Jimmy Voirin, Michel Wager, Marc Zanello, Patrick François, Stéphane Velut, Pascale Varlet, Dominique Figarella-Branger, Johan Pallud, Ilyess Zemmoura; Club de Neuro-Oncologie of the Société Française de Neurochirurgie

CHRU de Tours, Service de Neurochirurgie, Tours, France (L.-M.T., P.F., S.V., I.Z.); Université François-Rabelais de Tours, Inserm, Imagerie et Cerveau UMR U930, Tours, France (L.-M.T., S.V., I.Z.); Department of Neurosurgery and INSERM U1051, Hôpital Saint Eloi - Gui de Chauviac, Montpellier, France (L.B., S.Z.), French Brain Tumor DataBase, ICM, Montpellier, France (L.B., S.Z., V.R.); Department of Neuropathology and INSERM U1051, Hôpital Saint Eloi - Gui de Chauviac, Montpellier, France (V.R.); Department of Neurosurgery, Hôpital La Pitié Salpêtrière, APHP, Paris, France (A.A., P.C.); Plateforme CIRE, UMR-PRC, 37380 Nouzilly, Centre INRA Val de Loire (I.F.); Université François-Rabelais de Tours, Tours, France (A.C.); Inserm, CIC 1415, CHRU de Tours, Tours, France (A.C.); Department of Neurosurgery, Hôpital Pasteur, University Hospital Center, 06000, Nice, France (F.A.); Department of Pathology, Hôpital François Mitterrand, CHU de Dijon, 14 rue Paul Gaffarel, 21000 Dijon, France (M.-H.A.-L.); Service d'Anatomie et Cytologie Pathologique, CHRU de Tours, Tours, France (A.-M.B.-F.); Department of Neurosurgery and Neurotraumatology, Nantes University Hospital, Nantes, France (E.B.); Service de Neurochirurgie, CHU Jean-Minjoz, 3 boulevard Alexander-Fleming, Besançon cedex, France (A.C.); Department of Neurosurgery, CHU de la Cavale Blanche, Brest, France (P.D.H.); Department of Neurosurgery, Cèdres Hospital, Toulouse, France (B.D.); Laboratoire Universitaire d'Anatomie Pathologique, Neuropathologie humaine et expérimentale, CHU Rangueil, Toulouse, France (M.-B.D.); Department of Neurosurgery, University Hospital of Caen, Caen, France (E.E.); Service de Neurochirurgie, Hôpital François Mitterrand, CHU de Dijon, 14 rue Paul Gaffarel, 21000 Dijon, France (W.F.); Department of Pathology, CHU Nancy and INSERM U954, Faculty of Medicine, Université de Lorraine, France (G.G.); Department of Pathology, CHU de Clermont-Ferrand, Clermont-Ferrand, France (C.G.); Department of Neurosurgery, Neurological Hospital, Lyon, France (J.G.); Service de neurochirurgie, hôpital Gabriel-Montpied, CHU de Clermont-Ferrand, 58, rue Montalembert, 63003 Clermont-Ferrand, France (B.I.); Service de Neuroradiologie, CHRU de Tours, Tours, France (K.J.); Department of Neurosurgery, University Hospital Pontchaillou, 2, Rue Henri Le Guilloux, 35000, Rennes, France (P.-J.L.R.); Service de neurochirurgie A, place Amélie-Raba-Léon, 33076 Bordeaux cedex, France (D.L.); Université de Bordeaux - Service de Neurochirurgie B, hôpital Pellegrin Tripode, Bordeaux, France (H.L.); Department of Neurosurgery, Fondation Ophtalmologique Rothschild, Paris, France (G.L.); Service de neurochirurgie, hôpital de Rangueil, CHU de Toulouse, 1, avenue du Professeur-Jean-Poulhès, TSA 50032, 31059 Toulouse, France (V.L.); Department of Neurosurgery, Lariboisière Hospital, 75010 Paris, France (E.M.); Département de neurochirurgie, CHU d'Angers, 4, rue Larrey, 49940 Angers cedex 9, France (P.M.); Département de neurochirurgie, Aix-Marseille université, CHU Timone, Assistance publique-Hôpitaux de Marseille, 264, rue Saint-Pierre, 13385 Marseille cedex 05, France (P.M.); Department of Pathology, CHU de Poitiers, Hôpital la Milétrie, Poitiers, France (S.M.); Department of Neurosurgery, Orléans Hospital, France (B.M.); Service de Neurochirurgie, Hôpital Nord, APHM, University Hospital of Marseille Aix-Marseille Univ, Marseille, France (P.-H.R.); Département de Pathologie Cellulaire et Tissulaire, Centre Hospitalo-universitaire d'Angers, 4 rue Larrey, 49933, Angers Cedex 09, France (A.R.); CHU Toulouse, Hôpital de Rangueil, Service d'Anatomie et Cytologie Pathologique, 31400 Toulouse, France (E.U.-C.); Bordeaux Institute of Neuroscience, CNRS UMR 5227, F-33076, Bordeaux, France (A.V.); Department of Neurosurgery, Strasbourg-Colmar Hospital, France (J.V.); Department of Neurosurgery, Imaging Laboratory, University Hospital Poitiers, 2 Rue de La Miletrie, Poitiers Cedex, France (M.W.); Paris Descartes University, Sorbonne Paris Cité, Paris, France (M.Z., P.V., J.P.); Department of

Neurosurgery, Sainte-Anne Hospital, Paris, France (M.Z., J.P.); Department of Neuropathology, Sainte-Anne Hospital, Paris, France (P.V.); Department of Pathology and Neuropathology, Assistance Publique des Hôpitaux de Marseille (APHM), CHU Timone, Marseille, France (D.F.-B.)

Corresponding Author: Ilyess Zemmoura, MD, PhD, Service de Neurochirurgie, CHRU Bretonneau, 2 Boulevard Tonnellé, 37044 Tours cedex 9, France (ilyess.zemmoura@univ-tours.fr).

Abstract

Background. Anaplastic gangliogliomas (GGGs) are rare tumors whose natural history is poorly documented. We aimed to define their clinical and imaging features and to identify prognostic factors.

Methods. Consecutive cases of anaplastic GGGs in adults prospectively entered into the French Brain Tumor Database between March 2004 and April 2014 were screened. After diagnosis was confirmed by pathological review, clinical, imaging, therapeutic, and outcome data were collected retrospectively.

Results. Forty-three patients with anaplastic GGG (median age, 49.4 y) from 18 centers were included. Presenting symptoms were neurological deficit (37.2%), epileptic seizure (37.2%), or increased intracranial pressure (25.6%). Typical imaging findings were unifocal location (94.7%), contrast enhancement (88.1%), central necrosis (43.2%), and mass effect (47.6%). Therapeutic strategy included surgical resection (95.3%), adjuvant radiochemotherapy (48.8%), or radiotherapy alone (27.9%). Median progression-free survival (PFS) and overall survival (OS) were 8.0 and 24.7 months, respectively. Three- and 5-year tumor recurrence rates were 69% and 100%, respectively. The 5-year survival rate was 24.9%. Considering unadjusted significant prognostic factors, tumor midline crossing and frontal location were associated with shorter OS. Temporal and parietal locations were associated with longer and shorter PFS, respectively. None of these factors remained statistically significant in multivariate analysis.

Conclusions. We report a large series providing clinical, imaging, therapeutic, and prognostic features of adult patients treated for an intracerebral anaplastic GGG. Our results show that pathological diagnosis is difficult, that survivals are only slightly better than for glioblastomas, and that complete surgical resection followed with adjuvant chemoradiotherapy offers longer survival.

Key words

anaplastic ganglioglioma | cerebral malignancy | prognosis | surgery

Gangliogliomas (GGGs) are rare and usually benign neuroepithelial tumors. Histopathological examination exhibits both glial and neuronal cell components.¹ GGGs represent approximately 0.4–1.7% of all brain tumors.^{2–4} They are preferentially diagnosed in children and young adults with a slight preponderance in males.^{3,5–7} GGGs are predominantly located in the temporal lobe,^{5,8–12} a particularly epileptogenic cerebral lobe that in part explains the classical clinical presentation of GGGs with epileptic seizures.^{1,8,13} The standard treatment of GGGs is tumor resection. When gross total resection is performed and when WHO grade I malignancy is confirmed, no adjuvant therapy is recommended.¹⁴ Following subtotal resection, radiotherapy seems to improve local control of both low-grade and high-grade GGGs and may be indicated as adjuvant therapy.^{14,15} Prognostic factors of mortality are older age at diagnosis, male sex, and malignant glial features, while symptoms, tumor location, adjuvant radiotherapy, and extent of surgical resection have not been found to be as significantly related to survival.¹⁴

The incidence of anaplastic GGGs (aGGGs) defined by a WHO grade III component with increased proliferative index, angiogenesis, and necrosis is very rare and

estimated at 0.02 cases/million/year.¹⁶ This explains why most of the literature on aGGGs is limited to small retrospective case series and case reports.^{1,17–23} Thus, epidemiology, natural history, prognostic factors, and treatment options are poorly documented. According to the literature, aGGGs represent 1% to 31% of GGGs.^{1,13,24,25} In a recently published retrospective study from the SEER database of a cohort of 58 aGGGs mixing adult and pediatric cases, Selvanathan et al.¹⁶ identified surgery and unifocal disease as important predictors of OS, while adjuvant therapy did not seem to influence OS. Nevertheless, as indicated by the authors, this study presented a main limitation: the absence of detailed information regarding tumor size, extent of resection, dose and type of radiotherapy, use of chemotherapy, time to tumor recurrence, or treatment at recurrence, all of which are possible confounders for survival analyses.

In the present French Brain Tumor Database study, which benefited from the collaboration of 26 departments of neurosurgery in France and blind screening of medical records for all included patients, we report the largest multicenter cohort of adult patients with aGGG. To better identify prognostic factors, our study emphasized clinical, surgical, and imaging features plus adjuvant treatments.

Materials and Methods

Data collection

This study was approved by French legislation, the Société Française de Neurochirurgie (SFNC), and the Club Neuro-Oncologie of the Société Française de Neurochirurgie (CNO-SFNC). The cohort was extracted from the French Brain Tumor Database,^{26,27} with the International Classification of Diseases for Oncology code being aGGG: 9505/3. The French Brain Tumor Database offers a prospective collection of histologically diagnosed brain tumors in 54 French neurosurgical and neuropathological departments that began in January of 2004. We also consulted histopathological data in each neurosurgical department to identify cases of aGGGs that the French Brain Tumor Database could have failed to identify. Inclusion criteria were (1) adult patients (aged ≥ 18 y) at histopathological diagnosis, (2) intracranial tumor location, (3) histopathological diagnosis of WHO grade III GGG according to the WHO classification, version 2007, (4) inclusion between March of 2004 and April of 2014, and (5) independent pathological review (see below).

The French Brain Tumor Database registered 93 cases of aGGGs during the study period. The local screening of 26 French Departments of Neurosurgery (Angers, Besançon, Bordeaux, Brest, Caen, Clermont-Ferrand, Dijon, Lyon, Marseille-Nord, Marseille-Timone, Nantes, Nice, Orléans, Paris-Beaujon, Paris-Lariboisière, Paris-Necker, Paris-Fondation Rothschild, Paris-Sainte-Anne, Paris-Pitié-Salpêtrière, Poitiers, Rennes, Réunion, Strasbourg, Toulouse, Toulouse-Clinique des Cèdres, Tours) identified 12 additional cases of aGGG patients who had not been listed in the French Brain Tumor Database.

Comprehensive data collection had been performed in each neurosurgical department by one neurosurgeon (L.-M.T.). Medical record archives were consulted to extract clinical information, location and features of the tumor on imaging examinations, extent of resection, details from the histopathological examination, potential use of adjuvant therapy, and follow up. The cause of death was recorded.

Pathological Review

A pathological review confirmed that cases included in our series were actually aGGGs. After a first screening by manual examination of pathological records, histological diagnoses of aGGG by a senior pathologist member of the RENOP (Réseau de Neuro-Oncologie Pathologique; ie, the French network of neuropathologists) and/or GENOP (Groupe de Neuropathologie Oncologique Pédiatrique; ie, the French network of pediatric neuropathologists) at the time of diagnosis were not reviewed. For the other cases, histological samples were reviewed by RENOP referees blinded to clinical, imaging, therapeutic, and outcomes data.

Statistical Analyses

Results are expressed as median with interquartile range (IQR) for continuous variables. Unadjusted survival curves for OS and progression-free survival (PFS) were plotted by

the Kaplan-Meier method,²⁸ using log-rank tests to assess significance for group comparison. A P value $< .05$ was considered significant. Analyses were performed using R software, version 2.15.1.²⁹ OS was measured from the date of histopathological diagnosis to the date of death. PFS was measured from the date of histological diagnosis to the date of first radiological evidence of progression or to the date of death. For surviving patients, these intervals ended at the date of last follow-up. Progression was defined as an MRI recurrence or progression according to RANO criteria.³⁰ Cox proportional hazard models were used to identify independent prognostic factors affecting OS and PFS of patients. We estimated the hazard ratios (HRs) and their 95 % confidence intervals (CIs). In multivariate analysis, an adjustment for sex, age, MRI characteristics, history of grade I GGG, extent of resection, and adjuvant therapy was studied.

Results

A total of 105 patients fitting the criteria described above were enrolled. We excluded 48 patients (45.7 %) from the cohort: 10 medical records were unavailable, 18 patients were pediatric cases, 19 misclassifications were revealed by examining pathological records (14 cases of malignant glioneuronal tumors (MGNT), 2 primitive neuroectodermal tumors, 1 diffuse low-grade glioma (DLGG), 1 neurocytoma, 1 pinealocytoma), and 1 case was a medullary aGGG.

Pathological Review (see Supplementary Table 1)

After this first screening, among the 57 retained patients, 34 had already been diagnosed at the time of diagnosis by 2 senior neuropathologists, of whom at least one was a member of the RENOP and/or GENOP. Of the 23 remaining cases, only 22 were available for review. These 22 cases were submitted to RENOP referees; when the diagnosis of the referee was different from initial diagnosis, the cases were subsequently submitted to a third review by another member of the RENOP (D.F.B.) to confirm the exclusion. According to this process, 13 of these 22 cases were reclassified and excluded from the series. Nine of these 13 cases were reclassified as glioblastomas IDH wild-type (3), DLGG (3), pleomorphic xanthoastrocytoma (1), or unclassifiable gliomas (2). Four of these 13 cases were diagnosed as possible aGGG but with no possibility of excluding the diagnosis of anaplastic pleomorphic xanthoastrocytoma or epithelioid glioblastoma. These 4 cases were also excluded from the final series.

Finally, a total of 43 patients with a formal diagnosis of aGGG, from 18 departments of neurosurgery in France, were retained for full analyses.

Epidemiological and Clinical Data

Clinical data are summarized in [Table 1](#). Median age at diagnosis was 49.4 (IQR Q1-Q3 = 35y– 63y). De novo aGGGs occurred in 90.7% of cases, while the remaining

Table 1 Epidemiological, clinical, and radiological data

Epidemiological and clinical characteristics			Radiological characteristics		Radiological location		
	N	(%)		N	(%)	N	(%)
Age at diagnosis (y)			Average diameter			Anatomical location	
18–29	4	(9.3)	Contrast Enhancement	46.2 mm		Frontal lobe	16 (37.2)
30–39	12	(27.9)	FLAIR	70.3 mm		Temporal lobe	14 (32.6)
40–49	5	(11.6)	Contrast Enhancement			Parietal lobe	8 (18.6)
50–59	8	(18.6)	Yes	37	(88.1)	Occipital lobe	1 (2.3)
60–69	9	(20.9)	No	5	(11.9)	Basal ganglia	1 (2.3)
>69	5	(11.6)	NA	1		Cerebellum	3 (7)
Sex			Focality			Tumoral depth	
Male	26	(60.5)	Unifocal	36	(94.7)		
Female	17	(39.5)	Multifocal	2	(5.3)	Deep	11 (34.4)
First symptom			NA	5		Superficial	21 (65.6)
Seizures	16	(37.2)	Contrast enhancement characteristics			NA	11
Intracranial hypertension	11	(25.6)	Weakly intense	6	(16.2)		
Focal deficit	16	(37.2)	Nodular	14	(37.8)		
Symptom(s) present at diagnosis			Annular with central necrosis	16	(43.2)		
Seizures	21	(48.3)	NA	6			
Intracranial hypertension	14	(32.6)	Cyst(s)				
Time to diagnosis			Yes	8	(30.8)		
Average	5.2 mo		No	18	(69.2)		
Minimum	0.1 mo		NA	17			
Maximum	81 mo		Spontaneous bleeding				
Standard deviation	12.9 mo		Yes	6	(16.7)		
			No	30	(83.3)		
			NA	7			
			Mass Effect				
			Yes	20	(47.6)		
			No	22	(52.4)		
			NA	1			

Abbreviations: mo, months; NA: Not Available.

4 patients had a WHO grade I GGG at first surgery with a median time to anaplastic transformation at second surgery of 84 months (IQR= 9.75 mo– 153 mo). Medical history reported 2 patients with a history of visual pathway glioma in childhood and one patient with history of cerebral angioma. These latter 3 patients had received radiotherapy.

Imaging Data

Imaging data are summarized in Table 1. Typical imaging findings of aGGG were a unifocal (83.7%) tumor with intense annular contrast enhancement surrounding a central necrosis (43.2%) or with nodule-like contrast enhancement (37.8%). Mass effect (47.6%) was common (Fig. 1).

Temporal (32.6%) and frontal (37.2%) lobes were the most common locations.

Treatment Strategy

Therapeutic data are summarized in Table 2. Among the 41 patients treated by surgical resection, the extent of resection was quantified in 34 cases. Total resection of contrast enhancement was achieved in 20 of 34 patients (58.8%), according to postoperative contrast-enhanced MRI (25 cases) or CT scan (9 cases). Supratotal resection, encompassing the whole of the FLAIR hypersignal, was achieved in one of 41 patients (2.6%).

The postoperative performance status according to the WHO classification, as compared with the preoperative

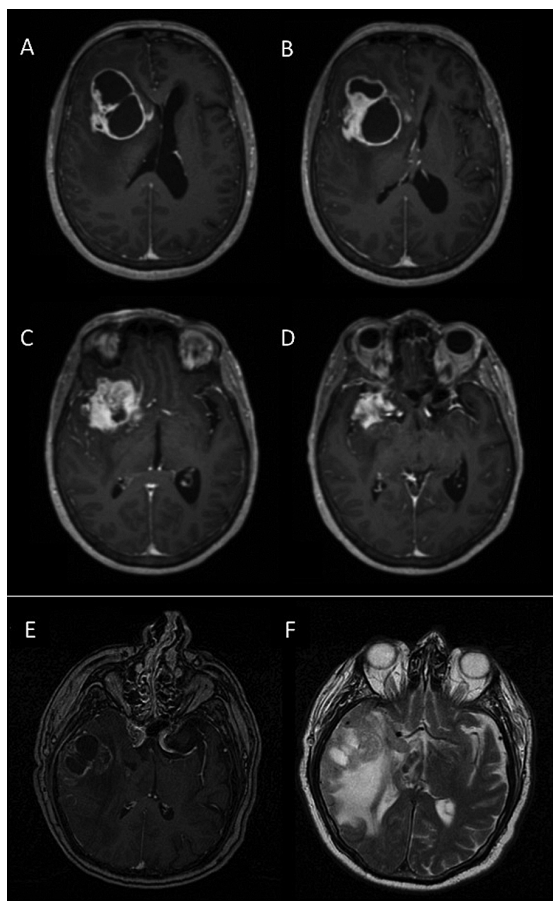


Fig. 1 Magnetic resonance imaging of anaplastic ganglioglioma. A, B, C, D: Axial postcontrast T1-weighted MRI showing a right frontoinsular cystic anaplastic ganglioglioma surrounded with annular and homogeneous contrast enhancement but with a diffuse pattern of infiltration toward basal ganglia. The tumor creates a mass effect on the ventricles. E: Axial postcontrast T1-weighted MRI showing a right temporal anaplastic ganglioglioma with heterogeneous contrast enhancement, central necrosis, and peripheral edema. F: Axial T2-weighted MRI of the same tumor showing peripheral edema in hypersignal and showing herniation of the temporal uncus on the right cerebral peduncle.

score, did not worsen in 29 of 43 (67.4%) cases, improved in 6 of 43 (13.9%) cases, and worsened in 14 of 43 (32.5%) cases (see Supplementary Table 2).

Radiotherapy and concomitant and adjuvant temozolomide (the so-called standard combined chemoradiotherapy for glioblastoma treatment according to Stupp et al.³¹) was performed in 21 of 43 patients (48.8%). Radiotherapy alone was performed in 12 of 43 patients (27.9%). Radiotherapy was administered 60 Gy in 30 fractions in all but one case treated with stereotactic radiosurgery. The median delay between surgery and radiotherapy was 6.6 weeks (range=5–9 wk; SD=1.45). Adjuvant chemotherapy without radiotherapy was administered to 3 of 43 patients: temozolomide (2) and fotemustine (1).

Three patients did not receive chemotherapy nor radiotherapy; one benefited from clinical and radiological surveillance, and the other two benefited from best supportive care due to their age (both were 76 years old).

Tumor recurrence rates at 3 and 5 years were respectively 69% (SD=3.1%) and 100%. At progression, for patients who benefited from MRI follow-up, progression occurred locally in 93.9% of cases. An intracranial metastasis was observed in one patient and a spinal metastasis in one patient. Therapeutic strategy at tumor progression was available in 33 of 38 (86.8%) patients: second surgical resection in 9 cases, second-line chemotherapy (procarbazine, CCNU, and vincristine [PCV] in 2 cases, irinotecan and bevacizumab in 4 cases, temozolomide in 3 cases, fotemustine in one case), radiotherapy alone in 3 cases, stereotactic radiotherapy gamma knife in one case, treatment continuation in 2 cases (temozolomide), combined chemoradiotherapy (Stupp protocol) in 2 cases, and best supportive care in 7 cases (Table 2).

Survival

After a median follow up of 42.5 months (SD=7.8 mo) 28 patients had died. OS and PFS data are summarized in Table 3 and Supplementary Table 3. Median PFS was 8.0 months (IQR=4–13 mo). Median OS was 24.7 months (SD=5.32 mo, IQR=10.6 – 47), and survival rates at three and five years were respectively 38.4% (SD=7.8%) and 24.9% (SD=8.2%) (Fig. 2 and 3). At the end of study, 28 patients had died, all from disease progression.

Prognostic Predictors

Univariate analysis identified frontal location and FLAIR crossing the midline as significant prognostic factors for OS (Table 3). Considering tumor location, patients treated for a frontal lobe tumor had a significantly shorter OS ($P=.037$) when compared with other locations. Considering radiological features, a tumor associated with FLAIR infiltration crossing the midline was associated with a significantly shorter OS ($P=.033$). A temporal tumor location was identified as a good prognostic factor for PFS ($P=.032$) while a parietal tumor location was associated with a lower PFS ($P=.038$).

Subgroup univariate analysis (see Supplementary Table 3) revealed, for the subgroup of patients with gross total resection, a trend toward a longer PFS for patients treated with radiotherapy ($P=.059$). Considering the subgroup of patients with partial resection, we identified a trend toward a shorter PFS for patients treated with combined chemoradiotherapy ($P=.07$). The subgroup with the best median OS (37.03 mo) was the group of patients who had undergone gross total resection followed by combined standard chemoradiotherapy (Stupp protocol).

Multivariate analysis did not identify these factors as independent prognostic factors (see Supplementary Table 4) but showed a trend toward a shorter OS for patients with a tumor crossing the midline in FLAIR MRI sequences ($P=.062$).

Table 2 Treatment strategy

	First treatment (43 patients)		Treatment at recurrence (38 patients)	
	N	(%)	N	(%)
Surgery			Best supportive care	7 (21.2)
Yes	41	(95.3)	Chemotherapy only (second line)	10 (30.3)
No (biopsy)	2	(4.7)	Second surgery	9 (27.3)
Resection of contrast enhancement			Surgery + adjuvant chemotherapy	6 (18.2)
Total	20	(58.8)	Surgery + carmustin implants	1 (3.0)
Partial	14	(41.2)	Surgery only	1 (3.0)
Not applicable (biopsy)	2	-	Surgery + radiotherapy	1 (3.0)
NA	7	-	Stupp protocol	1 (3.0)
Resection of FLAIR hypersignal			Pursuit of TMZ	2 (6.1)
Total	1	(2.6)	Stereotactic radiotherapy (Gamma knife)	1 (3.0)
Partial	38	(97.4)	Radiotherapy only	3 (9.1)
Not applicable (biopsy)	2	-	NA	5 -
NA	2	-		
Adjuvant treatment				
Stupp protocol	21	(48.8)		
Radiotherapy only	12	(27.9)		
Chemotherapy TMZ only	2	(4.7)		
Chemotherapy fotemustine only	1	(2.3)		
Radiochemotherapy (other)	1	(2.3)		
Best supportive care	2	(4.7)		
Stereotactic radiotherapy (Gamma knife)	1	(2.3)		
Wait-and-see	1	(2.3)		

Abbreviations: NA: not available; TMZ: temozolomide.

Discussion

Our study, based on the French Brain Tumor Database,^{26,27} is the largest series of adult patients treated for aGGG. The current literature concerning aGGGs is limited to small cases series or individual case reports^{1,13,17,20–23,25} and a unique large series from the SEER database, held by the National US Cancer Institute.¹⁶ Nonetheless, this latter study mixing adult and pediatric cases did not detail clinical, imaging, or therapeutic data. In the present series, the retrospective screening of each medical record allowed us to provide a detailed analysis of surgical, imaging, and therapeutic data for each patient of the series.

Pathological Review

Among the 22 cases independently reviewed by the RENOP for our study, only 9 were finally included in our series. Indeed, 9 (40.9 %) cases had been reclassified, and 4 were highly malignant glioneuronal tumors without any possibility of excluding anaplastic pleomorphic xanthoastrocytoma or epithelioid glioblastoma. These data highlight the difficulty of pathological diagnosis of aGGG

and should lead to a systematic independent pathological review when this diagnosis is suspected.

This independent review explains why our series, even if multicentric and performed over a period of 10 years, only included 43 cases. On the other hand, these restrictive inclusion criteria improved the accuracy of the pathological diagnosis and the homogeneity of the series.

Epidemiological and Clinical Data

In the present study, the mean age at diagnosis was 49.4 years, which is older than the previously reported median age for aGGG of 25.5–35 years.^{5,16} This may be partially explained by the exclusion of the pediatric population. The average age from the French Brain Tumor Database, if we include pediatric cases, was 40.2 years. Moreover, it is worth noting that such databases as the French Brain Tumor Database²⁷ or SEER database are based on manual classification and inclusions performed by the clinicians and/or pathologists. This could induce misclassification and consequently a bias in the determination of age at diagnosis. Thus, we excluded 34 of 77 cases initially registered as aGGGs. As a conclusion considering age at diagnosis, it appears that diagnosis is made at an older age for aGGGs than for grade I GGGs, for which median age

Table 3. Statistical Analysis – Univariate analysis

Variable		Overall Survival – Univariate analysis			Progression Free Survival – Univariate analysis				
		Median survival (months)	Confidence Interval	Overall P value	Median PFS (mo)	Confidence Interval	P value		
Sex	Male	28.33	5.35–51.3	.206	4.51	0.85–8.14	.205		
	Female	19.2	5.87–32.6		8.0	5.0–10.9			
Age group (y)	< 50	37.0	18.3–55.7	.07	8.1	4.3–11.6	.724		
	≥ 50	16.2	0.1–36.1		6.4	2.8–9.12			
Location	Frontal lobe	16.2	1.7–30.6	.037*	5.1	2.4–7.51	.40		
	Temporal lobe	28.3	6.8–49.9		.398	11.1		3.2–18.7	.032*
	Parietal lobe	19.2	5.3–57.6		.373	4.2		0.1–8.8	.038*
	Cerebellum	27.1	16.4–31.2		.908	5.5		-	-
	Basal ganglia	40.8	-		-	22		-	-
	Occipital lobe	37.0	-		-	8		-	-
Location depth	Deep	27.0	14.7–39.2	.916	10.0	7.31–12.68	.893		
	Superficial	28.1	6.1–50.2		8	3.9–12.03			
Mass effect	Yes	24.7	13.5–35.8	.870	7.0	3.6–10.31	.132		
	No	27	9.18–44.8		8.0	4.08–11.9			
FLAIR crossing the midline	Yes	1.4	0.2–11.25	.033*	6.3	6–13.3	.859		
	No	27.5	22.0–31.9		8.0	6.31–9.6			
Surgical resection	Partial	24.4	10.4–38.5	.338	8.3	2.1–13.8	.656		
	Total	30.6	11.3–49.8		7.0	5.05–8.94			
Stupp protocol	Yes	27.2	8.4–45.5	.681	8.3	5.3–10.65	.767		
	No	24.4	13.6–35.2		7.0	3.2–10.78			
Radiotherapy alone	Yes	30.6	20.9–40.2	.382	8.2	4.72–11.2	.484		
	No	19.2	12.9–25.6		9.06	4.95–13.04		-	
Focality	Unifocal	24.4	13.05–35.8	.627	7.1	4.40–9.59	-		
	Multifocal	17.2	12.4–37.1		8.0	-		-	
History of grade I ganglioglioma	Yes	15.0	2.3–27.7	.642	1.2	-	-		
	No	24.7	12.8–36.5		-	8.1		5.2–10.7	

*Statistically significant $P < .05$.

at surgery is 25.6 years.^{1,5,7,8,13,25,32} However, the median age for aGGG is lower than that for glioblastoma with a reported median age > 60 years.³³ Finally, the male predominance (60.5%) observed in the present study concurs with previously published series of GGGs in the adult^{1,16,22} and pediatric populations.³⁴

In our series the presenting symptom was focal neurological deficit in 37.2%, seizures in 37.2%, and increased cranial pressure in 25.6%. The previously published series, which contained a majority of grade I GGGs, found seizures as the first symptom in 70%–95% of cases.^{8,22,25,35} This difference between grade I and aGGGs' clinical presentation is consistent with the difference between DLGG and high-grade gliomas, in which seizure is the presenting symptom in 70%–90%^{36,37} and 18%–52% of cases, respectively.^{38,39} Thus, similar to high-grade gliomas, most aGGGs appear

to grow fast, leading to focal neurological deficit and increased intracranial pressure.

Tumor Characteristics

The most common locations were frontal and temporal lobes. Our data concerning the lobar distribution recall previously published series of high-grade, grade I, and adult and pediatric GGGs.^{1,8,16,34} Considering tumor location, it is worth noting that screening by the French Brain Tumor Database only registered one intramedullary aGGG and no brainstem aGGGs. This is not surprising, given the previously published data⁵ that established the rarity and absence of brainstem locations for grade I and anaplastic GGGs, respectively.

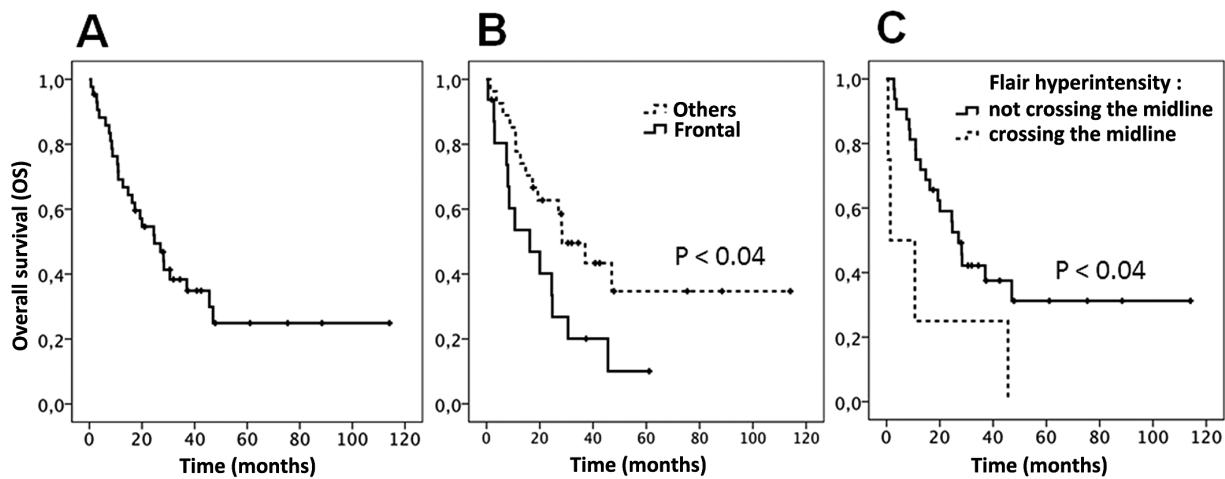


Fig. 2 Overall survival of anaplastic gangliogliomas. A. The median overall survival (OS) was 24.7 months in the whole population ($n=43$). B. OS according to tumor location. The median OS was 16.2 months for frontal lobe location ($P=.037$). C. OS according to crossing the midline in FLAIR sequences. The median OS was 27.5 months for patients with FLAIR hyperintensity not crossing the midline and 1.4 months for those with FLAIR hyperintensity crossing the midline ($P=.033$).

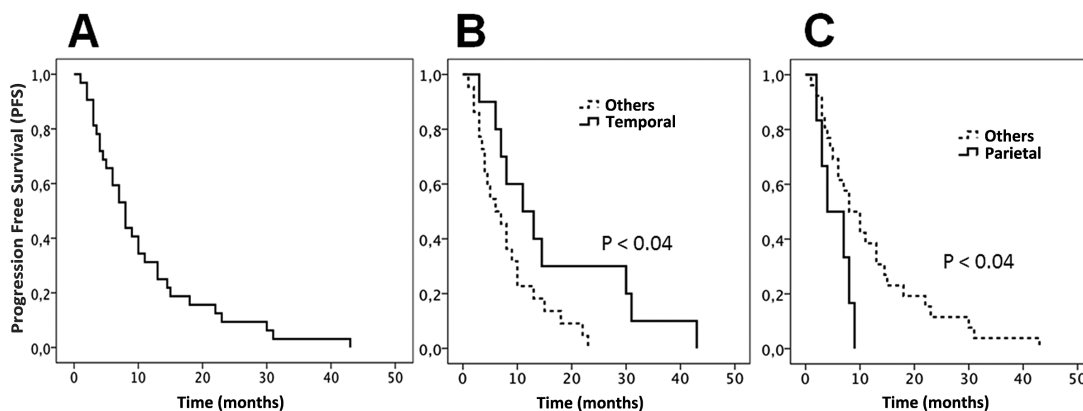


Fig. 3 Progression-free survival (PFS) of anaplastic gangliogliomas. A. The median PFS was 8.0 months in the whole population ($n=43$). B. PFS according to location. The median PFS was 11.1 months for temporal lobe location ($P=.032$). C. PFS according to location. The median PFS was 4.2 months for parietal lobe location ($P=.038$).

Radiological characteristics of aGGGs were (most of the time) a large unifocal tumor with intense annular contrast enhancement surrounding a central necrosis with mass effect and with an important perilesional vasogenic edema. The large majority of patients (88.1 %) demonstrated intense contrast enhancement. These characteristics not only recall reported cases of aGGGs^{20,22} but also grade I GGGs, especially considering contrast enhancement, which has been reported in 88 % to 100 % of grade I GGGs^{8,25} unlike DLGG which exhibit only around 16 % of contrast enhancement.⁴⁰ On the other hand, cysts were only present in 30.8 % of our cases, while they are described in 60%–81 % of grade I GGGs.^{8,25} In other words, aGGGs lose

the typical radiological characteristics of grade I GGGs, especially their cystic and well-circumscribed features, and gain characteristics of anaplastic gliomas and glioblastomas (ie, necrosis, surrounding cerebral edema, and mass effect). Our retrospective analysis did not allow us to study the interest of perfusion, diffusion, or spectroscopy MRI sequences in the diagnosis of aGGGs.

Management and Survival

The median OS of aGGGs patients (ie, 24.7 months in the present study) is close to that of glioblastoma patients.

Unsurprisingly, grade I GGGs have a better prognosis with an OS rate of 90% at 5 years,^{1,8,24} a recurrence rate of 39 %, and a median PFS of 5.6 years.⁸

The 24.9 % survival rate at 5 years shows a significant difference with those of other series of aGGGs: 53 % in the 5-case series of Majores et al.,²² and 63 % in the 58-case series of Selvanathan et al.¹⁶ The poorer survivals in the series may be explained by the absence of pediatric cases. Indeed, although univariate analysis of our series only showed a trend toward a better survival for young patients aged <50 years ($P=.07$), older age at diagnosis had already been proposed as a poor prognostic factor by Majores et al.²²

Our results do not clearly confirm the extent of surgical resection to be an important prognostic factor of longer OS, while these data had already been demonstrated in several studies.^{16,22,24,34} Nevertheless, while the benefit of adjuvant treatments is usually debated,¹⁶ the subgroup of our series with the best OS (37.03 mo) was the subgroup of patients treated with gross total resection followed by combined standard chemoradiotherapy. Adjuvant radiotherapy and/or chemotherapy are not usually recommended for grade I GGGs.^{20,22} For aGGGs, however, literature series are rare and lead only to a paucity of evidence and the absence of therapeutic guidelines. According to Selvanathan et al.,¹⁶ adjuvant radiotherapy did not induce a statistically significant difference in OS. They noticed a trend towards longer survival in patients who had undergone adjuvant radiotherapy, but the information about the use of chemotherapy or the type of radiotherapy was not available in their study.¹⁶ Our results did not show the superiority of a particular adjuvant treatment, especially standard combined chemoradiotherapy, nor did it demonstrate a better effect on survival than radiotherapy alone. As only 2 patients of our series did not receive adjuvant therapy, we could not conclude on the interest of adjuvant treatment as compared with surgery alone.

Limitations of the Study

Despite the retrospective design of this multicentric study, we collected detailed clinical, pathological, imaging, therapeutic, and follow-up data. Nonetheless, our series only included 43 cases of aGGGs, which reduces the power of statistical analysis. However, the rarity of this pathology makes it difficult to include a larger number of patients, and a prospective study appears unrealistic. Nonetheless, in order to minimize bias, we put an emphasis on data collection, which had been performed at the source of medical records.

A direct consequence of the small sample of our series was the inability to assess the prognostic impact of chemo- and radiotherapy. Indeed, approximately 90 % of the patients received surgery and radiotherapy, which limited statistical analysis of the impact of alternative therapeutic strategies on PFS and OS. Specifically, it was not possible to assess the impact of radiotherapy on the natural history of aGGGs since only 6 patients in our series were treated with chemotherapy alone, which generated no statistical difference for PFS and OS in this subgroup compared with the subgroup treated with radiotherapy. Another limitation concerns epileptic seizures. As medical records screened

were issued from neurosurgical and/or neuro-oncological departments, the epileptic status of patients was not systematically found. It is therefore not possible to provide pertinent data about the outcome of seizures following surgery and following adjuvant treatments.

Finally, considering histological classification of aGGGs, and molecular markers as BRAF V600E mutations, the retrospective design of our study did not allow us to integrate genotypic patterns for cases, although it would have been interesting to discuss their potential role in classifying aGGGs patients. Nonetheless, the recently published 2016 WHO classification of tumors of the central nervous system⁴¹ still recognizes the entity of aGGGs. According to this update of the 2007 fourth edition, histological diagnosis of aGGG still relies on the same characteristics and, importantly, does not integrate genotypic pattern. The absence of novelty in the diagnosis of aGGG in the new version of the WHO classification confirms the interest of our study and reinforces our conclusion that a large international study is the only method to obtain strong data on rare tumors such as aGGGs.

Conclusion

The management of aGGGs should include extensive surgical resection of contrast-enhanced areas and FLAIR infiltration as much as cerebral function and vascularization would allow, followed by adjuvant radiotherapy or combined standard chemoradiotherapy. The poor prognosis of aGGG (median OS is only 24.7 months) makes this rare pathological entity one of the most aggressive malignancies of the brain. Due to the rarity of the pathology and the difficulty of pathological diagnosis highlighted by our work, future works on aGGGs should include a larger international series and systematic pathological review and should focus on molecular biology to guide oncologists in choosing the best adjuvant treatment amongst radiotherapy, chemotherapy, and targeted therapies.

Supplementary Material

Supplementary material is available at *Neuro-Oncology* online.

Funding

Archimedes Pharma® partially funded Louis-Marie Terrier for the collection of data.

Acknowledgments

The authors would like to thank Dr. Fanny Burel-Vandenbos, Dr. Anne Jouvet, Dr. Delphine Loussouarn, and Prof. Karima Mokhtari for their help during pathological review.

Conflict of interest statement. The authors declare no conflicts of interest

References

- Luyken C, Blümcke I, Fimmers R, Urbach H, Wiestler OD, Schramm J. Supratentorial gangliogliomas: Histopathologic grading and tumor recurrence in 184 patients with a median follow-up of 8 years. *Cancer*. 2004;101(1):146–155.
- Kalyan-Raman UP, Olivero WC. Ganglioglioma: a correlative clinicopathological and radiological study of ten surgically treated cases with follow-up. *Neurosurgery*. 1987;20(3):428–433.
- Pandita A, Balasubramaniam A, Perrin R, Shannon P, Guha A. Malignant and benign ganglioglioma: a pathological and molecular study. *Neuro Oncol*. 2007;9(2):124–134.
- Demierre B, Stichnoth FA, Hori A, Spoerri O. Intracerebral ganglioglioma. *J Neurosurg*. 1986;65(2):177–182.
- Blümcke I, Wiestler OD. Gangliogliomas: an intriguing tumor entity associated with focal epilepsies. *J Neuropathol Exp Neurol*. 2002;61(7):575–584.
- Ulutin HC, Öngürü ö, Pak Y. Postoperative radiotherapy for ganglioglioma; report of three cases and review of the literature. *Minim Invasive Neurosurg*. 2002;45(4):224–227.
- Im S-H, Chung CK, Cho B-K, et al. Intracranial ganglioglioma: preoperative characteristics and oncologic outcome after surgery. *J Neurooncol*. 2002;59(2):173–183.
- Compton JJ, Issa Laack NN, Eckel LJ, Schomas DA, Giannini C, Meyer FB. Long-term outcomes for low-grade intracranial ganglioglioma: 30-year experience from the Mayo Clinic. *J Neurosurg*. 2012;117(5):825–830.
- Ghosal N, Dadlani R, Murthy G, Hegde AS. Primary malignant ganglioglioma of the dorsolumbar spine (D11- L1). *J Clin Neurosci*. 2010;17(12):1597–1599.
- Krouwer HG, Davis RL, McDermott MW, Hoshino T, Prados MD. Gangliogliomas: a clinicopathological study of 25 cases and review of the literature. *J Neurooncol*. 1993;17(2):139–154.
- Deling L, Nan J, Yongji T, et al. Intraventricular ganglioglioma prognosis and hydrocephalus: The largest case series and systematic literature review. *Acta Neurochir (Wien)*. 2013;155(7):1253–1260.
- Samdani AF, Torre-Healy A, Khalessi A, McGirt M, Jallo GI, Carson B. Intraventricular ganglioglioma: a short illustrated review. *Acta Neurochir (Wien)*. 2009;151(6):635–640.
- Rumana CS, Valadka AB, Contant CF. Prognostic factors in supratentorial ganglioglioma. *Acta Neurochir (Wien)*. 1999;141(1):63–69.
- Liau SL, Byer JE, Yachnis AT, Amdur RJ, Mendenhall WM. Radiotherapy after subtotaly resected or recurrent ganglioglioma. *Int J Radiat Oncol*. 2007;67(1):244–247.
- Rades D, Zwick L, Leppert J, et al. The role of postoperative radiotherapy for the treatment of gangliogliomas. *Cancer*. 2010;116(2):432–442.
- Selvanathan SK, Hammouche S, Salminen HJ, Jenkinson MD. Outcome and prognostic features in anaplastic ganglioglioma: analysis of cases from the SEER database. *J Neurooncol*. 2011;105(3):539–545.
- Mekni A, Chelly I, Haouet S, Zitouna M, Kchir N. Malignant cerebellar ganglioglioma. A case report and review of the literature[in French]. *Neurochirurgie*. 2006;52(2–3 Pt 1):119–122.
- Harding M, Brophy B, Geake T. Malignant cerebellar ganglioglioma. *J Clin Neurosci Off J Neurosurg Soc Australas*. 2008;15(5):582–585.
- Kawataki T, Sato E, Sato T, Kinouchi H. Anaplastic ganglioglioma with malignant features in both neuronal and glial components--case report. *Neurol Med Chir (Tokyo)*. 2010;50(3):228–231.
- DeMarchi R, Abu-Abed S, Munoz D, Loch Macdonald R. Malignant ganglioglioma: case report and review of literature. *J Neurooncol*. 2010;101(2):311–318.
- Mittelbronn M, Schittenhelm J, Lemke D, et al. Low grade ganglioglioma rapidly progressing to a WHO grade IV tumor showing malignant transformation in both astroglial and neuronal cell components: Malignant progression in ganglioglioma. *Neuropathology*. 2007;27(5):463–467.
- Majores M, von Lehe M, Fassunke J, Schramm J, Becker AJ, Simon M. Tumor recurrence and malignant progression of gangliogliomas. *Cancer*. 2008;113(12):3355–3363.
- Lee C-C, Wang W-H, Lin C-F, et al. Malignant transformation of supratentorial ganglioglioma. *Clin Neurol Neurosurg*. 2012;114(10):1338–1342.
- Lang FF, Epstein FJ, Ransohoff J, et al. Central nervous system gangliogliomas. Part 2: Clinical outcome. *J Neurosurg*. 1993;79(6):867–873.
- Gelabert-González M, Santín Amo JM, Arcos Algaba A, et al. Intracranial gangliogliomas. A review of a series of 20 patients. *Neurol Engl Ed*. 2011;26(7):405–415.
- Rigau V, Zouaoui S, Mathieu-Daudé H, et al. French brain tumor database: 5-year histological results on 25 756 cases. *Brain Pathol Zurich Switz*. 2011;21(6):633–644.
- Zouaoui S, Rigau V, Mathieu-Daudé H, et al. French brain tumor database: general results on 40,000 cases, main current applications and future prospects [in French]. *Neurochirurgie*. 2012;58(1):4–13.
- Kaplan EL, Meier P. "Nonparametric estimation from incomplete observations". *J. Amer. Statist. Assoc*. 1958;53(282):457–481. JSTOR 2281868.
- Development Core Team, R. *A language and environment for statistical computing*. R Foundation for Statistical Computing, Vienna, Austria. ISBN 3-900051-07-0. 2005. <http://www.R-project.org>. Accessed February 19, 2015.
- Vogelbaum MA, Jost S, Aghi MK, et al. Application of novel response/progression measures for surgically delivered therapies for gliomas: Response Assessment in Neuro-Oncology (RANO) Working Group. *Neurosurgery*. 2012;70(1):234–243.
- Stupp R, Mason WP, van den Bent MJ, et al. Radiotherapy plus concomitant and adjuvant temozolomide for glioblastoma. *N Engl J Med*. 2005;352(10):987–996.
- Brainer-Lima PT, Brainer-Lima AM, Azevedo-Filho HR. Ganglioglioma: comparison with other low-grade brain tumors. *Arq Neuropsiquiatr*. 2006;64(3A):613–618.
- Bauchet L, Mathieu-Daude H, Fabbro-Peray P, et al. Oncological patterns of care and outcome for 952 patients with newly diagnosed glioblastoma in 2004. *Neuro Oncol*. 2010;12(7):725–735.
- Karremann M, Pietsch T, Janssen G, Kramm CM, Wolff JEA. Anaplastic ganglioglioma in children. *J Neurooncol*. 2009;92(2):157–163.
- Rumana CS, Valadka AB. Radiation therapy and malignant degeneration of benign supratentorial gangliogliomas. *Neurosurgery*. 1998;42(5):1038–1043.
- Smits A, Duffau H. Seizures and the natural history of World Health Organization Grade II gliomas: a review. *Neurosurgery*. 2011;68(5):1326–1333.
- Pallud J, Audureau E, Blonski M, et al. Epileptic seizures in diffuse low-grade gliomas in adults. *Brain J Neurol*. 2014;137(Pt 2):449–462.

38. Kim Y-H, Park C-K, Kim TM, et al. Seizures during the management of high-grade gliomas: clinical relevance to disease progression. *J Neurooncol.* 2013;113(1):101–109.
39. Pace A, Bove L, Innocenti P, et al. Epilepsy and gliomas: incidence and treatment in 119 patients. *J Exp Clin Cancer Res CR.* 1998;17(4):479–482.
40. Pallud J, Capelle L, Taillandier L, et al. Prognostic significance of imaging contrast enhancement for WHO grade II gliomas. *Neuro Oncol.* 2009;11(2):176–182. doi:10.1215/15228517-2008-066.
41. Louis DN, Perry A, Reifenberger G, et al. The 2016 World Health Organization Classification of Tumors of the Central Nervous System: a summary. *Acta Neuropathol.* 2016;131(6):803–820.