



Partial proximal tibia fractures

Michael J. Raschke
Christoph Kittl
Christoph Domnick

- Partial tibial plateau fractures may occur as a consequence of either valgus or varus trauma combined with a rotational and axial compression component.
- High-energy trauma may result in a more complex and multi-fragmented fracture pattern, which occurs predominantly in young people. Conversely, a low-energy mechanism may lead to a pure depression fracture in the older population with weaker bone density.
 - Pre-operative classification of these fractures, by Müller AO, Schatzker or novel CT-based methods, helps to understand the fracture pattern and choose the surgical approach and treatment strategy in accordance with estimated bone mineral density and the individual history of each patient.
- Non-operative treatment may be considered for non-displaced intra-articular fractures of the lateral tibial condyle. Intra-articular joint displacement ≥ 2 mm, open fractures or fractures of the medial condyle should be reduced and fixed operatively. Autologous, allogenic and synthetic bone substitutes can be used to fill bone defects.
- A variety of minimally invasive approaches, temporary osteotomies and novel techniques (e.g. arthroscopically assisted reduction or 'jail-type' screw osteosynthesis) offer a range of choices for the individual and are potentially less invasive treatments.
- Rehabilitation protocols should be carefully planned according to the degree of stability achieved by internal fixation, bone mineral density and other patient-specific factors (age, compliance, mobility). To avoid stiffness, early functional mobilisation plays a major role in rehabilitation. In the elderly, low-energy trauma and impression fractures are indicators for the further screening and treatment of osteoporosis.

Keywords: partial proximal tibial fractures; tibial head; surgical approach; tibial plateau fractures

Cite this article: *EFORT Open Rev* 2017;2.
DOI: 10.1302/2058-5241.2.160067. Originally published online at www.efortopenreviews.org

Introduction

Partial tibial plateau fractures may occur as a consequence of a valgus or varus trauma combined with a rotational and axial compression component. In the following article, we focus mainly on unicompartamental AO type B1-B3 fractures. Soft-tissue damage, joint depression and fragment dislocation, as well as bone stock, patient compliance and concomitant injuries, may influence decision-making. However, due to these difficulties, a clear treatment strategy is required to achieve an anatomical reduction and, subsequently, an optimal clinical and functional result.

Three-dimensional (3D) pre-operative imaging (CT scans with two-dimensional (2D) and 3D reconstructions) is essential to fully understand the fracture morphology and may therefore influence the treatment strategy. Additionally, if clinical examination is difficult, a pre-operative MRI scans may be necessary to visualise concomitant intra-articular pathologies (e.g. meniscus), which also need to be addressed.

Mechanism of trauma

The typical valgus and varus bending mechanism can result in a corresponding lateral or medial plateau split fracture with a varying degree of articular surface depression. This situation leads to axis malalignment and pathological load distribution, which ultimately causes poor functional outcome and post-traumatic osteoarthritis. Concomitant ligament disruption, meniscus or cartilage damage will further weaken clinical results.

A high-energy traumatic mechanism may result in a more complex and multi-fragmented fracture pattern, which predominantly occurs in young people. Conversely, a low-energy mechanism may lead to a pure depression fracture in the older population who have reduced bone density. Thoughtful evaluation of the patient's history and fracture morphology (using CT) in accordance with existing classification systems may help to understand the fracture mechanism¹ and expected bone quality/density to develop the appropriate operative treatment strategy.

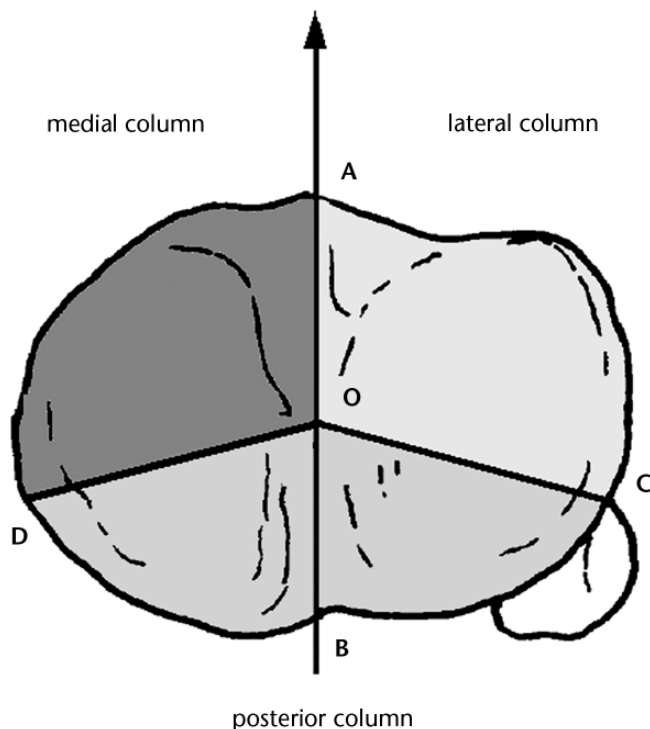


Fig. 1 The ‘medial’, ‘lateral’ and ‘posterior’ column of the Luo classification. Pure impression fractures are defined as ‘zero-column fractures’. Reprinted from Luo CF, Sun H, Zhang B, Zeng BF. Three-column fixation for complex tibial plateau fractures. *J Orthop Trauma* 2010;24:683-692, with permission from Wolters Kluwer Health.

Classification

Previous classification systems rely on conventional radiography evaluations (Müller AO/OTA² or Schatzker)³ and injury mechanisms (Moore¹). However, recent CT-oriented classification systems provide more detailed

information pertaining to the fracture morphology, degree of joint depression and appropriate surgical approach.^{4,5} Luo et al⁴ recently described a CT-based three-column model to evaluate tibial plateau fractures and clinical decision-making (Fig. 1). According to the authors: ‘one independent articular depression with a break of the column wall is defined as a fracture of the relevant column. Pure articular depression without fracture of the three columns (Schatzker type III) is defined as a zero-column fracture’.⁶

Krause et al⁵ investigated fracture patterns from a total of 242 patients with 246 affected knees and suggested ‘ten segment’ mapping of the tibial plateau (Fig. 2).

Based on their findings, a new classification system was developed that included implications for the treatment strategy. Unicondylar lateral tibial plateau fractures were most common (88.8%), whereas the medial plateau was only involved in 10% of unicompartmental or extended lateral type-B fractures.⁵ These unicompartmental medial plateau fractures are mainly associated with low-energy injury mechanisms. A possible reason for the relatively increased involvement of the lateral tibial plateau (Fig. 3) may be its decreased bone mineral density in comparison to the medial plateau.⁷

AO type B fractures showed a wide range of different fracture patterns with 29 different segment combinations overall. The posterolateral lateral (65.2%), the anterolateral lateral (64.6%) and the anterolateral central (60.9%) segments were the most frequently involved. One-third of all AO type B fractures included central segments of the tibial spine.⁵

In the non-osteopenic tibial bone, unicompartmental fractures of the medial column are rare.⁵ In a prospective study in an alpine skiing region (Grenoble, France), Morin et al⁸ detected unicompartmental posteromedial Moore I

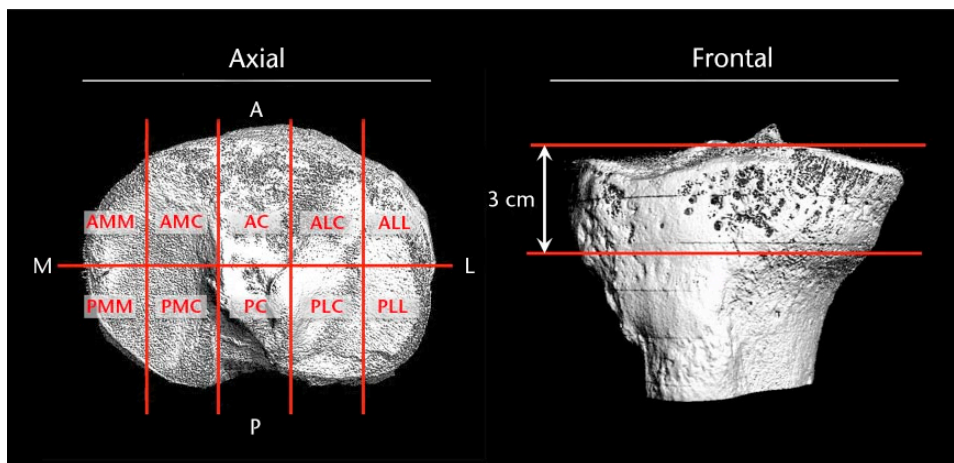


Fig. 2 Classifying tibial plateau fractures by ten segments in a CT model may help to choose an appropriate approach. Reprinted from Krause M, Preiss A, Müller G, et al. Intra-articular tibial plateau fracture characteristics according to the “Ten segment classification”. *Injury* 2016;47:2551-2557, with permission from Elsevier.

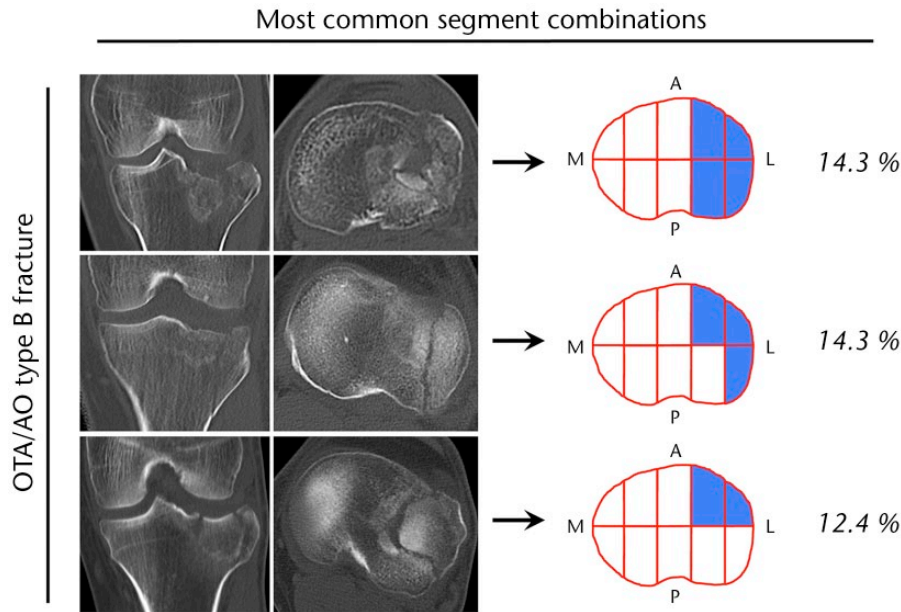


Fig. 3 Most partial tibial head fractures affect the lateral plateau. Reprinted from Krause M, Preiss A, Müller G, et al. Intra-articular tibial plateau fracture characteristics according to the “Ten segment classification”. *Injury* 2016;47:2551-2557, with permission from Elsevier.

fractures in 13% of all injured alpine skiers, who received surgical treatment for intra-articular tibial plateau fractures. However, in the well-mineralised tibial head, fractures of the medial compartment appeared more often in multi-part tibial-head dislocation-type injuries.^{1,9} Iatrogenic partial tibial fractures have been reported in a few cases after ligament reconstruction surgery and high tibial osteotomy, but the risk for these secondary fractures is low.¹⁰

Indications for operative reduction and fixation

In general, surgical reduction and fixation is indicated for most tibial head fractures. However, the fracture morphology, articular surface displacement level, axial stability, limb alignment and the patient's general condition should be considered. The following specific indications for surgical treatment have been reported in the literature:^{11,12}

- Intra-articular displacement of ≥ 2 mm
- Metaphyseal-diaphyseal translation of > 1 cm
- Lateral tilting of the plateau $> 5^\circ$
- Condylar widening > 5 mm
- Angular deformity of $> 10^\circ$ in either the coronal (varus-valgus) or sagittal plane (tibial slope)
- All medial tibial condyle fractures (except fissures)
- Open fracture
- Associated compartment syndrome
- Associated ligament injury requiring repair
- Associated fractures of the ipsilateral tibia or fibula

In addition to the general condition of the patient, soft-tissue damage and swelling should be taken into consideration when planning surgery. When an increase in soft-tissue damage is expected, fracture reduction should be performed either immediately before swelling of the limb, or the limb should be immobilised by cast or external fixator to condition the soft-tissue prior to secondary surgical reduction. Concomitant ligament injury with resulting instability should be identified before or during surgery.

Treatment options: approaches and techniques

Conventional (antero-)lateral approach

A conventional anterolateral approach may be used for reduction and fixation of the anterolateral part of the tibial plateau. The meniscotibial ligaments should be incised horizontally, and the lateral meniscus should be slightly lifted proximally to gain sufficient view of the tibial joint surface. After reduction, fixation can be performed using a proximal anterolateral tibial locking compression plate (LCP), anterolateral proximal tibial rafting LCP or lateral proximal tibial less-invasive stabilisation system LISS-plate (Fa. Synthes, Switzerland).

However, in some cases, the anterolateral approach does not provide full visualisation, especially of the posterior portion of the fracture zone. Thus, a fibular osteotomy,^{13,14}

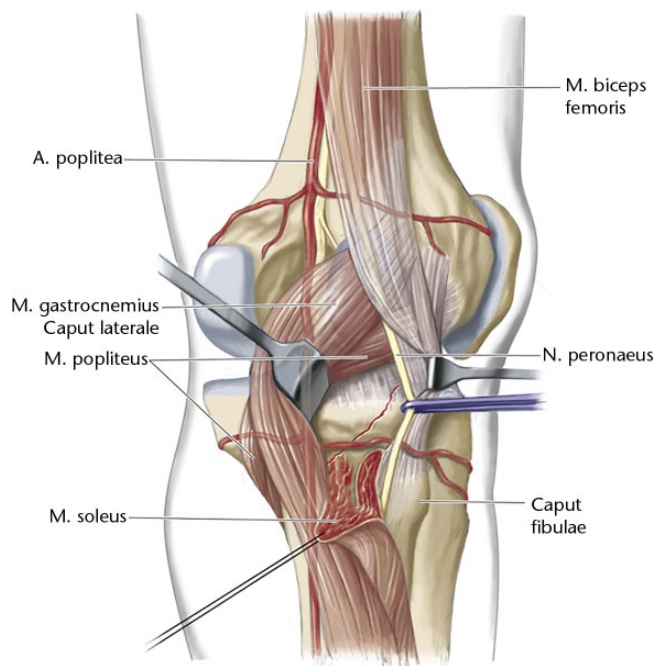


Fig. 4 A modified posterolateral approach between the soleus and the lateral head of the gastrocnemius (2), with blunt preparation of the popliteus muscle (held cranially) enables access to the posterolateral plateau. Reprinted from Frosch KH, Balcarek P, Walde T, Stürmer KM. A new posterolateral approach without fibula osteotomy for the treatment of tibial plateau fractures. *J Orthop Trauma* 2010;24:515-520, with permission from Wolters Kluwer Health.

lateral femoral epicondylar osteotomy¹⁵ or posterolateral approach may be necessary.

Posterolateral approach

To improve access to the posterolateral parts of the tibia in posterior partial fractures, a modified posterolateral approach may be helpful.¹⁶ In a lateral recumbent position, a skin incision is performed along the long biceps tendon and the proximal fibular line. Conventional anterolateral arthrotomy is suggested to visualise the joint. The common peroneal nerve is exposed and is protected until the surgery is finished.

First, dissection of the cavity between the head of the lateral gastrocnemius and the soleus muscle is conducted (Fig. 4), followed by blunt preparation between the popliteus muscle and soleus muscle without injuring the popliteal artery and vein. Holding the popliteus muscle cranially enables access to the posterolateral plateau. Fractures can be fixed using a posterolateral tibial LCP, a (small) 3.5 mm T-shaped LCDCP or, in some cases, a distal radius two-column LCP may fit. For larger or more difficult fragments, an additional temporary partial dissection of the fascia of the proximal soleus and/or an osteotomy of

the fibular head may improve exposure to the posterolateral fracture site.

Conventional medial approach

The medial tibial surface can be easily approached after performing a longitudinal skin incision. Although anteromedial partial proximal tibial fractures are rare,⁵ this approach may help to reduce and fix posterior or lateral partial tibial head fractures using retrograde K-wires or cannulated screws.⁸ In addition to the anteromedial tibial LCP and medial LISS-plate, the locked tomofix plate may be useful in selected cases. This approach can be easily extended both proximally and distally, and implant removal may be performed with little operative morbidity. However, if a second posteromedial or lateral incision is planned, care must be taken not to create an island of devascularised skin.

Posteromedial approach

Different techniques have been described to reduce posteromedial tibial head fractures.^{8,21,22} While some fractures can be reduced by retrograde cannulated screw osteosynthesis⁸ or by using an extended anteromedial approach,²¹ anterograde fixation of partial posteromedial fractures via a posteromedial approach²² offers direct visualisation of the fragment and a smaller incision compared with an extended anteromedial approach.

In a prone or side-lying position, the incision is performed longitudinally along the medial head of the gastrocnemius (Fig. 5). The medial border of the gastrocnemius muscle is palpated, bluntly prepared and carefully retracted laterally. Using a raspator, subperiosteal dissection of the popliteus muscle is performed and the semi-membranosus complex is retracted medially (Fig. 5). This procedure completely exposes the medial tibial condyle and the fracture may be fixed using screw osteosynthesis, small 2.7/3.5 mm LCDCP T-shaped-plates or distal radius two-column LCP.

Most posterocentral partial tibial head fractures can be reduced via a posteromedial or posterolateral approach, depending on the morphology of the fracture. Posterior cruciate ligament avulsion fractures of the tibial head are not considered to be partial tibial head fractures by the authors of this article. However, avulsions of the posterior cruciate ligament often involve larger fragments.²³ Although minimally invasive arthroscopic approaches to these fractures have been reported,²⁴ in cases of a dislocated fragment, the minimally invasive anterograde popliteal approach, which is a modified posteromedial approach with a smaller incision,²⁵ may enable better reduction of the fragment under direct vision. When incising the dorsal capsule, care must be taken not to injure the posterior cruciate ligament. If in doubt, a saline

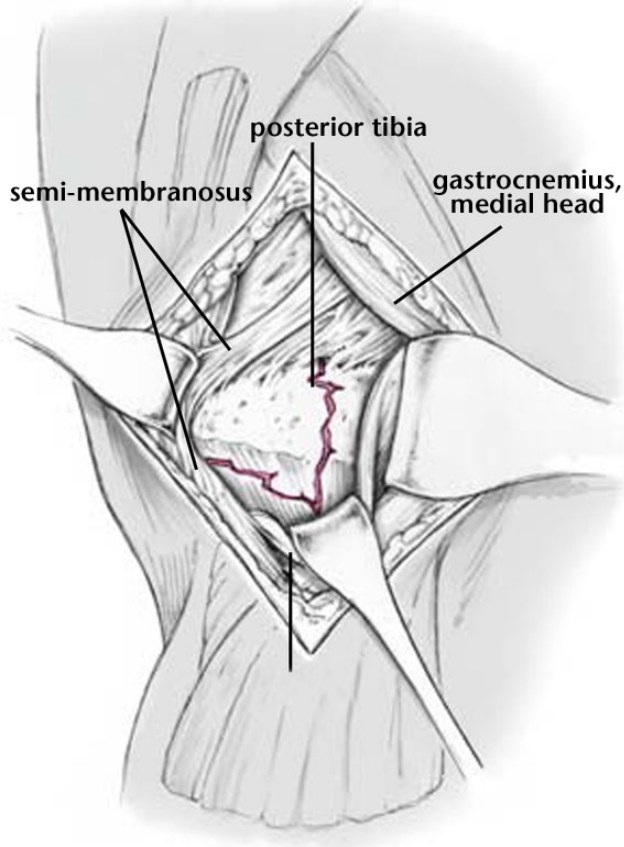


Fig. 5 For the posteromedial approach, the skin incision is performed along the medial head of the gastrocnemius. After blunt preparation, the semi-membranosus complex can be retracted medially and the medial gastrocnemius can be retracted laterally. After subperiosteal dissection of the popliteus muscle, the posteromedial tibia can be approached. Reprinted from Galla M, Riemer C, Lobenhoffer P. [Direct posterior approach for the treatment of posteromedial tibial head fractures]. *Oper Orthop Traumatol* 2009;21:51-64 (In German), with permission from Springer.

solution joint injection may help to clearly identify the capsule.

Osteotomies

To reduce extended anterolateral and posterolateral partial tibial head fractures, the conventional anterolateral approach may not provide enough vision of the whole fracture. Thus, the vision can be extended by performing an osteotomy of the fibula,^{13,14} the lateral femoral epicondyle^{15,17} or a combined submeniscal approach to better address the posterior fragments. The femoral epicondylar osteotomy¹⁵ has a lower risk for neurovascular damage compared with the proximal fibular osteotomy.^{13,14} In 90° flexion, the iliotibial tract is horizontally incised and the area around the lateral femoral epicondyle, including the insertions of the lateral collateral ligament and the

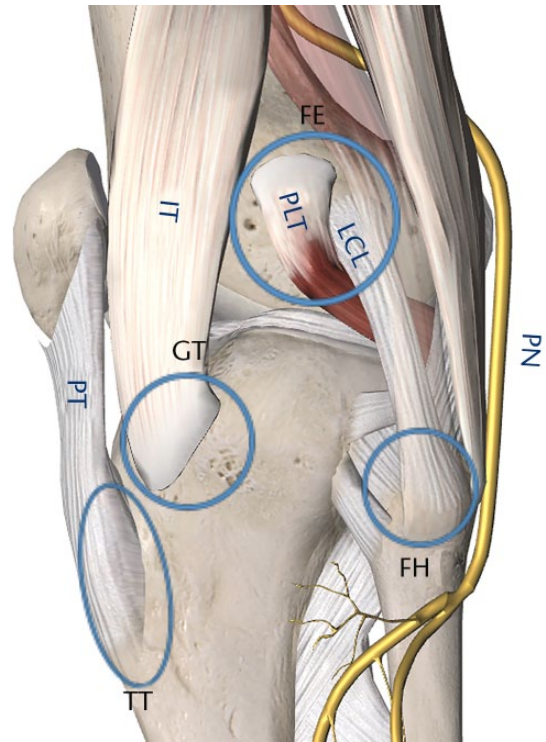


Fig. 6 Lateral view of the knee. Femoral epicondylar osteotomy (FE) is a safe distance from the common peroneal nerve (PN). Fibular head (FH) osteotomy also mobilises the distal biceps femoris insertions but the PN must be secured. Gerdy's tubercle osteotomy (GT) or tibial tuberosity osteotomy (TT) are additional, but rarely indicated, options. LCL, lateral collateral ligament; PLT, popliteus tendon; IT, iliotibial band; PT, patellar tendon. Images created with Essential Anatomy 5, 3D4 Medical.com

popliteus tendon, is identified and prepared. Epicondylar osteotomy is then performed circumferentially using a small osteotome and a micro-sagittal saw to create a bony wafer of 4 cm in diameter and 1 cm in depth.¹⁵ Care has to be taken not to injure the joint surface and to remember the clockwise orientation of the bony wafer. After fracture reduction, the epicondylar bony wafer can be re-positioned by one or two cancellous screws and washers.

Other osteotomy-like techniques for extended approaches of the tibial head have been reported (Fig. 6) and include fibular head partial resection,¹⁸ tibial tuberosity osteotomy¹⁹ and Gerdy's tubercle osteotomy,²⁰ which may help in selected cases to address relevant parts of the tibial plateau. However, due to a high risk of ligamentous and neurovascular damage, the indications for osteotomy should be evaluated carefully.

Arthroscopic reduction-internal fixation (ARIF) arthroscopically assisted reduction

In the case of a mild articular surface depression and an intact columnar wall (pure articular depression; Schatzker

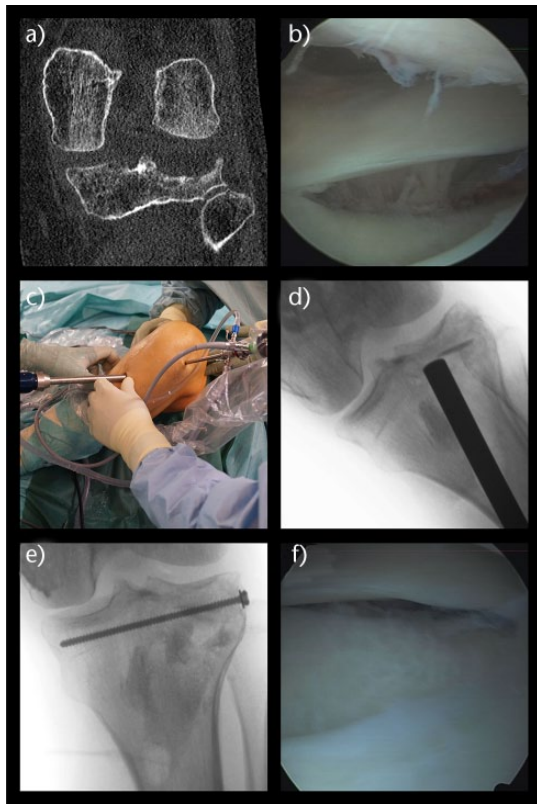


Fig. 7 Schatzker type III fractures ((a) zero column fractures; pure depression) can often be treated using arthroscopic reduction and internal fixation. The meniscus is elevated proximally (b) as a typical sign for this posterolateral depression fracture. The depressed region is accessed through an anteromedial approach using a hollow trephine (c, d) in order to minimise bone loss. A bone tamp is then used to elevate the depressed area under direct arthroscopic visualisation. Once joint congruity is restored, bone grafting and screw osteosynthesis (e) can be performed. As a sign of a perfect reduction, the meniscus should then be in its normal position (f).

Type III ‘zero-column fractures’ or AO Type B2), ARIF may be considered (Fig. 7).²⁶ This arthroscopic procedure has the benefit of a small skin incision as well as an optimal control of the articular reduction. Intra-articular pathologies (meniscus and cartilage damage) can also be evaluated and addressed, if necessary.

However, this technique is technically demanding and requires additional set-up. Operative planning includes the simultaneous use of the arthroscopic instruments, as well as a C-arm for detailed visualisation. The risk for compartment syndrome might be higher in comparison with conventional open reduction techniques.

Fixation techniques

If there are solitary fragments that can be fixated by screw osteosynthesis, a plate might not be necessary for fixation. However, this decision should be considered carefully, as

an angular stable plate provides increased stability and decreases the risk for secondary axial or horizontal displacement of fragments.²⁷ Additionally, in the osteoporotic bone, locked plates are considered to support with enhanced stability.²⁸

‘Jail’ technique

If performing screw osteosynthesis, stability of the elevated articular surface can be increased with a jail-type configuration of screws.²⁹ In a biomechanical study, a novel, minimally invasive reconstruction technique of lateral tibial plateau fractures using a three-screw ‘jail’ technique was compared with a conventional two-screw osteosynthesis technique (Fig. 8). A significant increase in the maximum load and a decrease in failure by cut-out was observed when using a ‘jail-type’ screw configuration.

Management of bone defects

Autograft, allograft or bone substitute

When managing impression fractures with loss of bone spongiosa substance, often bone substitutes are required to fill dead spaces. The perfect substitute should have high osteo-inductivity, osteogenicity and osteoconductivity.

The risks for harvest morbidity, infection rate and immunological reactions should be considered. Autograft of the iliac crest is still the ‘gold standard’ in terms of the aforementioned properties.³⁰ In some studies, however, graft substitutes have been favoured due to reduced total operative time, earlier weight-bearing and improved early functional outcome. In a systematic review, Goff et al³⁰ evaluated outcomes after the use of calcium phosphate cement, hydroxyapatite granules, calcium sulphate, bio-active glass, tricalcium phosphate, demineralised bone matrix, allografts and xenografts in tibial head fractures. Secondary collapse of the knee joint surface ≥ 2 mm, which was considered clinically relevant, was reported in 11.1% of the calcium sulphate cases, 8.6% of the biological substitute cases (allograft, demineralised bone matrix and xenograft), 5.4% of the hydroxyapatite cases and 3.7% of the calcium phosphate cement cases.³⁰ In cadaver studies, injectable calcium phosphate cement resulted in better stability and stiffness, which theoretically could reduce both the non-weight-bearing post-operative period and the secondary articular collapse. However, one has to be cautious because these are time-zero studies with their respective limitations.³⁰ There is limited evidence for higher osteo-integration of tricalcium phosphates in comparison with hydroxyapatites (Fig. 9).³⁰⁻³² This bone substitute may also fill subchondral bone defects without a gap, which may not be filled by biological repair tissue during healing.³²

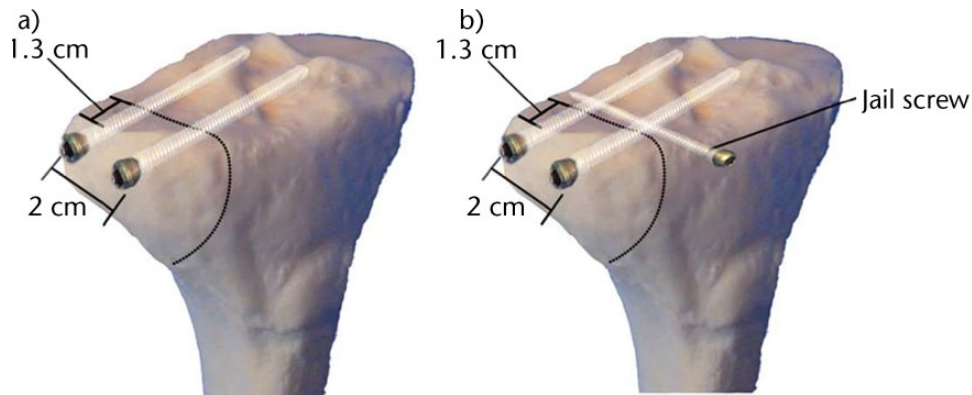


Fig. 8 Jail-type of screw configuration (b) in osteosynthesis may increase the maximum load and decrease cut-out failure vs conventional screw reconstruction (a). Provided by Weimann et al²⁹ and used with permission from BioMed Central.

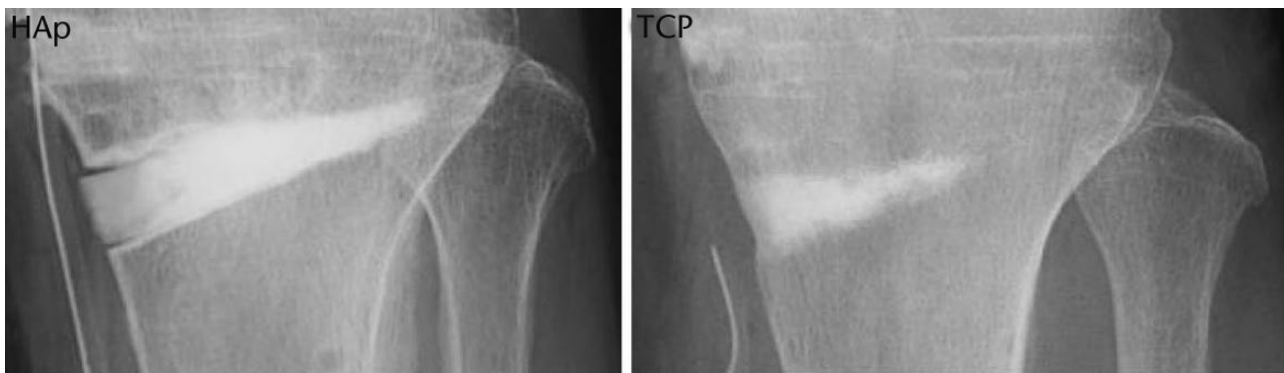

Fig. 9 Onodera et al³¹ found higher absorbability and osteoconductivity of tricalcium phosphate (TCP) spacers compared with hydroxyapatite spacers (HAp) in a retrospective comparative study of high tibial osteotomies. Reprinted from Onodera J, Kondo E, Omizu N, et al. Beta-tricalcium phosphate shows superior absorption rate and osteoconductivity compared to hydroxyapatite in open-wedge high tibial osteotomy. *Knee Surg Sports Traumatol Arthrosc* 2014;22:2763-2770, with permission from Springer.

In cases of symptomatic post-operative inflammatory response, septic and aseptic causes must be distinguished. When using biomaterials, the molecular surface may cause aseptic leukocyte proliferation and macrophage activation.³³

'To tourniquet or not to tourniquet?'

Using a tourniquet during surgery may improve visibility, reduce intra-operative blood loss and swelling during surgery, and may support PMMA cement interaction with bone when polymerising. Other than missed bleeding sources and time pressure within the 2-hour ischaemia interval, various other negative effects of tourniquet use have been reported in the current literature. Kruse et al³⁴ reported an increased post-operative opioid use in a prospective cohort study of patients who received ankle surgery with a correlation between opioid use and intra-operative tourniquet time. In a randomised trial of patients receiving total knee arthroplasty (TKA) with or without tourniquet, Dennis et al³⁵ determined that there were no differences in range of motion and strength, with the

exception of slightly lower quadriceps strength in the tourniquet group. Although intra-operative blood loss was reduced in the tourniquet group, there were no differences in total blood loss between both groups.³⁵ In a meta-analysis of 13 randomised controlled trials of studies that evaluated the effects of tourniquet use in TKA, Zhang et al³⁶ reported an increased risk for thromboembolic events when using a tourniquet (risk ratio (RR), 5.00; 95% confidence interval (CI), 1.31 to 19.10; $p = 0.02$). Other non-thromboembolic complications were also increased in the tourniquet group, such as infection, blistering, haematoma, wound oozing, bruising, nerve palsies and re-operation (RR, 2.03; 95% CI, 1.12 to 3.67; $p = 0.02$).³⁶

We suggest carefully considering whether fracture reduction of partial tibial head fractures can be performed without using a tourniquet.

Post-operative rehabilitation

Partial weight-bearing and early functional rehabilitation are recommended for at least six weeks in most cases after successful reduction and fixation with LCP have been

performed Unfortunately, evidence is still missing, and there may not be a ‘one size fits all’ post-operative rehabilitation scheme for every fracture type.^{27,37,38} In cases of osteopenic bones or losses of bone substance, a non-weight-bearing protocol might be indicated. Concomitant ligament injuries should also be considered when planning the rehabilitation protocol. Regardless of fracture type and concomitant injuries, full range of motion should be regained as soon as possible due to the high risk for developing a stiff knee joint. A hinged knee brace may be used in cases of a re-fixed collateral ligament. CT can be helpful to evaluate bone healing in cases of comminuted or impressed partial tibial head fractures.

If a unicondylar impression fracture was caused by a low-energy trauma in the elderly, this can be an indicator for osteopaenic bone mineral density. National guidelines for the treatment of osteoporosis suggest beginning with basic medical treatment (e.g. with 1000 IU of vitamin D per day or, in some cases, with calcium) in these cases. Further post-operative osteological investigation of bone mineral density by DXA or qCT and of endocrine status is suggested to evaluate whether the addition of bisphosphonates or other medications may be useful.³⁹

Knowing the fracture mechanism of partial proximal tibial fractures and classifying their morphology help to develop a peri-operative treatment strategy. Partial tibial head fractures can often be directly reduced using different approaches, which should be chosen depending on fracture location. Submeniscal arthrotomy, arthroscopy and osteotomies of the femoral epicondyle, the proximal fibula or Gerdy’s tubercle are useful tools to enhance visualisation of the joint or to decrease the invasiveness of the approach. Bone defects can be filled by iliac crest autograft, demineralised bone matrix or calcium phosphates. Osteoporosis and concomitant ligament injury should be diagnosed, peri-operatively addressed and considered for the rehabilitation strategy.

AUTHOR INFORMATION

Department of Trauma, Hand and Reconstructive Surgery, Westphalian Wilhelms University Muenster, Waldeyer Strasse 1, 48149 Muenster, Germany.

Correspondence should be sent to: Dr Michael J. Raschke, Department of Trauma, Hand and Reconstructive Surgery, Westphalian Wilhelms University Muenster, Waldeyer Strasse 1, 48149 Muenster, Germany.
Email: michael.raschke@ukmuenster.de

ICMJE CONFLICT OF INTEREST STATEMENT

None.

FUNDING

No benefits in any form have been received or will be received from a commercial party related directly or indirectly to the subject of this article.

LICENCE

© 2017 The author(s)

This article is distributed under the terms of the Creative Commons Attribution-Non-Commercial 4.0 International (CC BY-NC 4.0) licence (<https://creativecommons.org/licenses/by-nc/4.0/>) which permits non-commercial use, reproduction and distribution of the work without further permission provided the original work is attributed.

REFERENCES

1. Moore TM. Fracture–dislocation of the knee. *Clin Orthop Relat Res* 1981;156:128–140.
2. Müller ME, Koch P, Nazarian S, Schatzker J. *The Comprehensive Classification of Fractures of Long Bones*. Berlin, Heidelberg: Springer-Verlag Berlin Heidelberg, 1990:148–191.
3. Schatzker J, McBroom R, Bruce D. The tibial plateau fracture. The Toronto experience 1968–1975. *Clin Orthop Relat Res* 1979;138:94–104.
4. Luo CF, Sun H, Zhang B, Zeng BF. Three-column fixation for complex tibial plateau fractures. *J Orthop Trauma* 2010;24:683–692.
5. Krause M, Preiss A, Müller G, et al. Intra-articular tibial plateau fracture characteristics according to the “Ten segment classification”. *Injury* 2016;47:2551–2557.
6. Luo CF, Sun H, Zhang B, Zeng BF. Three-column fixation for complex tibial plateau fractures. *J Orthop Trauma* 2010;24:683–692.
7. Noble J, Alexander K. Studies of tibial subchondral bone density and its significance. *J Bone Joint Surg [Am]* 1985;67-A:295–302.
8. Morin V, Pailhé R, Sharma A, et al. Moore I postero-medial articular tibial fracture in alpine skiers: surgical management and return to sports activity. *Injury* 2016;47:1282–1287.
9. Acklin YP, Potocnik P, Sommer C. Compartment syndrome in dislocation and non-dislocation type proximal tibia fractures: analysis of 356 consecutive cases. *Arch Orthop Trauma Surg* 2012;132:227–231.
10. Aldebeyan W, Liddell A, Steffen T, Beckman L, Martineau PA. Proximal tibial fracture following anterior cruciate ligament reconstruction surgery: a biomechanical analysis of the tibial tunnel as a stress riser. *Knee Surg Sports Traumatol Arthrosc* 2015. [Epub ahead of print]
11. Prat-Fabregat S, Camacho-Carrasco P. Treatment strategy for tibial plateau fractures: an update. *EFORT Open Rev* 2016;1:225–232.
12. Honkonen SE. Indications for surgical treatment of tibial condyle fractures. *Clin Orthop Relat Res* 1994;302:199–205.
13. Lobenhoffer P, Gerich T, Bertram T, et al. [Particular posteromedial and posterolateral approaches for the treatment of tibial head fractures]. *Unfallchirurg* 1997;100:957–967. (In German)
14. Johnson EE, Timon S, Osuji C. Surgical technique: Tscherné–Johnson extensile approach for tibial plateau fractures. *Clin Orthop Relat Res* 2013;471:2760–2767.
15. Yoon YC, Sim JA, Kim DH, Lee BK. Combined lateral femoral epicondylar osteotomy and a submeniscal approach for the treatment of a tibial plateau fracture involving the posterolateral quadrant. *Injury* 2015;46:422–426.
16. Frosch KH, Balcarek P, Walde T, Stürmer KM. A new posterolateral approach without fibula osteotomy for the treatment of tibial plateau fractures. *J Orthop Trauma* 2010;24:515–520.
17. Hughston JC, Jacobson KE. Chronic posterolateral rotatory instability of the knee. *J Bone Joint Surg [Am]* 1985;67-A:351–359.
18. Yu B, Han K, Zhan C, et al. Fibular head osteotomy: a new approach for the treatment of lateral or posterolateral tibial plateau fractures. *Knee* 2010;17:313–318.

- 19. Lorbach O, Anagnostakos K, Kohn D.** [Osteotomy for approaches to the knee joint. Tibial tubercle, lateral epicondyle of the femur and head of the fibula]. *Orthopade* 2013;42:332-340. (In German)
- 20. Gavaskar AS, Gopalan H, Tummala NC, Srinivasan P.** The extended posterolateral approach for split depression lateral tibial plateau fractures extending into the posterior column: 2 years follow up results of a prospective study. *Injury* 2016;47:1497-1500.
- 21. Acklin YP, Potocnik P, Sommer C.** Extended medial approach in posteromedial proximal tibia fracture dislocation. *Oper Orthop Traumatol* 2015;27:183-190.
- 22. Galla M, Riemer C, Lobenhoffer P.** [Direct posterior approach for the treatment of posteromedial tibial head fractures]. *Oper Orthop Traumatol* 2009;21:51-64. (In German)
- 23. Griffith JF, Antonio GE, Tong CW, Ming CK.** Cruciate ligament avulsion fractures. *Arthroscopy* 2004;20:803-812.
- 24. Domnick C, Kösters C, Franke F, et al.** Biomechanical properties of different fixation techniques for posterior cruciate ligament avulsion fractures. *Arthroscopy* 2016;32:1065-1071.
- 25. Frosch K-, Proksch N, Preiss A, Giannakos A.** [Treatment of bony avulsions of the posterior cruciate ligament (PCL) by a minimally invasive dorsal approach]. *Oper Orthop Traumatol* 2012;24:348-353. (In German)
- 26. Herbort M, Domnick C, Petersen W.** [Arthroscopic treatment of tibial plateau fractures]. *Oper Orthop Traumatol* 2014;26:573-588. (In German)
- 27. Carrera I, Gelber PE, Chary G, et al.** Fixation of a split fracture of the lateral tibial plateau with a locking screw plate instead of cannulated screws would allow early weight bearing: a computational exploration. *Int Orthop* 2016;40:2163-2169.
- 28. Miranda MA.** Locking plate technology and its role in osteoporotic fractures. *Injury* 2007;38:S35-S39.
- 29. Weimann A, Heinkele T, Herbort M, et al.** Minimally invasive reconstruction of lateral tibial plateau fractures using the jail technique: a biomechanical study. *BMC Musculoskelet Disord* 2013;14:120.
- 30. Goff T, Kanakaris NK, Giannoudis PV.** Use of bone graft substitutes in the management of tibial plateau fractures. *Injury* 2013;44:S86-S94.
- 31. Onodera J, Kondo E, Omizu N, et al.** Beta-tricalcium phosphate shows superior absorption rate and osteoconductivity compared to hydroxyapatite in open-wedge high tibial osteotomy. *Knee Surg Sports Traumatol Arthrosc* 2014;22:2763-2770.
- 32. Matsuo T, Kita K, Mae T, et al.** Bone substitutes and implantation depths for subchondral bone repair in osteochondral defects of porcine knee joints. *Knee Surg Sports Traumatol Arthrosc* 2015;23:1401-1409.
- 33. Mestres G, Espanol M, Xia W, et al.** Inflammatory response to nano- and microstructured hydroxyapatite. *PLoS One* 2015;10:e0120381.
- 34. Kruse H, Christensen KP, Møller AM, Gögenur I.** Tourniquet use during ankle surgery leads to increased postoperative opioid use. *J Clin Anesth* 2015;27:380-384.
- 35. Dennis DA, Kittelson AJ, Yang CC, et al.** Does tourniquet use in TKA affect recovery of lower extremity strength and function? A randomized trial. *Clin Orthop Relat Res* 2016;474:69-77.
- 36. Zhang W, Li N, Chen S, et al.** The effects of a tourniquet used in total knee arthroplasty: a meta-analysis. *J Orthop Surg Res* 2014;9:13.
- 37. Haak KT, Palm H, Holck K, et al.** Immediate weight-bearing after osteosynthesis of proximal tibial fractures may be allowed. *Dan Med J* 2012;59:A4515.
- 38. Solomon LB, Callary SA, Stevenson AW, et al.** Weight-bearing-induced displacement and migration over time of fracture fragments following split depression fractures of the lateral tibial plateau: a case series with radiostereometric analysis. *J Bone Joint Surg [Br]* 2011;93-B:817-823.
- 39. Cosman F, de Beur SJ, LeBoff MS, et al.** Clinician's guide to prevention and treatment of osteoporosis. *Osteoporosis Int* 2014;25:2359-2381.