

Contents lists available at [ScienceDirect](http://www.sciencedirect.com)

International Journal of Surgery Case Reports

journal homepage: www.casereports.com

Synchronous mucinous adenocarcinoma of the recto sigmoid revealed by and seeding an anal fistula. (A case report and review of the literature)



Konstadinos G. Spiridakis*, Elefterios E. Sfakianakis, Manthos E. Flamourakis, Dimitra S. Intzepogazoglou, Eleni S. Tsagataki, Nikolaos E. Ximeris, Efstathios K. Rachmanis, Ioannis G. Gionis, Giorgos E. Kostakis, Manousos S. Christodoulakis

Venizeleio General Hospital, Department of Surgery, Heraklion, Crete, Greece

ARTICLE INFO

Article history:

Received 10 May 2017

Received in revised form 1 June 2017

Accepted 4 June 2017

Available online 8 June 2017

Keywords:

Case report

Extralevator abdominoperineal resection

Anal fistula

Rectosigmoid cancer

ABSTRACT

INTRODUCTION: There are few cases of synchronous rectal adenocarcinoma revealed by an anal fistula. The diagnosis of synchronous mucinous adenocarcinoma of the recto sigmoid and anal canal remains difficult. The chronic anal fistula can be mistaken as the common manifestation of a benign perianal abscess or fistula.

CASE PRESENTATION: We present a rare case of a Greek Caucasian 79 year old male patient with anal fistula and a recurrent perianal abscess who subsequently was found to have developed synchronous rectosigmoid and perianal mucinous adenocarcinoma on biopsy. The histological exam revealed mucinous adenocarcinoma in two sites, representing two tumors, cells were immunopositive for cytokeratin 20 and negative in cytokeratin 7. The patient underwent "laparoscopic extralevator abdominoperineal excision" with both lesions being resected. There is no recurrence after four years of follow up.

CONCLUSIONS: This case highlights the importance of high suspicion, further investigation and the need of biopsy in all anal fistulae.

© 2017 The Authors. Published by Elsevier Ltd on behalf of IJS Publishing Group Ltd. This is an open access article under the CC BY-NC-ND license (<http://creativecommons.org/licenses/by-nc-nd/4.0/>).

1. Introduction

Synchronous rectosigmoid mucinous adenocarcinoma seeding an anal fistula is a very rare condition. Diagnosis is difficult especially when primary tumor remains unknown and the chronic lesion of anal fistula seems to be a benign condition. The management of these cases remain controversial. We present a rare case of chronic anal fistula with the presence of a recurrent perianal abscess with synchronous rectosigmoid mucinous adenocarcinoma, treated with laparoscopic extralevator abdominoperineal resection. A persistent anal fistula with recurrent inflammation is known to lead to primary cancer, and such cancer develops in 0,1%

of all anal fistulae [1,2]. This case highlights the importance of further investigation and the need of biopsy in anal fistulae. Our case has been reported in line with the SCARE criteria [3], a 14-item checklist that was formulated to help improve the reporting quality of case reports.

2. Case presentation

A Caucasian Greek 79 years old male presented in our general hospital for investigation of an anal fistula with a recurrent perianal abscess that was treated as a benign condition. (Fig. 1) Clinical examination revealed the presence of a longstanding perianal fistula which appeared to be transsphincteric. The patient underwent pelvis Magnetic Resonance Imaging (Fig. 2) and colonoscopy. Biopsy was taken the histopathology examination revealed a well differentiated mucinous adenocarcinoma in two synchronous tumors with CK20 markers positive and CK7 markers negative. The possibility of primary cancer in the rectosigmoid with metastatic seeding in the perianal fistula could not be excluded.

The patient underwent laparoscopic abdominoperineal resection with complete excision of both lesions (Fig. 3) and the pelvic floor was strengthened by a biological mesh (Fig. 4) The histologi-

Abbreviations: CK7, Cytokeratin 7; CK20, Cytokeratin20.

* Corresponding author.

E-mail addresses: spiridakiskgiorgos@gmail.com

(K.G. Spiridakis), elsfakianakis@windowslive.com (E.E. Sfakianakis), manthosflamourakis@gmail.com (M.E. Flamourakis), demmie.intz@gmail.com (D.S. Intzepogazoglou), elina.1992@hotmail.com (E.S. Tsagataki), Ximerismed@yahoo.gr (N.E. Ximeris), srachmanis@yahoo.gr (E.K. Rachmanis), ioannsigionis@hotmail.com (I.G. Gionis), Gkost2000@yahoo.gr (G.E. Kostakis), Cristom7@gmail.com (M.S. Christodoulakis).

<http://dx.doi.org/10.1016/j.ijscr.2017.06.001>

2210-2612/© 2017 The Authors. Published by Elsevier Ltd on behalf of IJS Publishing Group Ltd. This is an open access article under the CC BY-NC-ND license (<http://creativecommons.org/licenses/by-nc-nd/4.0/>).

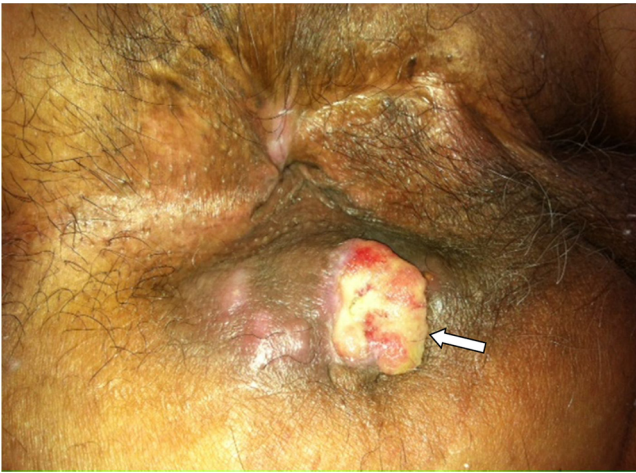

Fig. 1. Peri-anal fistula before surgery.

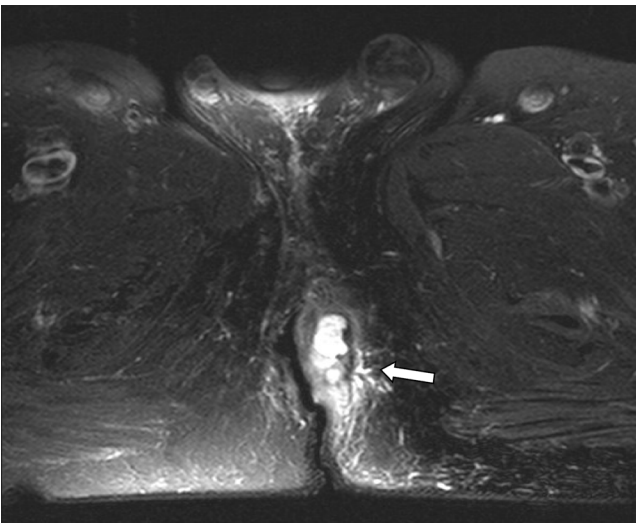


Fig. 2. Fistula presenting in pelvic MRI.

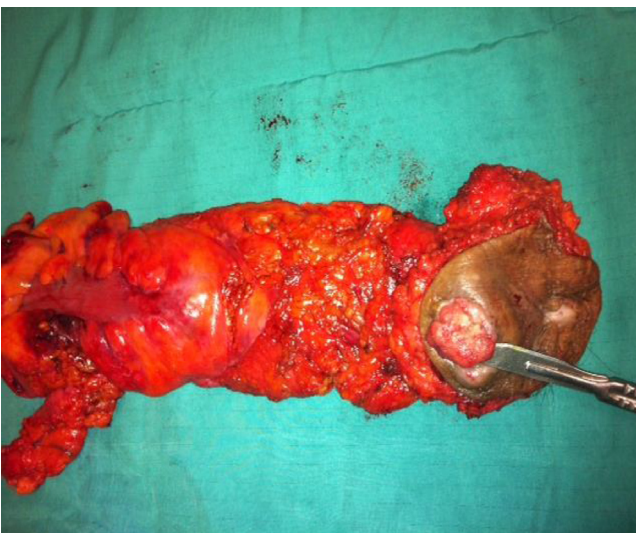

Fig. 3. Surgical specimen.

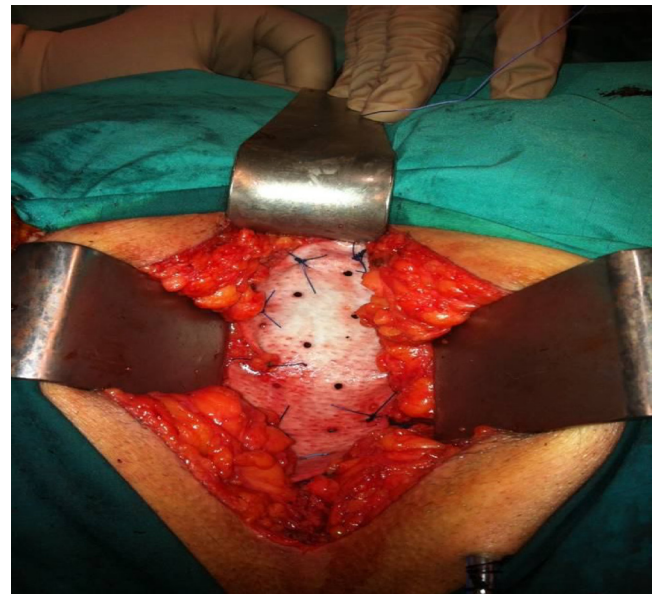


Fig. 4. Pelvis floor construction with biological mesh.

cal examination of the resection margin confirmed the diagnosis of well differentiated mucinous adenocarcinoma with 34 lymph nodes in the pericolic fat with maximum diameter of 0,2–0,7 cm, all negative for cancerous infiltration (T3N0M0). The resection margin was classified as R0. The postoperative course of the patient was normal. He was discharged on the 6th postoperative day.

3. Discussion

Synchronous adenocarcinoma of the rectosigmoid, seeding in an anal fistula, presenting as a recurrent perianal abscess is extremely rare. Symptoms in these patients appear due to their perianal disease. That's why the coexisting carcinoma is missed. There is an important observation about sex prevalence, all cases reported were male except only one female. In all cases of fistula and perianal abscess it is very important that histological examination is performed [4,5,6].

For the first time in 1907 Charles Ryall reported implantation metastasis of solid cancers and described this phenomenon as cancer infection [5,7,8].

The first case of cancer implantation to a perianal fistula was reported in 1954 by Guiss and al. Since then, more cases have been reported and metastasis of colorectal cancer into a perianal fistula has become accepted even if the management remains a matter of controversy [7]. In our case, the symptoms of our patient was attributed to his perianal disease and the primary carcinoma was missed. It is important that clinicians who manage patients with anal fistulae and recurrent perianal abscesses to refer them for further colonic investigation (colonoscopy and biopsies) in order to exclude the possibility of primary carcinoma.

Rosser in 1931 first described the following basic criteria which determine if a fistula has undergone malignant transformation. These include persistence of anal fistula for more than ten years, presence of mucous secretion, no evidence of tumor in the rectal or anal canal mucosa and internal opening of the fistula negative of malignancy [9,10].

Sumikoski, Skir and McIntyre et al. and Rundle [10–12] established the diagnostic criteria for primary cancer in anal fistula:

- 1) recurring inflammation of the fistula for at least ten years
- 2) Secretion of mucous

- 3) pain and induration at the fistula
- 4) no primary cancer at the rectum and anus and
- 5) presence of fistula orifice in the anal canal or presence of anal crypt.

There are 24 reported cases of colonic adenocarcinoma seeding into anal fistula [4,13–25] and the vast majority of cases regard male patients [5]. Marker as CK20 and CK7 can be useful in distinguishing the original from the metastatic carcinoma as the literature reports [4,5].

Remalingam et al. have described that anal glands were strongly immunoreactive for CK20 and negative for CK7. In this case both lesions are negative for CK7 and positive for CK20 [26].

The histogenesis of a carcinoma in anal fistula remains controversial. There are many theories about this. Dukes and Calvin suggested that such tumors arise via an unusual duplication of the mucosa [27]. Zimberg and Kay showed that even for tumors arising from anal fistula the most common site is the anal gland [28]. Also Nielsen and Koch report the same theory [29] Taniguchi et al. reported that these tumors originate from the rectal mucosal cells that migrate into the anal canal [30]. However the histogenesis of these carcinomas remains unclear.

The management of these cases remain controversial. There are no specific recommendations. In some cases authors suggest abdominoperineal resection in others local resection is proposed. The 5 years survival rate is less than 20% in most series [31].

In our case the patient underwent surgery. Laparoscopic extralevator abdominoperineal excision with both lesions resection (adenocarcinoma of rectosigmoid and adenocarcinoma of the anal fistula) was performed. The pelvic floor was strengthened by a biological mesh.

4. Conclusions

The diagnosis of synchronous mucinous adenocarcinoma of the rectosigmoid and anal fistula, a very rare condition is not always easy to be established, and remains difficult when the colonic tumor is unknown and the chronic lesion of anal fistula seems to be a benign condition. Furthermore, the treatment is still controversial. We reported the case of a patient who was treated with extralevator abdominoperineal resection. There is no recurrence after four years of follow up. A better prognosis is expected in the future by using different modalities of treatment. This case highlights the importance of suspicion in recurrence of anal fistula and the importance of biopsy in all anal fistulae.

Conflicts of interest

The authors declare that they have no competing interests.

Funding

No founding source was available for this study.

Ethical approval

No applicable.

Consent

Written informed consent was obtained from the patient for publication of this case report and any accompanying images. A copy of the written consent is available for review by the Editor-in-Chief of this journal.

Author contribution

KGS and EES analyzed and interpreted the patient data and were the major contributors to the writing of the manuscript. MEF and DSI participated in the design and coordination, EST, NEX, EKR, GEK and MSC helped to draft the manuscript. All authors performed the surgical treatment and the post surgery observation of the patient. All authors read and approved the final manuscript.

Registration of research studies

No applicable.

Guarantor

No applicable.

Acknowledgment

No applicable.

References

- [1] Rina Takahashi, Ryosuke Ichikawa, Singo Ito, Kosuke Mizukoshi, Shun Ishiyama, Kiichi Sgimoto, Yutaka Kojima, Michitoshi Goto, Yuichi Tomiki, Takashi Yao, Kazuhiro Sakamoto, A case of metastatic carcinoma of anal fistula caused by implantation from rectal cancer, *Surg. Case Rep.* 1 (December) (2015) 123.
- [2] A.K. McNally, M.B. Dockerty, Carcinoma developing in chronic draining cutaneous sinuses and fistulas, *Surg. Gynecol. Obstet.* 88 (1949) 87–96.
- [3] R.A. Agha, A.J. Fowler, A. Saetta, I. Barai, S. Rajmohan, D.P. Orgill, the SCARE Group, The SCARE Statement: consensus-based surgical case report guidelines, *Int. J. Surg.* 34 (2016) 180–186.
- [4] B. Benjelloun El, S. Aitalalim, L. Chbani, I. Mellouki, K. Mazaz, K. Aittaleb, Rectosigmoid adenocarcinoma revealed by metastatic anal fistula. The visible part of the iceberg: a report of two cases with literature review, *J. Surg. Oncol.* 10 (2012) 209, <http://dx.doi.org/10.1186/1477-7819-10-209>.
- [5] R. Al-Hadithi, M. Alorjani, A. Aboujoukh, T. Al-Jaberi, A. Almanasrah, A. El-hennawi, Synchronous adenocarcinoma of rectosigmoid and perianal fistula: report of a case, *Internet J. Pathol.* 11 (2009) 1.
- [6] C. Ryall, Cancer infection and cancer recurrence, *Lancet* 2 (1907) 1311–1316.
- [7] R.L. Guiss, The implantation of cancer cell within a fistula in ano, *Surgery* 36 (1954) 136–139.
- [8] C. Rosser, The aetiology of anal cancer, *Am. J. Surg.* 11 (1931) 328–333.
- [9] R.M. Gomes, R.K. Kumar, A. Desouza, A. Saklani, Implantation metastasis from adenocarcinoma of the sigmoid colon into a perianal fistula: a case report, *Ann Gastroenterol.* 27 (2014) 276–279.
- [10] I. Skir, Mucinous carcinoma associated with fistulas of long-standing, *Am. J. Surg.* 75 (1948) 285–289.
- [11] J.M. McIntyre, Carcinoma associated with fistula-in-ano, *Am. J. Surg.* 84 (1952) 610–613.
- [12] M. Hamada, K. Ozaki, J. Iwata, Y. Nishioka, T. Horimi, A case of rectosigmoid cancer metastasizing to a fistula in ano, *Jpn. J. Clin. Oncol.* 35 (November (11)) (2005) 676–679.
- [13] I.H. Parnes, An interesting case of cancer of the sigmoid with concomitant cancer in anal fistula, *Mt. Sinai J. Med.* 43 (1976) 476–479.
- [14] P.D. Rollinson, S.A.C. Dundas, Adenocarcinoma of sigmoid colon seeding into pre-existing fistula-in-ano, *Br. J. Surg.* 71 (1984) 664–665.
- [15] K. Ueta, N. Umekita, T. Matsumine, A case of metastatic carcinoma found at an anal fistula, *J. Jpn. Surg. Assoc.* 52 (1991) 1323–1326, in Japanese.
- [16] H. Tohira, N. Imai, K. Tateyama, Y. Ozeki, S. Yamamoto, A case of rectal cancer seeding to anal fistula, *Geka* 60 (1998) 853–856, in Japanese.
- [17] K. Tokuhara, H. Yamanaka, D. Ito, T. Koshiba, M. Sato, M. Kogire, A case of metastatic carcinoma at an anal fistula, *Jpn. J. Gastroenterol. Surg.* 34 (2001) 1690–1694, in Japanese.
- [18] H. Yoshimura, T. Ienaga, S. Ueda, T. Ota, A case of metastatic carcinoma of anal fistula caused implantation from rectal cancer, *Jpn. J. Gastroenterol. Surg.* 34 (2001) 1363–1366.
- [19] G. Kouraklis, A. Glinavou, M. Kouvaraki, J. Raftopoulos, G. Karatzas, Anal lesion resulting from implantation of viable tumor cells in a pre-existing anal fistula. A case report, *Acta Chir. Belg.* 102 (2002) 212–213.
- [20] N. Yagihashi, T. Ohsawa, J. Narita, T. Iwabuchi, T. Tsuge, A case of carcinomametastatic to an anal fistula treated by pelvic exenteration, *J. Jpn. Surg. Assoc.* 63 (2002) 2224–2228, in Japanese.
- [21] G. Gravante, D. Delogu, D. Venditti, Colosigmoid adenocarcinoma. anastomotic recurrence seeding into a transsphincteric fistula-in-ano: a clinical report and literature review, *Surg. Laparosc. Endosc. Percutan. Tech.* 18 (2008) 407–408.

- [22] R. Gupta, M. Kay, D.W. Birch, Implantation metastasis from adenocarcinoma of the colon into a fistula-in-ano: a case report, *Can. J. Surg.* 48 (2005) 162–163.
- [23] Y. Tomimaru, M. Ohue, S. Noura, T. Tanida, I. Miyashiro, M. Yano, H. Ohigashi, Y. Sasaki, O. Ishikawa, S. Imaoka, A case of anal fistula cancer probably developing from intraluminal dissemination of rectal cancer, *Gan Kagaku Ryoho* 32 (2005) 1776–1778, in Japanese.
- [24] M. Hamada, K. Ozaki, J. Iwata, Y. Nishioka, T. Horimi, A case of rectosigmoid cancer metastasizing to a fistula in ano, *Jpn. J. Clin. Oncol.* 35 (2005) 676–679.
- [25] S. Ishiyama, S. Inoue, K. Kobayashi, Y. Sano, N. Kushida, Y. Yamazaki, K. Yanaga, Implantation of rectal cancer in an anal fistula: report of a case, *Surg. Today* 36 (8) (2006) 747–749.
- [26] P. Ramalingam, W.R. Hart, J.R. Goldblum, Cytokeratin subset immunostaining in rectal adenocarcinoma and normal anal glands, *Arch. Pathol. Lab. Med.* 125 (2001) 1074–1077.
- [27] C.E. Dukes, C. Galvin, Colloid carcinoma arising within fistulae in the anorectal region, *Ann. R. Surg. Engl.* 18 (1956) 246–261.
- [28] Y.H. Zimberg, S. Kay, Anorectal carcinomas of extramucosal origin, *Ann. Surg.* 145 (1957) 344–354.
- [29] O.V. Nielsen, F. Koch, Carcinomas of anorectal region of extramucosal origin with special reference to anal ducts, *Acta Chir. Scand.* 139 (1973) 299–305.
- [30] S. Taniguchi, H. Yamanari, K. Inada, et al., Adenocarcinoma in the anal canal associated with a fistula: report of a case, *Surg. Today* 26 (1996) 707–710.
- [31] Tomoko Seya, Noritake Tanaka, Seiichi Shinji, Kimiyoshi Yokoi, Tatsuo Oguro, Yoshiharu Oaki, Toshiyuki Ishiwata, Zenya Naito, Takashi Tajiri, Squamous cell carcinoma arising from recurrent anal fistula, *J. Nippon Med. Sch.* 74 (August (4)) (2007) 319–324.

Open Access

This article is published Open Access at [sciencedirect.com](https://www.scienceopen.com). It is distributed under the [IJSCR Supplemental terms and conditions](#), which permits unrestricted non commercial use, distribution, and reproduction in any medium, provided the original authors and source are credited.