

Use of Allogenic Mesenchymal Cellular Bone Matrix in Anterior and Posterior Cervical Spinal Fusion: A Case Series of 21 Patients

Srikanth Naga Divi¹, Mark M. Mikhael^{1,2,3}

¹Department of Orthopaedic Surgery, University of Chicago Medical Center, Chicago, IL, USA

²Illinois Bone and Joint Institute, Glenview, IL, USA

³Department of Orthopaedic Surgery, NorthShore University Health System, Evanston, IL, USA

Study Design: Retrospective case series.

Purpose: To report our early experience using allogenic mesenchymal cellular bone matrix (CBM) products in cervical spine fusion.

Overview of Literature: Multi-level cervical fusions have historically yielded lower fusion rates than single level fusions, especially in patients with high risk medical comorbidities. At this time, significant literature in cervical fusion outcomes with this cellular allograft technology is lacking.

Methods: Twenty-one patients underwent either multilevel (3 or 4 level) anterior cervical discectomy and fusion, anterior cervical corpectomy and fusion, or posterior cervical fusion. ViviGen (DePuy Synthes Spine, Raynham, MA, USA), an allogenic bone matrix product, was used in addition to standard instrumentation. Radiographic evaluation was performed at 2 weeks, 12 weeks, 24 weeks and 1 year postoperative. Visual analog scale (VAS) and neck disability index (NDI) scores along with return to work and leisure activity were recorded.

Results: At 6 months postoperative, all patients had radiographic evidence of bone fusion regardless of age or medical comorbidities. All patients reported subjective improvement with a mean decrease in VAS from 8.3 to 1.5 and a mean decrease in NDI from 40.3% to 6.0% at 1 year. All patients also returned to work and/or regular leisure activity within 3 months.

Conclusions: Twenty-one patients undergoing high-risk anterior and posterior cervical spine fusion, with the use of a commercially available mesenchymal CBM product, went on to radiographic fusion and all had improvement in subjective outcomes. While further effort and research is needed to validate its widespread use, this study shows favorable use of CBM in cervical fusion for high-risk cases.

Keywords: Bone matrix; Bone substitute; Allograft; Spinal fusion; Cervical vertebrae

Introduction

Cervical fusion is a commonly performed treatment modality for a wide range of cervical pathologies that do not respond to conservative treatment. Trends over the past

two decades have shown that the rates of spinal arthrodesis as a reason for inpatient admission have been increasing at a faster rate than other orthopaedic procedures [1]. Concurrent with this increase in surgical volume has been the development and expansion of biologics in assisting

Received Sep 5, 2016; Revised Oct 12, 2016; Accepted Nov 3, 2016

Corresponding author: Srikanth Naga Divi

Department of Orthopaedic Surgery, University of Chicago Medical Center,
5841 S. Maryland Avenue, MC 3079, Chicago, IL 60637, USA

Tel: +1-773-834-2858, Fax: +1-773-702-4384, E-mail: srikanth.divi@uchospitals.edu

spinal fusion. Historically, the gold standard for augmentation in spinal fusion has been the use of autogenous iliac crest bone graft (ICBG) [2]. This type of bone graft is readily available and provides osteoconductive, osteoinductive and osteogenic elements for differentiation and proliferation of new bone. However, the use of ICBG also has several drawbacks including donor site morbidity, increase in operative time, and variable quality of autograft [3]. Individual patient biology can alter the quality of autograft since it is influenced by age, medical comorbidities, metabolic diseases, and modifiable risk factors such as smoking [2]. As an alternative to ICBG, local autograft salvaged from bone removed in the surgical site can also be used to aid fusion and reduces the need for extraspinal bone harvest. This method however, often does not produce the volume needed for the fusion site, especially in cervical spine surgery.

Alternatives to ICBG in spine fusion include the use of allograft, graft extenders and osteobiologic materials to increase rates of fusion [4]. All of these methods achieve their objective using one or more of the principles of osteoconduction, osteoinduction or osteogenesis [4]. Cellular bone matrix (CBM) products comprise of harvested allograft bone with a native mesenchymal stem cell population and represent a combination of all three principles. Several companies now manufacture readily available CBM products containing mesenchymal stem cells for use in spine fusion surgeries. Only a few industry sponsored studies have been published thus far regarding the use of these products, mostly investigating use in lumbar procedures.

In this study, we present our experience in a case series of patients undergoing either multilevel anterior cervical

discectomy and fusion (ACDF), anterior cervical corpectomy and fusion (ACCF), or posterior cervical fusion (PCF) with the use of a CBM product for achieving spinal fusion. Some patients had a combination of medical and surgical risk factors that placed them at higher risk for nonunion. This study is not industry sponsored. At this point, the literature lacks early surgeon experience with use of these products in the cervical spine.

Materials and Methods

Retrospective chart review was conducted to identify patients from 2013 to 2015 that underwent multilevel (>1 level) anterior or posterior cervical fusion with the use of allogenic mesenchymal CBM augmentation. All surgeries were performed by one orthopaedic spine surgeon at a single institution. All of the cases included the use of commercially available mesenchymal CBM (ViviGen,




Fig. 1. Cellular bone matrix product after it has been thawed intraoperatively.



Fig. 2. (A, B) Thawed bone matrix is prepared by implantation after removal of cryopreservation media with rinsing solution.

DePuy Synthes Spine, Raynham, MA, USA). The bone matrix is shown in its original packaging (Fig. 1) after it is thawed intraoperatively. It is then prepared with removal of cryopreservation media with a rinsing solution before it is ready for application into surgical fusion site (Fig. 2). Anterior cases involved using a standard anterior approach to the cervical spine. For all anterior discectomy cases, the CBM product was placed within the center opening of a freeze-dried allograft spacer (BIO AVS, Stryker Spine, Kalamazoo, MI, USA) and placed within the disc spaces following discectomy (Fig. 3). In anterior corpectomy cases, the CBM product was placed within a carbon fiber reinforced polymer spacer (Bengal, DePuy Synthes Spine, Raynham, MA, USA) and placed to bridge between the superior and inferior vertebral bodies following corpectomy and decompression (Fig. 4). For all anterior cases, a standard titanium plate and screws (MaxAn, Zimmer Biomet, Broomfield, CO, USA) was used to span across the fusion levels. All posterior cases were performed using a standard midline approach. Posterior fixation included either occipital plating, lateral mass screw fixation, or pedicle screw fixation with connecting rods (Synapse, DePuy Synthes Spine, Raynham, MA, USA) (Fig. 5). Allograft bone chips were mixed with the mesenchymal CBM and placed posterolaterally

following decortication to create a fusion mass. In all cases, the same commercial bone matrix product was used. Patients were admitted after surgery for postoperative monitoring of drain output and neurological function. After discharge, patients were seen in clinic in the 2 week, 6 week, 3 month, 6 month and 1 year postoperative time frame.

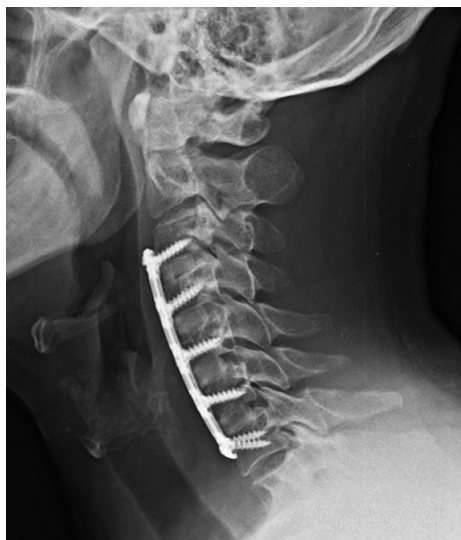

Fig. 3. Three-month postoperative lateral radiograph of a 4-level anterior cervical discectomy and fusion utilizing allograft bone spacers and spanning titanium plate fixation. At 3 months, there is no evidence of graft subsidence and early graft incorporation is evident at the endplate interfaces.

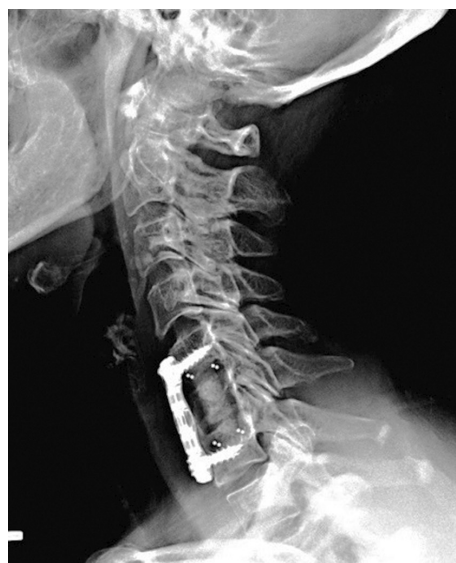

Fig. 4. One-year postoperative lateral radiograph demonstrating a C6 corpectomy with a carbon fiber reinforced polymer cage filled with cellular bone matrix bone material and spanning titanium plate fixation.

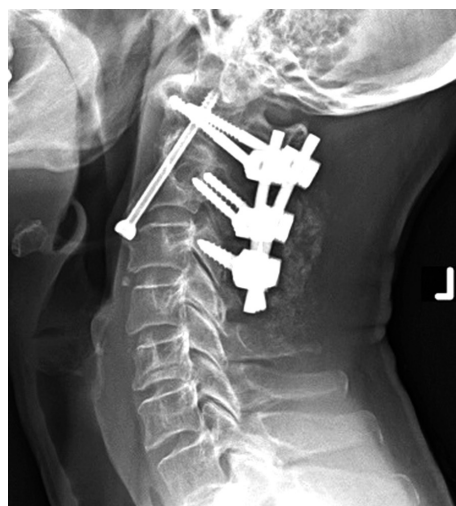


Fig. 5. Three-month postoperative lateral radiograph of posterior fixation performed for odontoid screw nonunion. Note the dorsal fusion mass evident at 3-months postoperative.

Results

Twenty-one patients resulted from our medical chart query and are summarized in Table 1. The ages of patients ranged from 39–84 years old. Fourteen were female and seven were male. The most common diagnosis and indication for surgery was cervical myelopathy. In seven patients, this was due to cervical spondylotic myelopathy, whereas in two patients this was secondary to a herniated nucleus pulposus, and in three patients this was secondary to ossification of the posterior longitudinal ligament. Six patients underwent surgery for a diagnosis of cervical radiculopathy secondary to spondylosis. Finally, three patients underwent surgery for C1–C2 instability, where one had instability secondary to rheumatoid arthritis (RA),

another had instability secondary to unstable fractures, and lastly one patient had instability due to prior attempted odontoid fixation with resultant nonunion (Fig. 5).

Radiographic examination revealed that all 21 patients demonstrated fusion mass evident on serial X-rays performed at 2 weeks, 3 months, 6 months, and 12 months. Although a CT scan was not obtained in all the patients because of favorable clinical outcomes, findings of bridging fusion mass were incidentally observed on those patients who did undergo CT scanning (Fig. 6). Clinically, all 21 patients demonstrated overall improvement with average decrease in VAS scores from 8.3 to 1.5. NDI scores showed similar improvements with an average of 40.3% preoperatively to an average of 6.0% at 1-year postoperatively (Table 2). The average decrease in VAS and NDI

Table 1. All 21 patients undergoing cervical fusion with associated diagnoses, comorbidities and complications

Patient	Procedure	Diagnosis	Age/Sex	Comorbidities	Complications
1	3 Level ACDF	CSM	39/Female	None	None
2	3 Level ACDF	CSM	69/Male	CAD, plavix/ASA	Hematoma evacuation
3	3 Level ACDF	Spondylosis, radiculopathy	58/Male	DMII, smoker, obesity	None
4	3 Level ACDF	Spondylosis, radiculopathy	67/Female	Obesity	None
5	3 Level ACDF	Spondylosis, radiculopathy	44/Female	Obesity, smoker	None
6	3 Level ACDF	Spondylosis, radiculopathy	63/Female	None	None
7	4 Level ACDF	Spondylosis, radiculopathy	59/Male	Smoker, DMII	None
8	4 Level ACDF	Spondylosis, radiculopathy	64/Male	DMII, obesity	None
9	C6 Corp, C5 to 7 ACF	HNP, myelopathy	59/Male	Smoker	None
10	C5 Corp, C4 to 6 ACF	HNP, myelopathy	69/Female	DMI	None
11	C5 Corp, C4 to 6 ACF	CSM	68/Female	Smoker, DMII	None
12	C3 to T1 PSF	CSM	84/Female	RA, Chronic steroid use	Delayed wound healing
13	C3 to T1 PSF	OPLL, myelopathy	53/Male	DMII	None
14	C3 to T1 PSF	OPLL, myelopathy	64/Male	Obesity, DMII	None
15	C4 to T1 PSF	CSM	67/Female	Obesity	None
16	C3 to C7 PSF	CSM	77/Female	None	C5 nerve palsy, resolved
17	C3 to C7	CSM	70/Female	COPD, chronic steroid use, plavix	None
18	C3 to C6 PSF	OPLL, myelopathy	56/Female	DMII, RA	Delayed wound healing
19	Occ to C4 PSF	C1, C2 unstable fractures	83/Female	None	Delayed wound healing
20	Occ to C3 PSF	C1-2 instability	84/Female	RA, chronic steroid use	None
21	C1 to C3 PSF	Odontoid nonunion	56/Female	None	None

All 21 patients undergoing cervical fusion with associated diagnoses, comorbidities and complications.

ACDF, anterior cervical discectomy and fusion; CSM, cervical spondylotic myelopathy; CAD, coronary artery disease; ASA, aspirin; Corp, corpectomy; DMII, diabetes mellitus type 2; ACF, anterior cervical fusion; HNP, herniated nucleus pulposus; DMI, diabetes mellitus type 1; PSF, posterior spinal fusion; RA, rheumatoid arthritis; OPLL, opacification of the posterior longitudinal ligament; COPD, chronic obstructive pulmonary disease; Occ, occipital.

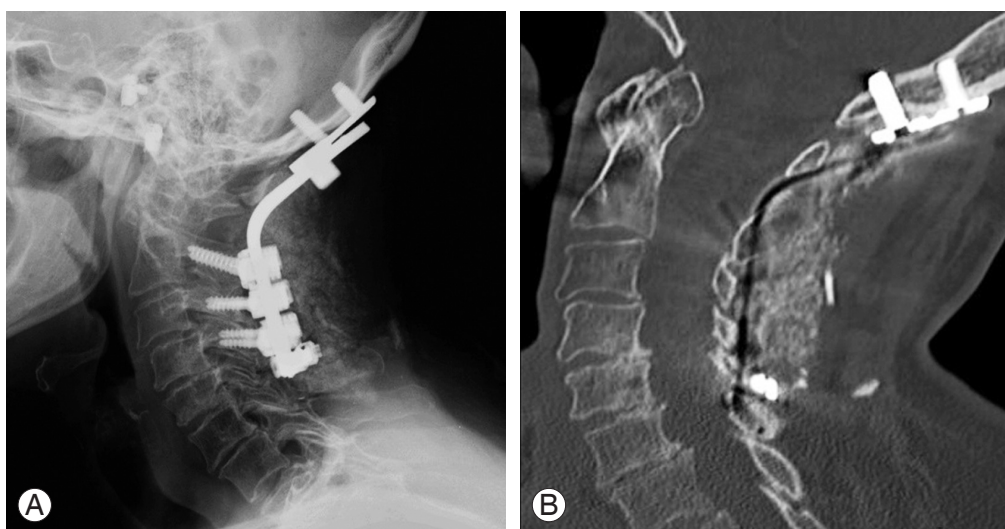


Fig. 6. (A) One year postoperative lateral radiograph of occipital cervical fusion. (B) Computed tomography section of same patient performed at 14 months postoperative after ground level fall demonstrating bridging dorsal fusion mass across the occipital cervical junction.

Table 2. Preoperative and 12 month postoperative VAS and NDI scores are listed along with the percentage decrease in scores

Patient	VAS			NDI		
	Preoperative	12 mo	% decrease	Preoperative (%)	12 mo (%)	% decrease
1	6	1	-83.3	30	4	-86.7
2	7	1	-85.7	26	4	-84.6
3	10	2	-80.0	30	2	-93.3
4	10	2	-80.0	42	2	-95.2
5	9	1	-88.9	26	2	-92.3
6	9	1	-88.9	26	2	-92.3
7	8	2	-75.0	28	2	-92.9
8	9	2	-77.8	40	2	-95.0
9	7	2	-71.4	46	10	-78.3
10	6	1	-83.3	40	4	-90.0
11	7	1	-85.7	32	6	-81.3
12	7	2	-71.4	46	6	-87.0
13	10	2	-80.0	52	8	-84.6
14	8	2	-75.0	50	8	-84.0
15	8	1	-87.5	48	8	-83.3
16	9	1	-88.9	38	6	-84.2
17	8	1	-87.5	50	6	-88.0
18	7	2	-71.4	52	10	-80.8
19	9	2	-77.8	50	14	-72.0
20	10	1	-90.0	52	12	-76.9
21	10	2	-80.0	44	8	-81.8

Preoperative and 12 month postoperative VAS and NDI scores are listed along with the percentage decrease in scores. NDI was scored as a percentage out of 100.

VAS, visual analog scale; NDI, neck disability index.

compared to preoperative scores were 81.4% and 85.9%, respectively. Despite postoperative complications listed in Table 1, all patients returned to their preoperative work and/or leisure activity within 3 months postoperatively.

Discussion

Patients undergoing multilevel fusion are at a higher risk for pseudarthrosis postoperatively than patients undergoing single level fusion [5,6]. While reported rates of pseudarthrosis for ACDF vary in literature, previous studies have consistently shown an inverse correlation with fusion rate and the number of levels being fused [7,8]. In studies conducted by Wang et al. [7,8] two and three level ACDFs without anterior plating were reported to have pseudarthrosis rates of 25% and 37% respectively, whereas pseudarthrosis rates with anterior plating were reported as 0 and 18% respectively. The advent of anterior support with plate fixation was designed to decrease shear force and micro-motion at the graft-bone interface, providing an optimal environment for healing and increasing fusion rates. With increased levels of fusion, there are more graft-bone interfaces to heal to create a successful fusion mass. A recent retrospective study looking at a large national database found nonunion rates of 2.9% and 6.5% for two and three level ACDFs, respectively [9], which are similar to previously reported retrospective rates [10,11]. Another recent retrospective review analyzed outcomes of three and four level fusions and found nonunion rates of 5.6% and 15.4% [12]. While the advent of anterior plating has helped to decrease overall pseudarthrosis rates, obtaining fusion in multilevel cases can still be problematic and the appropriate use osteobiologics may help increase overall success.

Posterior cervical fusion is used in cases of multilevel cervical spondylosis without significant kyphosis or in cases of revision fusion surgeries. In particular, the upper cervical spine posits a problematic area to effectively achieve fusion. Primary stability after sublaminar wiring techniques and bone grafting is poor, requiring prolonged periods of postop immobilization and high rates of non-unions [13]. Harm's or Magerl's techniques represent advancement in upper posterior fusion surgery, however, despite improved fusion rates from the past, they are both complex and require in-depth knowledge of cervical anatomy [14]. One systematic review of occipital cervical fusion outcomes noted comparable fusion rates and lower

complication rates with posterior screw and rod instrumentation compared to posterior wiring and in-lay bone grafting [15]. Used in this setting, allogenic bone grafting has the potential to increase fusion rates while keeping complication rates lower.

Recombinant human bone morphogenic proteins (rh-BMP) use in the cervical spine is considered "off-label" and has not been approved by the Food and Drug Administration [4,16]. Early prospective studies using recombinant human bone morphogenetic protein 2 (rhBMP-2) in anterior cervical spine surgery showed encouraging results, however later retrospective studies showed increased rate of complications, including "neck swelling" presenting as hematoma, dysphagia, or breathing difficulties in the BMP allograft group [17-19]. Similarly, there have been relatively few studies assessing the use of rhBMP in posterior cervical spine fusion. Two prior studies have shown satisfactory rates of PCF after the use of rhBMP-2 [20,21], however case reports of patients with catastrophic neurological decline due to postoperative seroma may prevent rhBMP from being used on a routine basis in cervical spine surgery [22]. Due to these reasons, CBM may offer a readily available and safe alternative to rhBMP in cervical spine fusion.

In this case series, we reviewed 21 patients undergoing multilevel anterior and posterior cervical fusion at a single institution under a single surgeon using allogenic mesenchymal CBM. In particular, these patients represent high-risk cases for nonunion, malunion, failure of implants due to their medical comorbidities. Eight patients had a history of diabetes mellitus, five patients were active smokers, six patients were clinically obese, three patients had a history of RA, and two patients had a history of chronic steroid use. Smoking has been analyzed extensively in the lumbar spine and is known to be a risk factor for lower fusion rates and delayed fusion, however recent studies have also shown this to hold true in cervical fusion as well [23]. Obesity on the other hand, may contribute to longer hospital rates, infection rates, and total cost of surgery but does not appear to affect fusion rates itself [24]. Other medical comorbidities such as inflammatory spine disorders (e.g. RA, ankylosing spondylitis), and type 2 diabetes mellitus increase overall time for recovery from surgery and increase risk for perioperative complications.

Several companies now manufacture readily available CBM products for use in spine fusion surgeries. Osteocel Plus (NuVasive, San Diego, CA), ViviGen (DePuy Synthes

Spine, Raynham, MA, USA), Bio4 (Stryker, Kalamazoo, MI, USA), Trinity Elite and Trinity Evolution (Orthofix, Lewisville, TX, USA), AlloStem (AlloSource, Centennial, CO, USA) are all examples of commonly available CBM products containing mesenchymal stem cells for use in spine fusion. Only a few studies have been published thus far regarding the use of CBM products and several prospective studies are currently underway. These describe the use of Osteocel Plus in lumbar lateral interbody fusion, transforaminal interbody fusion, as well as anterior cervical discectomy and fusion [25-28]. They generally report fusion rates 90% or greater at the 12 or 24 month point using a combination of plain films and computed tomography scans. A recent multicenter study looking at patients with 12 months of follow-up after undergoing single level ACDF with a commercial CBM product noted an overall fusion rate of 93.5% that persisted even when stratifying for patients with high risk factors (history of smoking, diabetes, obesity/severe obesity) [29]. In our study, patients underwent multilevel fusion and only 5 out of the 21 patients had no medical risk factors for adverse outcomes. Thus, our study adds to the current literature by showing improved fusion outcomes of high risk patients. Given these results, it is conceivable that CBM products can be considered as an adjunct in spinal fusion, especially for patients at higher risk for nonunions.

There are several limitations in our case series presented here. Because this is a retrospective series of 21 patients and not a prospective, controlled study, we do not have a control arm. However, given these encouraging early results, a future prospective, controlled study can be conducted to address this drawback and effectively compare outcomes with a control group. This would further clarify further advantages conferred with using CBM. In addition, fusion postoperatively was assessed with serial radiographic examination with flexion and extension views at the 2 week, 6 week, 3 month, 6 month and 1 year time points postoperatively and only those with questionable fusion underwent CT scanning for evaluation. This can be addressed in a future prospective study by a standardized protocol that includes routine postoperative CT for evaluation of fusion. Patients also underwent anterior or posterior surgery based on evaluation by the treating surgeon and their presenting pathology. No preoperative standardization towards an anterior vs. posterior approach was performed since this was a retrospective case series. This is also a single center study with a relatively homogeneous

patient population, which limits generalizability.

Conclusions

This study presents our early experience in a case series of patients undergoing either multilevel ACDF, ACCF, or PCF with the use of a CBM product for achieving spinal fusion. At this point, the literature lacks early surgeon experience with use of these products in the cervical spine and most of the studies available are typically industry funded. Despite the variance in medical and surgical risk factors that placed these patients at higher risk for nonunion, all patients went onto satisfactory radiographic fusion at their 6 and 12 month follow-up visits without any major medical or surgical complications. Additionally, all patients showed improved VAS and NDI scores and returned to their preoperative work and/or leisure activity within 3 months postoperatively. While it is conceivable that CBM products can be considered as an adjunct in spinal fusion, especially for patients at higher risk for nonunions, further studies and investigation are warranted.

Conflict of Interest

No potential conflict of interest relevant to this article was reported.

ORCID

Srikanth Naga Divi: 0000-0002-5776-2044

Mark M. Mikhael: 0000-0003-4966-007X

References

1. Rajae SS, Bae HW, Kanim LE, Delamarter RB. Spinal fusion in the United States: analysis of trends from 1998 to 2008. *Spine (Phila Pa 1976)* 2012;37:67-76.
2. Skovrlj B, Guzman JZ, Al Maaieh M, Cho SK, Iatridis JC, Qureshi SA. Cellular bone matrices: viable stem cell-containing bone graft substitutes. *Spine J* 2014; 14:2763-72.
3. Arrington ED, Smith WJ, Chambers HG, Bucknell AL, Davino NA. Complications of iliac crest bone graft harvesting. *Clin Orthop Relat Res* 1996;(329): 300-9.
4. Grabowski G, Cornett CA. Bone graft and bone graft

- substitutes in spine surgery: current concepts and controversies. *J Am Acad Orthop Surg* 2013;21:51-60.
5. Shriver MF, Lewis DJ, Kshetry VR, Rosenbaum BP, Benzel EC, Mroz TE. Pseudoarthrosis rates in anterior cervical discectomy and fusion: a meta-analysis. *Spine J* 2015;15:2016-27.
 6. El-Tantawy A. Is it possible to eliminate the plate-related problems and still achieve satisfactory outcome after multilevel anterior cervical discectomy? *Eur J Orthop Surg Traumatol* 2015;25 Suppl 1:S135-45.
 7. Wang JC, McDonough PW, Endow KK, Delamarter RB. Increased fusion rates with cervical plating for two-level anterior cervical discectomy and fusion. *Spine (Phila Pa 1976)* 2000;25:41-5.
 8. Wang JC, McDonough PW, Kanim LE, Endow KK, Delamarter RB. Increased fusion rates with cervical plating for three-level anterior cervical discectomy and fusion. *Spine (Phila Pa 1976)* 2001;26:643-6.
 9. Guppy KH, Harris J, Paxton LW, Alvarez JL, Bernbeck JA. Reoperation Rates for Symptomatic Non-unions in Anterior Cervical Fusions From a National Spine Registry. *Spine (Phila Pa 1976)* 2015;40:1632-7.
 10. Singh K, Phillips FM, Park DK, Pelton MA, An HS, Goldberg EJ. Factors affecting reoperations after anterior cervical discectomy and fusion within and outside of a Federal Drug Administration investigational device exemption cervical disc replacement trial. *Spine J* 2012;12:372-8.
 11. Samartzis D, Shen FH, Matthews DK, Yoon ST, Goldberg EJ, An HS. Comparison of allograft to autograft in multilevel anterior cervical discectomy and fusion with rigid plate fixation. *Spine J* 2003;3:451-9.
 12. De la Garza-Ramos R, Xu R, Ramhmdani S, et al. Long-term clinical outcomes following 3- and 4-level anterior cervical discectomy and fusion. *J Neurosurg Spine* 2016;24:885-91.
 13. De Iure F, Donthineni R, Boriani S. Outcomes of C1 and C2 posterior screw fixation for upper cervical spine fusion. *Eur Spine J* 2009;18 Suppl 1:2-6.
 14. Jacobson ME, Khan SN, An HS. C1-C2 posterior fixation: indications, technique, and results. *Orthop Clin North Am* 2012;43:11-8.
 15. Winegar CD, Lawrence JP, Friel BC, et al. A systematic review of occipital cervical fusion: techniques and outcomes. *J Neurosurg Spine* 2010;13:5-16.
 16. Lebl DR. Bone morphogenetic protein in complex cervical spine surgery: a safe biologic adjunct? *World J Orthop* 2013;4:53-7.
 17. Shields LB, Raque GH, Glassman SD, et al. Adverse effects associated with high-dose recombinant human bone morphogenetic protein-2 use in anterior cervical spine fusion. *Spine (Phila Pa 1976)* 2006;31:542-7.
 18. Smucker JD, Rhee JM, Singh K, Yoon ST, Heller JG. Increased swelling complications associated with off-label usage of rhBMP-2 in the anterior cervical spine. *Spine (Phila Pa 1976)* 2006;31:2813-9.
 19. Vaidya R, Weir R, Sethi A, Meisterling S, Hakeos W, Wybo CD. Interbody fusion with allograft and rhBMP-2 leads to consistent fusion but early subsidence. *J Bone Joint Surg Br* 2007;89:342-5.
 20. Xu R, Bydon M, Sciubba DM, et al. Safety and efficacy of rhBMP2 in posterior cervical spinal fusion for subaxial degenerative spine disease: Analysis of outcomes in 204 patients. *Surg Neurol Int* 2011;2:109.
 21. Crawford CH 3rd, Carreon LY, McGinnis MD, Campbell MJ, Glassman SD. Perioperative complications of recombinant human bone morphogenetic protein-2 on an absorbable collagen sponge versus iliac crest bone graft for posterior cervical arthrodesis. *Spine (Phila Pa 1976)* 2009;34:1390-4.
 22. Anderson DW, Burton DC, Jackson RS. Postoperative cervical myelopathy and cord compression associated with the use of recombinant bone morphogenetic protein-2 in posterior cervical decompression, instrumentation, and arthrodesis: a report of two cases. *Spine (Phila Pa 1976)* 2011;36:E682-6.
 23. Hilibrand AS, Fye MA, Emery SE, Palumbo MA, Bohlman HH. Impact of smoking on the outcome of anterior cervical arthrodesis with interbody or strutting. *J Bone Joint Surg Am* 2001;83:668-73.
 24. Higgins DM, Mallory GW, Planchard RF, et al. Understanding the impact of obesity on short-term outcomes and in-hospital costs after instrumented spinal fusion. *Neurosurgery* 2016;78:127-32.
 25. Ammerman JM, Libricz J, Ammerman MD. The role of Osteocel Plus as a fusion substrate in minimally invasive instrumented transforaminal lumbar interbody fusion. *Clin Neurol Neurosurg* 2013;115:991-4.
 26. Tohmeh AG, Watson B, Tohmeh M, Zielinski XJ. Allograft cellular bone matrix in extreme lateral interbody fusion: preliminary radiographic and clinical outcomes. *ScientificWorldJournal* 2012;2012:263637.
 27. Eastlack RK, Garfin SR, Brown CR, Meyer SC. Os-

- teocel Plus cellular allograft in anterior cervical discectomy and fusion: evaluation of clinical and radiographic outcomes from a prospective multicenter study. *Spine (Phila Pa 1976)* 2014;39:E1331-7.
28. Kerr EJ 3rd, Jawahar A, Wooten T, Kay S, Cavanaugh DA, Nunley PD. The use of osteo-conductive stem-cells allograft in lumbar interbody fusion procedures: an alternative to recombinant human bone morphogenetic protein. *J Surg Orthop Adv* 2011;20:193-7.
29. Vanichkachorn J, Peppers T, Bullard D, Stanley SK, Linovitz RJ, Ryaby JT. A prospective clinical and radiographic 12-month outcome study of patients undergoing single-level anterior cervical discectomy and fusion for symptomatic cervical degenerative disc disease utilizing a novel viable allogeneic, cancellous, bone matrix (trinity evolution™) with a comparison to historical controls. *Eur Spine J* 2016;25:2233-8.