

Observational Study

New totally intracorporeal reconstructive approach after robotic total gastrectomy: Technical details and short-term outcomes

Amilcare Parisi, Francesco Ricci, Alessandro Gemini, Stefano Trastulli, Roberto Cirocchi, Giorgio Palazzini, Vito D'Andrea, Jacopo Desiderio

Amilcare Parisi, Francesco Ricci, Alessandro Gemini, Stefano Trastulli, Roberto Cirocchi, Jacopo Desiderio, Department of Digestive Surgery, St. Mary's Hospital of Terni, University of Perugia, 05100 Terni, Italy

Roberto Cirocchi, Department of General Surgery, St. Mary's Hospital of Terni, University of Perugia, 05100 Terni, Italy

Giorgio Palazzini, Vito D'Andrea, Department of Surgical Science, "La Sapienza" University, 00185 Rome, Italy

Author contributions: Parisi A and Desiderio J were involved in study conception and design; Parisi A, Ricci F, Gemini A, Trastulli S, Cirocchi R, Palazzini G, D'Andrea V and Desiderio J collected data and were involved in critical revision and drafting of the final manuscript.

Institutional review board statement: The study was approved by the region ethics committee (CEAS Umbria).

Informed consent statement: Not required for the present study.

Conflict-of-interest statement: No benefits in any form have been received or will be received from a commercial party related directly or indirectly to the subject of this article.

Data sharing statement: Technical appendix available from the corresponding author at djdesi85@hotmail.it.

Open-Access: This article is an open-access article which was selected by an in-house editor and fully peer-reviewed by external reviewers. It is distributed in accordance with the Creative Commons Attribution Non Commercial (CC BY-NC 4.0) license, which permits others to distribute, remix, adapt, build upon this work non-commercially, and license their derivative works on different terms, provided the original work is properly cited and the use is non-commercial. See: <http://creativecommons.org/licenses/by-nc/4.0/>

Manuscript source: Invited manuscript

Correspondence to: Jacopo Desiderio, MD, Department of Digestive Surgery, St. Mary's Hospital of Terni, University of Perugia, Via Tristano di Joannuccio 1, 05100 Terni, Italy. jacopo.desiderio@studenti.unipg.it
Telephone: +39-349-7531121
Fax: +39-744-205078

Received: January 25, 2017

Peer-review started: February 1, 2017

First decision: March 3, 2017

Revised: March 31, 2017

Accepted: May 9, 2017

Article in press: May 9, 2017

Published online: June 21, 2017

Abstract

AIM

To show outcomes of our series of patients that underwent a total gastrectomy with a robotic approach and highlight the technical details of a proposed solution for the reconstruction phase.

METHODS

Data of gastrectomies performed from May 2014 to October 2016, were extracted and analyzed. Basic characteristics of patients, surgical and clinical outcomes were reported. The technique for reconstruction (Parisi Technique) consists on a loop of bowel shifted up antecolic to directly perform the esophago-enteric anastomosis followed by a second loop, measured up to 40 cm starting from the esojejunosomy, fixed to the biliary limb to create an enteroenteric anastomosis. The continuity between the two anastomoses is interrupted

just firing a linear stapler, so obtaining the Roux-en-Y by avoiding to interrupt the mesentery.

RESULTS

Fifty-five patients were considered in the present analysis. Estimated blood loss was 126.55 ± 73 mL, no conversions to open surgery occurred, R0 resections were obtained in all cases. Hospital stay was 5 (3-17) d, no anastomotic leakage occurred. Overall, a fast functional recovery was shown with a median of 3 (3-6) d in starting a solid diet.

CONCLUSION

Robotic surgery and the adoption of a tailored reconstruction technique have increased the feasibility and safety of a minimally invasive approach for total gastrectomy. The present series of patients shows its implementation in a western center with satisfying short-term outcomes.

Key words: Esophagojejunal anastomosis; Gastric cancer; Total gastrectomy; Robotic surgery; Minimally invasive surgery

© **The Author(s) 2017.** Published by Baishideng Publishing Group Inc. All rights reserved.

Core tip: Minimally invasive surgery is growing interest for gastric cancer. Technology has allowed to increase the safety and feasibility of this approach, even in demanding procedures. Total gastrectomy represents a challenge in this context due to the need to ensure a safe esophagojejunal anastomosis. Leakages can strongly influence the postoperative course of the patient until lead to serious consequences.

Parisi A, Ricci F, Gemini A, Trastulli S, Cirocchi R, Palazzini G, D'Andrea V, Desiderio J. New totally intracorporeal reconstructive approach after robotic total gastrectomy: Technical details and short-term outcomes. *World J Gastroenterol* 2017; 23(23): 4293-4302 Available from: URL: <http://www.wjgnet.com/1007-9327/full/v23/i23/4293.htm> DOI: <http://dx.doi.org/10.3748/wjg.v23.i23.4293>

INTRODUCTION

Minimally invasive surgery for gastric cancer is growing attention due to its potential advantages in enhancing the postoperative recovery of patients and quality of life^[1]. The main limitations are the proper execution of an extended lymphadenectomy, when required, and a safe approach for reconstruction.

The latter is still the object of controversy and most surgeons are concerned about the possibility to perform a totally intracorporeal procedure after a total gastrectomy.

Recent spread of the robotic systems has modi-

fied the way we perform minimally invasive surgery and has led to the evolution of traditional laparoscopy. This progress allows surgeons to overcome the limits of laparoscopy through a 3D vision, articulated instruments, filtering of physiological tremor and absence of fulcrum effects, thus increasing dexterity and precision in dissection and suturing movements. These are key factors required for complex and technical demanding reconstructions to restore the digestive continuity.

However, nowadays, few studies^[2] have discussed about reconstruction techniques for minimally invasive gastric surgery even if this issue is the most impacted factor on postoperative outcomes.

Hybrid procedures are common described in the literature, in most of cases an extracorporeal reconstruction approach has been adopted because allows to easily overcome the difficulties of an intracorporeal Roux-en-y procedure.

The main limitations surgeons have in minimally invasive reconstruction after total gastrectomy are: reduced freedom of movements in the pneumoperitoneum space, properly identification of the segment of small bowel for the E-J anastomosis and then the level where perform the Jejunojejunal anastomosis. Moreover, traditional laparoscopic instruments cannot enable a hand-sewn anastomosis, thus surgeons have adopted techniques based on the use of mechanical staplers. However, intrinsic limitations of these methods should be considered when approaching an intracorporeal anastomosis involving the esophagus.

This study aims to show outcomes after adopting a new robot-sewn intracorporeal reconstruction technique after total gastrectomy, conceived at our Institution, that can simplify and make friendly this challenging phase.

MATERIALS AND METHODS

Type of study

This is a single-institution observational study, evaluating a new reconstruction approach after total gastrectomy. The study was registered at clinical trials.gov with the registration number: NCT02325453.

Eligibility

Patients with the following characteristics were included: preoperative staging assessment in accordance to international guidelines^[3,4], Early Gastric Cancer, Advanced Gastric Cancer, curative surgery, robotic surgical approach. Exclusion criteria were: metastatic disease, palliative resection, synchronous malignancy in other organs, synchronous other major abdominal surgery, high operative risk (ASA > 4).

Data collection

Data of gastrectomies performed from May 2014 to

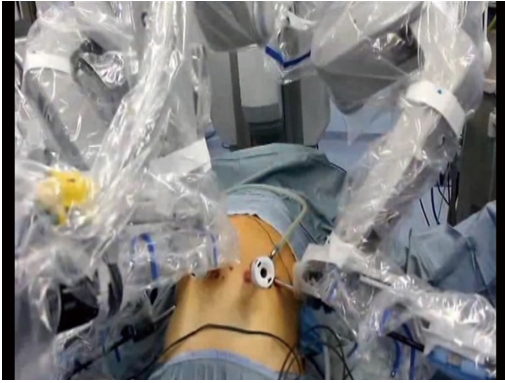

Figure 1 Robotic docking.

October 2016, at St. Mary's Hospital of Terni (Italy), were extracted and analyzed.

Data were collected by reviewing medical records and surgeries performed^[5]. A tailored web-based protected system was used (<https://imigastric.logix-software.it/>).

The present study was planned and developed in accordance with the STROBE guidelines and statement^[6].

Reported outcomes

Descriptive information on characteristics of patients, details of procedures and tumor findings were reported.

Operative results, data on the postoperative course and assessment of complications were based on the following primary outcomes: Estimated blood loss (EBL, mL), retrieved lymphnodes (No.), hospital stay (d), resumption of a liquid and solid diet (POD), in-hospital complications (No., Type), 30 d readmission (No.).

Secondary outcomes included: the operative time (min), margin status (No. negative/total) and R assessment (No. R0 resections), intraoperative complications and death (No.), resumption of peristalsis (POD).

Statistical analysis

IBM SPSS Statistics V.23 was used in this study and an intention to treat analysis was performed. Continuous variables were reported as mean \pm SD or median and range. Numbers and percentages were used to express dichotomous variables.

Surgical technique

A 4-arm Da Vinci SI Robotic Surgical System is used during the procedure (Figure 1). The surgical technique can be divided into six phases: (1) coloepiploic mobilization; (2) ligation of the right gastroepiploic artery; (3) ligation of the right gastric artery and section of the duodenum; (4) lymphadenectomy of major vessels; (5) section of the esophagus; and (6) double-loop reconstruction method (Parisi Technique).

The pneumoperitoneum is created with a Veress

needle in the peri-umbilical region. The intra-abdominal pressure is set to 12 mmHg.

The mobilization of the stomach can be performed by either traditional laparoscopy or robotic surgery, depending on patient characteristics and surgeon preferences.

First, a complete coloepiploic mobilization is achieved using the harmonic scalpel from right to left and the epiploon retrocavity is opened. During this phase lymph stations no. 4d, 4sa and 4sb are isolated and removed.

During the second phase the superior right colic vein is identified and the trunk of Henle is found. After this step, the gastroepiploic vein is sectioned at its origin. The right gastroepiploic artery is tied between hem-o-locks at its origin and the lymph nodes in station no. 6 are removed.

The first portion of the duodenum is released and the assistant introduces an articulated linear stapler for its section.

The lymphadenectomy of major vessels begins at the level of the proper hepatic artery.

The right gastric artery is identified and sectioned between hem-o-locks, at its origin, thus removing station no. 5. The lesser omentum is also dissected releasing station no. 3.

All the soft tissue along up to hepatic pedicle is removed including station no. 12a. Station no.8 is removed from the common hepatic artery. The dissection continues to the left of side of the celiac trunk to remove the station no. 9. Station no. 7 is dissected and the left gastric artery is sectioned. The splenic artery is followed and station no. 11p is removed, while the tissue on the proximal part of the artery (11p) is cleared based on the tumor and patient characteristics. Station no. 10 is not routinely dissected, because the high risk of major injuries due to anatomical characteristics of western patients that almost always does not allow a safety dissection of that area.

Finally, the soft tissue representing station no. 1 and no. 2 is dissected, thus releasing the esophagus and the anterior and posterior branches of the Vagus nerve which are sectioned.

In the last phase, the digestive continuity is restored with the Parisi Technique (Figure 2). Two stitches are placed to secure the esophagus to the diaphragm pillars (Figure 3). Then, the assistant temporarily removes the robotic arm no. 2 and changes the robotic trocar (8 mm) with a 12 mm trocar in order to introduce the stapler with the correct angle of section.

The esophagus is thereby sectioned and closed (Figure 3), through the mechanical linear stapler, considering the right distance from the tumor and avoiding tensions.

At the beginning the surgeon at the console detects the angle of Treitz to move the bowel loops above the

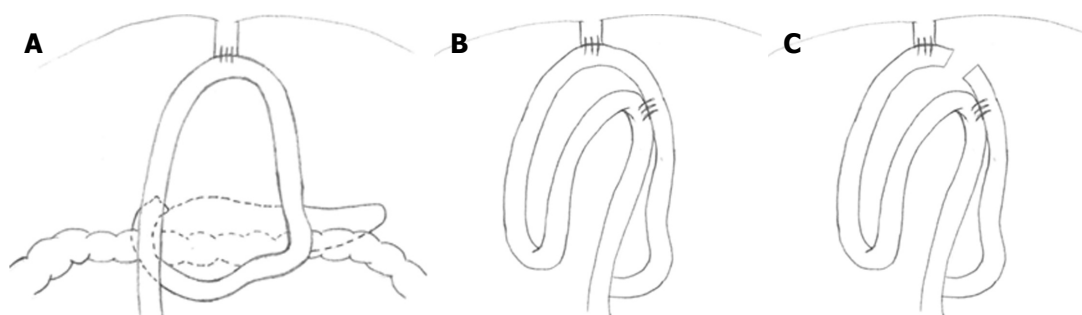


Figure 2 Double loop reconstruction method. A: 1 step: E-J anastomosis; B: 2 step: J-J anastomosis using the second loop; C: 3 step: interruption of continuity between the two anastomoses.

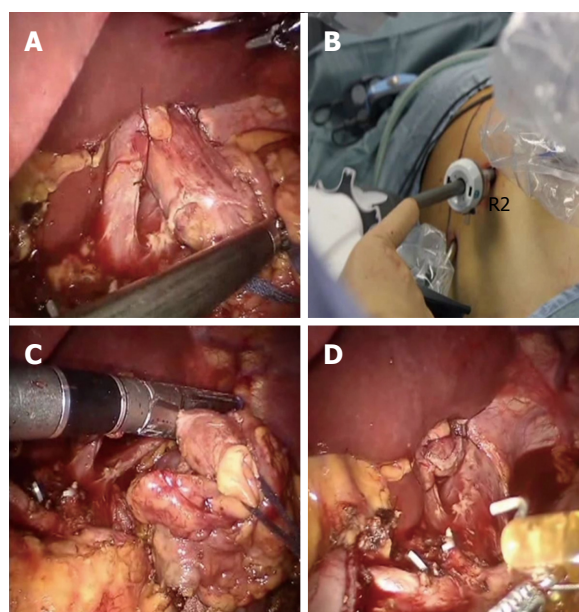


Figure 3 Division of the esophagus. A: After fixing the esophagus to the diaphragm pillars; B: An articulated mechanical linear stapler is introduced by the assistant through a 12 mm trocar; C and D: The esophagus is sectioned and closed.

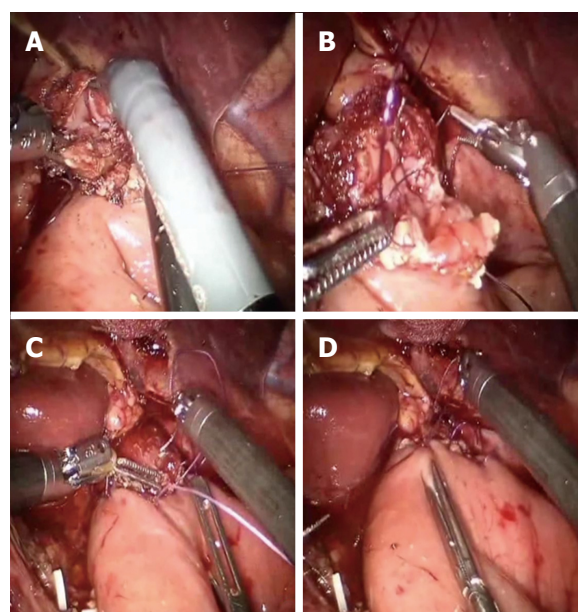


Figure 5 Esophagus and jejunum are opened (A), the posterior layer (B) is first performed followed by the anterior layer (C and D).

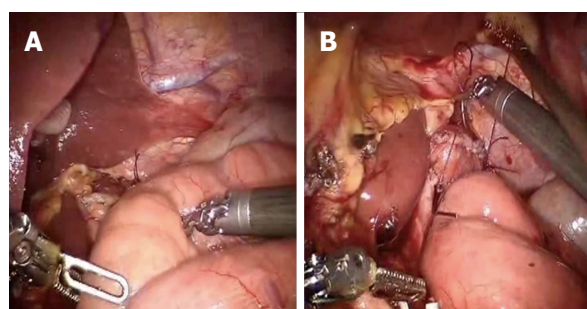


Figure 4 A first loop of small bowel is identified and brought antecolic (A), two stitches are placed to pair it with the esophagus (B).

transverse colon close to the sectioned esophagus. The selected portion of jejunum must be free from stretching and twisting, to ensure a successful anastomosis. The selected loop is fixed with two stitches to the posterior wall of the esophagus (Figure 4), placing the biliary

side on the esophagus left and the alimentary side on the right. The first loop is prepared. The surgeon performs an end-to-side esophago-jejunal robot-sewn anastomosis (Figure 5). The operator starts performing a first posterior layer with interrupted stitches using a Vicryl 2/0 for each point, joining the jejunal serosal and the muscle layer of the esophagus. Then, both the small intestine and the esophagus are opened. The surgeon performs the internal layer with a running suture, using a 3/0 PDS wire. During each step of the suture both the small intestine wall and the esophageal wall are full-thickness crossed. After this step, the anterior plane is approached. A second running suture joins the posterior one at the anastomosis angles. The anterior plane is completed with interrupted stitches covering the internal layer. The second loop is identified at a distance of about 30 to 40 cm from the E-J anastomosis. This loop is located close to the first anastomosis, on the left side, and it is used to perform the jejunojejunal anastomosis. At this point, the

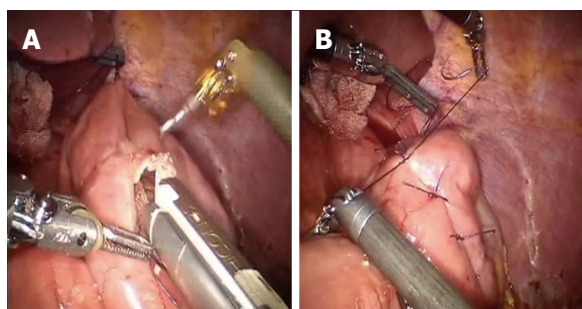


Figure 6 Second loop is identified at 40 cm from the E-J anastomosis, along the alimentary limb, and brought up to the first anastomosis on its left side through a mechanical stapler (A), a side to side jejunojunctional anastomosis is created between the second loop and the biliary limb of the first loop (B).

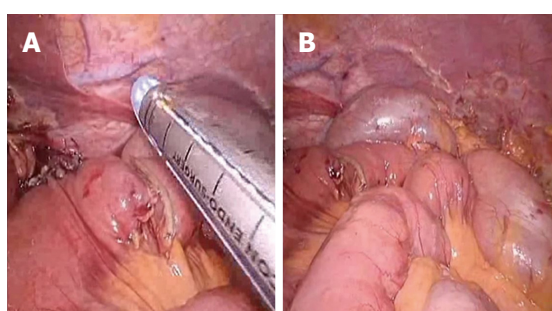


Figure 7 Two anastomoses are easily interrupted by firing the stapler (A and B).

Table 1 Characteristics of patients	
Characteristics	
Sex (male/female), no.	31/24
Age (yr)	72.56 ± 10.67
BMI (kg/m ²)	24.42 ± 72.56
Comorbidity, <i>n</i> (%)	35 (66.04)
ASA score, <i>n</i>	
I	8
II	19
III	28
IV	0
Tumor location, <i>n</i>	
Lower third	12
Middle third	30
Upper third	13

surgeon fixes the chosen intestinal segment (second loop) to the biliary limb of the first loop with two sero-serosal stitches. The assistant fires the stapler (Figure 6) and then the surgeon at the console closes the entry holes of the stapler with two layers of sutures (the first is a running suture and the second layer is made with interrupted stitches). The operation ends with the interruption of the digestive continuity between the two anastomoses (Figure 7) by firing a linear stapler and thus creating a modified Roux-en-Y.

Table 2 Operative results	
Outcomes	
Overall operative time, min	354.21 ± 68.8
Incision for specimen extraction, <i>n</i>	
Right McBurney incision	55
length of minilaparotomy, cm	5 (4-6)
Intraoperative blood loss, ml	126.55 ± 73
Intraoperative morbidity, <i>n</i>	0
Intraoperative Mortality, <i>n</i>	0
Conversion, <i>n</i>	0
Extent of lymphadenectomy, <i>n</i>	
D1	0
D1+	5
D2	50

A suction drain is positioned close to the E-J anastomosis, while the naso-enteric tube is not placed. The specimen is removed through a 5 cm Mc Burney incision, in the right iliac fossa.

RESULTS

Data of 55 consecutive patients underwent the robotic double-loop reconstruction method (called Parisi technique) after performing a robotic total gastrectomy for gastric cancer were considered in the present study. Table 1 reported patients' characteristics. Mean age was 72.56 ± 10.67, 66.04% of patients had one or more comorbidities and the mean BMI was 24.42 ± 72.56. Most tumors were in the middle third of the stomach (54.54%).

If the tumor is localized at the lower third of the stomach, usually we perform a BII subtotal gastrectomy, with a robotic intracorporeal anastomosis. However, in some selected cases we prefer to perform a total gastrectomy.

In 12 of the reported cases, where the tumor was located in between the lower and the middle third of the stomach, we decided, after discussion with the patient, to perform a total than a subtotal gastrectomy for the following reasons: (1) some patients were less than 65 years old and we wanted to reduce the risk of recurrence on the residual limb (5 patients); (2) the lesion appeared to extensively involve the lower two thirds of the stomach (5 patients); and (3) in two cases with diffuse type, there was not only a main prepyloric lesion but also a biopsy proven adenocarcinoma at the upper third.

Total operative time was 354.21 ± 68.8 (Table 2). Intraoperative blood loss was 126.55 ± 73. No conversion to open surgery or major intraoperative complications occurred. The median number of retrieved lymph nodes was 35 (95%CI: 15-47). All specimens were evaluated as R0 resections. Histopathological characteristics are shown in Table 3.

Table 4 summarizes the postoperative findings.

Table 3 Clinical outcomes during hospitalization and complications

Outcomes	
Time to peristalsis, d	1 (1-3) ¹
Time to resume liquid diet, d	2 (2-5) ¹
Time to resume solid intake, d	3 (3-6) ¹
Length of hospital stay, d	5 (3-17) ¹
Postoperative 30-d complications, <i>n</i>	0
Reoperations, <i>n</i>	0
30-d mortality, <i>n</i>	0

¹Values are expressed as median (range).

Table 4 Histopathological data

Outcomes	
Diameter of the tumor, cm	4.25 (1-8) ¹
Proximal margin, cm	6 (2-11) ¹
Number of harvested lymph nodes, <i>n</i>	35 (15-47) ¹
TNM staging, <i>n</i> (%)	
Stage 0	0
Stage I A	8 (14.55)
Stage I B	9 (16.37)
Stage II A	12 (21.82)
Stage II B	11 (20.00)
Stage III A	7 (12.72)
Stage III B	6 (10.91)
Stage III C	2 (3.63)
Stage IV	0
Residual tumor, <i>n</i>	
R0	55
R1	0
R2	0

¹Values are expressed as median (range).

The median hospital stay was 5 d. We observed a fast recovery of different levels of food intake after gastrectomy, enabling patients to go through a liquid diet (Median = 2; 95%CI: 2-5) until starting a solid diet (Median = 3; 95%CI: 3-6). No major complications or death occurred. None of the 55 patients experienced anastomotic leakage.

DISCUSSION

The restoration of the digestive tract after total gastrectomy is a technically demanding phase.

Minimally invasive surgery has been developed in recent years even for complex oncological procedures thanks to new available devices and increased surgeons experience^[2].

In the literature (Table 5), only 22 studies^[5,7-27] from 16 institutions have reported the use of robotic surgery in gastric cancer including total gastrectomy. Eleven studies are comparative^[9,11-15,17,18,21-23], others are case series and personal experiences^[5,7,8,10,16,19,20,24,27]. Limitations of studies are to provide outcomes including in their analysis different types of gastric resection.

In fact, only 5 studies^[5,17,22,24,27] reported information on total gastrectomy alone. Others reported data on surgical interventions within a more general analysis including different types of gastric resections as subtotal or proximal gastrectomy. Overall, 466 procedures on total gastrectomy can be detected in the literature. This makes difficult to better understand the real effect of robotic surgery on total gastrectomy that is a different and more complex surgery.

Moreover, Table 6 shows that most of studies reported limited information. Only eight studies showed data on patient and tumor characteristics or operative and clinical results^[2,17,20-24,26].

Regarding the technique used, all studies reported the assistance of the robot in the mobilization of the stomach and in lymphadenectomy. Ten authors reported an extracorporeal reconstruction and only eleven studies^[2,8-10,13,16,18,19,23,24,26] reported a robotic assistance in this phase and an intracorporeal approach.

There are two main issues to consider: the way to perform the Roux-en-y reconstruction and how to perform it.

In the intracorporeal approach, a circular stapler is generally used but other solutions include the Orvil^[16] or the Overlap technique^[16,23]. Some authors^[10,25] described the use of the robot to perform a manual purse-string around the anvil, but only few reports^[5,13,19,24] in the literature reported its use for a complete hand-sewn anastomosis.

Surgeons are generally afraid to perform the latter, because the high surgical skills required in conventional surgery and the risk for leakage if not well performed.

By the other hand and regardless of the approach, using mechanical staplers has standardized the way to perform the reconstruction after total gastrectomy and apparently give more safety. If this is true in open surgery, this is more challenging when adopting an intracorporeal approach. A mechanical trouble when firing the stapler or a leakage for incomplete closing at the E-J level can lead the patient to serious complications until death.

We decided to develop a new technique to overcome the reported limitations of the intracorporeal approach. Particularly we found a feasible and safe way to perform a complete robotic reconstruction without the need to convert the procedure to open or laparoscopic surgery or using others potentially dangerous techniques.

The accuracy of the robotic system, the micro-surgical instruments and particularly the endowrist allow the surgeon to perform movements that are even difficult to reproduce in open surgery.

We believe that this technology should be exploited in complex digestive procedures, as in a total gastrectomy and our study demonstrates the usefulness of the robotic system in performing a safe hand-sewn E-J anastomosis.

Table 5 Literature review on robotic total gastrectomy, overall number of reported cases

	Year	Type	Subject	Country	Institution	Period	No.
Present study	2017	Prospective CS	RTG	Italy	St. Mary's Hospital of Terni	2014-2016	55
Jiang <i>et al</i> ^[24]	2015	Retrospective CS	RAG	China	Nanjing University Medical College	2010-2012	65
Kim <i>et al</i> ^[14]	2012	nonRCT	RAG vs LG vs OG	South Korea	Yonsei University College of Medicine	2005-2010	109
Son <i>et al</i> ^[15]	2014	nonRCT	RTG vs LTG	Korea		2005-2010	51
Woo <i>et al</i> ^[11]	2011	nonRCT	RAG vs LG			2005-2009	62
Song <i>et al</i> ^[7]	2009	Prospective CS	RAG			2005-2007	33
Park <i>et al</i> ^[20]	2013	Retrospective CS	RAG	South Korea	National Cancer Center	2009-2012	46
Yoon <i>et al</i> ^[17]	2012	nonRCT	RTG vs LTG	Korea		2009-2011	36
Kang <i>et al</i> ^[13]	2012	nonRCT	RAG vs LG	South Korea	Ajou University School of Medicine	2008-2011	16
Hur <i>et al</i> ^[8]	2010	Retrospective CS	RAG	Korea		2010	2
Hyun <i>et al</i> ^[18]	2013	nonRCT	RAG vs LG	South Korea	Korea University Anam Hospital	2009-2010	9
Son <i>et al</i> ^[15]	2012	nonRCT	RAG vs LG	South Korea	Seoul University Bundang Hospital	2007-2011	1
Junfeng <i>et al</i> ^[21]	2014	nonRCT	RAG vs LG	China	Third Military Medical University	2010-2013	26
Liu <i>et al</i> ^[19]	2013	Prospective CS	RAG	China	Subei People's Hospital of Jiangsu	2011-2013	54
Giulianotti <i>et al</i> ^[25]	2003	Retrospective CS	RAG	Italy	Misericordia Hospital of Grosseto	2000-2002	10
Coratti <i>et al</i> ^[26]	2015	Retrospective CS	RAG	Italy		2000-2014	38
D'Annibale <i>et al</i> ^[10]	2011	Retrospective CS	RAG	Italy	S. Giovanni Addolorata Hospital	2004-2009	11
Caruso <i>et al</i> ^[9]	2011	nonRCT	RAG vs OG	Italy	Hospital of Spoleto	2006-2010	12
Suda <i>et al</i> ^[23]	2014	nonRCT	RAG vs LG	Japan	Fujita Health University	2009-2012	30
Huang <i>et al</i> ^[12]	2012	nonRCT	RAG vs LG vs OG	Taiwan	Taipei Veterans General Hospital	2010-2012	7
Vasilescu <i>et al</i> ^[16]	2012	Retrospective CS	RAG	Romania	Fundeni Clinical Institute	2008-2012	19
Zawadzki <i>et al</i> ^[27]	2014	CR	RAG	Poland	Wroclaw Medical University	2014	1
Parisi <i>et al</i> ^[5]	2015	Prospective CS	RTG	Italy	St. Mary's Hospital of Terni	2014-2015	22
Total ¹							466

¹Excluding the present study.

Although it may appear more complex than other techniques, during our experience, we have gained some tricks: (1) the esophagus should be fixed to both sides at the diaphragmatic pillars to avoid retraction in the chest; (2) a jejunal loop which can be easily approached to the esophagus is essential; (3) two interrupted stiches can help in pairing the esophagus and the jejunum, delimiting the two ends of the E-J anastomosis. Then other two central stitches are placed to complete the posterior external layer. Vicryl is preferable; (4) only at this point the esophagus and the jejunum wall should be opened, we suggest using monopolar curved scissors; (5) two running sutures for the internal layer, the first posterior and the second one anterior are preferable than an interrupted suturing. At the beginning of our experience we performed this step with interrupted stiches but after few cases we decided to move to a running suture because faster and it gives a feeling of safety and high adherence between the visceral walls; and (6) PDS sutures for the internal layer is best, because the combination of an absorbable suture and an extended anastomotic support. This suture gives fluidity and at the same time tightness,

when the thread is pulled in tension.

The double loop approach is the other innovative element we reported. This technique can speed up the reconstruction and have several relevant advantages: (1) the loop of bowel can be chosen without tension; (2) there is no confusion between biliary and alimentary tract; and (3) it is not necessary to interrupt the mesentery, reducing the risk of bleeding and internal hernias.

In conclusion, the present study is one of the largest series focused on robotic total gastrectomy in the literature and has shown satisfactory outcomes. The innovative technique adopted has demonstrated feasibility and safety when performing both the E-J and the J-J anastomoses with an intracorporeal robotic approach.

Every method for reconstruction has to tackle the functional problems of blind loop syndrome, or of inadequate transition (*e.g.*, weight loss) through the substitute stomach.

The short-term follow-up didn't highlight any functional problems until now, while the evaluation on long term results of our approach is ongoing.

Table 6 Literature review on robotic total gastrectomy, details of the reported data

	Robot - Assistance		Type	E-J anastomosis	Anastomosis performance	Site of minilaparotomy	Operative and clinical data	Patients and tumor details
	Lymphadenectomy	Stomach mobilization						
Jiang <i>et al</i> ^[24]	Performed	Performed	Roux-en-Y	EXTRA	Circular stapler	Not provided	Provided	Provided
Kim <i>et al</i> ^[14]	Not provided	Not provided	Roux-en-Y	INTRA	Robot-sewn	Not provided	Lack	Lack
Son <i>et al</i> ^[15]	Performed	Performed	Roux-en-Y	Not provided	Not provided	Upper midline	Provided	Provided
Woo <i>et al</i> ^[11]	Performed	Performed	Roux-en-Y	EXTRA	Circular stapler	Left lower port	Lack	Lack
Song <i>et al</i> ^[7]	Performed	Performed	Roux-en-Y	INTRA LAP	Not provided	Not provided	Lack	Lack
Park <i>et al</i> ^[20]	Performed	Performed	Roux-en-Y	EXTRA	Circular stapler	Upper midline	Lack	Lack
Yoon <i>et al</i> ^[27]	Performed	Performed	Roux-en-Y	EXTRA	Not provided	Upper midline	Provided	Lack
Kang <i>et al</i> ^[13]	Performed	Performed	Roux-en-Y	EXTRA	Circular stapler	Not provided	Provided	Provided
Hur <i>et al</i> ^[8]	Performed	Performed	Roux-en-Y	EXTRA	Circular stapler	Upper midline	Lack	Lack
Hyun <i>et al</i> ^[18]	Performed	Performed	Roux-en-Y	INTRA	Robot-sewn	Not provided	Lack	Lack
Son <i>et al</i> ^[15]	Performed	Performed	Roux-en-Y	INTRA	Robot-sewn	Not provided	Lack	Lack
Junfeng <i>et al</i> ^[21]	Performed	Performed	Roux-en-Y	EXTRA	Circular stapler	Upper midline	Lack	Lack
Liu <i>et al</i> ^[19]	Performed	Performed	Roux-en-Y	EXTRA	Circular stapler	Umbilical port	Lack	Lack
Giulianotti <i>et al</i> ^[25]	Performed	Performed	Roux-en-Y	EXTRA	Not provided	Not provided	Lack	Lack
Coratti <i>et al</i> ^[26]	Performed	Performed	Roux-en-Y	EXTRA	Circular stapler	Upper midline	Provided	Provided
D'Annibale <i>et al</i> ^[10]	Performed	Performed	Roux-en-Y	INTRA	Robot-sewn	Camera port	Lack	Lack
Caruso <i>et al</i> ^[9]	Performed	Performed	Roux-en-Y	INTRA	Circular stapler	Not provided	Provided	Provided
Suda <i>et al</i> ^[23]	Performed	Performed	Roux-en-Y	INTRA	Circular stapler	Suprapubic	Lack	Lack
Huang <i>et al</i> ^[12]	Performed	Performed	Roux-en-Y	INTRA	Circular stapler	Upper midline	Lack	Lack
Vasilescu <i>et al</i> ^[16]	Performed	Performed	Roux-en-Y	INTRA LAP	Linear stapler	Not provided	Provided	Provided
Parisi <i>et al</i> ^[5]	Performed	Performed	Roux-en-Y	INTRA	Circular stapler	Periumbilical	Lack	Lack
	Performed	Performed	Roux-en-Y	INTRA	Robot-sewn	McBurney	Provided	Provided

COMMENTS

Background

The development of surgical technology during last decades has allowed surgeons to offer patients new approaches and treatment strategies. Several studies have shown the usefulness of robotic systems when performing a gastrectomy for cancer and its potential advantages when compared with traditional laparoscopic devices. However, it has been well evaluated the role of both laparoscopic and robotic surgery for distal or subtotal gastrectomy, particularly in the eastern population, there is a big debate on safety and feasibility of intracorporeal procedures for reconstruction of the alimentary tract after a total gastrectomy. The present study has addressed this issue in a western center.

Research frontiers

Despite the spread of minimally invasive procedures for complex major abdominal surgeries, few studies have been performed on the totally robotic approach for gastric cancer. Current indications are still object of debate. Moreover, only few centers have tried to find solutions for the reconstruction phase after total gastrectomy.

Innovations and breakthroughs

Robotic systems have revolutionized minimally invasive surgery. Surgeons can overcome the limits of traditional laparoscopy through a three-dimensional vision and articulated instruments. This technological progress should be exploited

particularly when performing a demanding phase of a procedure, as in suturing movements. The present study shows a new robotic technique for a reconstructive approach. The double loop method can simplify the way to perform the reconstruction phase after a total gastrectomy and can allow surgeons to overcome the current limitations.

Applications

This study shows the possibility to safely perform a completely intracorporeal anastomosis after a total gastrectomy, considered one of the biggest obstacles in minimally invasive surgery.

Terminology

Robotic systems are used in minimally invasive surgery and allow the primary surgeon to perform the procedure through a remote console.

Peer-review

It is a good observational study who reported the outcome of robotic total gastrectomy in one Institution. Total gastrectomy with minimally invasive technique is quite challenging with either laparoscopic technique or robotic technique. With a series of 55 patients who successfully recovered, they can be convinced by the authors and draw such a conclusion that it can be safe.

REFERENCES

- 1 **Marano A**, Choi YY, Hyung WJ, Kim YM, Kim J, Noh SH. Robotic versus Laparoscopic versus Open Gastrectomy: A Meta-Analysis. *J Gastric Cancer* 2013; **13**: 136-148 [PMID: 24156033 DOI: 10.5230/jgc.2013.13.3.136]
- 2 **Parisi A**, Nguyen NT, Reim D, Zhang S, Jiang ZW, Brower ST, Azagra JS, Facy O, Alimoglu O, Jackson PG, Tsujimoto H, Kurokawa Y, Zang L, Coburn NG, Yu PW, Zhang B, Qi F, Coratti A, Anecchiario M, Novotny A, Goergen M, Lequeu JB, Eren T, Leblebici M, Al-Refaie W, Takiguchi S, Ma J, Zhao YL, Liu T, Desiderio J. Current status of minimally invasive surgery for gastric cancer: A literature review to highlight studies limits. *Int J Surg* 2015; **17**: 34-40 [PMID: 25758348]
- 3 **Japanese Gastric Cancer Association**. Japanese gastric cancer treatment guidelines 2010 (ver. 3). *Gastric Cancer* 2011; **14**: 113-123 [PMID: 21573742 DOI: 10.1007/s10120-011-0042-4]
- 4 **NCCN**. Clinical Practice Guidelines in Oncology: Gastric Cancer. Version 1.2014, 2014 Available from: URL: http://www.nccn.org/professionals/physician_gls/pdf/gastricpdf
- 5 **Parisi A**, Ricci F, Trastulli S, Cirocchi R, Gemini A, Grassi V, Corsi A, Renzi C, De Santis F, Petrina A, Pironi D, D'Andrea V, Santoro A, Desiderio J. Robotic Total Gastrectomy With Intracorporeal Robot-Sewn Anastomosis: A Novel Approach Adopting the Double-Loop Reconstruction Method. *Medicine (Baltimore)* 2015; **94**: e1922 [PMID: 26656323 DOI: 10.1097/MD.0000000000001922]
- 6 **von Elm E**, Altman DG, Egger M, Pocock SJ, Gøtzsche PC, Vandenbroucke JP. The Strengthening of Reporting of Observational Studies in Epidemiology (STROBE) Statement: guidelines for reporting observational studies. *Int J Surg* 2014; **12**: 1495-1499 [PMID: 25046131 DOI: 10.1016/j.ijsu.2014.07.013]
- 7 **Song J**, Oh SJ, Kang WH, Hyung WJ, Choi SH, Noh SH. Robot-assisted gastrectomy with lymph node dissection for gastric cancer: lessons learned from an initial 100 consecutive procedures. *Ann Surg* 2009; **249**: 927-932 [PMID: 19474671 DOI: 10.1097/01.sla.0000351688.64999.73]
- 8 **Hur H**, Kim JY, Cho YK, Han SU. Technical feasibility of robot-sewn anastomosis in robotic surgery for gastric cancer. *J Laparoendosc Adv Surg Tech A* 2010; **20**: 693-697 [PMID: 20809816 DOI: 10.1089/lap.2010.0246]
- 9 **Caruso S**, Patriti A, Marrelli D, Ceccarelli G, Ceribelli C, Roviello F, Casciola L. Open vs robot-assisted laparoscopic gastric resection with D2 lymph node dissection for adenocarcinoma: a case-control study. *Int J Med Robot* 2011; **7**: 452-458 [PMID: 21984205 DOI: 10.1002/rcs.416]
- 10 **D'Annibale A**, Pende V, Pernazza G, Monsellato I, Mazzocchi P, Lucandri G, Morpurgo E, Contardo T, Sovernigo G. Full robotic gastrectomy with extended (D2) lymphadenectomy for gastric cancer: surgical technique and preliminary results. *J Surg Res* 2011; **166**: e113-e120 [PMID: 21227455 DOI: 10.1016/j.jss.2010.11.881]
- 11 **Woo Y**, Hyung WJ, Pak KH, Inaba K, Obama K, Choi SH, Noh SH. Robotic gastrectomy as an oncologically sound alternative to laparoscopic resections for the treatment of early-stage gastric cancers. *Arch Surg* 2011; **146**: 1086-1092 [PMID: 21576595 DOI: 10.1001/archsurg.2011.114]
- 12 **Huang KH**, Lan YT, Fang WL, Chen JH, Lo SS, Hsieh MC, Li AF, Chiou SH, Wu CW. Initial experience of robotic gastrectomy and comparison with open and laparoscopic gastrectomy for gastric cancer. *J Gastrointest Surg* 2012; **16**: 1303-1310 [PMID: 22450954 DOI: 10.1007/s11605-012-1874-x]
- 13 **Kang BH**, Xuan Y, Hur H, Ahn CW, Cho YK, Han SU. Comparison of Surgical Outcomes between Robotic and Laparoscopic Gastrectomy for Gastric Cancer: The Learning Curve of Robotic Surgery. *J Gastric Cancer* 2012; **12**: 156-163 [PMID: 23094227 DOI: 10.5230/jgc.2012.12.3.156]
- 14 **Kim KM**, An JY, Kim HI, Cheong JH, Hyung WJ, Noh SH. Major early complications following open, laparoscopic and robotic gastrectomy. *Br J Surg* 2012; **99**: 1681-1687 [PMID: 23034831 DOI: 10.1002/bjs.8924]
- 15 **Son SY**, Lee CM, Ahn SH, Lee JH, Park DJ, Kim HH. Clinical Outcome of Robotic Gastrectomy in Gastric Cancer in Comparison with Laparoscopic Gastrectomy: A Case-Control Study. *J Minim Invas Surg* 2012; **15**: 27-31
- 16 **Vasilescu C**, Procopiuc L. Robotic surgery of locally advanced gastric cancer: a single-surgeon experience of 41 cases. *Chirurgia (Bucur)* 2012; **107**: 510-517 [PMID: 23025119]
- 17 **Yoon HM**, Kim YW, Lee JH, Ryu KW, Eom BW, Park JY, Choi JJ, Kim CG, Lee JY, Cho SJ, Rho JY. Robot-assisted total gastrectomy is comparable with laparoscopically assisted total gastrectomy for early gastric cancer. *Surg Endosc* 2012; **26**: 1377-1381 [PMID: 22083338 DOI: 10.1007/s00464-011-2043-0]
- 18 **Hyun MH**, Lee CH, Kwon YJ, Cho SI, Jang YJ, Kim DH, Kim JH, Park SH, Mok YJ, Park SS. Robot versus laparoscopic gastrectomy for cancer by an experienced surgeon: comparisons of surgery, complications, and surgical stress. *Ann Surg Oncol* 2013; **20**: 1258-1265 [PMID: 23080320 DOI: 10.1245/s10434-012-2679-6]
- 19 **Liu XX**, Jiang ZW, Chen P, Zhao Y, Pan HF, Li JS. Full robot-assisted gastrectomy with intracorporeal robot-sewn anastomosis produces satisfying outcomes. *World J Gastroenterol* 2013; **19**: 6427-6437 [PMID: 24151361 DOI: 10.3748/wjg.v19.i38.6427]
- 20 **Park JY**, Kim YW, Ryu KW, Eom BW, Yoon HM, Reim D. Emerging Role of Robot-assisted Gastrectomy: Analysis of Consecutive 200 Cases. *J Gastric Cancer* 2013; **13**: 255-262 [PMID: 24511422 DOI: 10.5230/jgc.2013.13.4.255]
- 21 **Junfeng Z**, Yan S, Bo T, Yingxue H, Dongzhu Z, Yongliang Z, Feng Q, Peiwu Y. Robotic gastrectomy versus laparoscopic gastrectomy for gastric cancer: comparison of surgical performance and short-term outcomes. *Surg Endosc* 2014; **28**: 1779-1787 [PMID: 24385251 DOI: 10.1007/s00464-013-3385-6]
- 22 **Son T**, Lee JH, Kim YM, Kim HI, Noh SH, Hyung WJ. Robotic spleen-preserving total gastrectomy for gastric cancer: comparison with conventional laparoscopic procedure. *Surg Endosc* 2014; **28**: 2606-2615 [PMID: 24695982 DOI: 10.1007/s00464-014-3511-0]
- 23 **Suda K**, Man-I M, Ishida Y, Kawamura Y, Satoh S, Uyama I. Potential advantages of robotic radical gastrectomy for gastric adenocarcinoma in comparison with conventional laparoscopic approach: a single institutional retrospective comparative cohort study. *Surg Endosc* 2015; **29**: 673-685 [PMID: 25030478 DOI: 10.1007/s00464-014-3718-0]
- 24 **Jiang ZW**, Liu J, Wang G, Zhao K, Zhang S, Li N, Li JS. Esophagojejunostomy reconstruction using a robot-sewing technique during totally robotic total gastrectomy for gastric cancer. *Hepatogastroenterology* 2015; **62**: 323-326 [PMID: 25916057]
- 25 **Giulianotti PC**, Coratti A, Angelini M, Sbrana F, Cecconi S,

- Balestracci T, Caravaglios G. Robotics in general surgery: personal experience in a large community hospital. *Arch Surg* 2003; **138**: 777-784 [PMID: 12860761 DOI: 10.1001/archsurg.138.7.777]
- 26 **Coratti A**, Fernandes E, Lombardi A, Di Marino M, Anecchiarico M, Felicioni L, Giulianotti PC. Robot-assisted surgery for gastric carcinoma: Five years follow-up and beyond: A single western center experience and long-term oncological outcomes. *Eur J Surg Oncol* 2015; **41**: 1106-1113 [PMID: 25796984 DOI: 10.1016/j.ejso.2015.01.014]
- 27 **Zawadzki M**, Witkiewicz W. Laparoscopic robotic total gastrectomy. *Wideochir Inne Tech Maloinwazyjne* 2014; **9**: 650-654 [PMID: 25562009 DOI: 10.5114/wiitm.2014.45128]

P- Reviewer: Garcia-Olmo D, Klinge U, Wu AW **S- Editor:** Qi Y

L- Editor: A **E- Editor:** Zhang FF





Published by **Baishideng Publishing Group Inc**
7901 Stoneridge Drive, Suite 501, Pleasanton, CA 94588, USA
Telephone: +1-925-223-8242
Fax: +1-925-223-8243
E-mail: bpgooffice@wjgnet.com
Help Desk: <http://www.f6publishing.com/helpdesk>
<http://www.wjgnet.com>



ISSN 1007-9327



9 771007 932045