

⁶⁸Ga-PSMA PET/CT for the detection of bone metastasis in recurrent prostate cancer and a PSA level <2 ng/ml: Two case reports and a literature review

LARS J. PETERSEN^{1,2}, JULIE B. NIELSEN^{1,2}, KATJA DETTMANN³, RUNE V. FISKER^{1,4},
UWE HABERKORN^{5,6}, LOUISE STENHOLT⁷ and HELLE D. ZACHO^{1,2}

¹Department of Nuclear Medicine, Clinical Cancer Research Center, Aalborg University Hospital; ²Department of Clinical Medicine, Aalborg University, DK-9000 Aalborg; ³Department of Urology, Regional Hospital West Jutland, DK-7500 Holstebro; ⁴Department of Radiology, Clinical Cancer Research Center, Aalborg University Hospital, DK-9000 Aalborg, Denmark; ⁵Department of Nuclear Medicine, University Hospital of Heidelberg; ⁶Clinical Cooperation Unit Nuclear Medicine, German Cancer Research Centre, D-69120 Heidelberg, Germany; ⁷The Medical Library, Aalborg University Hospital, DK-9000 Aalborg, Denmark

Received March 14, 2017; Accepted May 23, 2017

DOI: 10.3892/mco.2017.1280

Abstract. Localization of prostate cancer recurrence, particularly in the bones, is a major challenge with standard of care imaging in patients with biochemical recurrence following curatively intended treatment. Gallium-68-labeled prostate specific membrane antigen positron emission tomography/computed tomography (⁶⁸Ga-PSMA PET/CT) is a novel and promising method for imaging in prostate cancer. The present study reports two cases of patients with prostate cancer with biochemical recurrence, with evidence of bone metastases on ⁶⁸Ga-PSMA PET/CT images and low prostate specific antigen PSA levels (<2 ng/ml) and PSA doubling time >6 months. The bone metastases were verified by supplementary imaging with ¹⁸F-sodium fluoride PET/CT and magnetic resonance imaging as well as biochemical responses to androgen deprivation therapy. Therefore, ⁶⁸Ga-PSMA PET/CT is promising for the restaging of patients with prostate cancer with biochemical recurrence, including patients with low PSA levels and low PSA kinetics.

Introduction

Localization of prostate cancer recurrence is a major challenge in patients with biochemical recurrence following curatively intended treatment. The currently applied imaging modalities such as bone scintigraphy and abdominal pelvic computed tomography (CT) are too insensitive, particularly at low serum prostate-specific antigen (PSA) values (1). These two modalities only reliably show the site of relapse in patients with very high PSA levels (>10 ng/ml) (2). This is of particular importance as salvage radiotherapy in these patients is most effective at serum PSA values <0.5 ng/ml (3,4).

Established positron emission tomography (PET) tracers such as ¹¹C- or ¹⁸F-choline or ¹¹C-acetate are able to directly detect tumor tissue, which is also true at the bone level, where these tracers show tumor tissue, as opposed to reactive bone as with bone scans and ¹⁸F-sodium fluoride (NaF) PET/CT. This result may convey higher sensitivity for both osteoblastic and osteolytic bone lesions at low PSA levels (5). However, the majority of large series have included patients with a PSA level >2 ng/ml (6,7). Most studies that included patients with low PSA levels have shown infrequent bone metastases, and little information is provided concerning tumor characteristics in individual patients (8-11). Generally, choline PET is only indicated in biochemical failure if the PSA level is >2 ng/ml or the PSA level is rising rapidly (12).

Gallium-68-labelled prostate-specific membrane antigen (⁶⁸Ga-PSMA) PET/CT has recently been introduced as a promising method for prostate cancer imaging, both for staging and restaging (13-17). In contrast to existing PET tracers, ⁶⁸Ga-PSMA PET has revealed pathological sites of uptake, even with low PSA levels, in several retrospective series (13-17).

In 2015, the present authors initiated two prospective trials with ⁶⁸Ga-PSMA PET/CT in prostate cancer, including a study of PSMA-11 (DKFZ-PSMA-11, also known as PSMA-HBED-CC) PET/CT in recurrent prostate cancer in

Correspondence to: Professor Lars J. Petersen, Department of Nuclear Medicine, Clinical Cancer Research Center, Aalborg University Hospital, Hobrovej 18-22, DK-9000 Aalborg, Denmark
E-mail: lajp@rn.dk

Abbreviations: CT, computed tomography; ⁶⁸Ga, Gallium-68; MRI, magnetic resonance imaging; NaF, ¹⁸F-sodium fluoride; PET, positron emission tomography; PSMA, prostate specific membrane antigen; PSA, prostate specific antigen; PSA_{dt}, PSA doubling time; STARD, the standards for reporting of diagnostic accuracy

Key words: biochemical recurrence, ⁶⁸Ga-prostate-specific membrane antigen, positron emission tomography, prostate-specific antigen, prostate-specific antigen kinetics

comparison with magnetic resonance imaging (MRI) and NaF PET/CT (EudraCT no.; 2014-005073-37). The trial was approved by the Danish Health and Medicine Authority, The Danish Data Protection Agency, and the North Denmark Region Committee in Health Research Ethics. The patients received written and oral information and provided written informed consent, inclusive presentation of individual study results in a blinded fashion. The current study reports two cases of bone metastasis in patients with PSA levels <2 ng/ml and slow PSA kinetics.

Case reports

Case one. A 70-year old male was included in the present study in October 2015 due to biochemical recurrence of a prostate cancer. Five years previously, the patient underwent radical prostatectomy due to prostate cancer (T2c, Gleason 7 (3+4), with a PSA level of 10.9 ng/ml). The PSA values remained unmeasurable (<0.1 ng/ml) for 4 years but then increased to 0.4 ng/ml. The PSA doubling time (PSAdt) was 22.5 months. A ^{68}Ga -PSMA-11 PET/CT scan with low-dose CT showed pathological PSMA uptake in several bone lesions, with corresponding morphological findings in the CT scan, including the right and left scapula, right 5th rib and left 3rd rib (Fig. 1). There was no pathological uptake in the lymph nodes, prostatic bed or soft tissues. In addition, the patient underwent a NaF PET/CT scan, which confirmed the skeletal findings on the ^{68}Ga -PSMA PET/CT, but also revealed at least four additional bone metastases (ribs and the left iliac bone), but without corresponding changes on the CT. The NaF PET/CT scan identified numerous sites of enhanced uptake associated with benign, degenerative bone disorders. The MRI scan did not identify any enlarged lymph nodes in the pelvis. A slightly heterogeneous bone marrow signal was observed in the pelvis and lumbar spine on T1-weighted images but without the anatomical appearance of bone metastases, and a normal signal on the short T1-inversion recovery (STIR) sequences. In conclusion, the MRI was negative for bone metastases. Notably, the MRI covered the pelvis and spine only as recommended by the European Society of Urological Oncology guideline for nodes and bone (18). Thus, the MRI was not able to confirm the four skeletal lesions. The patient received leuprorelin acetate and six cycles of docetaxel. The PSA level dropped to an unmeasurable level (nadir PSA level <0.1 ng/ml).

Case two. A 71-year old male was diagnosed with prostate cancer (pT2b, Gleason 7, with a PSA level of 16.1 ng/ml) in 2002. The patient received a radical prostatectomy with postoperative normalization of PSA levels (PSA level <0.1 ng/ml). Due to biochemical recurrence (a peak PSA level of 0.6 ng/ml) in 2006, the patient received salvage radiotherapy in 5 fields with a central dose of 48 Gray (34 fractions) supplemented with 12 months of treatment with flutamide. The PSA levels normalized within the first year following radiotherapy. In October 2014, the patient presented with an elevated PSA level (0.4 ng/ml) that further increased to 1.8 ng/ml at the time of evaluation in August 2016 (PSAdt 8.7 months). A ^{68}Ga -PSMA-11 PET/CT scan with low-dose CT revealed PSMA uptake in four small lymph nodes on the left side of the pelvis and a skeletal lesion at the level of fourth lumbar vertebra (Fig. 2). Low-dose CT showed a discrete

sclerotic lesion at L4. There was no pathological PSMA uptake in other sites. The NaF PET/CT confirmed the lesion at L4 as a bone metastasis. There were no additional malignant bone lesions identified. The MRI found that the four lymph nodes detected on ^{68}Ga -PSMA PET/CT were of normal size. The skeletal lesion was suspicious for malignancy on the MRI scan due to a low signal in the T1 image and high signal on the STIR sequence. However, a slight depression of the upper discus at L4 caused the final MRI-based diagnosis to be equivocal for bone metastasis. The patient subsequently received treatment with bicalutamide, which caused the PSA level to decline to an unmeasurable level (<0.1 ng/ml).

Discussion

Imaging in cases of biochemical recurrence of prostate cancer has been hampered by the lack of appropriately sensitive modalities, particularly for bone lesions. Bone scans and CT in general do not have adequate sensitivity, and choline PET is only indicated if the PSA level is >2 ng/ml or if the PSA has rapidly rising kinetics (e.g., PSAdt <6 months). The current study presents two cases of pathological ^{68}Ga -PSMA uptake on PET/CT scans with PSA levels <2 ng/ml and slow PSA kinetics. These data, along with a number of cases identified in the published literature (Table I, data captured from a search of 1,858 references in an ongoing systematic review with a cutoff date of August 2016), indicated that ^{68}Ga -PSMA PET/CT may be a valuable imaging technique to localize disease in very early biochemical recurrence.

^{68}Ga -PSMA PET/CT identified pathological uptake in the bones in the first patient and in both the lymph nodes and the bones in the other patient. One of the current cases, as well as a number of cases presented in Table I, were identified to have a solitary site relapse in the bone. From a clinical point of view, the majority of published cases have a minimum amount of clinical and laboratory data to indicate if relapse was expected to occur at the prostate level, in lymph nodes or in the bones. The missing information includes data about resection margins, the nodal status at staging and/or surgery, and the levels and duration of post-treatment PSA levels (or time since curative treatment).

The presented data with ^{68}Ga -PSMA PET/CT use in early recurrence are encouraging. Similar data with other PET tracers are scarce in the published literature. In several previous studies with choline PET/CT, no bone lesions were detected in early biochemical recurrence (10,11). Kjolhede *et al* (8) presented 5 patients with suspected bone lesions among 58 patients with biochemical recurrence and PSA levels of <2 ng/ml, but there were no data on PSA kinetics in patients with bone lesions. Castellucci *et al* (9) performed ^{11}C -choline PET/CT in 605 patients with biochemical recurrence and PSA levels of 0.2–2.0 ng/ml and a median PSAdt of 6 months, and showed pathological bone uptake in 51/172 patients with choline-positive scans. The PSAdts of these 51 patients were not reported. It is appropriate to say that lesions detected by choline PET/CT must be cautiously interpreted due to low to moderate specificity; a study with verification by histology showed a low predictive value of 24% at the node level (19).

A number of trials are emerging that directly compare ^{68}Ga -PSMA with other PET tracers and standard imaging in

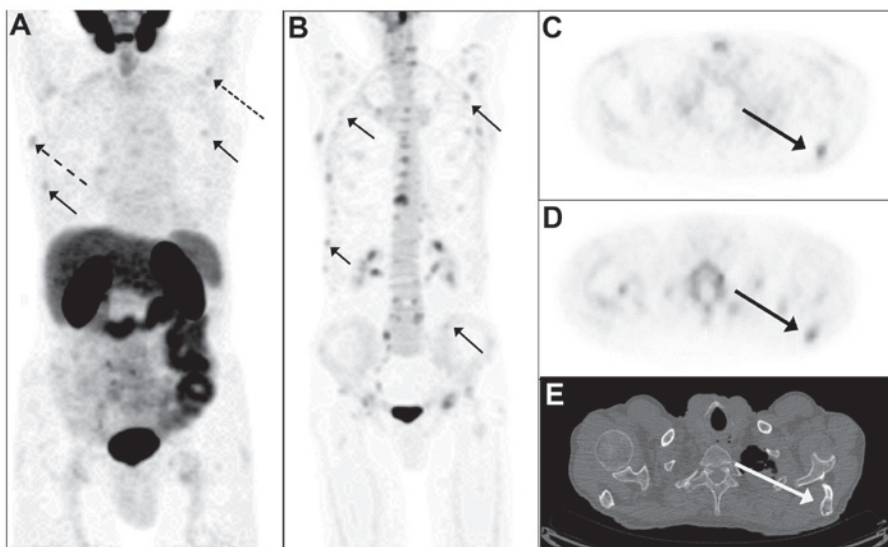


Figure 1. Prostate cancer imaging of biochemical recurrence. (A) MIP of the ^{68}Ga -PSMA-11 PET image in the anterior view. The small, full arrows indicate pathologic PSMA uptake in the ribs (right 5th rib and left 3rd rib). The dotted arrow indicates a lesion in the left scapula, and the hatched arrow indicates uptake in the right scapula. (B) MIP of ^{18}F -NaF-PET/CT confirmed the PSMA bone lesions shown in (A) and showed additional lesions in the ribs, the left scapula and the right scapula (all full arrows). Axial ^{68}Ga -PSMA PET image of the thorax shows pathologic PSMA-uptake in the left scapula (C) (indicated by the arrow), confirmed by ^{18}F -NaF PET (D) and by mixed osteosclerotic and osteolytic lesions on low dose CT (E) (arrow). MIP, maximum-intensity projection; PSMA, prostate specific membrane antigen; PET, positron emission tomography.

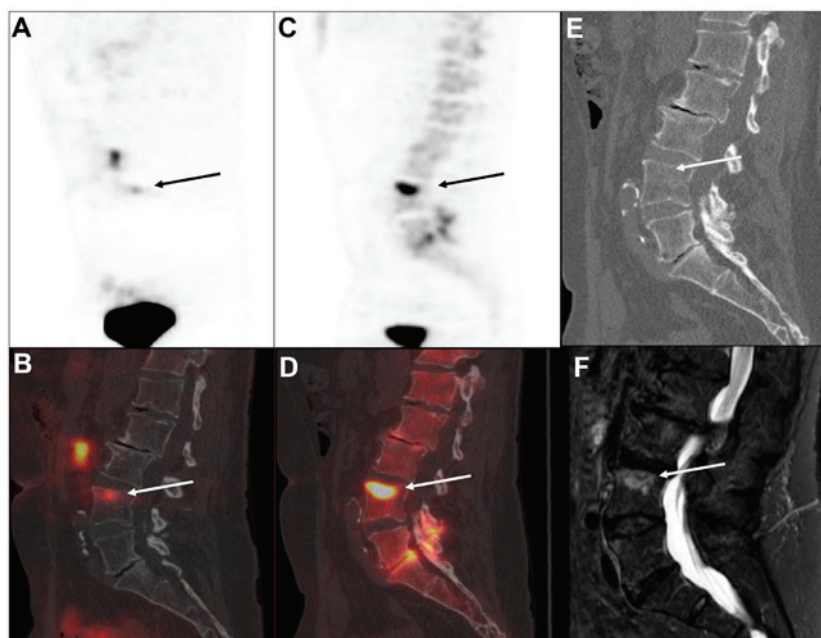


Figure 2. Imaging of bone metastasis in a patient with prostate cancer with biochemical recurrence. A single bone metastasis was identified in the upper part of the fourth lumbar vertebra indicated by the arrow in all the images. The lesion was identified by ^{68}Ga -PSMA-11 PET/CT as shown in (A) the sagittal view of the ^{68}Ga -PSMA-11 PET image with (B) the corresponding fused ^{68}Ga -PSMA-11 PET/CT and (C) by ^{18}F -NaF-PET with (D) corresponding fused images of NaF PET/CT. Morphological changes were recognized as (E) discrete sclerotic changes on the low-dose CT and (F) by magnetic resonance imaging exhibiting a high signal on the sagittal short TI-inversion recover image. PSMA, prostate specific membrane antigen; PET, positron emission tomography.

patients with biochemical recurrence. Although ^{68}Ga -PSMA PET/CT appeared to detect more lesions than choline PET/CT, both on the whole patient level and at the level of individual lesions, the majority of studies include patients with high PSA levels, and there are limited data on skeletal involvement and characteristics of individual patients (20-22).

^{68}Ga -PSMA PET/CT is developing rapidly (16,17). However, most studies are retrospective reports with inherent

methodological deficiencies, including lack of compliance with the standards for reporting of diagnostic accuracy (STARD) criteria (23). One key feature of the STARD guidelines is the definition of the reference test. In the absence of a true reference, it remains unknown if PET uptake parallels tumor recurrence. This is well known with choline PET/CT (19), and it is shown with suspicious lesions without sclerosis on CT with NaF PET as in the current case no. 1. In the present cases, skeletal malignancy was

Table I. Published data with identification of bone metastases by ⁶⁸Ga-PSMA PET/CT in patients with recurrent prostate cancer and a PSA level <2 ng/ml.

Trigger PSA (ng/ml)	T stage at staging	PSA at staging (ng/ml)	Gleason at staging	Treatment	PSA nadir	Years since last Tx	PSA velocity (ng/ml/month)	PSAdt (months)	Number of bone metastases	Other sites	Concurrent imaging or biopsy of bone lesions	Post-imaging follow up	(Refs.)
0.01	-	-	9	-	-	-	-	-	1	None	-	-	(18)
0.1	-	-	9	-	-	-	-	-	3	None	-	-	(19)
0.1	-	-	7	-	-	-	-	-	3	LN	-	-	(18)
0.1	pT3a	-	7	RP (Rx)	-	-	-	-	-	-	-	-	(13)
0.19	-	-	7	RP (Rx)	-	-	-	-	1	LN	-	-	(20)
0.28	-	-	-	ADT	-	-	-	-	-	Prostatic bed, LN	Positive bone on scintigraphy	-	(21)
0.4	pT2c	10.9	7	RP (R0)	<0.1	5	0	22.5	4	None	Confirmed by NaF PET/CT	Response to ADT and docetaxel with PSA decrease (nadir <0.1 ng/ml)	This report
0.43	-	-	7	-	-	-	-	-	1	None	Bone biopsy	-	(22)
0.48	-	-	7	-	-	-	-	-	1	None	-	-	(19)
0.55	pT3a	8.3	7	RP (Rx)	<0.007	-	-	15.4	1	None	-	Last PSA 0.22 ng/ml	(23)
0.56	pT2c	8.6	7	RP (Rx) + RT (prostate)	<0.007	-	-	6.3	1	None	-	Last PSA 0.12 ng/ml	(23)
0.56	pT2c	10.8	7	RP (Rx), RT (prostate), ADT	<0.007	-	-	1.0	2	None	-	-	(23)
0.7	pT3a	13.5	8	RP (R1)	-	12 ^a	-	-	2	none	2 suspicious lesions on MRI, 1 on CT	Response to RT with PSA decrease (nadir <0.1ng/ml) AND confirmation by post-treatment PSMA PET/CT	(24)

Table I. Continued.

Trigger PSA (ng/ml)	T stage at staging	PSA at staging (ng/ml)	Gleason at staging	Treatment	PSA nadir	Years since last Tx	PSA velocity (ng/ml/month)	PSAdt (months)	Number of bone metastases	Other sites	Concurrent imaging or biopsy of bone lesions	Post-imaging follow up	(Refs.)
0.8	pT3b	27.0	8	RP (R1)	-	4 ^a	-	-	1	None	1 suspicious lesion on MRI, 0 on CT	Response to ADT with PSA decrease (nadir <0.1 ng/ml)	(24)
1.0	pT3b	9.1	7	RP (R0)	-	6 ^a	-	-	1	LN	1 suspicious lesion on MRI, 1 on CT	Response to RT and ADT with PSA decrease (nadir <0.1 ng/ml)	(24)
1.35	-	-	-	RP (Rx) + ADT	-	-	--	-	Multiple	-	-	-	(25)
1.5	pT3b	21.2	-	RP (R1)	-	7 ^a	-	-	1	None	1 suspicious lesion on MRI, 1 on CT	Response to ADT with PSA decrease (nadir <0.1 ng/ml)	(24)
1.70	-	-	7	-	-	-	-	-	1	None	-	-	(18)
1.71	-	-	8	RP (Rx)	-	-	-	-	2	LN	-	-	(20)
1.8	pT2b	16.1	7	RP (Rx), salvage (2002), salvage RT (2006).	<0.1	8	0.02	8.7	1	LN	Confirmation by NaF PET/CT. Equivocal on MRI	Response to ADT with PSA decrease (nadir <0.1 ng/ml)	This report
1.86	-	-	8	RP (Rx) + ADT	-	-	-	-	3	Prostate	-	-	(20)

ADT, androgen-deprivation therapy; CT, computed tomography; LN, lymph node; MRI, magnetic resonance imaging; NaF, ¹⁸F-sodium fluoride; PSA, prostate-specific antigen; pT, pathological T stage; PET, positron emission tomography; PSAdt, PSA doubling time; RP (R1), radical prostatectomy with positive margins; RP (R0), radical prostatectomy with unknown status for margins; RP (Rx), radical prostatectomy with unknown status for margins; RT, radiotherapy; Tx, treatment; -, not reported. ^aTime from year of diagnosis to year of publication of the paper.

confirmed in both the patients with positive findings with two functional methods (⁶⁸Ga-PSMA and NaF PET) and at least one anatomical method (low-dose CT and/or MRI). In addition, both patients responded biochemically to anti-cancer treatment.

In conclusion, ⁶⁸Ga-PSMA PET/CT has emerged as a very promising imaging technique for use in identifying tumor sites in patients with biochemical recurrence. In comparison with standard imaging modalities as well as existing PET tracers, ⁶⁸Ga-PSMA PET/CT appeared to be sensitive at very low PSA levels (and in patients with slow PSA kinetics), which is optimal in terms of salvage radiotherapy.

Acknowledgements

The present study was supported by an unrestricted grant from the Obel Family Foundation.

References

- Vargas HA, Martin-Malburet AG, Takeda T, Corradi RB, Eastham J, Wibmer A, Sala E, Zelefsky MJ, Weber WA and Hricak H: Localizing sites of disease in patients with rising serum prostate-specific antigen up to 1 ng/ml following prostatectomy: How much information can conventional imaging provide? *Urol Oncol* 34: 482.e5-482.e10, 2016.
- Kane CJ, Amling CL, Johnstone PA, Pak N, Lance RS, Thrasher JB, Foley JP, Riffenburgh RH and Moul JW: Limited value of bone scintigraphy and computed tomography in assessing biochemical failure after radical prostatectomy. *Urology* 61: 607-611, 2003.
- Stephenson AJ, Scardino PT, Kattan MW, Pisansky TM, Slawin KM, Klein EA, Anscher MS, Michalski JM, Sandler HM, Lin DW, *et al.*: Predicting the outcome of salvage radiation therapy for recurrent prostate cancer after radical prostatectomy. *J Clin Oncol* 25: 2035-2041, 2007.
- Stish BJ, Pisansky TM, Harmsen WS, Davis BJ, Tzou KS, Choo R and Buskirk SJ: Improved metastasis-free and survival outcomes with early salvage radiotherapy in men with detectable prostate-specific antigen after prostatectomy for prostate cancer. *J Clin Oncol*: pii: JCO683425, 2016 (Epub ahead of print).
- Ceci F, Castellucci P, Graziani T, Schiavina R, Chondrogiannis S, Bonfiglioli R, Costa S, Virgolini IJ, Rubello D, Fanti S and Colletti PM: ¹¹C-choline PET/CT identifies osteoblastic and osteolytic lesions in patients with metastatic prostate cancer. *Clin Nucl Med* 40: e265-e270, 2015.
- Fanti S, Minozzi S, Castellucci P, Balduzzi S, Herrmann K, Krause BJ, Oyen W and Chiti A: PET/CT with ¹¹C-choline for evaluation of prostate cancer patients with biochemical recurrence: Meta-analysis and critical review of available data. *Eur J Nucl Med Mol Imaging* 43: 55-69, 2016.
- Sobel I, Zaid HB, Haloi R, Mynderse LA, Froemming AT, Lowe VJ, Davis BJ, Kwon ED and Karnes RJ: Contemporary mapping of post-prostatectomy prostate cancer relapse with ¹¹C-choline positron emission tomography and multiparametric magnetic resonance imaging. *J Urol* 197: 129-134, 2017.
- Kjölhede H, Ahlgren G, Almquist H, Liedberg F, Lyttkens K, Ohlsson T and Bratt O: ¹⁸F-choline PET/CT for early detection of metastases in biochemical recurrence following radical prostatectomy. *World J Urol* 33: 1749-1752, 2015.
- Castellucci P, Ceci F, Graziani T, Schiavina R, Brunocilla E, Mazzarotto R, Pettinato C, Celli M, Lodi F and Fanti S: Early biochemical relapse after radical prostatectomy: Which prostate cancer patients may benefit from a restaging ¹¹C-Choline PET/CT scan before salvage radiation therapy? *J Nucl Med* 55: 1424-1429, 2014.
- Giovacchini G, Picchio M, Briganti A, Cozzarini C, Scattoni V, Salonia A, Landoni C, Gianolli L, Di MN, Rigatti P, *et al.*: [¹¹C] choline positron emission tomography/computerized tomography to restage prostate cancer cases with biochemical failure after radical prostatectomy and no disease evidence on conventional imaging. *J Urol* 184: 938-943, 2010.
- Giovacchini G, Picchio M, Garcia-Parra R, Mapelli P, Briganti A, Montorsi F, Gianolli L and Messa C: [¹¹C]choline positron emission tomography/computerized tomography for early detection of prostate cancer recurrence in patients with low increasing prostate specific antigen. *J Urol* 189: 105-110, 2013.
- Heidenreich A, Bastian PJ, Bellmunt J, Bolla M, Joniau S, van der Kwast T, Mason M, Matveev V, Wiegel T, Zattoni F, *et al.*: EAU guidelines on prostate cancer. Part I: Screening, diagnosis, and local treatment with curative intent-update 2013. *Eur Urol* 65: 124-137, 2014.
- Afshar-Oromieh A, Avtzi E, Giesel FL, Holland-Letz T, Linhart HG, Eder M, Eisenhut M, Boxler S, Hadaschik BA, Kratochwil C, *et al.*: The diagnostic value of PET/CT imaging with the (⁶⁸Ga)-labelled PSMA ligand HBED-CC in the diagnosis of recurrent prostate cancer. *Eur J Nucl Med Mol Imaging* 42: 197-209, 2015.
- Eiber M, Maurer T, Souvatzoglou M, Beer AJ, Ruffani A, Haller B, Graner FP, Kübler H, Haberhorn U, Eisenhut M, *et al.*: Evaluation of Hybrid ⁶⁸Ga-PSMA Ligand PET/CT in 248 patients with biochemical recurrence after radical prostatectomy. *J Nucl Med* 56: 668-674, 2015.
- Maurer T, Eiber M, Schwaiger M and Gschwend JE: Current use of PSMA-PET in prostate cancer management. *Nat Rev Urol* 13: 226-235, 2016.
- Evangelista L, Briganti A, Fanti S, Joniau S, Reske S, Schiavina R, Stief C, Thalmann GN and Picchio M: New clinical indications for (18)F/(11)C-choline, new tracers for positron emission tomography and a promising hybrid device for prostate cancer staging: A systematic review of the literature. *Eur Urol* 70: 161-175, 2016.
- Perera M, Papa N, Christidis D, Wetherell D, Hofman MS, Murphy DG, Bolton D and Lawrentschuk N: Sensitivity, specificity and predictors of positive ⁶⁸Ga-prostate-specific membrane antigen positron emission tomography in advanced prostate cancer: A systematic review and meta-analysis. *Eur Urol* 70: 926-937, 2016.
- Barentsz JO, Richenberg J, Clements R, Choyke P, Verma S, Villeirs G, Rouviere O, Logager V and Futterer JJ: European Society of Urogenital Radiology: ESUR prostate MR guidelines 2012. *Eur Radiol* 22: 746-757, 2012.
- Passoni NM, Suardi N, Abdollah F, Picchio M, Giovacchini G, Messa C, Freschi M, Montorsi F and Briganti A: Utility of [¹¹C] choline PET/CT in guiding lesion-targeted salvage therapies in patients with prostate cancer recurrence localized to a single lymph node at imaging: Results from a pathologically validated series. *Urol Oncol* 32: 38.e9-e16, 2014.
- Afshar-Oromieh A, Zechmann CM, Malcher A, Eder M, Eisenhut M, Linhart HG, Holland-Letz T, Hadaschik BA, Giesel FL, Debus J and Haberkorn U: Comparison of PET imaging with a (⁶⁸Ga)-labelled PSMA ligand and (¹⁸F)-choline-based PET/CT for the diagnosis of recurrent prostate cancer. *Eur J Nucl Med Mol Imaging* 41: 11-20, 2014.
- Bluemel C, Krebs M, Polat B, Linke F, Eiber M, Samnick S, Lapa C, Lassmann M, Riedmiller H, Czernin J, *et al.*: ⁶⁸Ga-PSMA-PET/CT in patients with biochemical prostate cancer recurrence and negative ¹⁸F-Choline-PET/CT. *Clin Nucl Med* 41: 515-521, 2016.
- Schwenck J, Rempp H, Reischl G, Kruck S, Stenzl A, Nikolaou K, Pfannenbergl C and la Fougère C: Comparison of ⁶⁸Ga-labelled PSMA-11 and ¹¹C-choline in the detection of prostate cancer metastases by PET/CT. *Eur J Nucl Med Mol Imaging* 44: 92-101e, 2017.
- Bossuyt PM, Reitsma JB, Bruns DE, Gatsonis CA, Glasziou PP, Irwig LM, Lijmer JG, Moher D, Rennie D and de Vet HC: STARD Group: Towards complete and accurate reporting of studies of diagnostic accuracy: The STARD initiative. *Fam Pract* 21: 4-10, 2004.
- Freitag MT, Radtke JP, Hadaschik BA, Kopp-Schneider A, Eder M, Kopka K, Haberkorn U, Roethke M, Schlemmer HP, and Afshar-Oromieh A: Comparison of hybrid (⁶⁸Ga)-PSMA PET/MRI and (⁶⁸Ga)-PSMA PET/CT in the evaluation of lymph node and bone metastases of prostate cancer. *Eur J Nucl Med Mol Imaging* 43: 70-83, 2016.
- Demirkol MO, Acar O, Ucar B, Ramazanoglu SR, Saglican Y and Esen T: Prostate-specific membrane antigen-based imaging in prostate cancer: impact on clinical decision making process. *Prostate* 75: 748-757, 2015.