



CASE REPORT

Primary Cutaneous Nocardiosis Caused by *Nocardia takedensis*

Taek Geun Lee, Woo Jung Jin, Woo Seok Jeong, Seung Hyun Moon, Tae Gwang Kwon, Sook Kyung Lee, Hye Sook Kang¹, Hyun Hwangbo²

Departments of Dermatology and ¹Laboratory Medicine, Maryknoll Medical Center, ²Department of Dermatology, Kosin University College of Medicine, Busan, Korea

Nocardia species are aerobic, gram-positive, filamentous, partially acid-fast actinomycetes which are found worldwide in soil and decaying organic plant matter. When they infect human beings, they generally enter through the respiratory tract and then disseminate systemically. Rarely has a primary infection occurred as the result of direct inoculation. Isolation of *Nocardia* from clinical specimens and identification of species are difficult. But, with the introduction of new genetic technologies, reports of novel species of *Nocardia* have increased. We describe a case of cutaneous nocardiosis caused by *Nocardia takedensis* in an 87-year-old woman who was diagnosed by bacterial culture and 16S ribosomal RNA sequencing. *N. takedensis* has been described as a new species. This report describes the first clinical isolate of *N. takedensis* from a skin specimen in Korea. (Ann Dermatol 29(4) 471 ~ 475, 2017)

-Keywords-

Nocardia infections, *Nocardia takedensis*

Received July 5, 2016, Revised September 22, 2016, Accepted for publication October 14, 2016

Corresponding author: Sook Kyung Lee, Department of Dermatology, Maryknoll Medical Center, 121 Junggu-ro, Jung-gu, Busan 48972, Korea. Tel: 82-51-461-2438, Fax: 82-51-467-3232, E-mail: heartthrob80@naver.com

This is an Open Access article distributed under the terms of the Creative Commons Attribution Non-Commercial License (<http://creativecommons.org/licenses/by-nc/4.0>) which permits unrestricted non-commercial use, distribution, and reproduction in any medium, provided the original work is properly cited.

Copyright © The Korean Dermatological Association and The Korean Society for Investigative Dermatology

INTRODUCTION

Nocardia is an uncommon human pathogen infecting the lungs, skin, central nervous system, or other organs. It can present as a localized or disseminated infection¹⁻³. In 2005, *Nocardia takedensis* was isolated from moat sediment and sludge around the Takeda shrine in Japan and reported as a novel species^{4,5}. This species is closely related to *N. beijingensis* (98.1% ~ 98.3%), *N. brasiliensis* (97.9% ~ 98.0%), and *N. tenerifensis* (97.8% ~ 97.9%) according to 16S ribosomal RNA (rRNA) sequencing⁵. We report a case of cutaneous nocardiosis caused by *N. takedensis*, which is the first report of an infection caused by this species in Korea.

CASE REPORT

An 87-year-old Korean woman presented with erythematous and swollen plaque on her left forearm. She was elderly and lived alone in a rural area adjacent to Busan. When spraying an insecticide to kill ants in her house, she had suffered an abrasion on the left forearm; the abrasion had been present for several weeks and had not been treated. The same area revealed tender erythematous with swollen plaque accompanied by pustules, fluctuated abscesses, ulcers, and crustiness (Fig. 1A, B). She had no other remarkable history besides hypertension.

Abnormal laboratory findings included a total white blood cell count of 19,300/mm³ with 89% neutrophils. No abnormal findings were found on a chest X-ray or computed tomography scan, electrocardiograph, or blood chemistry, electrolyte, and urinary analyses. A skin biopsy was performed for histopathologic examination.

Histopathologic findings revealed by hematoxylin-eosin

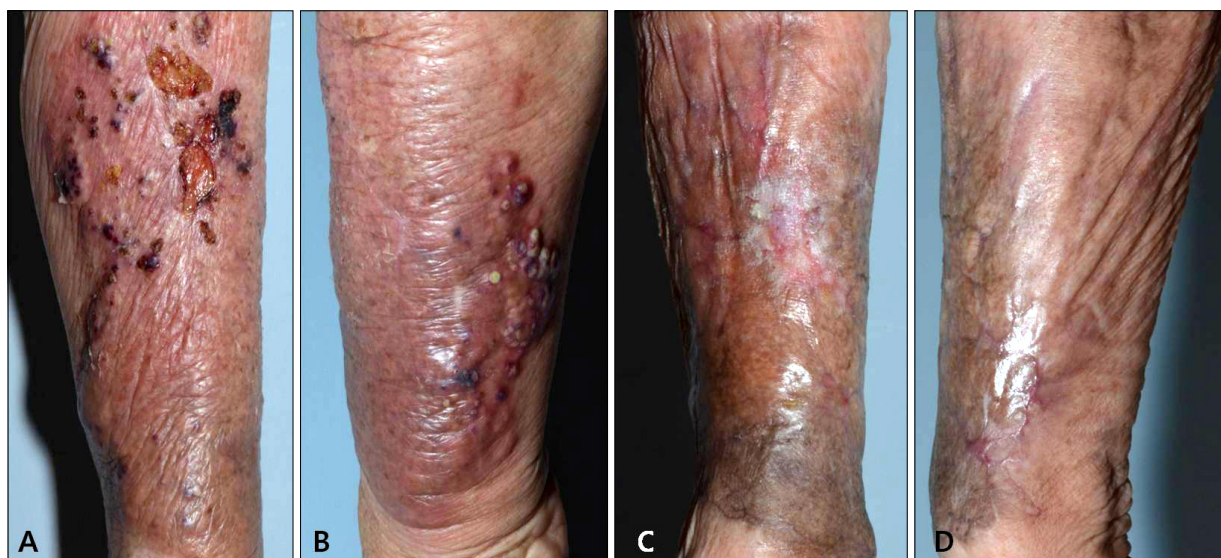

Fig. 1. Cutaneous nocardiosis from *Nocardia takedensis* infection. The left lower arm shows erythematous and edematous plaque, multiple ulcerations, abscesses, and black crusts. (A) Pretreatment lateral side, (B) pretreatment medial side, (C) posttreatment lateral side, (D) posttreatment medial side.

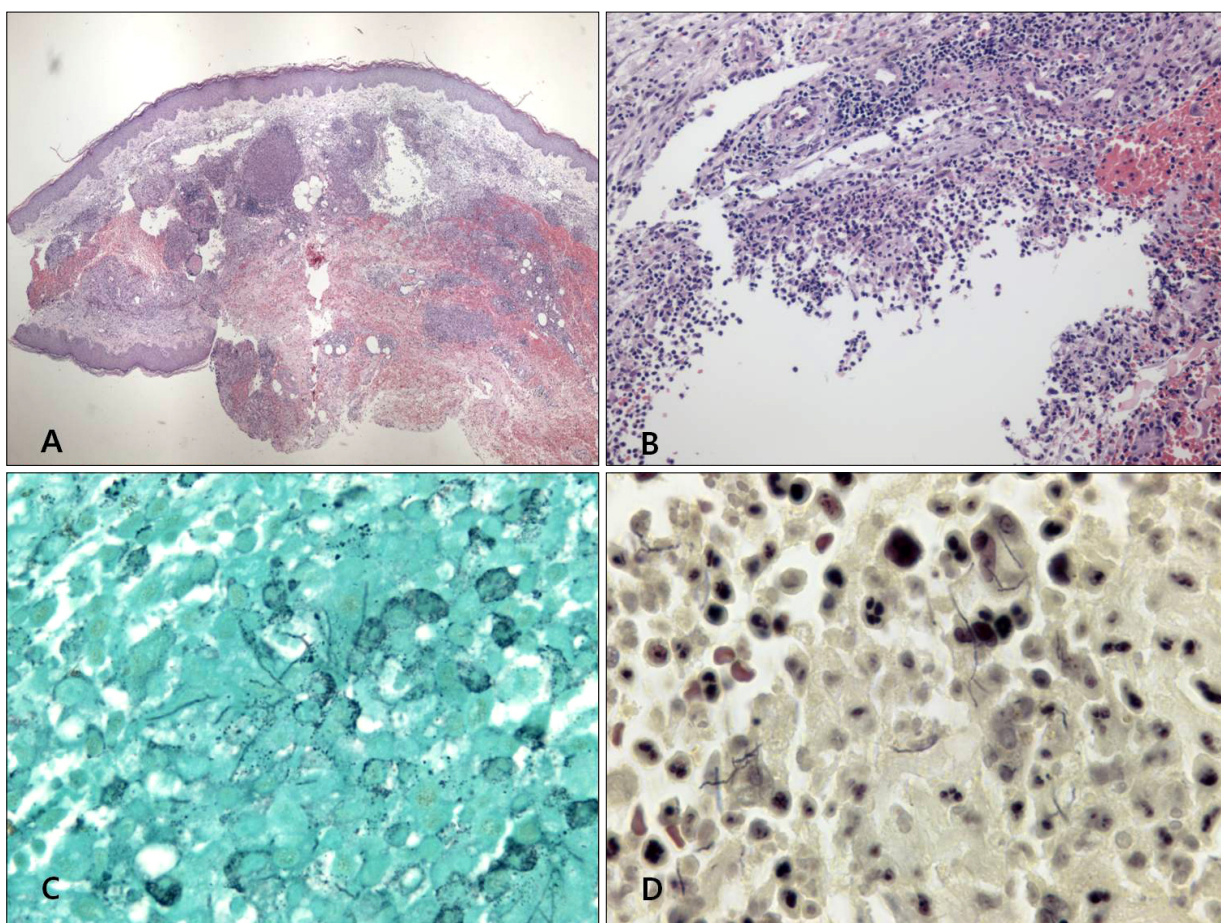


Fig. 2. Histopathologic findings. (A) Intense edema in the upper dermis and dense multinodular panniculitis and subcutaneous neutrophilic infiltration (H&E, $\times 40$). (B) Dense inflammatory infiltrates, with abscess formation, in the dermis (H&E, $\times 200$). (C) Fine, filamentous branching bacilli (Grocott-Gomori's methenamine silver [GMS] stain, $\times 1,000$). (D) Gram-positive rods with long, sinuous branches (Gram stain, $\times 1,000$).

staining included intense edema in the upper dermis and dense multinodular pandermal and subcutaneous neutrophilic infiltration (Fig. 2A, B). Grocott-Gomori's methenamine silver staining identified thin, filamentous bacilli (Fig. 2C). On gram staining, the organism was seen to be a Gram-positive long rod with branching hypae (Fig. 2D). Periodic acid-Schiff (PAS) and PAS with diastase also revealed filamentous bacilli and Ziehl-Neelsen staining showed partial positive results of a cultured colony (Fig. 3A), but not in a tissue specimen. Fungal culture and mycobacterium tuberculosis-polymerase chain reaction were negative.

When pus culture was conducted, chalky-orange colored colonies formed on a blood agar plate 2 weeks after the start of incubation (Fig. 3B). Sequencing of 16S rRNA gene using a cultured colony was done for molecular identification. The isolated sequence was then compared with those of representative species of the genus *Nocardia* as classified in GenBank of the National Center for Biotechnology Information (NCBI). Our cultured isolate was identified as *N. takedensis* with 99.56% sequence similarity (3 nucleotide differences out of 688 nucleotides) to the strain

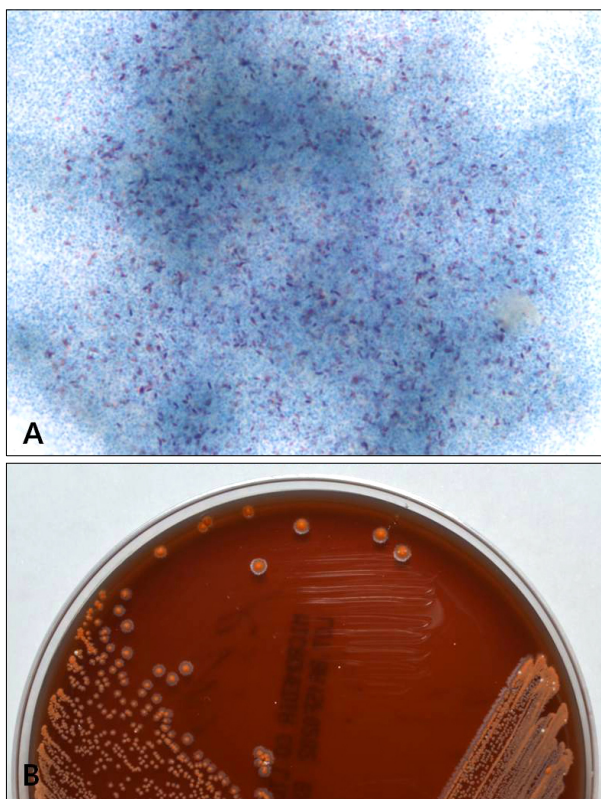


Fig. 3. Colony culture. (A) Ziehl-Neelsen stain revealing a partially positive result on cultured colony (Ziehl-Neelsen, $\times 1,000$). (B) Chalky-orange-colored colonies formed on a blood agar plate incubated at 35°C for 2 weeks.

WE30 (Fig. 4).

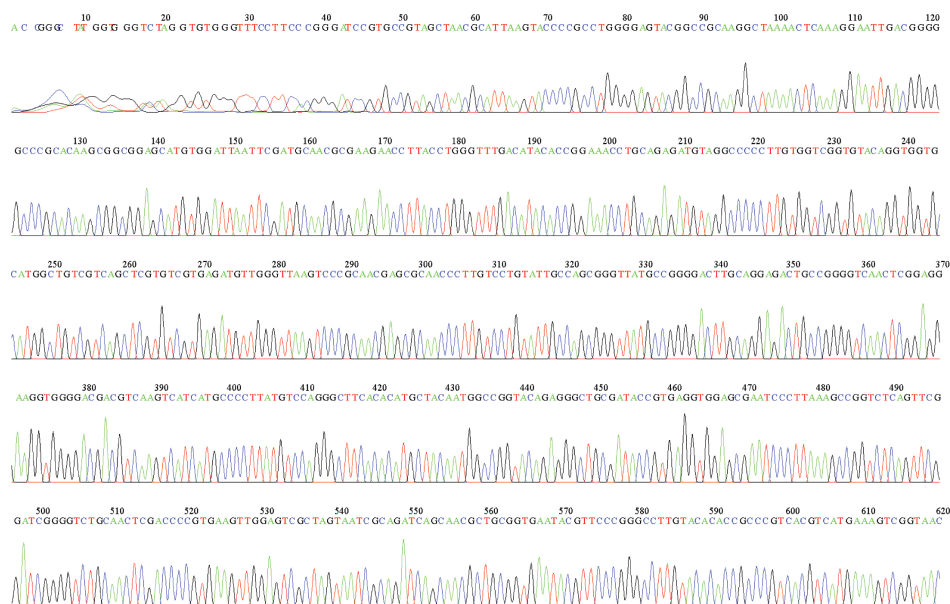
At the time the skin biopsy was taken (on the first hospital day), treatment by drip infusion of 2 g/day of ceftriaxone sodium was begun as an empirical therapy; treatment was continued for 16 days with improvement. After systemic disease was excluded and *N. takedensis* was identified, the patient was administered trimethoprim-sulfamethoxazole (TMP-SMX), 400/80 mg by mouth twice daily considering antimicrobial susceptibility and difficulties in securing an intravenous line. Treatment was maintained for 40 days until the patient recovered completely (Fig. 1C, D).

DISCUSSION

Nocardia is usually an "opportunistic pathogen," with the majority of infections occurring in patients with immunosuppressive conditions. Up to one-third of patients with nocardiosis, however, are immunocompetent. *Nocardia* are ubiquitous in the environment and can be found worldwide as saprophytic entities in fresh and salt water, soil, dust, and decaying vegetation⁶. Cutaneous manifestation of nocardiosis can be classified into primary cutaneous nocardiosis and disseminated disease. Primary cutaneous nocardiosis results from direct inoculation of pathogenic *Nocardia*. Disseminated disease is more common and usually occurs in the setting of primary pulmonary infection and underlying immunosuppression⁷. Primary cutaneous nocardiosis can be further divided into three major subtypes: lymphocutaneous disease, superficial cellulitis, and nocardial mycetoma. Cutaneous nocardiosis can result from traumatic injury to the skin that involves contamination with soil and resembles soft tissue infection caused by *Staphylococcus aureus* or streptococci; however, this form of nocardial disease usually follows an indolent course⁶. We supposed that the organism might have gained access via a contaminated superficial abrasion on the patient's forearm, thus forming superficial cellulitis in our case.

Three cases of primary cutaneous nocardiosis caused by *N. takedensis* have been identified. The first case involved a 68-year-old woman in Taiwan who had chronic kidney disease and diabetes mellitus and presented with foot cellulitis. *N. takedensis* was isolated from a biopsy of foot tissue⁸. The second case was a healthy 33-year-old man in Mexico who presented with hemithoracic actinomycetoma⁹. The last case was a 68-year-old woman with a history of follicular lymphoma and myelodysplastic syndrome after allogenic peripheral blood stem cell transplantation who presented with painful lymphangitic erythematous papules on the left arm after suffering an abrasion on the left dorsal hand⁷. All patients were treated with oral

File: Agar_plate_2_785F.ab1 Run Ended: 2015/7/2 23:35:27 Signal G:5352 A:3944 C:5907 T:4002
 Sample: Agar_plate_2_785F Lane: 52 Base spacing: 14.592572 713 bases in 8640 scans Page 1 of 2



File: Agar_plate_2_785F.ab1 Run Ended: 2015/7/2 23:35:27 Signal G:5352 A:3944 C:5907 T:4002
 Sample: Agar_plate_2_785F Lane: 52 Base spacing: 14.592572 713 bases in 8640 scans Page 2 of 2

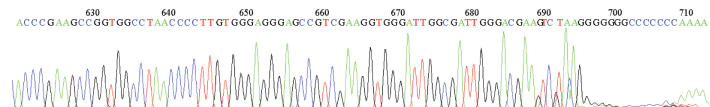


Fig. 4. 16S ribosomal RNA (rRNA) gene sequencing. DNA was extracted from a cultured colony for polymerase chain reaction amplification and sequencing of both strands of the 16S rRNA gene. The sequence data confirmed the presence of *Nocardia takedensis*.

TMP-SMX.

The genus *Nocardia* consists of distinctive gram-positive variably acid-fast, strictly aerobic bacteria that form branched aerial and substrate filaments which, as they age, fragment into pleomorphic rod-shaped or coccoid elements. The colonies with abundant aerial filamentous growths have a chalky white or cotton-ball appearance on blood agar plates and may resemble *Streptomyces* species or, superficially, even some fungi³. The organisms are rarely partially acid-fast with routine Ziehl-Neelsen stain. Actinomyces may appear morphologically similar to these organisms, but unlike *Nocardia*, they are not acid-fast and grow under anaerobic conditions. Most other fungal hyphal structures do not figure in the differential diagnosis of *Nocardia* as they have much thicker hyphal forms¹⁰. Clinicians and pathologists should be aware that the *Nocardia* genus continues to undergo the addition of new species; more than 50 species have been identified to date. The species variability in general morphologic characteristics and acid fastness, which is caused by differences in cell wall mycolic acid composition and the type of stain used, makes identification and species differentiation challenging⁷. Classical identification based on

colony morphology or morphological characteristics of *Nocardia* does not allow for differentiation between the numerous species. The new molecular methods based on the 16S rRNA gene are crucial for *Nocardia* identification¹¹. The different species of *Nocardia* display variable *in vitro* antimicrobial susceptibility patterns, so management of nocardial infections must be individualized⁶. TMP-SMX is active against most species; however, clinicians should note that *N. otitidiscaviarum*, *N. nova*, and *N. farcinica* have shown notable resistance and that up to 42% of *Nocardia* isolates submitted to the Centers for Disease Control and Prevention for antimicrobial susceptibility testing between 1995 and 2004 were resistant to TMP-SMX⁷. Alternative antimicrobial agents with activity against *Nocardia* include amikacin, imipenem, meropenem, ceftriaxone, cefotaxime, minocycline, moxifloxacin, levofloxacin, linezolid, tigecyclin, and amoxicillin-clavulanic acid. Combination therapy with imipenem and cefotaxime, amikacin and TMP-SMX, imipenem and TMP-SMX, amikacin and cefotaxime, or amikacin and imipenem may provide enhanced efficacy⁶. The suggested duration of therapy ranges from 6 weeks for minor infections to 1 year for severe systemic diseases¹². In our case, the minimum

inhibitory concentration ceftriaxone, amikacin and TMP-SMX were checked. The bacterial strain was susceptible to ceftriaxone and TMP-SMX.

In conclusion, the new molecular identification methods based on the 16S rRNA gene for *Nocardia* identification are crucial¹¹. Because there are no optimal recommendations for treatment of all *Nocardia* species, physicians should use empirical combination therapy that may include TMP-SMX, ceftriaxone, and imipenem until susceptibility results are available. The authors recommend that identification and antimicrobial susceptibility testing be performed by a reference laboratory to help guide therapeutic decisions for all clinical *Nocardia* isolates¹³.

CONFLICTS OF INTEREST

The authors have nothing to disclose.

REFERENCES

1. Brown-Elliott BA, Brown JM, Conville PS, Wallace RJ Jr. Clinical and laboratory features of the *Nocardia* spp. based on current molecular taxonomy. *Clin Microbiol Rev* 2006;19:259-282.
2. Saubolle MA, Sussland D. Nocardiosis: review of clinical and laboratory experience. *J Clin Microbiol* 2003;41:4497-4501.
3. Lerner PI. Nocardiosis. *Clin Infect Dis* 1996;22:891-903.
4. Yamamura H, Hayakawa M, Nakagawa Y, Tamura T, Kohno T, Komatsu F, et al. *Nocardia takedensis* sp. nov., isolated from moat sediment and scumming activated sludge. *Int J Syst Evol Microbiol* 2005;55:433-436.
5. Japan MLJVTGJ. Takeda shrine. 2007-2012 [Internet]. MustLoveJapan; 2014 Oct 29. Available from: http://www.mustlovejapan.com/subject/takeda_jinja/.
6. Wilson JW. Nocardiosis: updates and clinical overview. *Mayo Clin Proc* 2012;87:403-407.
7. Chung E, Pulitzer MP, Papadopoulos EB, Papanicolaou GA, Babady NE, Marchetti MA. Lymphangitic papules caused by *Nocardia takedensis*. *JAAD Case Rep* 2015;1:126-128.
8. Liu WL, Lai CC, Ko WC, Chen YH, Tang HJ, Huang YL, et al. Clinical and microbiological characteristics of infections caused by various *Nocardia* species in Taiwan: a multicenter study from 1998 to 2010. *Eur J Clin Microbiol Infect Dis* 2011;30:1341-1347.
9. Kresch-Tronik NS, Carrillo-Casas EM, Arenas R, Atoche C, Del Río-Ávila C, Ochoa-Carrera LA, et al. First case of mycetoma associated with *Nocardia takedensis*. *J Dermatol* 2013;40:135-136.
10. Mathur S, Sood R, Aron M, Iyer VK, Verma K. Cytologic diagnosis of pulmonary nocardiosis: a report of 3 cases. *Acta Cytol* 2005;49:567-570.
11. Betrán A, Rezusta A, Lezcano MA, Villuendas MC, Revillo MJ, Boiron P, et al. First Spanish case of nocardiosis caused by *Nocardia takedensis*. *J Clin Microbiol* 2009;47:1918-1919.
12. In SG, Han SH, Shin JH, Choi GS, Chung MH. A case of disseminated nocardiosis secondary to the skin nodules in an elderly woman. *Ann Dermatol* 2008;20:82-85.
13. Uhde KB, Pathak S, McCullum I Jr, Jannat-Khah DP, Shadomy SV, Dykewicz CA, et al. Antimicrobial-resistant nocardia isolates, United States, 1995-2004. *Clin Infect Dis* 2010;51:1445-1448.