

The diagnostic accuracy of ultrasonography for soft tissue lipomas: a systematic review

George Rahmani¹, Peter McCarthy^{1,2} and Diane Bergin¹

Acta Radiologica Open
6(6) 1–6
© The Foundation Acta Radiologica
2017
Reprints and permissions:
sagepub.co.uk/journalsPermissions.nav
DOI: 10.1177/2058460117716704
journals.sagepub.com/home/arr



Abstract

Background: Ultrasound has been used in the diagnosis of soft-tissue lesions for well over a decade. Lipomas are the most common, benign, soft-tissue tumor and comprise adipose tissue. The sensitivity and specificity of diagnosing lipomas on ultrasound vary greatly in the literature.

Purpose: To perform a systematic review on ultrasonography in soft-tissue lipomas to better ascertain the true diagnostic value of this test.

Material and Methods: A systematic review of the diagnostic value of ultrasound in lipomas was performed where possible in line with the Preferred Reporting Items for Systematic Reviews and Meta-Analyses (PRISMA) guidelines. A comprehensive search of the literature was conducted using several well-known databases Scopus[®], PubMed[®], Ovid[®] Medline, and Web of Science[®].

Results: A total of 455 articles were identified in the initial literature search. Six papers were included in the final systematic review, which revealed an overall sensitivity and specificity of 86.87% (95% confidence interval [CI] = 82.14–90.73) and 95.95% (95% CI = 93.75–97.54), respectively.

Conclusion: Ultrasound is a useful tool in the diagnosis of superficial lipomas with good sensitivity and even better specificity and should continue to be the first line investigation in such cases.

Keywords

Soft tissue/ skin, ultrasound, statistics, systematic review

Date received: 9 April 2017; accepted: 31 May 2017

Introduction

A lipoma is a benign tumor comprising adipose tissue and can occur in any region of the body that contains fat including the subcutaneous soft tissues, bones, mediastinum, and along the gastrointestinal tract (1). It is one of the most common mesenchymal derived tumors and the most benign soft-tissue tumor accounting for nearly half of all soft-tissue neoplasms (2,3).

When it comes to imaging suspected soft-tissue lipomas, ultrasonography is often the first modality that is called upon because it is cheap, readily available, relatively sensitive and specific, and offers focused and real-time evaluation of the lesion of interest. Traditionally it has been taught that the sonographic appearance of a simple lipoma is consistent with a hyperechoic mass with no posterior acoustic enhancement (4). These soft-tissue masses are lower in reflectivity than muscle

but more reflective than adjacent subcutaneous fat. In reality, while the majority of lipomas are hyperechoic, a significant proportion of them can also be hypoechoic or isoechoic (5).

The diagnostic sensitivity and specificity of lipomas on ultrasound in the literature are in the range of 52–100% and 86–100%, respectively (5,6).

The aim of this study was to conduct a systematic review of all the studies that have examined the diagnostic accuracy of ultrasound in lipomas in order to

¹Department of Radiology, Galway University Hospitals, Galway, Ireland
²National University of Ireland, Galway, Ireland

Corresponding author:

George Rahmani, Galway University Hospitals, Galway, Ireland.
Email: george.rahmani@gmail.com



better understand the true sensitivity and specificity of this diagnostic test. To the best of our best knowledge, this is the first systematic review looking specifically at the sensitivity and specificity of ultrasound in the diagnosis of lipomas.

Material and Methods

A systematic review of the literature was performed where possible in line with the Preferred Reporting Items for Systematic Reviews and Meta-Analyses (PRISMA) guidelines (7–9).

Database search

A comprehensive and in-depth search of the literature was conducted using several well-known databases Scopus[®], PubMed[®], Ovid[®] Medline, and Web of Science[®]. The search terms and Boolean operators used were “ultrasound” AND “lipoma” AND (“diagnostic” OR “accuracy”). Articles were then examined for potential inclusion in the final review. The references from each of the papers that were selected for the final review were also examined for additional articles that may have been missed during the initial search.

Inclusion and exclusion criteria

After a thorough review of the articles from the above databases, the initially identified articles were then vetted against the predetermined inclusion and exclusion criteria (Table 1) at several different stages including title review, abstract review, and full text review. The inclusion criteria were as follows: all articles published in the English language that compared ultrasound diagnosis with histological diagnosis of soft-tissue lipomas and were performed in humans. Articles were not deemed eligible for inclusion if they were published in a language other than English, if they were animal-based or lab-based bench research, if

another imaging modality was used instead of ultrasound, or if the ultrasound was not diagnostic but was used purely as an adjunct for a guided biopsy/fine needle aspiration cytology. Only full-length articles were included. Case reports, letters to the editor, and review articles were excluded.

Data extraction

Data were extracted from the text and tables of the papers. The author, journal, year of publication, and institution of origin were recorded. The characteristics of the lipoma on ultrasound were recorded where described including the echogenicity, color flow, and location of the lipoma. The sensitivity, specificity, and accuracy of the sonographic tests when compared with their final histological diagnosis were also recorded.

Results

Articles included

From 1971 to 2016, a total of 455 articles were identified in the initial literature search across the four selected databases (Fig. 1). There were no additional articles discovered by cross-referencing with the references from the papers that were included in the final analysis. After examining article titles and removing duplicates, 37 papers were selected for abstract review. After reviewing these abstracts, 20 papers were identified for review of the full text. After reviewing the full text of these 20 articles and applying the inclusion and exclusion criteria, six articles that were published between 2004 and 2015 were selected for inclusion in the final systematic review (Table 2). The reason for the 14 papers being excluded from the final analysis after full text review were as follows: two review articles, one article examined ganglia only, three non-English language articles, one article used ultrasound to guide biopsies only, one article was an abstract only, one article did not examine histology reports, and five articles did not discern lipomas from other soft-tissue masses.

Data extracted

The sensitivity, specificity, and accuracy of ultrasound in the diagnosis of lipomas varied widely across the studies with sensitivities as low as 52% in a series by Inampudi et al. (5) compared with 100% as described by Hwang et al. (6). The largest series came from Hung et al. with a total of 105 histopathological proven lipomas included in their study of 714 superficial soft-tissue lesions (10). There were a further 231 presumed lipomas identified on ultrasound in this case that did

Table 1. Predefined inclusion and exclusion criteria for articles to be included in the final review.

Inclusion criteria	Exclusion criteria
Human studies	Non-human, animal or bench research
English language	Non-English language
Ultrasound compared with histology	Ultrasound guided biopsy only
Lipomas	No histological comparison Lipomas not specifically identified Other imaging modality used instead of ultrasound

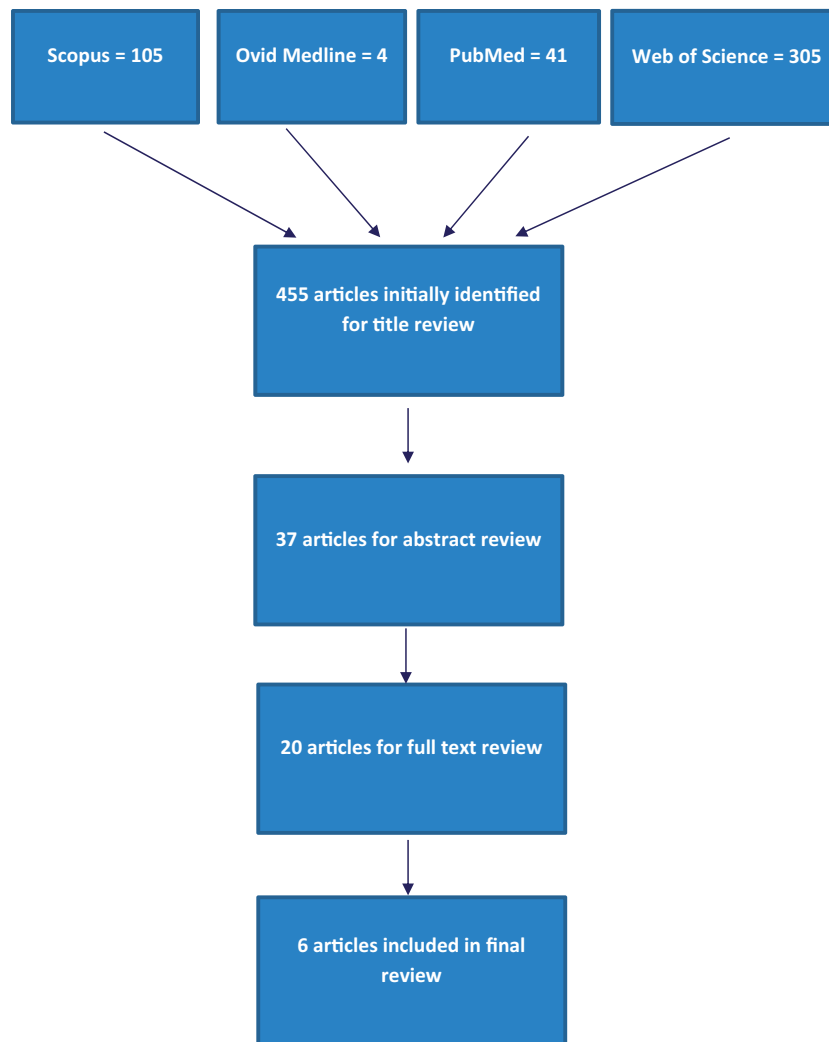


Fig. 1. Flowchart of the selection process of papers for inclusion in the systematic review.

not undergo any form of biopsy for histopathological analysis.

Most studies examined lipomas in the wider context of other soft-tissue nodules or masses including ganglions, epidermal cysts, dermoid cysts, hemangiomas and vascular malformations, pilomatrixomas, angioli-pomas, fibrolipomas, well-differentiated liposarcomas, dermatofibromas, glomus tumors, lymphadenopathy, and nerve sheath tumors. In all cases, it was possible to extract data specific to lipomas given that they are the most common benign soft-tissue tumors and tended to be the most frequent finding.

Echogenicity

Two studies commented on the echogenic patterns of lipoma on ultrasound (5,11). Cumulatively, 17% were hypoechoic, 59% were isoechoic, and 24% were hyperechoic when compared with adjacent subcutaneous fat.

Location

Inampudi et al. commented on the location of the lipoma as being subcutaneous or intramuscular. All other studies strictly examined superficial lipomas and these were all presumably subcutaneous and supra fascial. Wagner et al. also commented on the distribution of lipomas throughout the body. Of the 39 lipomas in that series, six (15%) were found in the head/neck, 14 (36%) in the shoulder/upper extremity (three of these being angioli-pomas), six (15%) in the abdomen (one of these being an angioli-poma), and 13 (33%) on the back (one of these being a fibrolipoma).

Color flow

Wagner et al. commented on the presence or absence of color flow in lipomas (11). In that study, 58.6% of cases had absent color flow and 41.4% had minimal color flow on Doppler sonography.

Table 2. Papers included in the systematic review.

Paper	(N)	Sensitivity (%)	Specificity (%)	Equipment Used
Hwang et al., 2015 (6)	13	100	100	Philips iU-22; 5-15 MHz
Hung et al., 2014 (10)	105	95.2	94.3	Philips iU-22 / Siemens Sonoline Elegra; 9-17 MHz
Wagner et al., 2013 (11)	39	92	100	Siemens Acuson Sequoia 512; 7-14MHz
Lin et al., 2009 (22)	35	74	86	Toshiba Xario Model; 7-14 MHz
Kuwano et al., 2009 (23)	42	88.1	99.3	Toshiba Aplio; 8.5 MHz
Inampudi et al., 2004 (5)	25	52	86	Philips HDI 3000 and 5000 / Siemens Sonoline Elegra; 7-12 MHz
Total	259	86.87	95.95	

Table 3. Breakdown of true/false positives/negatives in each study.

Paper	True +	False -	True -	False +
Hwang et al., 2015 (6)	13	0	87	0
Hung et al., 2014 (10)	100	5	115	7
Wagner et al., 2013 (11)	36	3	33	0
Lin et al., 2009 (22)	26	9	62	9
Kuwano et al., 2009 (23)	37	5	141	1
Inampudi et al., 2004 (5)	13	12	12	2
Total	225	34	450	19

Type of equipment used

There were a wide variety of ultrasound machines and probes used across the various studies. The majority of studies used linear transducers with frequencies in the range of 5–15 MHz (Table 2). These included ultrasound machines and probes made by Philips[®], Toshiba[®], GE[™], and Siemens[®].

Sensitivity and specificity

The overall sensitivity and specificity of ultrasound in the diagnosis of lipomas was 86.87% (95% CI = 82.14–90.73) and 95.95% (95% CI = 93.75–97.54), respectively (Tables 2 and 3).

Discussion

The overall sensitivity and specificity of ultrasound in the diagnosis of lipomas was 85.71% (95% CI = 80.85–89.74) and 95.95% (95% CI = 93.75–97.54), respectively. As mentioned previously, the diagnostic sensitivity and specificity of lipomas on ultrasound in the literature are in the range of 52–100% and 86–100%, respectively (5,6). This variance in described accuracy of ultrasound in the diagnosis of lipomas may be due to several factors. As technology has improved,

so too has the diagnostic power of ultrasound; and as papers are being published over time, it is reasonable to presume that diagnostic accuracy has improved over time due to this fact alone. The advent of high frequency, high-resolution ultrasound has led to improvements in image quality and these images are projected on higher resolution screens that allow a more accurate representation of the lesion of interest.

The differential diagnoses other than lipomas on ultrasound include epidermoid and ganglion cyst, peripheral nerve sheath tumor, accessory breast tissue, hamartomas, and fibroma. These soft-tissue lesions accounted for some of the false positives and false negatives in the included studies. Epidermoid cysts generally have the appearance of a well circumscribed, hypoechoic mass and are often associated with a hair follicle (12). Ganglia are typically hypoechoic or anechoic, well circumscribed, and are generally found closely related to joints usually in the hand/wrist. Benign peripheral nerve sheath tumors such as Schwannomas and neurofibromas are generally also hypoechoic, well circumscribed lesions but they are usually found in continuity with the involved peripheral nerve and may also display a target sign of peripheral hypoechoicity and central hypoechoicity, as well as posterior acoustic enhancement, allowing them to be better distinguished from lipomas (13). Hamartomas are typically well-defined hypoechoic lesions with hyperechoic internal bands or nodules caused by the fibrous component of these lesions (14).

A soft-tissue lipoma can be characterized as being superficial or deep. In general, it is best to consider all lipomas deep to the investing fascia or subfascial as being deep-seated lipomas and all others superficial to this fascia as being superficial lipomas (15). Clinically, a superficial lipoma has the characteristic feel of a discrete, freely mobile, fluctuant, ovoid or elliptical mass, and in these cases, clinical examination alone is sufficient in achieving an accurate diagnosis up to 85% of cases (3,16,17). Deep-seated lipomas are more difficult to assess on clinical examination in this regard.

By definition, they lie at least under the superficial fascia of the muscle and may even be intramuscular and so the examiner may only feel a vague and non-specific soft tissue mass on palpation. Ultrasound characteristics of deep-seated lipomas are more varied than superficial lipomas. The fibrous capsule often seen on ultrasound in superficial lipomas cannot be appreciated in intramuscular lipomas as the capsule cannot be distinguished from the muscle that envelops it. Skeletal muscle can also interdigitate these lipomas and create irregular margins and give a striated appearance.

With the exception of Inampudi et al. (5), all other studies included in the systematic review were superficial lipomas. Inampudi et al. included deep-seated, sub-fascial lipomas, which may explain why it is the study with lowest sensitivity. Inampudi et al. also made a distinction between lipomas and angioliomas and this would also have increased the number of false positives on ultrasound. Histopathologically, angioliomas are distinct entities in their own right; clinically, they are very similar in behavior to benign lipomas and in reality are treated the same. It is for this reason that we have not made this distinction in our own study which reflects the practices of other such previously published studies (11).

One of the disadvantages of ultrasound is that it can be dependent on body habitus in certain circumstances. The penetrance of an ultrasound wave is inversely proportional to the frequency of that wave. While a high frequency probe like a 15 MHz linear transducer can provide high-resolution visualization of superficial structures, it is much less effective in accurately imaging the rotator cuff of a patient with an extremely obese or muscular body habitus. In this case, a lower frequency probe must be required to assess deeper structures at the expense of the resolution of the images. Having said that, like all areas of radiology, with technological advances come improvements in imaging and the advent of phase inversion tissue harmonic sonographic imaging has allowed better resolution in these cases (18).

Another disadvantage of ultrasound compared with other imaging modalities and partly due to the dynamic nature of the study is that it is highly user-dependent (19). A study by Pohl et al. examined the diagnostic value of provisional ultrasound reports issued by non-radiologists in suspected appendicitis and concluded that the sensitivity is so diminished that it is not reliable enough to justify performing the examination without an experienced radiologist to provide their interpretation of the images (20). There are other technical factors that can affect ultrasound, which can make its interpretation difficult. Ideally, the transducer must be placed at 90° to the structure of interest to prevent an artifact known as anisotropy in which a deviance of the transducer angle causes the ultrasound waves to reflect

away from the probe causing an apparent reduction in echogenicity of the examined structure. Other technical considerations include maintaining proper skin contact, using the appropriate transducer size, shape, and frequency for the structure of interest and body part being examined (21).

Limitations of this systematic review include low number of studies, many of which have relatively low numbers. The smallest study, by Hwang et al., only included 13 lipomas, and while they describe a sensitivity and specificity of 100%, it is clear that it is not possible to draw any meaningful conclusions from it alone. Some of the studies were retrospective in design, with static images being reviewed retrospectively (Hwang et al. (6) and Wagner et al. (11)). The studies by Inampudi et al. (5) and Wagner et al. (11) used a combination of both prospective and retrospective review of images. The retrospective review of static images is a common limitation of clinical studies into ultrasonography.

In conclusion, sonography is a useful test in the diagnosis of superficial, soft tissue lipomas. It is sensitive and specific enough to be a reasonable first line investigation in these cases.

Declaration of Conflicting Interests

The author(s) declared no potential conflicts of interest with respect to the research, authorship, and/or publication of this article.

Funding

The author(s) received no financial support for the research, authorship, and/or publication of this article.

References

1. Fornage BD, Tassin GB. Sonographic appearances of superficial soft tissue lipomas. *J Clin Ultrasound* 1991; 19:215–220.
2. Bancroft LW, Kransdorf MJ, Peterson JJ, et al. Benign fatty tumors: classification, clinical course, imaging appearance, and treatment. *Skeletal Radiol* 2006;35: 719–733.
3. Myhre-Jensen O. A consecutive 7-year series of 1331 benign soft tissue tumours. Clinicopathologic data. Comparison with sarcomas. *Acta Orthop Scand* 1981;52: 287–293.
4. Ahuja AT, King AD, Kew J, et al. Head and neck lipomas: sonographic appearance. *Am J Neuroradiol* 1998;19: 505–508.
5. Inampudi P, Jacobson JA, Fessell DP, et al. Soft-Tissue Lipomas: Accuracy of Sonography in Diagnosis with Pathologic Correlation. *RSNA Radiology* 2004;233: 763–767.
6. Hwang EJ, Yoon HS, Cho S, et al. The diagnostic value of ultrasonography with 5-15-MHz probes in benign subcutaneous lesions. *Int J Dermatol* 2015;54:e469–e75.

7. Moher D, Liberati A, Tetzlaff J, et al. Preferred reporting items for systematic reviews and meta-analyses: the PRISMA statement. *J Clin Epidemiol* 2009;62:1006–1012.
8. Moher D, Shamseer L, Clarke M, et al. Preferred reporting items for systematic review and meta-analysis protocols (PRISMA-P) 2015 statement. *Syst Rev* 2015;4:1.
9. Shamseer L, Moher D, Clarke M, et al. Preferred reporting items for systematic review and meta-analysis protocols (PRISMA-P) 2015: elaboration and explanation. *BMJ* 2015;349:g7647.
10. Hung EHY, Griffith JF, Ng AWH, et al. Ultrasound of musculoskeletal soft-tissue tumors superficial to the investing fascia. *Am J Roentgenol* 2014;202:W532–540.
11. Wagner JM, Lee KS, Rosas H, et al. Accuracy of sonographic diagnosis of superficial masses. *J Ultrasound Med* 2013;32:1443–1450.
12. Beaman FD, Kransdorf MJ, Andrews TR, et al. Superficial soft-tissue masses: analysis, diagnosis, and differential considerations. *Radiographics* 2007;27:509–523.
13. Reynolds DL, Jacobson JA, Inampudi P, et al. Sonographic characteristics of peripheral nerve sheath tumors. *Am J Roentgenol* 2004;182:741–744.
14. Presazzi A, Di Giulio G, Calliada F. Breast hamartoma: ultrasound, elastosonographic, and mammographic features. Mini pictorial essay. *J Ultrasound* 2015;18:373–377.
15. Murphey MD, Carroll JF, Flemming DJ, et al. From the archives of the AFIP: benign musculoskeletal lipomatous lesions. *Radiographics* 2004;24:1433–1466.
16. Rydholm A, Berg NO. Size, site and clinical incidence of lipoma. Factors in the differential diagnosis of lipoma and sarcoma. *Acta Orthop Scand* 1983;54:929–934.
17. Osment LS. Cutaneous lipomas and lipomatosis. *Surg Gynecol Obstet* 1968;127:129–132.
18. Rosenthal SJ, Jones PH, Wetzel LH. Phase inversion tissue harmonic sonographic imaging: a clinical utility study. *Am J Roentgenol* 2001;176:1393–1398.
19. Beyer D, Schulte B, Kaiser C, et al. [Sonography of acute appendicitis. A 5-year prospective study of 2074 patients. 2]. *Radiologe* 1993;33:399–406.
20. Pohl D, Golub R, Schwartz GE, et al. Appendiceal ultrasonography performed by nonradiologists: does it help in the diagnostic process? *J Ultrasound Med* 1998;17:217–221.
21. Lento PH, Primack S. Advances and utility of diagnostic ultrasound in musculoskeletal medicine. *Curr Rev Musculoskelet Med* 2008;1:24–31.
22. Lin C-S, Wang T-G, Shieh J-Y, et al. Accuracy of Sonography in the Diagnosis of Superficial Ganglion Cyst and Lipoma. *J Med Ultrasound* 2009;17:107–113.
23. Kuwano Y, Ishizaki K, Watanabe R, et al. Efficacy of diagnostic ultrasonography of lipomas, epidermal cysts, and ganglions. *Arch Dermatol* 2009;145:761–764.