

## Small bowel obstruction caused by *Anisakis* and Meckel's diverticulum: a rare case

G. CARBOTTA, R. LAFORGIA, M. MILELLA, M.G. SEDERINO,  
M. MINAFRA, F. FORTAREZZA, D. PISCITELLI, N. PALASCIANO

**SUMMARY: Small bowel obstruction caused by *Anisakis* and Meckel's diverticulum: a rare case.**

G. CARBOTTA, R. LAFORGIA, M. MILELLA, M.G. SEDERINO,  
M. MINAFRA, F. FORTAREZZA, D. PISCITELLI, N. PALASCIANO

**Introduction.** *Anisakiasis* is a parasitic infection caused by the ingestion of raw fish contaminated by larval nematodes of *Anisakis* species. Intestinal or extraintestinal manifestations are rated to > 4% and >1% respectively.

**Presentation of case.** A 61-year old patient was admitted to our General Surgical and Emergency Unit because of sudden abdominal pain, vomit and constipation. He had eaten raw fish 3 days before admission. Laboratory data showed high levels of WBC and PCR. CT scanning showed "dilation of jejunum and ileum loops, thickening of the terminal ileum and cecum and signs of inflammation of the intestinal wall and mesentery". The following emergency surgical procedure

was performed: laparotomy with evidence of obstruction of the small bowels, a giant Meckel's diverticulum, resection of terminal ileum and cecum and ileocolonic anastomosis. At the microscopic examination, the intestinal wall appeared occupied by a transmural inflammatory infiltrate, mainly eosinophilic, edema and nematode larvae, referable to *Anisakis*, surrounded by necrotic-inflammatory material. Moreover, there was evidence of giant a Meckel's diverticulum.

**Discussion.** Normally, enteric *Anisakiasis* exhibits leukocytosis with eosinophilia and high CRP levels. There are cases of successful medical treatment and other cases of endoscopic treatment avoiding surgical procedure. In our case, enteric *Anisakiasis* had not been taken into consideration at the moment of the operation and only histopathology could reveal *Anisakis* larvae inside the intestinal wall.

**Conclusion.** Our surgical approach is considered in literature as the best one for this clinical presentation. Those patients need to be better studied and more attention should be paid to their history.

KEY WORDS: *Anisakis* - Meckel's diverticulum - Bowel obstruction.

## Introduction

*Anisakiasis* is a parasitic infection caused by the ingestion of raw fish contaminated by larval nematodes of *Anisakis* species and *Pseudoterranova decipiens* (1). This disease is frequently reported in Asian countries where eating raw seafood is a habit (2). *Anisakis* larvae can cause gastric, intestinal, extraintestinal or allergic manifestations (3). The number of gastric manifestations due to ingestion of *Anisakis* larvae are rated to > 95%, while intestinal or extraintestinal ones to > 4% and >1% respectively (4).

In human body larvae normally die within 14 days,

but they can penetrate the intestinal wall and can cause inflammation and consequently a granuloma (5). In fact intestinal *Anisakiasis* usually presents itself with abdominal pain, diarrhea, high levels of inflammation biomarkers and it can be complicated by intestinal obstruction, peritonitis and perforation (6).

Since larvae die in the course of time, a conservative treatment can be considered, while intestinal complications need to be treated with an emergency surgical procedure (7).

Sometimes, intestinal *Anisakiasis* is very difficult to recognize and surgery is necessary for its diagnosis.

## Case report

A 61-year old patient was admitted to our General Surgical and Emergency Unit because of sudden abdominal pain, vomit and constipation. He referred to have eaten raw fish 3 days before admission and denied

General Surgery Unit "V. Bonomo", Department of Emergency and Transplantation of Organs, Policlinico of Bari, Bari, Italy

Corresponding author: Giuseppe Carbotta, e-mail: pippocarbotta@gmail.com

© Copyright 2016, CIC Edizioni Internazionali, Roma

any previous surgical treatment. Abdominal examination revealed muscular rigidity, pain in the right abdominal quadrants with rebounding pain and positive Blumberg's sign. Digital rectal exam gave no evidence of stools and no bleeding. Laboratory data showed high levels of WBC (especially neutrophils and no eosinophils) and PCR. The patient underwent an abdominopelvic CT scanning that showed "dilation of jejunum and ileum loops, thickening of the terminal ileum and cecum and signs of inflammation of the intestinal wall and mesentery".

After a CT scan, the following emergency surgical procedure was performed: 1) laparotomy with evidence of purulent liquid in abdomen, a stenotic terminal ileum with obstruction of the small intestine bowels and a giant Meckel's diverticulum, 2) resection of terminal ileum and cecum and ileocolonic anastomosis L-L; 3) toilette and drainage. The patient started enteral feeding and antibiotics protocol and underwent blood exams that showed improved of WBC and PCR values. There were no post-operative complications. 8 days after surgery he was discharged. Then he started his post-operative and medical follow-up in the Infectious Diseases Unit which lasted for 6 months and after that he refused any further examination.

Gross examination showed ileal stenosis with thickening of the wall for the length of 18 cm. At the microscopic examination, the intestinal wall appeared occupied by a transmural inflammatory infiltrate, mainly eosinophilic, edema, angiectasias and nematode larvae, referable to *Anisakis*, surrounded by necrotic-inflammatory material (Figures 1 and 2). Moreover, there was evidence of giant a Meckel's diverticulum (at about 12 cm from the resection).

## Discussion

Owing to the very high consumption of raw fish *Anisakis* is very common among the population of the Eastern Countries where approximately 20,000 cases are reported (8). It commonly affects the gastric mucosa but rarely the intestinal one. Diagnosis of intestinal anisakiasis can therefore be challenging and the history of recent raw fish consumption can be helpful (9). US and CT scanning are very useful in the differential diagnosis. In fact, typical CT outcomes include a thickening of the intestinal wall, diffuse contrast enhancement of the involved intestinal tract and ascites (10). According to Ido (11), US scanning can show the presence of ascites, dilation of the small intestine and localized edema of Kerckring's folds. Unfortunately, in our case, US was not performed.

Normally, enteric anisakiasis exhibits leukocytosis with eosinophilia and high C-reactive protein levels

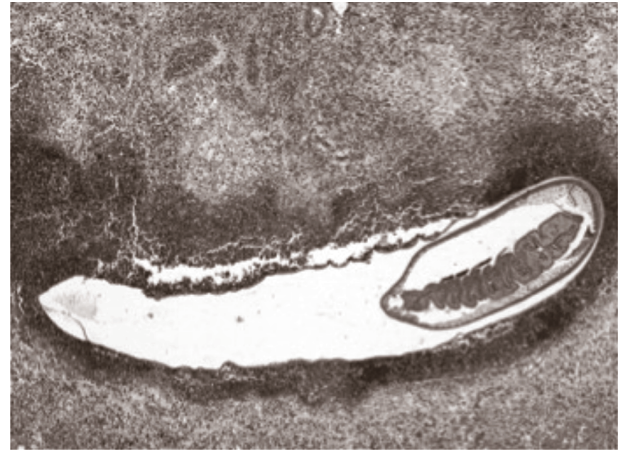


Fig. 1 - Larva of *Anisakis* received in the bowel wall thickness, surrounded by a necrotic-inflammatory, predominantly eosinophilic (40x, E&E)

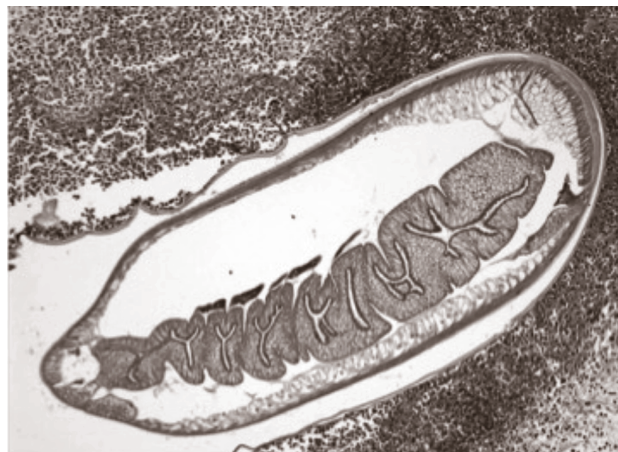

Fig. 2 - At higher magnification can observe the anatomical details of the parasite: a thin external cuticle overlying a muscle layer and intestine composed of a single layer of columnar epithelium forming a central tripartite lumen (100x, E&E)

(10). In literature, some studies report also the possibility of using *Anisakis*' antibodies to improve the differential diagnosis (11). Concerning treatment, there are cases of successful medical treatment with prednisolone and olopatadine hydrochloride avoiding hospitalization (7) and other cases of endoscopic treatment avoiding surgical procedure (12).

In our case, enteric *Anisakis* had not been taken into consideration at the moment of the operation because the presence of a bowels' obstruction diagnosed on CT scanning. After surgery a strong suspicion of obstruction caused by Meckel's diverticulum was considered and only histopathology could reveal *Anisakis* larvae inside the intestinal wall. Our laboratory cannot allow the research of *Anisakis*' Ab in a short time and it would have been ineffective in this case. Another

similar case has been reported in literature with this rare combination of anisakiasis and Meckel's diverticulum (13).

## Conclusions

Enteric anisakiasis is a rare disease and in some cases a conservative approach can be recommended (10), but it is important to focus on history and clinical presentation for differential diagnosis. Anyway in cases of bowel obstruction or perforation, surgical procedure needs to be performed.

In our case there was no suspicion of anisakiasis apart from the fact that the patient had reported that he had recently eaten raw fish. After laparotomy a Meckel's diverticulum was evident and it was considered as the primary cause of the bowels' obstruction as it

normally happens in the Surgery and Emergency Unit Department. In fact only the histological exam revealed the presence of anisakiasis larvae inside the intestinal submucosa.

With our experience we want to demonstrate that complicated anisakiasis is difficult to diagnose, especially without such positive laboratory data as eosinophilia. We always also recommend a CT scanning followed by an emergency surgical approach, in as much as it can be possible to find out a combination of a Meckel's diverticulum and Anisakis larvae.

---

## Consent section

Written informed consent was obtained from the patient for publication of this case report and accompanying images. A copy of the written consent is available for review by the Editor-in-Chief of this journal on request.

## References

1. Moore DA, Girdwood RW, Chiodini PL. Treatment of anisakiasis with albendazole. *Lancet*. 2002;360:54.
2. Hochberg NS, Hamer DH. Anisakidosis: perils of the deep. *Clin Infect Dis*. 2010;51:806-812.
3. Sweiki E, Rittenhouse DW, Joana OE, et al. Acute Small-Bowel Obstruction From Intestinal Anisakiasis After the Ingestion of Raw Clams; documenting a New Method of Marine-to-Human Parasitic Transmission. 2014, Brief Report, OFID 1-5.
4. Valle J, Lopera E, Sanchez M, et al. Spontaneous splenic rupture and Anisakis appendicitis presenting as abdominal pain: a case report. *J Med Case Rep*. 2012;6:114.
5. Audicana MT, Kennedy MW. Anisakis simplex: from obscure infectious worm to inducer of immune hypersensitivity. *Clin Microbiol Rev*. 2008;21:360-379.
6. Sasaki T, Fukumori D, Matsumoto H, Ohmori H, Yamamoto F. Small bowel obstruction caused by anisakiasis of the small intestine: report of a case. *Surg Today*. 2003;33:123-125.
7. Toyoda H, Tanaka K. Intestinal Anisakiasis treated successfully with prednisolone and olopatadine hydrochloride. *Case Reports in Gastroenterology*. 2016;10:30-35.
8. Pravettoni V, Primavesi L, Piantanida M. Anisakis simplex: current knowledge. *European Annals of Allergy and Clinical Immunology*. 2012;44:150-156.
9. Caramello P, Vitali A, Canta F, et al. Intestinal localization of anisakiasis manifested as acute abdomen. *Clinical Microbiology and Infection*. 2003;9(7):734-737.
10. Takano Y, Gomi K, et al. Small intestinal obstruction caused by Anisakis. *Case Reports in Infectious Diseases*. 2013.
11. Ido K, Yuasa H, Ide M, Kimura K, Toshimitsu K, Suzuki T. Sonographic diagnosis of small intestinal anisakiasis. *Journal of Clinical Ultrasound*. 1998;26:125-130.
12. Yorimitsu N, Hiraoka A, et al. Colonic Intussusception Caused by Anisakis: A Case Report and Review of the Literature. *Intern Med*. 2013;52:223-226.
13. Furukawa K, Yoshida K, et al. Adult intussusception caused by Meckel's diverticulum complicated by anisakiasis of the small intestine: report of a case. *Clin J Gastroenterol*. 2014 Aug;7(4):316-9.