

# Sepsis due to *Streptococcus pneumoniae* associated with secondary hemophagocytic lymphohistiocytosis in a splenectomized patient for spherocytosis

## A case report

Victoria Birlutiu, MD, PhD<sup>a,b</sup>, Rares Mircea Birlutiu, MD, PhD Student<sup>a,c,\*</sup>

### Abstract

**Rationale:** Hemophagocytic lymphohistiocytosis (HLH) is a syndrome that is characterized by an inappropriate hyperinflammatory immune response – primary, as a consequence of a genetic defect of NK cells and cytotoxic T lymphocytes or – secondary, in the progression of infections, rheumatic or autoimmune diseases, malignancies or metabolic diseases.

**Patient concerns:** We present the case of a secondary HLH due to *Streptococcus pneumoniae* infection in a splenectomized patient for spherocytosis, a 37-year-old patient who was splenectomized in childhood for spherocytosis, without immunoprophylaxis induced by antipneumococcal vaccine.

**Outcomes:** He developed a severe pneumococcal sepsis associated with secondary HLH, with unfavorable outcome and death.

**Lessons:** To our knowledge, just 2 similar cases had been published in the literature, none in which the secondary HLH was the consequence of an invasive pneumococcal infection in a splenectomized patient for spherocytosis, and the association of splenectomy with HLH is surprizing.

**Abbreviation:** HLH = hemophagocytic lymphohistiocytosis.

**Keywords:** hemophagocytic lymphohistiocytosis, HLH, splenectomized patient, *Streptococcus pneumoniae*

## 1. Introduction

Hemophagocytic lymphohistiocytosis (HLH) is a syndrome that is characterized by an inappropriate hyper-inflammatory immune response – primary, as a consequence of a genetic defect of NK cells and cytotoxic T lymphocytes or – secondary, in the progression of infections, rheumatic or autoimmune diseases, malignancies or metabolic diseases. Among HLH-related infections, the most common are the viral infections: Epstein–Barr virus, cytomegalovirus, other herpes viruses, the viruses of

hepatitis B and C, etc., followed by bacterial, parasitic, or fungal infections. Association of secondary HLH to *Streptococcus pneumoniae* infection in a patient splenectomized for spherocytosis has not been described so far.

## 2. Case report

We present the case of a male Caucasian patient, aged 37 years, splenectomized for spherocytosis since the age of 4, with no prophylaxis of meningococcal, and pneumococcal infections through vaccination, that was brought to the emergency room for fever, diarrhea, vomiting, rash skin, myalgia, anuria, and marked alteration of his general condition. At the time of admission, on physical examination, the following changes were noticed: facial erythema, purpura on the legs (see Fig. 1), cyanosis of the extremities, jaundice, left basilar crackles, heart rate of 130 beats per minute, blood pressure of 140/100 mmHg, hepatomegaly, and anuria. The laboratory investigations that were performed revealed the following alterations (at admission and in evolution) that are presented in Table 1.

Peripheral smear revealed normochromic normocytic red blood cells, as well as microspherocytes and spherocytes, frequent polychromatophilic macrocytes; erythrocytes with Howell–Jolly bodies (splenectomy), rare dacryocytes (teardrop cells), and schistocytes. Polymorphonuclears with vacuolated cytoplasm are present (toxic appearance), diplo-, encapsulated, and intra- and extracellular gram-positive cocci. Bone marrow sample was harvest and on hematoxylin-eosin stain an increased number of activated macrophages with prominent hemophagocytosis of hematopoietic elements was revealed. Blood cultures

Editor: Victor Asensi.

Authorship: VB and RMB contributed equally to this manuscript in terms of acquisition, analysis and interpretation of data, conception and design, and drafting the manuscript. Both the authors read and approved the final manuscript.

The authors have no funding and conflicts of interest to disclose.

<sup>a</sup> Faculty of Medicine Sibiu, Lucian Blaga University of Sibiu, <sup>b</sup> Academic Emergency Hospital Sibiu, Infectious Diseases Clinic, Sibiu, <sup>c</sup> Spitalul Clinic de Ortopedie-Traumatologie si TBC Osteoarticular "Foisor" Bucuresti, Romania.

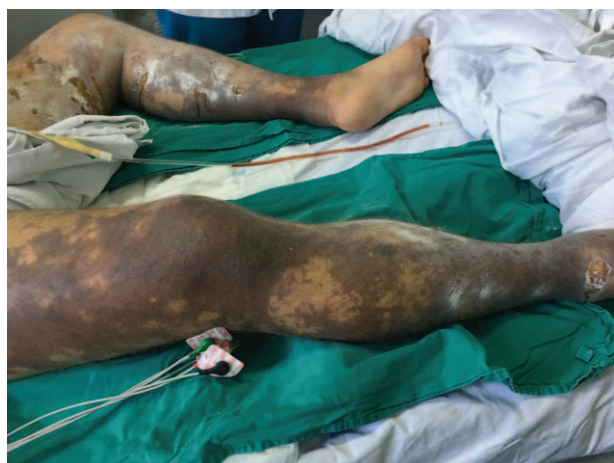\* Correspondence: Rares Mircea Birlutiu, Spitalul Clinic de Ortopedie-Traumatologie si TBC Osteoarticular "Foisor" Bucuresti, Faculty of Medicine Sibiu, Lucian Blaga University of Sibiu, Str. Lucian Blaga, Nr. 2A, Sibiu 550169, Romania (e-mail: raresmircea@gmail.com).

Copyright © 2017 the Author(s). Published by Wolters Kluwer Health, Inc. This is an open access article distributed under the Creative Commons Attribution License 4.0 (CCBY), which permits unrestricted use, distribution, and reproduction in any medium, provided the original work is properly cited.

Medicine (2017) 96:28(e7520)

Received: 16 January 2017 / Received in final form: 24 June 2017 / Accepted: 26 June 2017

<http://dx.doi.org/10.1097/MD.0000000000007520>



**Figure 1.** Picture from the emergency room that presents the purpura on the legs and skin lesions.

and urine cultures were positive for *S pneumoniae*, resistant to benzylpenicillin, chloramphenicol, erythromycin, trimethoprim/sulfamethoxazole, tetracycline, cefotaxime, and intermediate resistance to ceftriaxone, imipenem, sensitive to ofloxacin, vancomycin, moxifloxacin, quinupristin/dalfopristin, levofloxacin, linezolid, rifampicin, sparfloxacin, pristinamycin, amoxicillin, and telithromycin. Viral, parasitic etiologies were excluded,

as well as rheumatic diseases, malignant tumors, which may be involved in secondary HLH.

A cardiac ultrasound was performed and revealed no suggestive images of infectious endocarditis or valvular heart disease. Initially, the chest radiography revealed no changes, but in evolution, it showed bilateral alveolar condensation and left pleural effusion.

The case was interpreted as sepsis due to a multidrug-resistant *S pneumoniae* associated with consumption coagulopathy (bleeding at venepuncture site and epistaxis), acute liver failure, acute renal failure by myoglobinuria, and HLH. In evolution, acute respiratory failure occurred, for which endotracheal intubation of the patient was performed.

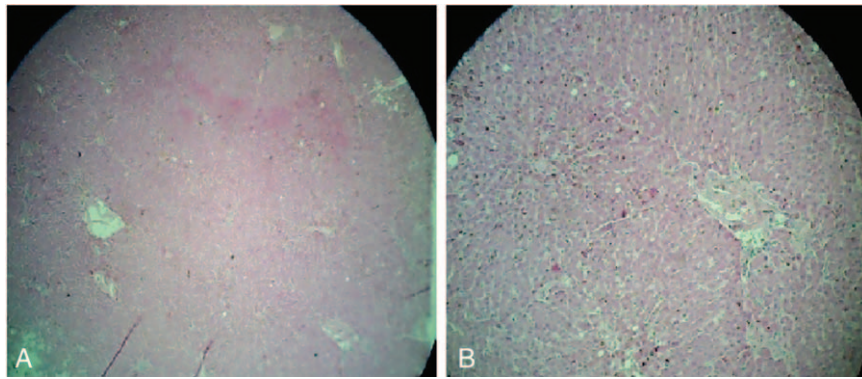
The treatment was started with infusions of macromolecular solutions, hydro-electrolytic rebalancing, packed red blood cells, fresh frozen plasma, and antibiotics – initially, with ultrabroad-spectrum antibiotics, meropenem 2g/day associated with linezolid 2 × 600 mg/day, thereafter treatment continued with linezolid associated with moxifloxacin 400 mg/day according to antibiogram results, dexamethasone, etoposides 150 mg/m<sup>2</sup>/day, 3 days, anidulafungin, intravenous immunoglobulin, and daily hemodialysis sessions throughout hospitalization. The evolution was unfavorable with coma, Glasgow Coma Scale of 3, and quadriplegia, the occurrence of bronchopneumonia required endotracheal intubation. During hospitalization, the patient was anuric. Patient death occurred on day 15 of hospitalization. Hematoxylin-eosin and immunohistochemically stainings of liver

**Table 1**

**Laboratory studies.**

Parameter	Values				References value
	Day 1	Day 2	Day 7	Day 15	
WBC	38.7 × 10 <sup>3</sup> /μL	50.4 × 10 <sup>3</sup> /μL	36.47 × 10 <sup>3</sup> /μL	38.5 × 10 <sup>3</sup> /μL	4–10 × 10 <sup>3</sup> /μL
Differential blood count	Myelocytes 1%	Myelocytes 1%			
	Metamyelocytes 4%	Metamyelocytes 2%			
	Nonsegmented neutrophils 23%	Nonsegmented neutrophils 28%			
	Segmented neutrophils 58%	Segmented neutrophils 63%	Segmented neutrophils 84.2%	NA	1%–4%
	Eosinophils 1%	Eosinophils 1%	Eosinophils 0%		45%–70%
	Lymphocytes 13%	Lymphocytes 5%	Lymphocytes 13.3%		1%–4%
	Monocytes 1%	Monocytes 1%	Monocytes 2.3%		25%–35%
Erythroblasts 1%	Erythroblasts 2%	Basophils 0.2%		4%–8%	
Hemoglobin	12.8 g/dL	10.8 g/dL	8.5 g/dL	NA	13–17 g/dL
Thrombocytes	56 × 10 <sup>3</sup> /μL	76 × 10 <sup>3</sup> /μL	48 × 10 <sup>3</sup> /μL	28 × 10 <sup>3</sup> /μL	150–400 × 10 <sup>3</sup> /μL
AST	1419 U/L	1922 U/L	982 U/L	159 U/L	10–40 U/L
ALT	605 U/L	584 U/L	253 U/L	77 U/L	10–41 U/L
Total bilirubin	NA	7.39 mg/dL	2.25 mg/dL	NA	0.2–1.2 mg/dL
Direct bilirubin	NA	4.45 mg/dL	2.00 mg/dL	NA	0–0.3 mg/dL
LDH	2312 U/L	5488 U/L	5684 U/L	3806 U/L	136–145 U/L
CPK	2303 U/L	4072 U/L	16,417 U/L	15,731 U/L	39–308 U/L
Fibrinogen	107.8 mg/dL	71.1 mg/dL	86.9 mg/dL	85.2 mg/dL	180–380 mg/dL
Fibrin monomers	Neg	++	+	Neg	Absent
Ferritin	NA	>1500 ng/mL	NA	>1500 ng/mL	28–397 ng/mL
Glycemia	35 mg/dL	98 mg/dL	150 mg/dL	380 mg/dL	74–106 mg/dL
BUN	99 mg/dL	131 mg/dL	309 mg/dL	433 mg/dL	16.6–48.5 mg/dL
Creatinine	5.58 mg/dL	6.66 mg/dL	9.65 mg/dL	10.25 mg/dL	0.7–1.2 mg/dL
Cholesterol	NA	117 mg/dL	102 mg/dL	NA	109–202 mg/dL
Triglycerides	NA	267 mg/dL	289 mg/dL	NA	50–160 mg/dL
Total proteins	4.9 g/dL	6.3 g/dL	4.9 g/dL	NA	6.4–8.3 g/dL
PT	31 sec	27 sec	19.4 sec	14.3 sec	9.8–12.2 sec
INR	2.57	2.04	NA	2.39	0.86–1.1
APTT	100.2 sec	157 sec	78 sec	216 sec	24–36

ALT = alanine aminotransferase, APTT = activated partial thromboplastin time, AST = aspartate aminotransferase, BUN = blood urea nitrogen, CPK = creatine phosphokinase, INR = international normalized ratio, LDH = lactate dehydrogenase, NA = not available, PT = prothrombin time, WBC = white blood cell.



**Figure 2.** Hematoxylin and eosin-stained sections of liver. Magnifications:  $\times 40$  (A) and  $\times 100$  (B).

biopsies taken during the anatomopathological examination revealed the following changes: massive infiltration of portal tract and sinusoids by mononuclear cells. The CD68 stain shows numerous large, irregularly shaped CD68+ cells as being macrophages, cells that are localized both in the portal tract and sinusoids, and with an increased phagocytic activity on lymphocytes, erythrocytes, and polynuclear cells. On CD8 stain, numerous CD8+ lymphocytes were revealed. The conclusion was: the described aspect is in concordance with the diagnosis of hemophagocytic lymphohistiocytosis. Autopsy examination also revealed bilateral renal papillae necrosis secondary to myoglobinuria, and the presence of hemophagocytosis in bone marrow, and lymph nodes Figs. 2–4.

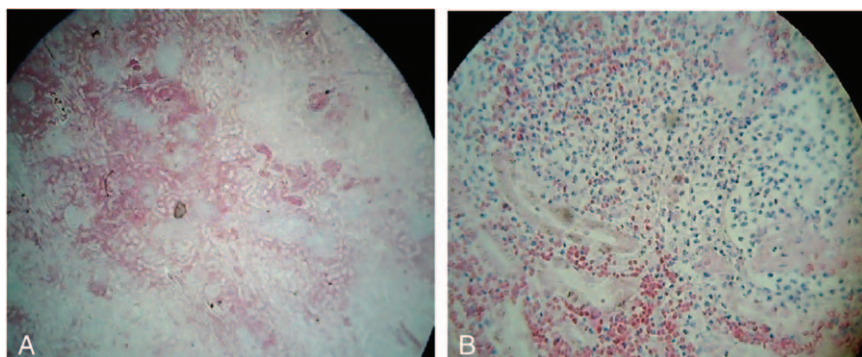
### 3. Discussions

This case brings into question the risk of splenectomised patients to develop severe systemic infections with encapsulated bacteria, against which the vaccine prophylaxis is essential – for *S pneumoniae*, *H influenzae*, and *Meningococcus*. Lack of vaccination in this patient has enabled the development of severe infections with multidrug-resistant *S pneumoniae* and the induction of secondary HLH, characterized by an uncontrolled inflammatory response, resulting in patient's death.

Primary HLH has a family, autosomal recessive transmission, and is present in 50,000 new-borns annually. Secondary HLH may be induced by viral (29%), bacterial, or parasitic infections (20%), autoimmune or rheumatic diseases (7%), cancers (27%), and metabolic diseases or immunodeficiency syndromes (6%).<sup>[11]</sup>

Among viral causes, the most common is associated with Epstein–Barr virus. There are also described associations with cytomegalovirus, herpes simplex,<sup>[2,3]</sup> varicella-zoster virus,<sup>[4]</sup> herpes virus 8, and associated with HIV infection.<sup>[5]</sup> There were also published associations with hepatitis B and C viruses,<sup>[6,7]</sup> influenza viruses,<sup>[8]</sup> enteroviruses,<sup>[9]</sup> rotavirus, severe acute respiratory syndrome virus,<sup>[10]</sup> hemorrhagic fevers,<sup>[11–15]</sup> HIV,<sup>[15–18]</sup> and so on. Among bacterial infections associated with HLH, there were published associations with *Borrelia*,<sup>[19]</sup> *Babesia* sp,<sup>[20]</sup> *Bartonella* sp,<sup>[21]</sup> *Brucella* sp,<sup>[22]</sup> Q fever,<sup>[23]</sup> *Leptospira* sp,<sup>[24]</sup> *Listeria monocytogenes*,<sup>[25]</sup> *Mycoplasma pneumoniae*,<sup>[26]</sup> and mycobacteria.<sup>[27–32]</sup> The most frequently described parasitic causes responsible for secondary HLH are: *Leishmania* sp,<sup>[33,34]</sup> malaria,<sup>[35–37]</sup> and *Toxoplasma gondii*.<sup>[38,39]</sup> Fungal infections are found to be associated with secondary HLH in HIV-infected patients such as *Cryptococcus neoformans*,<sup>[40]</sup> *Candida* spp,<sup>[41]</sup> or in patients with renal transplantation-association with disseminated histoplasmosis.<sup>[42]</sup>

Of the defining HLH criteria established by the Histiocyte Society, respectively, fever, splenomegaly, cytopenia (on at least 2 lines in peripheral blood), hypofibrinemia, hyperferritinemia, hypertriglyceridemia, presence of hemophagocytosis in bone marrow or lymph node, reduction/absence of NK cells activity, and increase in the concentration of soluble IL-2 receptor, CD25,<sup>[43]</sup> the patient had 5 defining criteria for HLH. The presence of consumption coagulopathy evidenced by the presence of fibrin degradation products is associated with hypofibrinemia and thrombocytopenia in HLH, as well as the liver damage-elevated transaminases, hyperbilirubinemia, activated partial thromboplastin time prolongation. These changes are also



**Figure 3.** Hematoxylin and eosin-stained sections of kidney. Magnifications:  $\times 40$  (A) and  $\times 100$  (B).



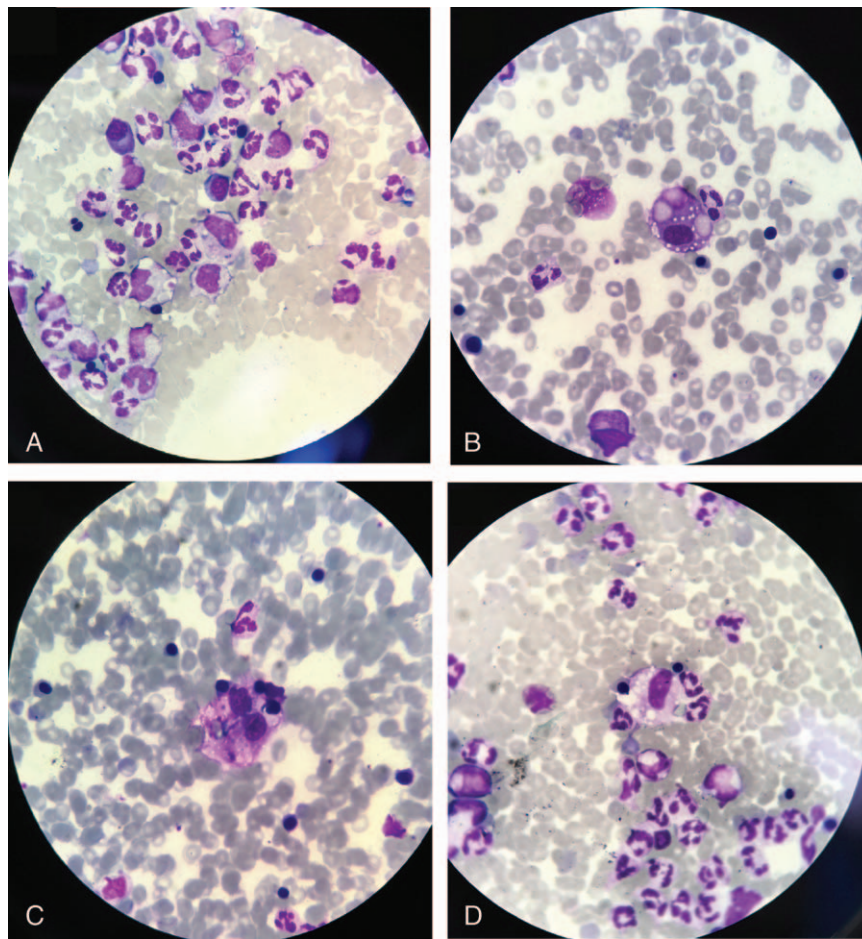


Figure 4. May-Grünwald Giemsa-stained sections of bone marrow. Magnifications:  $\times 100$  (A–D).

**Table 2**

**Clinical and biological characteristics of the 3 cases with HLH due to *S pneumoniae*.**

#	1	2	3
Author	Our case	Dalle et al <sup>[45]</sup> 1995	Ondruschka et al <sup>[46]</sup> 2016
Sex	M	M	M
Age, y	37	8	25
BMI/general and nutritional condition	22.4 kg/m <sup>2</sup>	NA	12.9 kg/m <sup>2</sup> Extremely poor general and nutritional condition
Fever	Yes	Yes	Yes
Organomegaly (liver, spleen)	Yes	Yes	Yes
Hemoglobin <9 g/dL	Yes	NA	No
Platelets <100,000/ $\mu$ L	Yes	NA	Yes
Neutrophils <1000/ $\mu$ L	No	Yes	Yes
Hypertriglyceridemia $\geq 265$ mg/dL	Yes	Yes	Yes
Ferritin $\geq 500$ ng/mL	Yes	NA	NA
Hemophagocytosis, any involved organ	Yes	Yes	Yes
Natural killer cell activity, low or absent	NA	NA	NA
Soluble IL-2 receptor $\geq 2400$ U/mL	NA	NA	NA
C reactive protein, normal range <5 mg/L	117.74	NA	74.6 mg/L
HIV	Negative	Yes	Negative
Epstein-Barr nuclear antigen 1 antibody serology	Negative	NA	Positive
Epstein-Barr virus viral capsid antigen	Negative	NA	Negative
Cytomegalovirus IgG antibody	Negative	Negative	Negative
Herpes simplex virus 1/2 IgG antibody	Negative	Negative	Negative
Site of infection	Sepsis	Ears	Lungs
<i>S pneumoniae</i>	Multiresistant	Multiresistant	Multiresistant
Outcome	Death	Rapid improve of his condition with adapted antibiotherapy	Death

BMI = body mass index, HIV = human immunodeficiency virus, HLH = hemophagocytic lymphohistiocytosis, IgG = immunoglobulin G, M = male, NA = not available.

present within the septic context, their strict delimitation is not possible.

Although the diagnosis of HLH was early, the administration of dexamethasone, intravenous immunotherapy, and administration of etoposides have not improved prognosis, the patient's death occurring on the 15th day of hospitalization. Renal insufficiency due to bilateral renal papillary necrosis has been associated with myoglobinuria as a result of septic myositis, demonstrated by high levels of creatine phosphokinase. There have been described situations in which *S pneumoniae* infections are responsible for the death of patients with primary HLH.<sup>[44]</sup> Two cases of HLH associated with a pneumococcal infection had been published (see Table 2). HLH association with hereditary spherocytosis is found in association with viral infections, such as parvovirus B19<sup>[47]</sup> or Epstein-Barr virus. Moreover, splenectomy is described as a therapeutic method in refractory HLH cases.<sup>[48–50]</sup>

### 3.1. Informed consent

Written informed consent was obtained from the patient's next of kin (from his father) for publication of this case report and any accompanying images. The study was accepted by the Ethics Committee of the hospital and they encouraged publishing the article. A copy of the written consent is available for review by the Editor-in-Chief of this journal.

## 4. Conclusion

The association of sepsis due to *S pneumoniae* with secondary HLH in a splenectomized patient for spherocytosis should be taken into consideration in similar cases like ours. To our knowledge, no similar cases had been published in the literature, in which the secondary HLH was the consequence of an invasive pneumococcal infection in a splenectomized patient for spherocytosis, and the association of splenectomy with HLH is surprising. Other similar observations are necessary in the future.

## Acknowledgments

The authors thank the medical staff from the Hematology and Infectious Disease Department of the Academic Emergency Hospital from Sibiu, and to Dr Ioan Sorin Zaharie for his contribution to the anatomopathological examination.

## References

- [1] Dhote R, Simon J, Papo T, et al. Reactive hemophagocytic syndrome in adult systemic disease: report of twenty-six cases and literature review. *Arthritis Rheum* 2003;49:633–9.
- [2] Wada Y, Kai M, Tanaka H, et al. Computed tomography findings of the liver in a neonate with Herpes simplex virus-associated hemophagocytic lymphohistiocytosis. *Pediatr Int* 2011;53:773–6.
- [3] Yamaguchi K, Yamamoto A, Hisano M, et al. Herpes simplex virus 2-associated hemophagocytic lymphohistiocytosis in a pregnant patient. *Obstet Gynecol* 2005;105(5 Pt 2):1241–4.
- [4] van der Werff ten Bosch JE, Kollen WJ, Ball LM, et al. Atypical varicella zoster infection associated with hemophagocytic lymphohistiocytosis. *Pediatr Blood Cancer* 2009;53:226–8.
- [5] Fardet L, Blum L, Kerob D, et al. Human herpesvirus 8-associated hemophagocytic lymphohistiocytosis in human immunodeficiency virus-infected patients. *Clin Infect Dis* 2003;37:285–91.
- [6] Faurouchou M, Nielsen OJ, Hansen PB, et al. Fatal virus-associated hemophagocytic syndrome associated with coexistent chronic active hepatitis B and acute hepatitis C virus infection. *Am J Hematol* 1999;61:135–8.
- [7] Wu CS, Chang KY, Dunn P, et al. Acute hepatitis A with coexistent hepatitis C virus infection presenting as a virus-associated hemophagocytic syndrome: a case report. *Am J Gastroenterol* 1995;90:1002–5.
- [8] Zheng Y, Yang Y, Zhao W, et al. Novel swine-origin influenza A (H1N1) virus-associated hemophagocytic syndrome – a first case report. *Am J Trop Med Hyg* 2010;82:743–5.
- [9] Lindamood KE, Fleck P, Narla A, et al. Neonatal enteroviral sepsis/meningoencephalitis and hemophagocytic lymphohistiocytosis: diagnostic challenges. *Am J Perinatol* 2011;28:337–46.
- [10] Nicholls JM, Poon LL, Lee KC, et al. Lung pathology of fatal severe acute respiratory syndrome. *Lancet* 2003;361:1773–8.
- [11] Jain D, Singh T. Dengue virus related hemophagocytosis: a rare case report. *Hematology* 2008;13:286–8.
- [12] Erduran E, Cakir M. Reactive hemophagocytic lymphohistiocytosis and Crimean-Congo hemorrhagic fever. *Int J Infect Dis* 2010;14(Suppl 3):e349author reply e350.
- [13] Barut S, Dincer F, Sahin I, et al. Increased serum ferritin levels in patients with Crimean-Congo hemorrhagic fever: can it be a new severity criterion? *Int J Infect Dis* 2010;14:e50–4.
- [14] Tasdelen Fisgin N, Fisgin T, Tanyel E, et al. Crimean-Congo hemorrhagic fever: five patients with hemophagocytic syndrome. *Am J Hematol* 2008;83:73–6.
- [15] Cascio A, Todaro G, Bonina L, et al. Please, do not forget secondary hemophagocytic lymphohistiocytosis in HIV-infected patients. *Int J Infect Dis* 2011;15:e885–6.
- [16] Chen TL, Wong WW, Chiou TJ. Hemophagocytic syndrome: an unusual manifestation of acute human immunodeficiency virus infection. *Int J Hematol* 2003;78:450–2.
- [17] Wong CK, Wong BC, Chan KC, et al. Cytokine profile in fatal human immunodeficiency virus tuberculosis Epstein-Barr virus associated hemophagocytic syndrome. *Arch Intern Med* 2007;167:1901–3.
- [18] Sun HY, Chen MY, Fang CT, et al. Hemophagocytic lymphohistiocytosis: an unusual initial presentation of acute HIV infection. *J Acquir Immune Defic Syndr* 2004;37:1539–40.
- [19] Cantero-Hinojosa J, Diez-Ruiz A, Santos-Perez JL, et al. Lyme disease associated with hemophagocytic syndrome. *Clin Investig* 1993;71:620.
- [20] Gupta P, Hurley RW, Helseth PH, et al. Pancytopenia due to hemophagocytic syndrome as the presenting manifestation of babesiosis. *Am J Hematol* 1995;50:60–2.
- [21] Karras A, Thervet E, Legendre C. Hemophagocytic syndrome in renal transplant recipients: report of 17 cases and review of literature. *Transplantation* 2004;77:238–43.
- [22] Karakukcu M, Patiroglu T, Ozdemir MA, et al. Pancytopenia, a rare hematologic manifestation of brucellosis in children. *J Pediatr Hematol Oncol* 2004;26:803–6.
- [23] Harris P, Dixit R, Norton R. *Coxiella burnetii* causing haemophagocytic syndrome: a rare complication of an unusual pathogen. *Infection* 2011;39:579–82.
- [24] Niller HH. Myelodysplastic syndrome (MDS) as a late stage of sub-clinical hemophagocytic lymphohistiocytosis (HLH): a putative role for *Leptospira* infection. A hypothesis. *Acta Microbiol Immunol Hung* 2010;57:181–9.
- [25] Lambotte O, Fihman V, Poyart C, et al. *Listeria monocytogenes* skin infection with cerebritis and haemophagocytosis syndrome in a bone marrow transplant recipient. *J Infect* 2005;50:356–8.
- [26] Ishida Y, Hiroi K, Tauchi H, et al. Hemophagocytic lymphohistiocytosis secondary to *Mycoplasma pneumoniae* infection. *Pediatr Int* 2004;46:174–7.
- [27] Yang WK, Fu LS, Lan JL, et al. *Mycobacterium avium* complex-associated hemophagocytic syndrome in systemic lupus erythematosus patient: report of one case. *Lupus* 2003;12:312–6.
- [28] Wali Y, Beshlawi I. BCG lymphadenitis in neonates with familial hemophagocytic lymphohistiocytosis. *Pediatr Infect Dis J* 2012;31:324.
- [29] González MJ, Franco AG, Alvaro CG. Hemophagocytic lymphohistiocytosis secondary to Calmette-Guèrin bacilli infection. *Eur J Intern Med* 2008;19:150.
- [30] Maheshwari P, Chhabra R, Yadav P. Perinatal tuberculosis associated hemophagocytic lymphohistiocytosis. *Indian J Pediatr* 2012;79:1228–9.
- [31] Su NW, Chen CK, Chen GS, et al. A case of tuberculosis-induced hemophagocytic lymphohistiocytosis in a patient under hemodialysis. *Int J Hematol* 2009;89:298–301.
- [32] Brastianos PK, Swanson JW, Torbenson M, et al. Tuberculosis-associated haemophagocytic syndrome. *Lancet Infect Dis* 2006;6:447–54.
- [33] Martin A, Marques L, Soler-Palacin P, et al. Visceral leishmaniasis associated hemophagocytic syndrome in patients with chronic granulomatous disease. *Pediatr Infect Dis J* 2009;28:753–4.
- [34] Koubaa M, Maaloul I, Marrakchi C, et al. Hemophagocytic syndrome associated with visceral leishmaniasis in an immunocompetent adult-case report and review of the literature. *Ann Hematol* 2012;91:1143–5.

- [35] Sung PS, Kim IH, Lee JH, et al. Hemophagocytic lymphohistiocytosis (HLH) associated with plasmodium vivax infection: case report and review of the literature. *Chonnam Med J* 2011;47:173–6.
- [36] Saribeyoglu ET, Anak S, Agaoglu L, et al. Secondary hemophagocytic lymphohistiocytosis induced by malaria infection in a child with Langerhans cell histiocytosis. *Pediatr Hematol Oncol* 2004;21:267–72.
- [37] Bae E, Jang S, Park CJ, et al. Plasmodium vivax malaria-associated hemophagocytic lymphohistiocytosis in a young man with pancytopenia and fever. *Ann Hematol* 2011;90:491–2.
- [38] Segall L, Moal MC, Doucet L, et al. Toxoplasmosis-associated hemophagocytic syndrome in renal transplantation. *Transpl Int* 2006; 19:78–80.
- [39] Duband S, Cornillon J, Tavernier E, et al. Toxoplasmosis with hemophagocytic syndrome after bone marrow transplantation: diagnosis at autopsy. *Transpl Infect Dis* 2008;10:372–4.
- [40] Numata K, Tsutsumi H, Wakai S, et al. A child case of haemophagocytic syndrome associated with cryptococcal meningoencephalitis. *J Infect* 1998;36:118–9.
- [41] Bhatia S, Bauer F, Bilgrami SA. Candidiasis-associated hemophagocytic lymphohistiocytosis in a patient infected with human immunodeficiency virus. *Clin Infect Dis* 2003;37:e161–6.
- [42] Lo MM, Mo JQ, Dixon BP, et al. Disseminated histoplasmosis associated with hemophagocytic lymphohistiocytosis in kidney transplant recipients. *Am J Transplant* 2010;10:687–91.
- [43] Henter JI, Horne A, Arico M, et al. HLH-2004: diagnostic and therapeutic guidelines for hemophagocytic lymphohistiocytosis. *Pediatr Blood Cancer* 2007;48:124–31.
- [44] Sung L, Weitzman SS, Petric M, et al. The role of infections in primary hemophagocytic lymphohistiocytosis: a case series and review of the literature. *Clin Infect Dis* 2001;33:1644–8.
- [45] Dale JH, Dofflus C, Leverger G, et al. Hemophagocytic syndrome in children infected by HIV. A propos of 3 cases. *Arch Pediatr* 1995; 2:442–4.
- [46] Ondruschka B, Habeck JO, Hädrich C, et al. Rare cause of natural death in forensic setting: hemophagocytic syndrome. *Int J Legal Med* 2016; 130:777–81.
- [47] Cheong CS, Gan GG, Chen TM, et al. Parvovirus B19 associated haemophagocytic lymphohistiocytosis in hereditary spherocytosis patient: a case report. *JUMMEC* 2016;19:7–11.
- [48] Zhang LJ, Zhang SJ, Xu J, et al. Splenectomy for an adult patient with refractory secondary hemophagocytic lymphohistiocytosis. *Biomed Pharmacother* 2011;65:432–5.
- [49] Maciej , Machaczka . Splenectomy as a therapeutic approach in refractory hemophagocytic lymphohistiocytosis. *Biomed Pharmacother* 2012;66:159–60.
- [50] Jing-Shi W, Yi-Ni W, Lin W, et al. Splenectomy as a treatment for adults with relapsed hemophagocytic lymphohistiocytosis of unknown cause. *Ann Hematol* 2015;94:753–60.