



REVIEW

Diagnostic approach to pleural diseases: new tricks for an old trade [version 1; referees: 2 approved]

Fabien Maldonado, Robert J. Lentz, Richard W. Light

Division of Allergy, Pulmonary and Critical Care Medicine, Vanderbilt University School of Medicine, 1161 21st Avenue South, T-1218 Medical Center North, Nashville, TN, 37232, USA

v1 **First published:** 17 Jul 2017, 6(F1000 Faculty Rev):1135 (doi: [10.12688/f1000research.11646.1](https://doi.org/10.12688/f1000research.11646.1))
Latest published: 17 Jul 2017, 6(F1000 Faculty Rev):1135 (doi: [10.12688/f1000research.11646.1](https://doi.org/10.12688/f1000research.11646.1))

Abstract

The burden of pleural diseases has substantially increased in the past decade because of a rise in the incidence of pleural space infections and pleural malignancies in a patient population that is older and more immunocompromised and has more comorbidities. This complexity increasingly requires minimally invasive diagnostic options and tailored management. Implications for patients are such that the limitations of current diagnostic methods need to be addressed by multidisciplinary teams of investigators from the fields of imaging, biology, and engineering. Ignored for a long time as an epiphenomenon at the crossroad of many unrelated medical problems, pleural diseases are finally getting the attention they deserve and have spurred a vibrant and exciting field of research.

Open Peer Review

Referee Status:

	Invited Referees	
	1	2
version 1 published 17 Jul 2017		

F1000 Faculty Reviews are commissioned from members of the prestigious F1000 Faculty. In order to make these reviews as comprehensive and accessible as possible, peer review takes place before publication; the referees are listed below, but their reports are not formally published.

- 1 **Liju Ahmed**, Guy's and St Thomas' NHS Foundation Trust, UK
- 2 **Nick Maskell**, University of Bristol, UK

Discuss this article

Comments (0)

Corresponding author: Fabien Maldonado (fabien.maldonado@vanderbilt.edu)

Competing interests: Robert J. Lentz and Richard W. Light declare that they have no competing interests.

How to cite this article: Maldonado F, Lentz RJ and Light RW. **Diagnostic approach to pleural diseases: new tricks for an old trade [version 1; referees: 2 approved]** *F1000Research* 2017, 6(F1000 Faculty Rev):1135 (doi: [10.12688/f1000research.11646.1](https://doi.org/10.12688/f1000research.11646.1))

Copyright: © 2017 Maldonado F *et al.* This is an open access article distributed under the terms of the [Creative Commons Attribution Licence](https://creativecommons.org/licenses/by/4.0/), which permits unrestricted use, distribution, and reproduction in any medium, provided the original work is properly cited.

Grant information: Fabien Maldonado received an unrestricted educational grant from Centurion, Inc.

First published: 17 Jul 2017, 6(F1000 Faculty Rev):1135 (doi: [10.12688/f1000research.11646.1](https://doi.org/10.12688/f1000research.11646.1))

Introduction

The term pleura refers to the membrane separating the lungs from the chest wall, which is constituted by two leaflets attached to the outer surface of the lung (visceral pleura) and the inside of the chest wall (parietal pleura), joining at the hilum of the lungs, hence forming a genuine sac surrounding both lungs. The small amount of pleural fluid separating visceral from parietal pleural membranes serves as a lubricant, optimizing respiratory mechanics by facilitating synchronous chest wall and lung movements during respiratory efforts¹. Interestingly, surgical removal of the pleura, or chemical fusion of the visceral and parietal membranes for therapeutic purposes (pleurodesis), seems to have little physiologic effect on lung function or work of breathing in long-term human studies and this raises the question of why such a complex structure was selected for in the first place²⁻⁵.

Notwithstanding this lack of clear physiologic function, pleural disorders represent one of the most common reasons for consultation of lung specialists, and an estimated 1.5 million new pleural effusions identified every year in the US alone are caused by more than 60 distinct disease processes⁶. Approximately 150,000 of these effusions are caused by malignancy—lung and breast cancer are by far the most common offenders—generally due to parietal pleural involvement in advanced disease⁷. Other common causes of pleural effusions include congestive heart failure, pleural space infections, pulmonary embolism, and manifestations of connective tissue diseases such as lupus or rheumatoid arthritis. It should be intuitively obvious, given the profound implications of such diagnoses for patients, that timely and accurate diagnosis of unexplained pleural effusions is of considerable importance. Pleural fluid aspiration followed by application of the time-honored Light's criteria remains a remarkably useful step in the diagnostic algorithm of pleural effusions, although an expanding panel of diagnostic tools in the past decade has slowly transformed our approach to pleural diseases, the increasing complexity of which has motivated the development of multidisciplinary pleural subspecialty programs at many institutions in recent years⁸⁻¹². In this brief report, we will attempt to summarize what we believe are the most significant and promising recent advances in the diagnosis of pleural diseases and highlight current research efforts in the field.

1. Diagnosis of pleural diseases: non-invasive studies

a. The ultrasound revolution

Thoracic ultrasound, widely available in the form of increasingly sophisticated and affordable portable and handheld units, has unquestionably changed the paradigm in bedside medical evaluation. Basic ultrasound education now complements traditional physical examination training at many medical schools, residency, and fellowship programs. Point-of-care ultrasound for diagnosis and management of thoracic diseases in particular is recommended and endorsed by most relevant scientific societies, and there are established training and certification standards¹³⁻¹⁶. In fact, the evidence for improved outcomes and reduced complication rates with ultrasound for thoracic procedures is so overwhelming that its use is now universally considered the standard of care^{17,18}. Bedside ultrasound examination of the pleura can easily confirm the presence of pleural fluid when conventional chest x-ray findings are equivocal.

In addition, it allows an estimation of its volume and complexity and occasionally identifies pleural nodules or masses suggestive of pleural malignancy¹⁹. While most physicians use ultrasound merely to mark the site for needle insertion before setting up for the procedure, real-time ultrasound using a sterile sleeve allows sampling of previously unreachable small loculated effusions and occasionally allows parietal pleural biopsies. Furthermore, recent evidence suggests that pre-procedural identification of the intercostal artery, the course of which can be unpredictable, is easily achieved with a high-frequency probe and could help avoid rare but potentially fatal bleeding complications²⁰⁻²². Ultrasound examination immediately after the procedure can indirectly suggest the occurrence of pneumothorax by the disappearance of the typical “sliding” sign, representing the sliding of visceral and parietal pleura over each other. Rare but potentially serious bleeding complications from injury of the intercostal artery or one of its collateral vessels may also be identified in the form of rapid re-accumulation of echogenic pleural fluid^{23,24}.

Interestingly, there has been relatively little research on pleural ultrasound as a predictive tool. Two small studies suggest that a highly organized pleural space with loculations and septations during pleural space infection predicts poorer outcomes, but these studies are small and unadjusted for possible confounders^{25,26}. An intriguing recent report suggests that ultrasound may allow the identification of unexpandable lung before thoracentesis. In some cases, such as when chronic inflammatory effusions have resulted in the creation of a thick peel around the lung, fluid drainage is not accompanied by lung re-expansion. The vacuum generated can expose patients to complications including pain, pneumothorax, and re-expansion pulmonary edema. Transmission of the heartbeat results in differential lung movement and deformation changes that can be identified by using specific ultrasound modes such as the M-mode and speckle tracking²⁷. In this small study, ultrasound in fact performed better than pleural manometry, long regarded as the gold standard for the diagnosis of unexpandable lung and the utility of which is being assessed in an ongoing randomized clinical trial (ClinicalTrials.gov identifier NCT02677883).

b. Other imaging modalities

There have been comparatively less recent data on other imaging modalities. Whereas loculations (sequestrations of fluid in non-dependent areas) are well identified on computed tomography, the degree of organization within the effusion is better appreciated on ultrasound. In addition, the presence of any of the four following radiologic signs is highly predictive of malignancy: parietal pleural thickening of more than 1 cm, thickened mediastinal pleura, circumferential thickening, and the presence of pleural nodules²⁸. However, in the absence of such specific findings, computed tomography appears neither sensitive nor specific enough to obviate the need for invasive diagnostic interventions^{29,30}. Positron emission tomography is often used to assess the probability of malignant pleural effusion but with modest sensitivity and specificity, which in a recent meta-analysis were estimated to be 81% and 74%, respectively³¹. Recently, magnetic resonance imaging has been proposed as a potentially superior imaging modality for pleural effusions in general and malignant pleural mesothelioma in particular but remains largely underutilized compared with

computed tomography^{32–34}. Radiomic approaches to thoracic diseases represent an early and exciting field in imaging science, and very preliminary work in quantitative imaging for the diagnosis of malignant pleural effusion—and staging and diagnosis of mesothelioma in particular—is generating considerable interest^{35,36}.

2. Diagnosis of pleural diseases: minimally invasive studies

a. Pleural fluid analysis

The “diagnostic separation of transudates and exudates” using a combination of pleural fluid protein and lactate dehydrogenase levels was published in 1972 (in a study that has been cited more than 1,500 times) and to this day remains the single most important step in determining the etiology of a pleural effusion¹¹. Briefly, at the risk of oversimplifying complex processes, transudative effusions typically result from local alterations of the Starling rules that govern capillary microcirculation in the parietal pleura with increased hydrostatic (for example, heart failure) or decreased oncotic (for example, liver failure) pressures, whereas exudative effusions suggest a disease process involving the parietal pleura itself, whether from malignancy, infection, or inflammatory diseases. However, these processes are complex and overlaps are frequent in terms of both pathophysiology and pleural fluid analysis. For example, an estimated 25% of effusions due to congestive heart failure may classify as exudates (“pseudo-exudates”), particularly if the patient is on diuretics³⁷, and conversely a small percentage of documented malignant pleural effusions may classify as transudative effusions. While a high index of suspicion should lead to pleural biopsies in the latter scenario, recent data suggest that the pleural fluid–to–serum albumin gradient could help clarify the etiology of heart failure–related pseudo-exudative pleural effusions³⁸. Pleural and serum brain natriuretic peptide and amino-terminal pro-brain natriuretic peptide levels are also useful to establish heart failure as the cause of the effusion³⁹. Pleural space infections, potentially life-threatening conditions, are usually characterized by typical pleural fluid biochemistry and hence are more straightforward from a diagnostic standpoint, and an interesting recent observation is that the yield of pleural fluid cultures can be increased by 20% by simply inoculating blood culture bottles with pleural fluid at the bedside rather than sending the fluid directly to the laboratory⁴⁰.

b. Cytology and biomarkers

The diagnostic utility of pleural fluid analysis for malignant pleural effusions has been the object of several recent studies. The sensitivity of cytology for malignancy is estimated around 60%, and there is a 15% increase with a second procedure⁴¹, although some reports suggest much lower estimates⁴². Others focusing on modern immunohistochemistry techniques seem much more optimistic, particularly for mesothelioma, a primary pleural malignancy which traditionally requires pleural biopsies for definitive diagnosis^{43,44}. In addition, pleural fluid has been shown to be a biospecimen suitable for the majority of molecular analyses required for targeted therapy⁴⁵. High-throughput techniques and modern molecular techniques promise to identify biomarkers expressed

by cancer cells or their environment that could ultimately transform our diagnostic approach. Novel proposed techniques include single-cell mechanophenotyping which evaluates the deformability of pleural cells⁴⁶, circulating tumor cells and cell-free tumor DNA^{47,48}, and metabolic-based assays to identify non-leukocyte metabolically active tumor cells⁴⁹. These recent developments, though exciting, remain preliminary and are still closer to the bench than they are to the clinic. The search for optimal biomarkers has been hampered by a lack of standardized methodology and failure to externally validate promising results, as in the case of fibulin-3, a biomarker once anticipated to transform our approach to malignant mesothelioma^{50–53}. Large ongoing research projects are attempting to identify reliable alternative candidates.

c. Clinical prediction models

An unprecedented number of well-designed randomized controlled studies published in the last decade by a growing international pleural research network have clarified and sometimes transformed patient management for malignant pleural effusions and pleural space infections in particular. However, one major obstacle faced by researchers and clinicians has been the lack of clinical prediction models allowing appropriate patient selection and stratification. The RAPID (renal, age, purulence, infection source, and dietary factors) score was derived and validated from two large datasets and proposes to risk-stratify patients with pleural space infections, and ultimately its purpose is to individualize management, which currently is subject to local preferences and expertise rather than patient characteristics⁵⁴. A large multicenter observational prospective study to validate this score is ongoing. Similarly, the LENT (pleural fluid lactate dehydrogenase, Eastern Cooperative Oncology Group performance score, neutrophil-to-lymphocyte ratio, and tumor type) score is a clinical prediction model that provides estimates of survival for patients with malignant pleural effusions, which could prove very useful in subject selection in clinical trials and ultimately individualized medical or surgical management of pleural effusions⁵⁵.

3. Diagnosis of pleural diseases: invasive studies

Approximately 25% of exudative pleural effusions remain without identifiable causes after pleural fluid analysis and cytology. Parietal pleural biopsies are the recommended next step in the diagnostic assessment but often are not pursued as they sometimes require thoracic surgery which, though less invasive since the advent of video-assisted thoracoscopic surgery, remains a major operation requiring general anesthesia, double-lumen endotracheal intubation, large-bore chest tube placement, and a hospital stay. Hence, clinicians often default to observation after an unfruitful pleural fluid analysis⁵⁶. An example from a Bayesian approach to diagnosis might be helpful to illustrate the limitations of this approach. Given a sensitivity for cytology of 60% and a specificity of 100%, a patient with a 50% pre-test probability of pleural malignancy would have, after a negative cytology, a remaining 27% post-test probability of disease. After a second thoracentesis, this number decreases to only approximately 18% (a generous estimate as the same test is used twice). Given the profound implications of a diagnosis of malignant pleural effusion, it should be intuitively obvious that moving

forward with additional, ideally minimally invasive, diagnostic tests would be desirable.

Reclaiming a procedure initially introduced by Hans Christian Jacobaeus, a Swedish Professor of Internal Medicine at the Karolinska Institute in Stockholm from 1916 to 1937, interventional pulmonologists and pleural specialists have popularized minimally invasive, so-called “local anesthetic” pleuroscopy, which allows pleural exploration and biopsies in awake patients and often is performed on an outpatient basis^{57–61}. While pleuroscopy is slowly gaining traction in the US, centers offering the procedure have exponentially increased over the past decade in Europe and other parts of the world and presumably this is due to more favorable regulatory environments and sometimes more selective access to thoracic surgery. The development of dedicated interventional pulmonology training programs in the US, with accreditation standards that include pleuroscopy training endorsed by all relevant medical societies, may facilitate a more widespread adoption of this safe and effective diagnostic modality¹⁵. Even less invasive interventions, such as “mini-thoracoscopy”, using increasingly smaller instruments, have been proposed⁶².

When focal pleural lesions can be identified by computed tomography or ultrasound, percutaneous image-guided biopsies performed by interventional radiologists or pulmonary specialists

are a useful and minimally invasive approach to diagnosis which in recent studies has had a yield similar to that of thoracoscopy but without the option to offer definitive treatment in the same setting (pleurodesis or indwelling pleural catheter placement)⁶³.

Conclusions

The rising burden of pleural disease in an increasingly complex patient population demands a more tailored approach to diagnosis and management than ever before. Thoracic ultrasound, the application of new bioassays in addition to foundational biochemical analysis of pleural fluid, the development of models for prognosis and prediction of treatment response, and the resurgence of medical thoracoscopy-pleuroscopy comprise recent advances in pleural disease, and there is a great need for further basic, translational, and clinical research in this field.


Competing interests

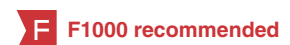Robert J. Lentz and Richard W. Light declare that they have no competing interests.

Grant information

Fabien Maldonado received an unrestricted educational grant from Centurion, Inc.

References

- Wang NS: **Anatomy and physiology of the pleural space.** *Clin Chest Med.* 1985; **6**(1): 3–16.
[PubMed Abstract](#)
- A survey of the long-term effects of talc and kaolin pleurodesis.** Research Committee of the British Thoracic Association and the Medical Research Council Pneumoconiosis Unit. *Br J Dis Chest.* 1979; **73**(3): 285–8.
[PubMed Abstract](#) | [Publisher Full Text](#)
- Lange P, Mortensen J, Groth S: **Lung function 22–35 years after treatment of idiopathic spontaneous pneumothorax with talc poudrage or simple drainage.** *Thorax.* 1988; **43**(7): 559–61.
[PubMed Abstract](#) | [Publisher Full Text](#) | [Free Full Text](#)
- Light RW: **Pleural effusions.** *Med Clin North Am.* 2011; **95**(6): 1055–70.
[PubMed Abstract](#) | [Publisher Full Text](#)
- Viskum K, Lange P, Mortensen J: **Long term sequelae after talc pleurodesis for spontaneous pneumothorax.** *Pneumologie.* 1989; **43**(2): 105–6.
[PubMed Abstract](#)
- Azzopardi M, Porcel JM, Koegelenberg CF, *et al.*: **Current controversies in the management of malignant pleural effusions.** *Semin Respir Crit Care Med.* 2014; **35**(6): 723–31.
[PubMed Abstract](#) | [Publisher Full Text](#)
- Thomas R, Francis R, Davies HE, *et al.*: **Interventional therapies for malignant pleural effusions: the present and the future.** *Respirology.* 2014; **19**(6): 809–22.
[PubMed Abstract](#) | [Publisher Full Text](#)
- Bhatnagar R, Maskell N: **Developing a ‘pleural team’ to run a reactive pleural service.** *Clin Med (Lond).* 2013; **13**(5): 452–6.
[PubMed Abstract](#) | [Publisher Full Text](#)
- DePew ZS, Maldonado F: **The role of interventional therapy for pleural diseases.** *Expert Rev Respir Med.* 2014; **8**(4): 465–77.
[PubMed Abstract](#) | [Publisher Full Text](#)
- Hooper CE, Lee YC, Maskell NA: **Setting up a specialist pleural disease service.** *Respirology.* 2010; **15**(7): 1028–36.
[PubMed Abstract](#) | [Publisher Full Text](#)
- Light RW, Macgregor MI, Luchsinger PC, *et al.*: **Pleural effusions: the diagnostic separation of transudates and exudates.** *Ann Intern Med.* 1972; **77**(4): 507–13.
[PubMed Abstract](#) | [Publisher Full Text](#)
- Young RL, Bhatnagar R, Medford AR, *et al.*: **Evaluation of an ambulatory pleural service: costs and benefits.** *Br J Hosp Med (Lond).* 2015; **76**(10): 608.
[PubMed Abstract](#) | [Publisher Full Text](#)
- Education and Practical Standards Committee, European Federation of Societies for Ultrasound in Medicine and Biology: **Minimum training recommendations for the practice of medical ultrasound.** *Ultraschall Med.* 2006; **27**(1): 79–105.
[PubMed Abstract](#) | [Publisher Full Text](#)
- Mayo PH, Beaulieu Y, Doelken P, *et al.*: **American College of Chest Physicians/ La Société de Réanimation de Langue Française statement on competence in critical care ultrasonography.** *Chest.* 2009; **135**(4): 1050–60.
[PubMed Abstract](#) | [Publisher Full Text](#)
- Mullon JJ, Burkart KM, Silvestri G, *et al.*: **Interventional Pulmonology Fellowship Accreditation Standards: Executive Summary of the Multisociety Interventional Pulmonology Fellowship Accreditation Committee.** *Chest.* 2017; **151**(5): 1114–21.
[PubMed Abstract](#) | [Publisher Full Text](#)
-  Phelps A, Wan J, Straus C, *et al.*: **Incorporation of Ultrasound Education Into Medical School Curricula: Survey of Directors of Medical Student Education in Radiology.** *Acad Radiol.* 2016; **23**(7): 830–5.
[PubMed Abstract](#) | [Publisher Full Text](#) | [F1000 Recommendation](#)
- Duncan DR, Morgenthaler TI, Ryu JH, *et al.*: **Reducing iatrogenic risk in thoracentesis: establishing best practice via experiential training in a zero-risk environment.** *Chest.* 2009; **135**(5): 1315–20.
[PubMed Abstract](#) | [Publisher Full Text](#)
- Gordon CE, Feller-Kopman D, Balk EM, *et al.*: **Pneumothorax following thoracentesis: a systematic review and meta-analysis.** *Arch Intern Med.* 2010; **170**(4): 332–9.
[PubMed Abstract](#) | [Publisher Full Text](#)
- Corcoran JP, Tazi-Mezalek R, Maldonado F, *et al.*: **State of the art thoracic ultrasound: intervention and therapeutics.** *Thorax.* 2017; pii: thoraxjnl-2016-209340.
[PubMed Abstract](#) | [Publisher Full Text](#)
- Helm EJ, Rahman NM, Talakoub O, *et al.*: **Course and variation of the intercostal artery by CT scan.** *Chest.* 2013; **143**(3): 634–9.
[PubMed Abstract](#) | [Publisher Full Text](#)
- Salamonsen M, Doheli K, McGrath D, *et al.*: **Physician-performed ultrasound can**



- accurately screen for a vulnerable intercostal artery prior to chest drainage procedures. *Respirology*. 2013; 18(6): 942–7.
[PubMed Abstract](#) | [Publisher Full Text](#)
22. Salamonson M, Ellis S, Paul E, *et al.*: Thoracic ultrasound demonstrates variable location of the intercostal artery. *Respiration*. 2012; 83(4): 323–9.
[PubMed Abstract](#) | [Publisher Full Text](#)
23. **F** Corcoran JP, Psallidas I, Ross CL, *et al.*: Always Worth Another Look? Thoracic Ultrasonography before, during, and after Pleural Intervention. *Ann Am Thorac Soc*. 2016; 13(1): 118–21.
[PubMed Abstract](#) | [Publisher Full Text](#) | [F1000 Recommendation](#)
24. Shostak E, Brylka D, Krepp J, *et al.*: Bedside sonography for detection of postprocedure pneumothorax. *J Ultrasound Med*. 2013; 32(6): 1003–9.
[PubMed Abstract](#) | [Publisher Full Text](#) | [Free Full Text](#)
25. Chen CH, Chen W, Chen HJ, *et al.*: Transthoracic ultrasonography in predicting the outcome of small-bore catheter drainage in empyemas or complicated parapneumonic effusions. *Ultrasound Med Biol*. 2009; 35(9): 1468–74.
[PubMed Abstract](#) | [Publisher Full Text](#)
26. Chen KY, Liaw YS, Wang HC, *et al.*: Sonographic septation: a useful prognostic indicator of acute thoracic empyema. *J Ultrasound Med*. 2000; 19(12): 837–43.
[PubMed Abstract](#) | [Publisher Full Text](#)
27. **F** Salamonson MR, Lo AKC, Ng ACT, *et al.*: Novel use of pleural ultrasound can identify malignant entrapped lung prior to effusion drainage. *Chest*. 2014; 146(5): 1286–93.
[PubMed Abstract](#) | [Publisher Full Text](#) | [F1000 Recommendation](#)
28. Leung AN, Müller NL, Miller RR: CT in differential diagnosis of diffuse pleural disease. *AJR Am J Roentgenol*. 1990; 154(3): 487–92.
[PubMed Abstract](#) | [Publisher Full Text](#)
29. **F** Hallifax RJ, Haris M, Corcoran JP, *et al.*: Role of CT in assessing pleural malignancy prior to thoracoscopy. *Thorax*. 2015; 70(2): 192–3.
[PubMed Abstract](#) | [Publisher Full Text](#) | [F1000 Recommendation](#)
30. **F** Tsim S, Stobo DB, Alexander L, *et al.*: The diagnostic performance of routinely acquired and reported computed tomography imaging in patients presenting with suspected pleural malignancy. *Lung Cancer*. 2017; 103: 38–43.
[PubMed Abstract](#) | [Publisher Full Text](#) | [Free Full Text](#) | [F1000 Recommendation](#)
31. **F** Porcel JM, Hernández P, Martínez-Alonso M, *et al.*: Accuracy of fluorodeoxyglucose-PET imaging for differentiating benign from malignant pleural effusions: a meta-analysis. *Chest*. 2015; 147(2): 502–12.
[PubMed Abstract](#) | [Publisher Full Text](#) | [F1000 Recommendation](#)
32. Gorkem SB, Coskun A, Yikilmaz A, *et al.*: Evaluation of pediatric thoracic disorders: comparison of unenhanced fast-imaging-sequence 1.5-T MRI and contrast-enhanced MDCT. *AJR Am J Roentgenol*. 2013; 200(6): 1352–7.
[PubMed Abstract](#) | [Publisher Full Text](#)
33. Hierholzer J, Luo L, Bittner RC, *et al.*: MRI and CT in the differential diagnosis of pleural disease. *Chest*. 2000; 118(3): 604–9.
[PubMed Abstract](#) | [Publisher Full Text](#)
34. Nickell LT Jr, Lichtenberger JP 3rd, Khorashadi L, *et al.*: Multimodality imaging for characterization, classification, and staging of malignant pleural mesothelioma. *Radiographics*. 2014; 34(6): 1692–706.
[PubMed Abstract](#) | [Publisher Full Text](#)
35. **F** Gill RR, Naidich DP, Mitchell A, *et al.*: North American Multicenter Volumetric CT Study for Clinical Staging of Malignant Pleural Mesothelioma: Feasibility and Logistics of Setting Up a Quantitative Imaging Study. *J Thorac Oncol*. 2016; 11(8): 1335–44.
[PubMed Abstract](#) | [Publisher Full Text](#) | [Free Full Text](#) | [F1000 Recommendation](#)
36. **F** Pena E, Ojaku M, Inacio JR, *et al.*: Can CT and MR Shape and Textural Features Differentiate Benign Versus Malignant Pleural Lesions? *Acad Radiol*. 2017; pii: S1076-6332(17)30133-2.
[PubMed Abstract](#) | [Publisher Full Text](#) | [F1000 Recommendation](#)
37. Porcel JM: Pleural effusions from congestive heart failure. *Semin Respir Crit Care Med*. 2010; 31(6): 689–97.
[PubMed Abstract](#) | [Publisher Full Text](#)
38. Roth BJ, O'Meara TF, Cragun WH: The serum-effusion albumin gradient in the evaluation of pleural effusions. *Chest*. 1990; 98(3): 546–9.
[PubMed Abstract](#) | [Publisher Full Text](#)
39. **F** Han ZJ, Wu XD, Cheng JJ, *et al.*: Diagnostic Accuracy of Natriuretic Peptides for Heart Failure in Patients with Pleural Effusion: A Systematic Review and Updated Meta-Analysis. *PLoS One*. 2015; 10(8): e0134376.
[PubMed Abstract](#) | [Publisher Full Text](#) | [Free Full Text](#) | [F1000 Recommendation](#)
40. Menzies SM, Rahman NM, Wrightson JM, *et al.*: Blood culture bottle culture of pleural fluid in pleural infection. *Thorax*. 2011; 66(8): 658–62.
[PubMed Abstract](#) | [Publisher Full Text](#)
41. Hooper C, Lee YC, Maskell N, *et al.*: Investigation of a unilateral pleural effusion in adults: British Thoracic Society Pleural Disease Guideline 2010. *Thorax*. 2010; 65(Suppl 2): ii4–17.
[PubMed Abstract](#) | [Publisher Full Text](#)
42. Porcel JM, Esquerda A, Vives M, *et al.*: Etiology of pleural effusions: analysis of more than 3,000 consecutive thoracenteses. *Arch Bronconeumol*. 2014; 50(5): 161–5.
[PubMed Abstract](#) | [Publisher Full Text](#)
43. Metzgeroth G, Kuhn C, Schulteis B, *et al.*: Diagnostic accuracy of cytology and immunocytochemistry in carcinomatous effusions. *Cytopathology*. 2008; 19(4): 205–11.
[PubMed Abstract](#) | [Publisher Full Text](#)
44. Segal A, Sterrett GF, Frost FA, *et al.*: A diagnosis of malignant pleural mesothelioma can be made by effusion cytology: results of a 20 year audit. *Pathology*. 2013; 45(1): 44–8.
[PubMed Abstract](#) | [Publisher Full Text](#)
45. Liu X, Lu Y, Zhu G, *et al.*: The diagnostic accuracy of pleural effusion and plasma samples versus tumour tissue for detection of EGFR mutation in patients with advanced non-small cell lung cancer: comparison of methodologies. *J Clin Pathol*. 2013; 66(12): 1065–9.
[PubMed Abstract](#) | [Publisher Full Text](#) | [Free Full Text](#)
46. **F** Tse HT, Gossett DR, Moon YS, *et al.*: Quantitative diagnosis of malignant pleural effusions by single-cell mechanophenotyping. *Sci Transl Med*. 2013; 5(212): 212ra163.
[PubMed Abstract](#) | [Publisher Full Text](#) | [F1000 Recommendation](#)
47. Schwed Lustgarten DE, Thompson J, Yu G, *et al.*: Use of circulating tumor cell technology (CELLSEARCH) for the diagnosis of malignant pleural effusions. *Ann Am Thorac Soc*. 2013; 10(6): 582–9.
[PubMed Abstract](#) | [Publisher Full Text](#) | [Free Full Text](#)
48. Sriram KB, Relan V, Clarke BE, *et al.*: Pleural fluid cell-free DNA integrity index to identify cytologically negative malignant pleural effusions including mesotheliomas. *BMC Cancer*. 2012; 12: 428.
[PubMed Abstract](#) | [Publisher Full Text](#) | [Free Full Text](#)
49. **F** Tang Y, Wang Z, Li Z, *et al.*: High-throughput screening of rare metabolically active tumor cells in pleural effusion and peripheral blood of lung cancer patients. *Proc Natl Acad Sci U S A*. 2017; 114(10): 2544–9.
[PubMed Abstract](#) | [Publisher Full Text](#) | [Free Full Text](#) | [F1000 Recommendation](#)
50. Creaney J, Dick IM, Meniawy TM, *et al.*: Comparison of fibulin-3 and mesothelin as markers in malignant mesothelioma. *Thorax*. 2014; 69(10): 895–902.
[PubMed Abstract](#) | [Publisher Full Text](#) | [Free Full Text](#)
51. Pass HI, Goparaju C: Fibulin-3 as a biomarker for pleural mesothelioma. *N Engl J Med*. 2013; 368(2): 190.
[PubMed Abstract](#) | [Publisher Full Text](#) | [Free Full Text](#)
52. Pass HI, Levin SM, Harbut MR, *et al.*: Fibulin-3 as a blood and effusion biomarker for pleural mesothelioma. *N Engl J Med*. 2012; 367(15): 1417–27.
[PubMed Abstract](#) | [Publisher Full Text](#) | [Free Full Text](#)
53. Blyth KG: Inconsistent results or inconsistent methods? A plea for standardisation of biomarker sampling in mesothelioma studies. *Thorax*. 2015; 70(4): 374.
[PubMed Abstract](#) | [Publisher Full Text](#)
54. Rahman NM, Kahan BC, Miller RF, *et al.*: A clinical score (RAPID) to identify those at risk for poor outcome at presentation in patients with pleural infection. *Chest*. 2014; 145(4): 848–55.
[PubMed Abstract](#) | [Publisher Full Text](#)
55. Clive AO, Kahan BC, Hooper CE, *et al.*: Predicting survival in malignant pleural effusion: development and validation of the LENT prognostic score. *Thorax*. 2014; 69(12): 1098–104.
[PubMed Abstract](#) | [Publisher Full Text](#) | [Free Full Text](#)
56. Davies HE, Rosenstengel A, Lee YC: The diminishing role of surgery in pleural disease. *Curr Opin Pulm Med*. 2011; 17(4): 247–54.
[PubMed Abstract](#) | [Publisher Full Text](#)
57. Hatzinger M, Kwon ST, Langbein S, *et al.*: Hans Christian Jacobaeus: Inventor of human laparoscopy and thoracoscopy. *J Endourol*. 2006; 20(11): 848–50.
[PubMed Abstract](#) | [Publisher Full Text](#)
58. DePew ZS, Wagle D, Mullan JJ, *et al.*: Feasibility and safety of outpatient medical thoracoscopy at a large tertiary medical center: a collaborative medical-surgical initiative. *Chest*. 2014; 146(2): 398–405.
[PubMed Abstract](#) | [Publisher Full Text](#)
59. Psallidas I, Corcoran JP, Fallon J, *et al.*: Provision of Day-Case Local Anesthetic Thoracoscopy: A Multicenter Review of Practice. *Chest*. 2017; 151(2): 511–2.
[PubMed Abstract](#) | [Publisher Full Text](#)
60. Rahman NM, Ali NJ, Brown G, *et al.*: Local anaesthetic thoracoscopy: British Thoracic Society Pleural Disease Guideline 2010. *Thorax*. 2010; 65(Suppl 2): ii54–60.
[PubMed Abstract](#) | [Publisher Full Text](#)
61. Marchetti GP, Pinelli V, Tassi GF: 100 years of thoracoscopy: historical notes. *Respiration*. 2011; 82(2): 187–92.
[PubMed Abstract](#) | [Publisher Full Text](#)
62. Tassi GF, Marchetti GP, Pinelli V: Minithoracoscopy: a complementary technique for medical thoracoscopy. *Respiration*. 2011; 82(2): 204–6.
[PubMed Abstract](#) | [Publisher Full Text](#)
63. Koegelenberg CF, Diacon AH: Pleural controversy: close needle pleural biopsy or thoracoscopy-which first? *Respirology*. 2011; 16(5): 738–46.
[PubMed Abstract](#) | [Publisher Full Text](#)

Open Peer Review

Current Referee Status:  

Editorial Note on the Review Process

F1000 Faculty Reviews are commissioned from members of the prestigious F1000 Faculty and are edited as a service to readers. In order to make these reviews as comprehensive and accessible as possible, the referees provide input before publication and only the final, revised version is published. The referees who approved the final version are listed with their names and affiliations but without their reports on earlier versions (any comments will already have been addressed in the published version).

The referees who approved this article are:

Version 1

- 1 **Nick Maskell** Academic Respiratory Unit, School of Clinical Sciences, University of Bristol, Bristol, UK
Competing Interests: No competing interests were disclosed.
- 1 **Liju Ahmed** Department of Thoracic Medicine, Guy's and St Thomas' NHS Foundation Trust, London, UK
Competing Interests: No competing interests were disclosed.