

Contents lists available at [ScienceDirect](http://www.sciencedirect.com)

International Journal of Surgery Case Reports

journal homepage: www.casereports.com

Laparoscopic treatment of Dunbar syndrome: A case report



Orlando Jorge M. Torres*, Ozimo Pereira Gama-Filho, Camila Cristina Salazar Torres, Ricardo Mary Medeiros, Caio Márcio Barros Oliveira

Department of Gastrointestinal Surgery, Internal Medicine and Anesthesiology, Hospital São Domingos, São Luiz, MA, Brazil

ARTICLE INFO

Article history:

Received 21 March 2017

Received in revised form 23 June 2017

Accepted 25 June 2017

Available online 8 July 2017

Keywords:

Dunbar syndrome

Celiac compression syndrome

Arcuate ligament syndrome

Laparoscopy

ABSTRACT

BACKGROUND: Dunbar syndrome is a rare disorder due to external compression of the celiac trunk by the median arcuate ligament. The symptoms include abdominal pain, nausea and vomiting. Laparoscopic treatment was suggested as a safe procedure. The aim of this study is to present a case of Dunbar syndrome underwent laparoscopic treatment.

CASEPRESENTATION: A 17-year-old female patient presented at emergency room with upper abdominal pain and dyspepsia, related to food intake. A selective arteriography of the celiac trunk revealed stenosis due to compression of the celiac artery. The decompression of the celiac trunk by the median arcuate ligament was performed. Postoperative course was uneventful and the patient was discharged on the 5th postoperative

CONCLUSIONS: Laparoscopic division of the arcuate ligament in patients with Dunbar syndrome is feasible and safe. This procedure can be performed uneventful in order to restore quality of life of the patient.

© 2017 The Authors. Published by Elsevier Ltd on behalf of IJS Publishing Group Ltd. This is an open access article under the CC BY-NC-ND license (<http://creativecommons.org/licenses/by-nc-nd/4.0/>).

1. Introduction

Dunbar syndrome, also known as celiac artery compression syndrome or median arcuate ligament syndrome is a rare disorder due to external compression of the celiac trunk by the median arcuate ligament. The syndrome was first described by Harjola in 1963 and Dunbar et al. in 1965, the pain is associated to insertion of the ligament at a lower level of the diaphragm, narrowing the lumen of the celiac trunk by compression [1,2]. Dunbar syndrome is more prevalent in children and adolescents and is associated with vegetative symptoms, mainly during expiration. The symptoms include the classical triad observed in mesenteric ischemia characterized by postprandial abdominal pain, nausea and vomiting and subsequently weight loss [3,4].

After the suspicion, selective angiography in expiration or magnetic resonance angiography identify the stenosis of the initial segment of the celiac artery and confirms the diagnosis. The treatment includes the section of the median arcuate ligament and the fibers of the celiac plexus that can be performed by percutaneous transluminal angioplasty or surgery [3,4]. As open surgical approach is considered an invasive technique, laparoscopic surgery has been suggested [5,6]. The aim of this study is to present a case of Dunbar syndrome treated by laparoscopic approach. This work is in line with the SCARE criteria [9].

* Corresponding author.

E-mail addresses: o.torres@uol.com.br, orlando.torres@huufma.br (O.J.M. Torres).

2. Case report

A 17-year-old female patient presented at emergency room with upper abdominal pain, nausea, vomiting and dyspepsia, related to food intake. Physical examination of the abdomen revealed tenderness to palpation. Laboratory blood tests were unremarkable. Esophagogastroduodenal endoscopy revealed gastric and duodenal distension with slow peristalsis. Colonoscopy was normal. A computed tomography of the abdomen was performed and showed gastric and duodenal distension. The patient underwent laparoscopy for diagnosis and the findings were normal. Three weeks after discharge, the patient was rehospitalized presenting the same symptoms, refusing any oral nutrition. A selective arteriography of the celiac trunk and superior mesenteric artery revealed stenosis due to compression of the celiac artery by median arcuate ligament. Angiotomography confirm the diagnosis (Figs. 1 and 2).

After cardiovascular evaluation the patient was reoperated by laparoscopy. The celiac trunk with splenic artery and left gastric artery were identified and transection of the median arcuate ligament was performed (Fig. 3). All compressive tissue extending one centimeter from the celiac trunk was circumferentially removed. Postoperative course was uneventful, food intake start on postoperative day two and the patient was discharged on the 5th postoperative day without complications. Four weeks after laparoscopy an angiotomography was performed and the celiac trunk was successful decompressed with blood flow almost complete (Fig. 4).

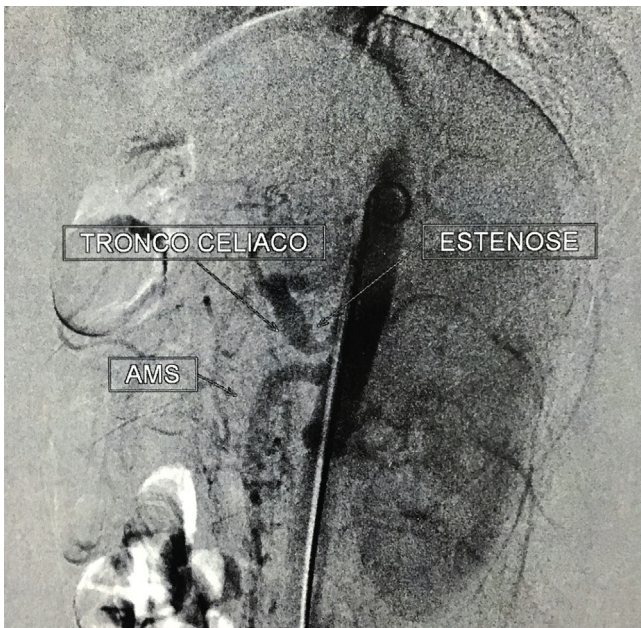


Fig. 1. Selective arteriography of the celiac trunk reveal stenosis of the artery due to compression by arcuate ligament.

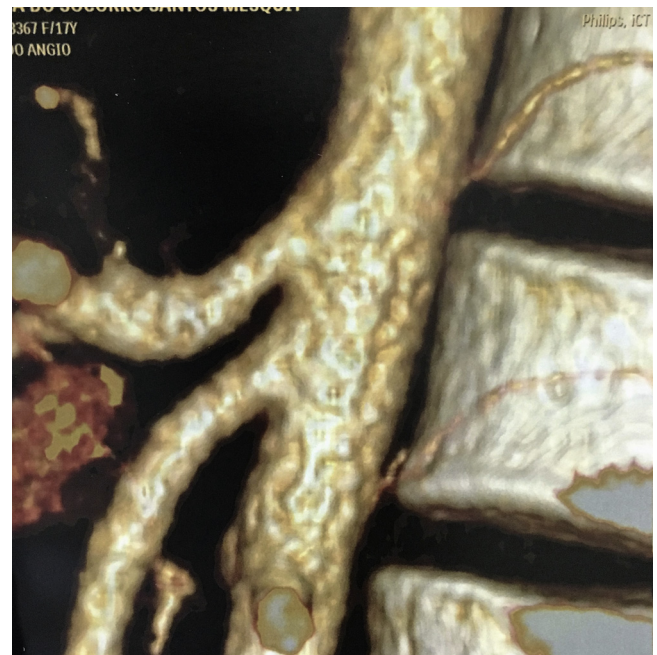


Fig. 4. Angiotomography four weeks after laparoscopic surgery.

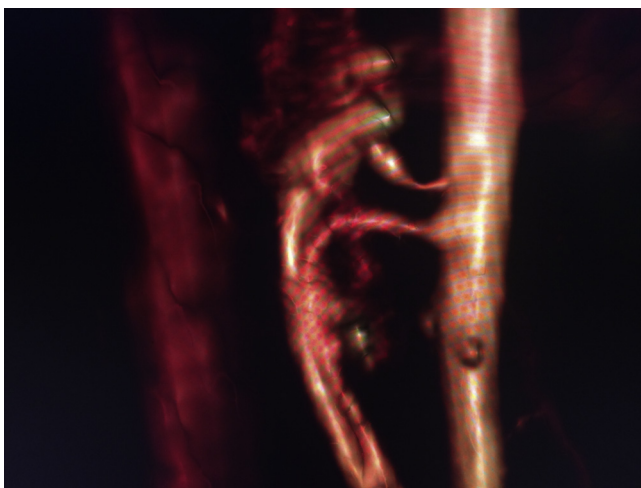


Fig. 2. Angiotomography reveal stenosis of the celiac artery.

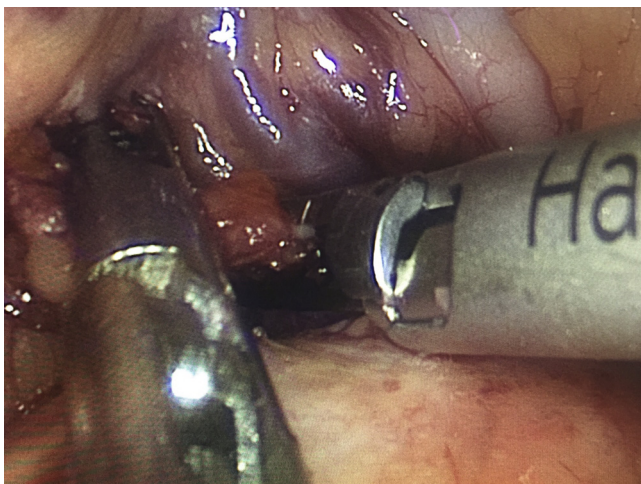

Fig. 3. Dissection of median arcuate ligament by laparoscopy.

3. Discussion

Dunbar syndrome is a rare and controversial vascular compression syndrome, characterized by postprandial intestinal angina caused by insufficient blood supply from the celiac artery to the gastrointestinal tract. The median arcuate ligament is a fibrous arch located anterior to the aorta and formed by a connection of the diaphragmatic crura. The celiac plexus is located between the arcuate ligament and the celiac trunk in up to 25% of normal individuals. Among other causes, the compression of the celiac trunk is due to a descensus of the diaphragm after period of accelerated growth in adolescents. The female to male ratio is 3:1 and the classic patient is a female aged between 18 and 30 years [2–4]. In the present study the patient was a 17 year-old female and abdominal pain was the main symptom.

The incidence of this disease is not known and typical symptoms are chronic or recurring epigastric pain associated with vegetative symptoms including nausea, vomiting, dizziness, tachycardia, diarrhea, weight loss and sweating. Radiating to the flanks or back can also be observed. The classical manifestation of abdominal angina is seen in about 40% of patients. The pain seems to be related to mechanical irritation of the celiac plexus nerve fibers. Two theories have been suggested to elucidate the symptoms. In the first theory, compression of the mesenteric artery producing mesenteric ischemia and the second is the splanchnic vasoconstriction due to stimulation of the celiac ganglion and celiac plexus [1,3,4]. Others clinical symptom are bloating and reduced appetite. In some cases, an epigastric bruit is detected on clinical examination [4,5]. In this study the symptom was related to oral intake, but without weight loss.

Dunbar syndrome is a diagnosis of exclusion and some other diseases may cause similar symptoms like esophagitis, pancreatitis, cholelithiasis, and food intolerance. The diagnosis of Dunbar syndrome may be made by selective angiography, magnetic resonance angiography, spiral computed tomographic angiography, and Doppler ultrasound. The combination of color duplex sonography and gastric exercise tonometry has been reported as having excellent accuracy for the diagnosis. Respiratory maneuvers are necessary for complete diagnosis. The stenosis is respiratory-

dependent, it is present in expiration and disappear during deep inspiration. The demonstration of the stenosis followed by dilatation of the celiac trunk during expiration confirms the diagnosis. The typical hook-like downward displacement followed by a dilatation of the celiac artery is a typical finding [3–5]. The diagnosis in this study was made by selective arteriography of the celiac trunk followed by angiotomography.

Treatment modalities after the diagnosis of symptomatic Dunbar syndrome include endovascular and open or laparoscopic surgical procedures. Endovascular procedures include percutaneous transluminal angioplasty and stent implantation. However it does not solve the problem of extrinsic compression and sometimes requires surgical intervention [3–5].

Symptomatic patients with celiac artery compression confirmed by angiography will benefit more from surgical treatment. The operative procedure is based on the visualization and division of the arcuate ligament with decompression of the celiac artery. In some cases reconstruction of the artery or interposition of graft is necessary. Decompression by minimally invasive surgery should be the treatment of choice. Laparoscopic technique has been reported for treating patients with Dunbar syndrome and recently authors have reported robotic-assisted decompression as a safe modality of treatment. Laparoscopic or robotic are safe options for the treatment of Dunbar syndrome [5–8]. Laparoscopic approach was performed in this case and the postoperative course was uneventful.

4. Conclusions

Laparoscopic division of the arcuate ligament and the resection of the coeliac plexus in patients with Dunbar syndrome are feasible and safe. This procedure can be performed uneventful in order to restore quality of life of the patient.

Conflicts of interest

No conflict of interest.

Sources of funding

No financial. No funding.

Ethical approval

Ethical approval was not required and patient identifying knowledge was not presented in this report.

Consent

“Written informed consent was obtained from the patient for publication of this case report and accompanying images. A copy of the written consent is available for review by the Editor-in-Chief of this journal on request”.

Author contribution

Orlando Jorge M Torres – Study concept, design, data collection, data analysis, interpretation, written.

Ozimo Pereira Gama-Filho – Data collection, data analysis.

Camila Cristina S Torres – Design, data collection, data analysis, interpretation, written.

Ricardo Mary Medeiros – Data collection, data analysis, interpretation.

Caio Marcio Barros Oliveira – Data collection, data analysis.

Guarantor

I accept full responsibility for the work and for financial issues.

References

- [1] P.T. Harjola, A rare obstruction of the coeliac artery; report of case, *Ann. Chir. Gynecol. Fenn.* 52 (1963) 547–550.
- [2] J.D. Dunbar, W. Molnar, F.F. Beman, S.A. Marable, Compression of celiac trunk and abdominal angina, *Am. J. Roentgenol. Radium. Ther. Nucl. Med.* 95 (1965) 731–744.
- [3] S. Gander, D.J. Mulder, S. Jones, J.D. Ricketts, D.A. Soboleski, C.J. Justinich, Recurrent abdominal pain and weight loss in an adolescent: celiac artery compression syndrome, *Can. J. Gastroenterol.* 24 (2010) 91–93.
- [4] J.L. Bobadilla, Mesenteric ischemia, *Surg. Clin. North. Am.* 93 (2013) 925–940.
- [5] J.C. Jimenez, M. Harlander-Locke, E.P. Dutson, Open and laparoscopic treatment of median arcuate ligament syndrome, *J. Vasc. Surg.* 56 (2012) 869–872.
- [6] L. Dordoni, Y. Tshomba, M. Giacomelli, Celiac artery compression syndrome: successful laparoscopic treatment—a case report, *Vasc. Endovasc. Surg.* 36 (2002) 317–321.
- [7] K.M. El-Hayek, J. Titus, A. Bui, Laparoscopic median arcuate ligament release: are we improving symptoms, *J. Am. Coll. Surg.* 216 (2013) 272–279.
- [8] G.S. Roseborough, Laparoscopic management of celiac artery compression syndrome, *J. Vasc. Surg.* 50 (2009) 124–133.
- [9] R.A. Agha, A.J. Fowler, A. Saeta, I. Barai, S. Rajmohan, Orgill DP, for the SCARE group, the SCARE statement: consensus-based surgical case report guidelines, *Int. J. Surg.* 34 (2016) 180–186.

Open Access

This article is published Open Access at sciedirect.com. It is distributed under the [IJSCR Supplemental terms and conditions](#), which permits unrestricted non commercial use, distribution, and reproduction in any medium, provided the original authors and source are credited.