

Research article

Evrin Bougie: A new instrument in the management of urethral strictures

Ugur Yilmaz*, Ali Gunes, Ahmet Soylu and Mevlana Derya Balbay

Address: Department of Urology, Inonu University Medical Faculty, Malatya, Turkey

E-mail: Ugur Yilmaz* - uyilmaz@inonu.edu.tr; Ali Gunes - gunesali@yahoo.com; Ahmet Soylu - asoylu@inonu.edu.tr; Mevlana Derya Balbay - mdbmd@hotmail.com

*Corresponding author

Published: 24 August 2001

Received: 20 May 2001

BMC Urology 2001, 1:1

Accepted: 24 August 2001

This article is available from: <http://www.biomedcentral.com/1471-2490/1/1>

© 2001 Yilmaz et al; licensee BioMed Central Ltd. Verbatim copying and redistribution of this article are permitted in any medium for any non-commercial purpose, provided this notice is preserved along with the article's original URL. For commercial use, contact info@biomedcentral.com

Abstract

Background: In this study a new instrument and technique is described for the endoscopic treatment of complete posterior urethral strictures, which may result in serious complications and sometimes require troublesome treatments.

Methods: Three patients with complete posterior urethral obstruction were treated endoscopically with the guidance of a new instrument: Evrim Bougie. Evrim Bougie looks like a Guyon Bougie, has a curved end, which facilitates getting into the bladder through the cystostomy tract and with a built in channel of 1.5 mm in diameter for a sliding needle exiting at its tip. Having confirmed fluoroscopically and endoscopically that the sliding needle had passed across the strictured segment, the strictured segment was incised with internal urethrotomy, distal to the strictured segment, and urethral continuity was accomplished. At the end of the operation a Foley urethral catheter was easily placed into the bladder per urethra. Patients were instructed in self-catheterization after removal of the urethral catheter. All patients achieved normal voiding at postoperative 7th month follow-up evaluation.

Conclusion: Internal urethrotomy could be performed under the guidance of the sliding needle of Evrim Bougie advanced from above the posterior urethral strictures, which to our knowledge was described for the first time in the English literature. We also believe that there may be other possible indications of Evrim Bougie for different procedures in urethral surgery.

Background

Bulbomembranous urethral strictures occur most commonly as a result of urethral distraction injuries following pelvic trauma or straddle injuries. Although the most common point of distraction is at the junction of the membranous and the bulbospongious segments, injury can also involve any part between the bulbospongious and prostatic urethral segments [1]. Various treatment modalities such as core-through internal urethrotomy,

immediate or delayed realignment with "above-and-below" or "cut-to-the-light" procedures, 2-stage endourethroplasty and use of titanium stents have been advocated for the treatment of posterior urethral disruption injuries [2-7]. After the prompt placement of a suprapubic cystostomy, delayed repairs of a bulbomembranous urethral disruption, i.e. surgical reconstruction, minimally invasive procedure with endo-

scopic reconstitution and internal urethrotomy carry an approximately 100% risk of urethral stricture formation.

The most discouraging factor in selecting an endoscopic intervention as the treatment of choice, especially for a long segment of bulbomembranous urethra with complete obliteration is the lack of a proper guide with the help of which a safe and easy internal urethrotomy can be performed. The most troublesome complications of such an intervention are urethral false passages and rectal injuries.

We report a new technique, with the presentation of a new bougie, to overcome commonly encountered difficulties in internal urethrotomy procedures carried out for complete posterior urethral obliterations, which prevents the above-mentioned possible complications, and also shortens the time of the operation.

Patients and Methods

Three male patients were treated with internal urethrotomy using a new instrument Evrim Bougie. Two patients (28 and 43 years) had prior perineal urethroplasties and developed urethral strictures in the early postoperative period. The third patient a 21-year-old man, presented with a vesicocutaneous fistula secondary to a complete prostatomembranous stricture. All patients had complete bulbomembranous strictures longer than 1 cm in length and open bladder necks confirmed by cystographic evaluations.

Evrin Bougie, (Evrin=evolution in Turkish), is made up of chromium-nickel which looks like an 18F Guyon Bougie with a curved end which facilitates getting into the bladder through the cystostomy tract, and an additional built-in channel of 1.5 mm in diameter for a sliding needle (1 mm thick) exiting at its tip (Figure 1).

At the time of the procedure, Evrim Bougie with the sliding needle in its channel was advanced through the cystostomy tract in two cases and through a cystostomy incision at the time of an open bladder and urethra exploration to reach the bladder neck and prostatic urethra. After confirming that Evrim Bougie was in its proper position with transrectal palpation of its tip in the prostatic urethra, bladder neck or in the proximal part of the obliterated segment, an internal urethrotome was then passed through external urethral meatus up to the distal part of the stricture and the plane between the urethrotome and the bougie was confirmed fluoroscopically at both 90° and 30° angles, so that both instruments were in line with each other in both planes. The sliding needle was then slowly and cautiously advanced through the strictured segment under fluoroscopic and endoscopic control until its tip was clearly seen endoscopical-




Figure 1
Evrin Bougie (above) with a built-in channel of 1.5 mm in diameter for the sliding needle of 1 mm thickness (below) to exit at its tip.

ly from the distal part of the urethra (Figure 2). The obliterated segment was incised with the internal urethrotomy and urethral continuity was accomplished. There was not any significant bleeding that would obscure the endoscopic vision.

The operation was completed with the placement of a 16F urethral catheter, which was removed on postoperative 10th day in each case with normal voiding and full continence. Patients were then placed on intermittent catheterization once a day with a 16F Foley catheter for two months. All the patients demonstrated normal voiding function as per uroflowmetry at the postoperative 7th month follow-up evaluation.

Discussion

Among various treatment approaches for distraction injuries of posterior urethra, there is definitely a role for endoscopic urethral re-alignment. However, success rates of such procedures are limited by the length of the stricture, and recurrent stricture rates are without question higher for endoscopically repaired strictures than for primary delayed open repair [1,8,9]. Since stricture rates are much less than with formal suprapubic cystostomy alone if primary re-alignment can be accomplished, most major trauma centers advocate an attempt at primary urethral re-alignment at the time of injury. The limiting factors for all approaches are development of complete or incomplete urethral strictures following the trauma and the need of recanalization procedure of the obliterated segment by either one of the open reconstructive techniques such as perineal urethroplasty or by minimally invasive procedures [10]. Yet, the "gold standard" of post-traumatic urethral surgery for residual stricture is still open one-stage posterior urethroplasty. The

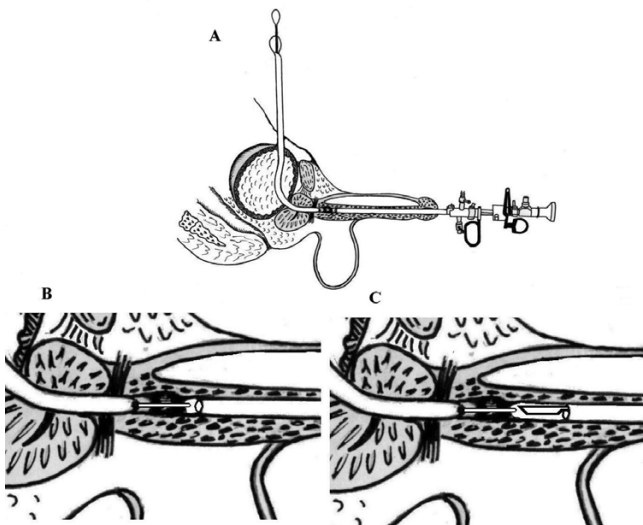


Figure 2
A: Evrim Bougie is advanced through the cystostomy tract in the bladder neck towards the proximal part of the obliterated segment and an internal urethrotome is passed transurethraly to the distal part of the stricture, **B:** In the second step, the sliding needle is advanced through the strictured segment, **C:** The strictured segment is incised with internal urethrotome under the guidance of the sliding needle.

rates of incontinence and erectile dysfunction are the same with all treatment approaches, as the injury itself causes these complications, and not the corrective surgery [8].

Should the endoscopic intervention be elected to treat post-traumatic urethral stricture, the surgeon must be cautious to minimize the procedure related complications such as rectal injury or formation of a false passage, especially in completely obliterated urethral strictures when performing "cut-to-the-light" procedure. Besides, urethral bleeding during urethrotomy can obscure the clear endoscopic vision especially in strictures with longer segments. Therefore, a precise, easily done and bloodless technique to obviate the strictured segment is needed.

To our knowledge, Evrim Bougie, is the first instrument used for such a purpose published in the English literature. Its sliding needle makes the procedure less traumatic since it is possible to pierce the strictured fibrotic segment without creating a false passage. In cases of misdirection, as assessed fluoroscopically and endoscopically, the needle can be withdrawn without creating any significant trauma to the neighboring structures. Injury to the rectum is not expected, since the curved end of the bougie lets the sliding needle out only in the anterior di-

rection toward the distal end of the stricture. In our opinion, the presented technique might be easier than other procedures in recanalizing the long strictured segments.

Conclusions

The presented technique allows easy endoscopic recanalization of posterior bulbomembranous obliterations with the help of the "Evrin Bougie". Following this minimally invasive procedure, patients can be instructed to self-catheterize, as needed. Required only are a port of access, which is a cystostomy tract and an open bladder neck to reach into the lumen of the proximal portion of the obliterated segment. We believe that, this innovative device may prove of interest to urologic surgeons who are uncomfortable with open posterior urethral surgery, or as an alternative to open surgery in patients who have contraindications to a formal open approach. The Evrim Bougie may also prove to be of interest in open surgery as well, specifically to define the proximal urethra as well as aiding in the dissection of dense scar distal to the proximal urethra.

Competing Interests

None of the authors of the manuscript have received reimbursements, fees, funding, or salary from an organisation in the past five years that may in any way gain or lose financially from the publication of this paper. And, none of the authors hold any stocks or shares in an organization that may in any way gain or lose financially from the publication of this paper and none have any other financial or non-financial competing interests, either.

References

- Jordan GH, Schlossberg SM, Devine CJ: **Surgery of the penis and urethra.** In: *Campbell's Urology* (Edited by Walsh PC, Vaughan ED, Retik AB, AJ Wein) Philadelphia, Saunders 1998, **7th edn:**3316-3394
- Gupta NP, Gill IS: **Core-through optical internal urethrotomy in management of impassable traumatic posterior urethral strictures.** *J Urol* 1986, **136:**1018-1021
- Leonard MP, Emtage JE, Perez T, Morales A: **Endoscopic management of urethral stricture: "cut to the light" procedure.** *Urology* 1990, **35:**117-120
- Gonzales R, Chiou RK, Hekmat T, Fraley EE: **Endoscopic reestablishment of urethral continuity after traumatic disruption of the membranous urethra.** *J Urol* 1983, **130:**785-787
- Chiou RK: **Endourethroplasty in the management of complicated posterior strictures.** *J Urol* 1988, **140:**607-610
- Quint HJ, Stanicic TH: **Above and below delayed endoscopic treatment of traumatic posterior urethral disruptions.** *J Urol* 1993, **149:**484-487
- Morey AF, McAninch JW: **Reconstruction of posterior urethral disruption injuries: Outcome analysis in 82 patients.** *J Urol* 1997, **157:**506-510
- Mundy AR: **Pelvic fracture injuries of the posterior urethra.** *World J Urol* 1999, **17:**90-95
- Morey AF, Hernandez J, McAninch JW: **Reconstructive surgery for trauma of the lower urinary tract.** *Urol Clin North* 1999, **26(1):**49-60
- Koraitim MM: **Pelvic fracture urethral injuries: Evaluation of various methods of management.** *J Urol* 1996, **156:**1288-1291