

Evaluation of the Efficacy of Clinical Breast Examination Gloves in the Diagnosis of Breast Lumps

VANESSA MONTEIRO SANVIDO¹, ANDREA YUMI WATANABE², JOAQUIM TEODORO DE ARAÚJO NETO³, SIMONE ELIAS⁴, GIL FACINA⁵, AFONSO CELSO PINTO NAZÁRIO⁶

ABSTRACT

Introduction: Recent studies have questioned the efficacy of mammography in reducing breast cancer-related mortality. Additionally, the efficacies of commercially available gloves marketed as aiding the detection of breast lumps have not been independently verified.

Aim: To evaluate the efficacy of clinical breast examination gloves in the detection of breast lumps.

Materials and Methods: During the period from October 2011 to June 2012, patients were submitted to clinical examination with and without gloves. This prospective study involved 202 patients who underwent conventional clinical breast examination (test 1) or clinical breast examination with Sensifemme[®] gloves (test 2). All patients underwent subsequent bilateral ultrasonography (test 3) to confirm the findings of the physical examinations. The Chi-square test was used to compare values, while the kappa concordance index was used to determine the concordance between the diagnostic tests.

Results: The mean age of the patients was 43 years; 298 breast lumps were detected. In the clinical examination group (test 1),

sensitivity was 54%, specificity was 78%, and accuracy was 57%. These rates for clinical breast examinations with gloves (test 2) were 68%, 58%, and 66%, respectively. The glove increased the diagnosis of breast nodules by 14%; the rate of false-positives was also higher (42% for test 2 compared to 22% for test 1). The accuracy of the glove was found to be superior to clinical examination after 100 patients had been examined. The kappa indices for test 1 vs. test 3 and for test 2 vs. test 3 were 0.15 and 0.16, respectively.

Conclusion: Clinical examination using the glove was more effective than clinical examination with bare hands for the diagnosis of breast lumps, as it increased the sensitivity and accuracy of lump detection. However, this was at the expense of a higher false-positive rate, which can lead to further tests, unnecessary biopsies, and patient anxiety. The concordance of clinical examination results (whether performed with or without the glove) with those of ultrasonography is weak. Moreover, the glove has a steep learning curve that may discourage its use in certain circumstances.

Keywords: Breast neoplasms, Mammography, Physical examination, Self-examination

INTRODUCTION

Breast cancer is the second most frequent cancer in women after non-melanoma skin cancers. It is a public health problem for which the main prevention mechanisms include health awareness, early detection and effective treatment. Secondary prevention is accomplished by self-examination, clinical examination and mammography; the latter is the primary screening method that leads to reduced mortality [1,2]. There is no evidence that self-examination or clinical examinations reduce breast cancer mortality [3,4]. Moreover, diagnosis is still often delayed in developing countries [5].

Recent studies have questioned the impact of mammographic screening and its actual benefit. In 2014, the Canadian National Breast Screening Study published the results of 25 years of follow-up of patients who did or did not undergo mammographic screening; the study found no difference in overall survival between two groups. However, survival was higher in patients with non-palpable lesions [6].

Clinical examination is a simple, inexpensive, and non-invasive method for detecting breast cancer. While screening solely based on this method does not rule out the disease or reduce breast cancer mortality, the high specificity of an abnormal physical examination increases the likelihood of diagnosing a malignancy [7,8]. Moreover, the combination of clinical examination with mammography increases screening sensitivity.

Self-examination is not recommended owing to increased breast-related complaints as well as a greater number of biopsies for

benign lesions [9-11]; however, it may play a role in increasing the awareness of women regarding the importance of breast cancer prevention, i.e., breast cancer awareness. The patient is encouraged to perform self-examination when convenient in order to perceive minimum changes in the breast and to actively seek medical care if any suspicious changes are detected [12].

Breast examination gloves were developed to facilitate the gliding of the examiner's fingers on the breast in order to increase the sensitivity of both clinical and self-examinations. Many gloves are available in the market, such as Donna Glove[®], Be-Glove[®], Sensifemme[®], Sensa Touch[®], and others. Such gloves consist of three layers of 0.5-mm-thick polyurethane. The outermost layer is in direct contact with the breast, and mineral oil is contained between this layer and the middle layer. All components of the device conform to European Community Directives and Food and Drug Administration requirements (21 CFR 172.878 and 21 CFR 178.3620A) [13].

A cross-sectional study with 130 patients at the University of Rome Tor Vergata and the Central Hospital of Viterb was performed to evaluate the detection of palpable lesions by self-examination with and without the use of the gloves. Nodule detection was 100% in the group that used the glove compared to 48% in the group that did not. Patients found the product easy to use and noted that its availability increased awareness about breast cancer prevention [13].

Conversely, there have been published warnings against the use of such gloves as a replacement for mammography screening, stating that their effectiveness is inferior to that of mammography

and emphasizing evidence that these devices are of very limited use for the detection of breast tumours [14].

Although there are some reports of increased touch sensitivity and greater detection of breast nodules while performing clinical breast examinations using gloves, there are no scientific studies investigating the benefits of these devices. Therefore, we performed the present study to address this issue.

MATERIALS AND METHODS

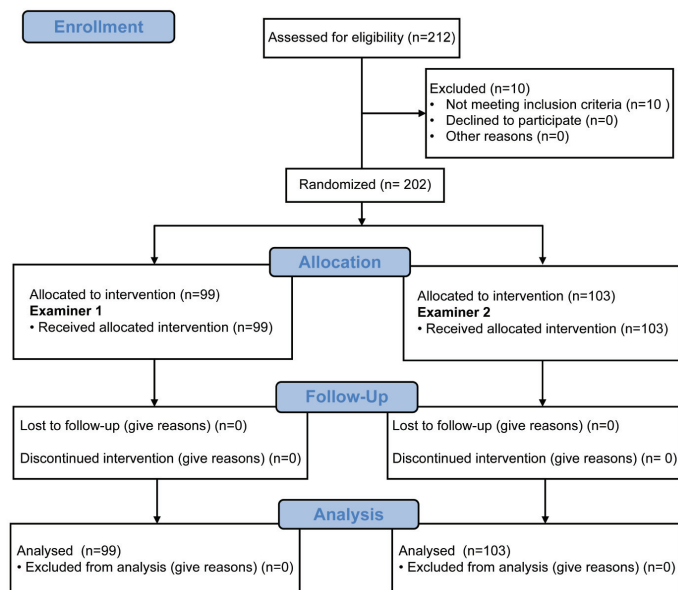
In this prospective study, patients from the Division of Mastology at the Department of Gynaecology, Federal University of São Paulo (UNIFESP) School of Medicine, Brazil, were randomly subjected to clinical breast examinations without (test 1) or with the Sensifemme® glove (test 2) by two different examiners (examiners 1 and 2). All patients underwent subsequent bilateral breast ultrasonography (test 3) to confirm or rule out the physical examination findings; this method is gold standard for diagnosis [Table/Fig-1]. The examiners were blinded to the results of the imaging tests. Ultrasonography was performed by a single observer (examiner 3) to decrease the false-positive rate. The Sensifemme® glove was developed by the Biotechnology Department of University of Alicante, Spain [Table/Fig-2]. The sample size was calculated using a type I error of 0.05, power of 0.9 and proportion of nodules diagnosed with glove unknown.

Participants

Female patients aged 16 years and older were included, while patients with current or previous diagnoses of breast cancer were excluded. All participants signed an informed consent form, and the Ethics Committee of the UNIFESP approved the study. All the procedures followed were in accordance with the ethical standards of the responsible committee on human experimentation (institutional or regional) and with the Helsinki Declaration of 1975 that was revised in 2000.

Study End-points

The primary end-point was the success rate of diagnosing breast nodules using the glove. The secondary end-points were the sensitivity, specificity, accuracy and the positive and negative predictive values of the glove, as well as the concordance of conventional clinical examination with that using either the glove or ultrasonography. Other secondary end-points included the calculated learning curve



[Table/Fig-1]: Study design to evaluate the clinical efficacy of using Sensifemme® glove in the diagnosis of breast nodules. Patients with and without nodules underwent tests 1, 2, and 3 by two different examiners (1 and 2).



[Table/Fig-2]: The Sensifemme® glove used in the study. The device is made from the same material as other gloves and marketed for improving the detection of breast lumps.

for using the glove and the inter-observer variability when using the device.

STATISTICAL ANALYSIS

The following parameters were evaluated for assessing the validity of tests 1 and 2: sensitivity, specificity, accuracy, positive predictive value, and negative predictive value. The Chi-square (χ^2) test was used to compare the observed and expected values and to assess whether the differences between values were likely to be actual or coincidental. The results of tests 1, 2, and 3 were compared with respect to the presence or absence of nodules, and the p-value <0.05 was considered statistically significant.

Analysis of the reproducibility of the diagnostic test was performed using the kappa concordance index. The ranges of the kappa values and the degree of concordance between each range used were as follows: less than 0.00: no concordance; 0.00–0.20: poor concordance; 0.21–0.40: fair concordance; 0.41–0.60: moderate concordance; 0.61–0.80: good concordance; 0.81–0.99: excellent concordance; and 1.00: perfect concordance [15]. All data were tabulated in a Windows Excel spreadsheet (Microsoft Excel 2011) and statistically analysed using Minitab software version 17.3.

RESULTS

The study evaluated 202 patients with a mean age of 43.7 years; 152 patients were found to have breast nodules and 50 patients did not. Moreover, 298 breast lesions were diagnosed after clinical examination and imaging, representing 1.96 nodules per subject.

The mean size of the nodules was 1.5 cm and the mean distance of the nodule from the skin was 0.68 cm; both were measured by ultrasonography. The diagnosed lesions were predominantly nodular; 80% were solid nodules while 20% were cysts. Examiners 1 and 2 inspected a similar number of patients (99 and 103, respectively). The patients' characteristics were homogeneous with respect to age, breast size, and the number of nodules present.

Diagnostic Test Results

In total, 161 nodules were detected by conventional clinical examination, while 203 were detected using the glove. This indicated a 14% increase in the rate of diagnosis of nodules when using the glove, given that the total number of nodules found by ultrasonography was 298 [Table/Fig-3]. The sensitivity, specificity and accuracy for subjects examined conventionally or using the glove are shown in [Table/Fig-4]. Comparing the detection of breast nodules when using tests 1, 2 and 3 showed that using the glove increased the rate of diagnosis; however, the results were inferior to those achieved with ultrasonography.

Variables	Clinical examination TEST 1	Clinical examination with the Sensifemme® glove TEST 2	Ultrasound TEST 3
Nodule present (TP)	161	203	298
Nodule absent (TN)	39	29	50

[Table/Fig-3]: Diagnoses of True-Positive (TP) and True-Negative (TN) findings breast nodules with clinical examination, clinical examination with the Sensifemme® glove, and breast ultrasonography.

Results of diagnostic tests	Clinical examination (TEST 1)	Clinical examination with the Sensifemme® glove (TEST 2)
Sensitivity	54%	68%
Specificity	78%	58%
Accuracy	57%	66%
Positive predictive value	93%	90%
Negative predictive value	22%	23%
False-positive	22%	42%
False-negative	46%	31%
True-positive	54%	68%
True-negative	78%	58%

[Table/Fig-4]: Results of the diagnostic tests with clinical examination (test 1) and clinical examination with the Sensifemme® glove (test 2).

Statistical analysis revealed significant differences between tests 1 and 3 ($\chi^2= 370.795$; $p<0.001$), between tests 2 and 3 ($\chi^2= 127.896$; $p<0.001$) and between tests 1 and 2 ($\chi^2 = 33.877$; $p<0.001$). These results show that using gloves results in superior efficacy in diagnosing breast nodules compared to conventional clinical examination. The sensitivities of clinical examinations with and without gloves decreased significantly as the distance between the nodule and the skin increased. This shows the difficulty of detecting small, deep changes in fibroglandular tissues during physical breast examination. However, the sensitivity of the examination when using the glove was far superior to conventional clinical examination, especially for nodules up to 0.5 cm deep (83% vs. 68%, respectively) [Table/Fig-5]. The size of the nodule was also a variable that directly influenced the sensitivity of diagnostic tests 1 and 2; the largest differences occurred with nodules ≤ 1.0 cm, with sensitivities of 21% and 44%, respectively [Table/Fig-6].

Concordance between Diagnostic Tests

The concordance between tests 1 and 2 was moderate, with a kappa index of 0.58. However, the analysis of concordance between clinical examination and ultrasonography (test 1 vs. test 3) and between examination with the glove and ultrasonography (test 2 vs. test 3) produced kappa indices of 0.15 and 0.16, respectively, indicating poor concordance.

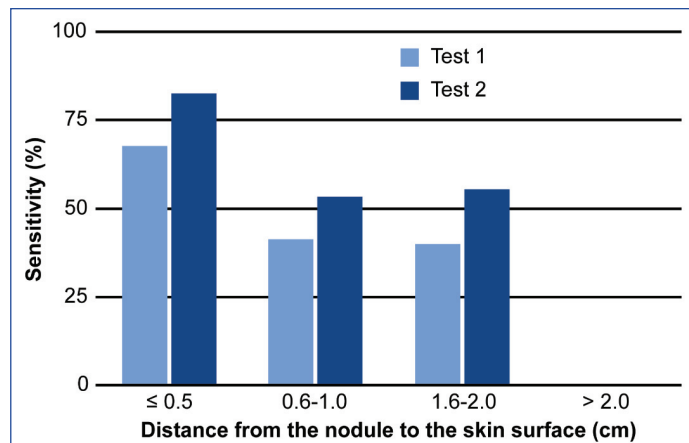
Learning Curve for Performing Clinical Breast Examinations with the Glove

The examiners' learning curve for using the glove was calculated considering the accuracy of nodule detection in relation to the number of patients examined. The accuracy of physical examination with the glove was much lower in the first 25 patients examined (36%) but increased throughout the duration of the study. When analysing for the accuracy of nodule diagnosis with the glove, a rising curve was observed representing the first 100 women, after which the accuracy plateaued [Table/Fig-7]. Compared with the overall accuracy of conventional clinical examination (57%), the accuracy when using the glove was superior to that when performing conventional clinical examination after examining only 100 patients.

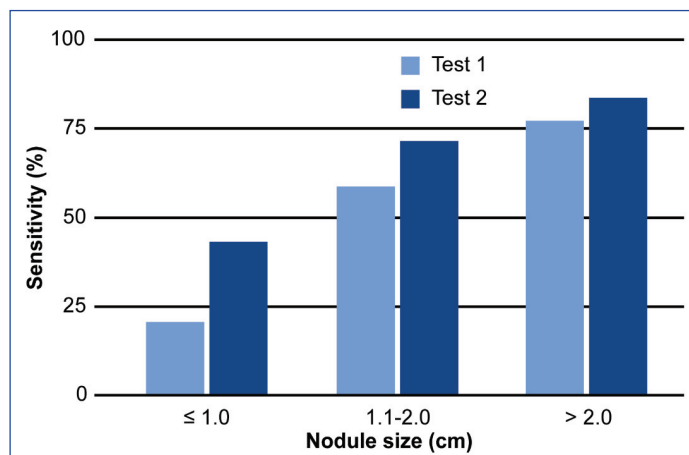
Inter-observer Variability in the Clinical Efficacy of Breast Examinations with the Glove

The accuracies of examinations with the gloves by examiners 1 and 2 were 64% and 69%, respectively, with no discordance between

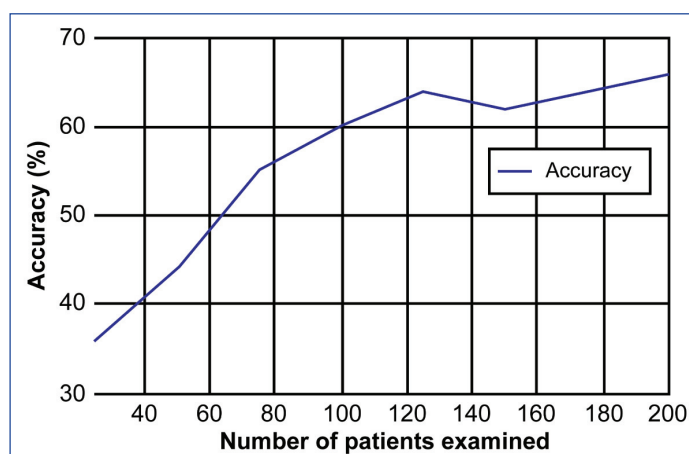
them; both examiners showed superior clinical examination accuracy when using gloves compared to conventional examination (57%). The kappa indices of examiners 1 and 2 when comparing to ultrasonography were 0.12 and 0.20, respectively. Hence, the diagnostic tests correlated poorly with ultrasonography regardless of the examiner.



[Table/Fig-5]: Comparison of the sensitivity of the diagnosis of breast nodules in tests 1 (conventional breast examination) and 2 (examination using the Sensifemme® glove) in relation to the distance from the nodule to the skin surface, as measured by ultrasonography.



[Table/Fig-6]: Comparison of the sensitivity of the diagnosis of breast nodules in tests 1 (conventional breast examination) and 2 (examination using the Sensifemme® glove) in relation to nodule size.



[Table/Fig-7]: The learning curve for clinical examination using the Sensifemme® glove: accuracy in relation to the number of patients examined.

DISCUSSION

The greater sensitivity of clinical breast examination with the glove (68% for test 2 vs. 54% for test 1) is likely the result of the easier gliding of the glove along the breast tissue, facilitating the detection

of nodules during the physician's examination. However, this was at the expense of an increased rate of false-positives (42% using test 2 compared to 22% using test 1), which can lead to prescribing complementary tests, short clinical follow up periods, unnecessary biopsies, increased costs, and patient anxiety.

The specificity of the examination with test 2 was lower compared to the control group (58% vs. 78%, respectively). The accuracy when detecting breast nodules during examination with the glove was 66%, which was significantly higher than conventional clinical examination (57%). This result illustrates a greater efficacy when using the glove. The predictive values of the study do not apply universally because they are directly influenced by the prevalence of the disease in any particular study population.

Using the glove increased the sensitivity and accuracy of detecting breast nodules by 14% and 9%, respectively, albeit with a higher rate of false-positive findings. Among the variables analysed, the distance from the nodule to the skin and the size of the lesion most influenced the sensitivity of the test. The sensitivity of the clinical examination with or without the glove decreased substantially for deeper lesions and increased in direct proportion to the nodule size. This is consistent with data from the literature [7,12,16]; however, the consistency variable was not assessed in the present study.

The high sensitivities identified in our study (54% for test 1 and 68.1% for test 2) may be due to sampling bias. Our cohort was not representative of the general population, as advanced cases and patients who experienced abnormal examination results may have been included among subjects who were referred to our study; this may have resulted in the overestimation of the sensitivity of the test compared to if it had been performed in the general population [17].

Ultrasonography is the examination of choice for palpable lesions, breasts of young patients, and dense breasts; it is also used to differentiate between solid and cystic lesions and to guide invasive procedures [18,19]. However, this technique is operator-dependent and is associated with false-positive lesions [20,21]. Moreover, the mean age of the women in the present study was 43.7 years, an age group for which the standard screening technique is mammography [22], which was not evaluated.

The use of the gloves requires a learning curve; examination of a 100 women was necessary for sufficient training to improve the detection accuracy to a level that justifies their use compared to conventional examination. The gloves are sold with the goal of increasing the sensitivity of breast self-examination, which could result in the early diagnosis of breast cancer. However, studies have shown that self-examination is not recommended for breast cancer screening [1], as detected lesions are usually symptomatic by the time they are felt and are associated with decreased odds of survival [6,23]. Conversely, early diagnosis of cancer is directly associated with the detection of subclinical lesions by mammography [6].

Breast cancer awareness is a recommended practice for health education and familiarity with one's own body. Awareness of breast diseases can sensitise patients to any changes in their breasts and direct them to seek medical care promptly [24]. Annual clinical examinations are indicated for breast cancer screening, and usually involved bilateral mammography [24,25]. To that end, the glove can make a positive impact, as it can assist in improving the accuracy of clinical examinations without diminishing the importance of mammography [25].

CONCLUSION

Using the glove during clinical examination of the breast for lumps is feasible, beneficial and inexpensive; however, it is not a substitute

for traditional breast cancer screening. The glove can be used as an additional tool to improve the efficacy of clinical examination, and to alert the individual to seek medical advice when any change is detected.

Using the glove to perform clinical breast examinations was more effective than conventional examination for the diagnosis of breast nodules, and exhibited increased sensitivity and accuracy. However, this was at the expense of a higher false-positive rate, which can lead to additional tests, unnecessary biopsies, and patient anxiety. The concordance of the clinical examinations (with or without the glove) with ultrasonography is weak independent of the examiner. Moreover, there is a steep learning curve when using the glove.

ACKNOWLEDGEMENTS

The authors wish to acknowledge all participants who kindly agreed to participate in our survey.

REFERENCES

- [1] Nelson HD, Tyne K, Naik A, Bougatsos C, Chan BK, Humphrey L. Screening for breast cancer: An update for the U.S. Preventive Services Task Force. *Ann Intern Med.* 2009;151(10):727-37.
- [2] Gøtzsche PC, Jørgensen KJ. Screening for breast cancer with mammography. *Cochrane Database Syst Rev.* 2013;6:CD001877.
- [3] Kösters JP, Gøtzsche PC. Regular self-examination or clinical examination for early detection of breast cancer. *Cochrane Database Syst Rev.* 2003;2:CD003373.
- [4] Weiss NS. Breast cancer mortality in relation to clinical breast examination and breast self-examination. *Breast J.* 2003;9(Suppl 2):S86-89.
- [5] Corbex M, Burton R, Sancho-Garnier H. Breast cancer early detection methods for low and middle income countries, a review of the evidence. *Breast.* 2012;21(4):428-34.
- [6] Miller AB, Wall C, Baines CJ, Sun P, To T, Narod SA. Twenty five year follow-up for breast cancer incidence and mortality of the Canadian National Breast Screening Study: randomised screening trial. *BMJ.* 2014;348:g366.
- [7] Barton MB, Harris R, Fletcher SW. The rational clinical examination. Does this patient have breast cancer? The screening clinical breast examination: should it be done? How? *JAMA.* 1999;282(13):1270-80.
- [8] Ravi C, Rodrigues G. Accuracy of clinical examination of breast lumps in detecting malignancy: A retrospective study. *Indian J Surg Oncol.* 2012;3(2):154-57.
- [9] Semiglazov VF, Moiseyenko VM, Bavli JL, Migmanova NSh, Seleznyov NK, Popova RT, et al. The role of breast self-examination in early breast cancer detection (results of the 5-years USSR/WHO randomized study in Leningrad). *Eur J Epidemiol.* 1992;8(4):498-502.
- [10] Semiglazov VF, Manikhas AG, Moiseenko VM, Protsenko SA, Kharikova RS, Seleznev IK, et al. Results of a prospective randomized investigation Russia (St. Petersburg)/WHO to evaluate the significance of self-examination for the early detection of breast cancer. *Vopr Onkol.* 2003;49(4):434-41.
- [11] Gao DL, Thomas DB, Ray RM, Wang WW, Allison CJ, Chen FL, et al. Randomized trial of breast self-examination in 266,064 women in Shanghai [Article in Chinese]. *Zhonghua Zhong Liu Za Zhi.* 2005;27(6):350-54.
- [12] McCready T, Littlewood D, Jenkinson J. Breast self-examination and breast awareness: a literature review. *J Clin Nurs.* 2005;14(5):570-78.
- [13] Verardi S, Palla L, Brinci L, Cerretani C, Tati E, Petrocelli M, et al. A new device for breast self-examination. *J Plast Dermatol.* 2010;6(1):1-6.
- [14] Harding E. Warning over £25 glove 'that helps detect breast cancer': Charities say evidence of its effectiveness is limited. *Daily Mail.* 2012; Sect Health:1 (col. 1). [cited 2012 Nov7]. Available from: <http://www.dailymail.co.uk/health/article-2229182>.
- [15] Landis JR, Koch GG. The measurement of observer agreement for categorical data. *Biometrics.* 1977;33(1):159-74.
- [16] Fletcher SW, O'Malley MS, Pilgrim CA, Gonzalez JJ. How do women compare with internal medicine residents in breast lump detection? *J Gen Intern Med.* 1989;4(4):277-83.
- [17] Lijmer JG, Mol BW, Heisterkamp S, Bossel GJ, Prins MH, Van der Meulen JH, et al. Empirical evidence of design-related bias in studies of diagnostic tests. *JAMA.* 1999;282(11):1061-66.
- [18] Iruhe NK, Adekola OO, Awosanya GO, Adeyomoye AO, Olowoyeye OA, Awolola NA, et al. The accuracy of ultrasonography in the diagnosis of breast pathology in symptomatic women. *Niger Q J Hosp Med.* 2012;22(4):236-39.
- [19] Gonzaga MA. How accurate is ultrasound in evaluating palpable breast masses? *Pan Afr Med J.* 2010;7:1.
- [20] Uematsu T. Ultrasonographic findings of missed breast cancer: Pitfalls and pearls. *Breast Cancer.* 2014;21(1):10-19.
- [21] Merry GM, Mendelson EB. Update on screening breast ultrasonography. *Radiol Clin N Am.* 2014;52(3):527-37.
- [22] Mainiero MB, Lourenco A, Mahoney MC, Newell MS, Bailey L, Barke LD, et al. ACR appropriateness criteria breast cancer screening. *J Am Coll Radiol.* 2013;10(1):11-14.
- [23] Ma I, Dueck A, Gray R, Wasif N, Giurescu M, Lorans R, et al. Clinical and self breast examination remain important in the era of modern screening. *Ann Surg Oncol.* 2012;19(5):1484-90.

- [24] NCCN Clinical Practice Guidelines in Oncology. Breast cancer screening and diagnosis. Version 2.2016. Fort Washington: National Comprehensive Cancer Network; 2016. [cited 2016 Oct17]. Available from: http://www.nccn.org/professionals/physician_gls/f_guidelines.asp.
- [25] Provencher L, Hogue JC, Desbiens C, Poirier B, Poirier E, Boudreau D, et al. Is clinical breast examination important for breast cancer detection? *Curr Oncol*. 2016;23(4):e332-39.

PARTICULARS OF CONTRIBUTORS:

1. Gynaecologist and Mastologist, Department of Gynaecology, Universidade Federal de São Paulo, Escola Paulista de Medicina (Unifesp-EPM), São Paulo, Brazil.
2. Gynaecologist and Mastologist, Department of Gynaecology, Universidade Federal de São Paulo, Escola Paulista de Medicina (Unifesp-EPM), São Paulo, Brazil.
3. Gynaecologist and Mastologist, Department of Gynaecology, Universidade Federal de São Paulo, Escola Paulista de Medicina (Unifesp-EPM), São Paulo, Brazil.
4. Gynaecologist and Mastologist, Department of Gynaecology, Universidade Federal de São Paulo, Escola Paulista de Medicina (Unifesp-EPM), São Paulo, Brazil.
5. Professor, Department of Gynaecology, Universidade Federal de São Paulo, Escola Paulista de Medicina (Unifesp-EPM), São Paulo, Brazil.
6. Professor, Department of Gynaecology, Universidade Federal de São Paulo - Escola Paulista de Medicina (Unifesp-EPM), São Paulo, Brazil.

NAME, ADDRESS, E-MAIL ID OF THE CORRESPONDING AUTHOR:

Dr. Vanessa Monteiro Sanvido,
Universidade Federal de São Paulo, Escola Paulista de Medicina. Rua Napoleão de Barros,
608. Vila Clementino-São Paulo-SP Brazil CEP 04024-008.
E-mail: vanessasanvido@gmail.com

Date of Submission: **Nov 21, 2016**Date of Peer Review: **Feb 14, 2017**Date of Acceptance: **Feb 14, 2017**Date of Publishing: **Jun 01, 2017****FINANCIAL OR OTHER COMPETING INTERESTS:** None.