

Received: 2016.10.29
Accepted: 2016.12.19
Published: 2017.07.29

Performance of Cardiac Magnetic Resonance Imaging for Diagnosis of Myocarditis Compared with Endomyocardial Biopsy: A Meta-Analysis

Authors' Contribution:
Study Design A
Data Collection B
Statistical Analysis C
Data Interpretation D
Manuscript Preparation E
Literature Search F
Funds Collection G

ABCDEF G 1 **Shuheng Wei**
BCDEF 2 **Jing Fu**
BCDEF 3 **Liang Chen**
BCDEF 1 **Shujing Yu**

1 Department of CT Diagnostics, The Central Hospital of Cangzhou, Cangzhou, Hebei, P.R. China
2 Department of Food and Bioengineering, Cangzhou Technical College, Cangzhou, Hebei, P.R. China
3 Second Department of Surgical Oncology, The Central Hospital of Cangzhou, Cangzhou, Hebei, P.R. China

Corresponding Author: Shuheng Wei, e-mail: cmri2016@163.com
Source of support: Departmental sources

Background: Cardiac magnetic resonance imaging (CMRI) is considered to be useful for the diagnosis of myocarditis, and the Lake Louise Criteria (LLC) has been proved to be of significance as the standard of diagnosis. However, the diagnostic performance of LLC-based CMRI for myocarditis compared with endomyocardial biopsy (EMB) has not been quantitatively evaluated in a meta-analysis.





Material/Methods: The databases PubMed, Cochrane's Library, and EMBASE were searched to identify studies on LLC and its individual components for the diagnosis of myocarditis. EMB was the control reference. The sensitivity, specificity, and positive and negative diagnostic likelihood ratios were calculated with a random-effects model. The area under the receiver operating characteristic curve (AUC) was estimated to show overall effectiveness.

Results: We included 9 cohorts (614 patients) of patients with suspected MC. The combined sensitivities, specificities, and AUCs for T1-weighted global relative enhancement were 0.66, 0.73, and 0.71; for T2-weighted edema ratio they were 0.52, 0.73, and 0.72; for the late gadolinium enhancement, they were 0.70, 0.57, and 0.67; and for LLC-based CMRI they were 0.70, 0.56, and 0.70, respectively. Subgroup analysis indicated that the sensitivities, specificities, and diagnostic accuracies of LLC and its individual component-based CMRI seemed to be similar in patients with acute or chronic myocarditis. Results of the Deeks' funnel plot asymmetry test showed no significant publication bias among the studies.

Conclusions: CMRI based on LLC or its individual components seems to have moderate accuracy in diagnosis of acute or chronic myocarditis.

MeSH Keywords: **Diffusion Magnetic Resonance Imaging • Meta-Analysis • Myocarditis**

Full-text PDF: <https://www.medscimonit.com/abstract/index/idArt/902155>

 2914  3  4  39



Background

Myocarditis (MC) is now considered as an inflammatory cardiovascular disease that is complicated by heterogeneous clinical presentations [1]. The incidence and mortality associated with MC is difficult to estimate since endomyocardial biopsy (EMB), the criterion standard for the diagnosis of MC, is not commonly used in clinical practice [2]. Results of autopsy studies show that MC accounts for the causes of sudden cardiac death in 2~42% of young cases [3,4], while results of studies based on biopsy showed that MC contributes to 9%~16% of causes for adult patients with dilated cardiomyopathy (DCM) [5], and more than 40% for children with DCM [6]. MC is characterized by histopathological features associated with chronic myocardial inflammation, including myocardial fibrosis, ventricular remodeling, and subsequent cardiac dysfunction, which are not specific to MC [7]. Accordingly, diagnosis of MC is an enormous challenge in cardiovascular practice [8]. Because MC can be fatal, early diagnosis of MC is important for the prevention and treatment of the disease [1,2]. The clinical manifestations of MC vary according to the severity of the disease. Moreover, the symptoms and signs of patients with MC are usually non-specific, which underlies the importance of additional medical examinations for the diagnosis of MC [2,9].

The criterion standard for the diagnosis of MC is EMB [10]. However, the application of EMB in clinical practice is limited since it is an invasive procedure that causes discomfort and there is an increased risk of severe complications [10]. Recent studies suggested that cardiac magnetic resonance imaging (CMRI) may be a useful noninvasive diagnostic tool for patients with suspected MC [7]. Based on the results of accumulated studies, 3 CMRI-related parameters have been suggested to be of diagnostic efficacy for MC, including T1-weighted global relative enhancement (gRE), T2-weighted edema ratio of the myocardium (ER), and late gadolinium enhancement (LGE) in contrast CMRI [8,9,11]. These parameters are considered to be reflective of myocardial hyperemia, edema, necrosis, and fibrosis, which are the major histopathological characteristics of myocardium in patients with MC [12]. Moreover, a subsequent expert consensus proposed that the diagnostic efficacy of CMRI for MC could be further improved if 2 of the 3 above parameters were found to be positive, which are known as the Lake Louise Criteria (LLC) [11].

However, the LLC were based on studies with limited sample sizes [13–17]. More importantly, these studies compared the diagnostic efficacy of LLC and its individual components with clinically-diagnosed MC rather than EMB-diagnosed MC [13–17]. Therefore, the diagnostic performance of LLC-based CMRI for MC as compared with EMB deserves further evaluation. Since the proposal of LLC, some studies [18–24] have been published that investigated the potential diagnostic efficacy of LLC and

its individual components-based CMRI for patients with MC. However, the results were not always consistent. The aim of the present study was to quantitatively evaluate the diagnostic performance of LLC-based CMRI for MC in a meta-analysis, as compared with the criterion standard of EMB.

Material and Methods

Database searching

We performed this systematic review and meta-analysis following the guidance of the Preferred Reporting Items for Systematic Reviews and Meta-Analyses (PRISMA) Statement [25] and the Cochrane Handbook [26]. The studies were identified through computerized searching of the databases PubMed (MEDLINE), Cochrane Library, and EMBASE using the terms “magnetic resonance”, “magnetic resonance imaging”, MR, MRI, or CMRI, paired with “myocarditis” and “endomyocardial biopsy” or EMB. The search was limited to studies in humans and the last search was completed on 1 August 2016. We also manually searched the reference lists of original and review articles.

Inclusion and exclusion criteria

We evaluated the full text of each article with the following inclusion criteria: (1) original study published as full-length article in English; (2) designed as prospective or retrospective cohorts; (3) including patients suspected of acute MC (AMC) or chronic MC (CMC); (4) aimed to evaluate the diagnostic performance of CMR for MC based on LLC or its individual component (gRE, ER and LGE); (5) using EMB as the referenced standard for the diagnosis of MC according to the Dallas Criteria [2]; and (6) reported the essential data so that true- and false-positive values, and true- and false-negative values, could be extracted or calculated and a 2×2 table created. The definitions of AMC and CMC were consistently applied in the original studies according to duration of symptoms from onset to hospital admission (AMC within 14 days; CMC >14 days) [24]. Specifically, Dallas Criteria defined the histological evidence of MC as inflammatory infiltrates within the myocardium associated with myocyte degeneration and necrosis of non-ischemic origin, and quantitatively defined as ≥ 14 leucocytes/mm², which include up to 4 monocytes/mm² with the presence of CD3-positive T lymphocytes ≥ 7 cells/mm² [2]. Review articles and duplicate publications were excluded.

Data extraction and quality assessment

Two authors independently performed the literature search, data extraction, and quality assessment based on the inclusion criteria. Discrepancies were resolved by consensus. Data extracted from each study included: first author, published

year, location, number of participants, mean ages, proportion of male patients, AMC or CMC, characteristics of CMRI scanners, and CMRI variables analyzed. True- and false-positive data, and true- and false-negative data, obtained from LLC or its individual components for the diagnosis of MC, were extracted for further evaluation. For studies that reported the results of 2 or more cohorts without overlapping participants, multiple sets of data were extracted. We evaluated the quality of the included studies using QUADAS-2 (Quality Assessment Tool for Diagnostic Accuracy Studies) [27]. Each study's risk of bias and applicability were rated as low, high, or unclear for each domain.

Statistics

The summary sensitivity, specificity, and positive and negative diagnostic likelihood ratios (DLRs) were calculated from the 2×2 tables with corresponding 95% confidence intervals (CIs). The efficacy of LLC-based CMRI for the diagnosis of MC was measured by the diagnostic odds ratio [OR], which is the ratio of the odds of a correct diagnosis to the odds of a misdiagnosis [28]. The area under the receiver operating characteristic (AUC) curve derived from the data was taken to reflect the overall effectiveness of each quantitative method. Inter-study heterogeneity was formally tested using Cochrane's Q test, and significant heterogeneity was defined as $P < 0.10$. We also calculated the I^2 statistic, which describes the percentage of total variation across studies that is due to heterogeneity rather than chance; $I^2 > 50\%$ was considered significant heterogeneity [29]. We used a random-effects model, rather than a fixed-effects model, to estimate the overall effect. This is because the random-effects model is a more conservative method that takes into account that study heterogeneity can vary beyond chance, and the results are thus more generalizable. Subgroup analyses were performed to summarize the sensitivity, specificity, and diagnostic accuracy of LLC and its individual component-based CMRI for the diagnosis of AMC and CMC. Deeks' funnel plot asymmetry test was used to evaluate publication bias. Statistical analyses were performed using STATA 12.0. All statistical tests were 2-sided, with $P < 0.05$ indicating statistical significance.

Results

Results of literature searching

Initially, 302 records were retrieved from the primary database search, and the process of study identification was summarized in Figure 1. Briefly, 21 studies were detected based on title and abstract screening, and 7 studies were finally included after reviewing the full texts of the 21 articles. Fourteen studies were further excluded because 5 were not relevant studies,

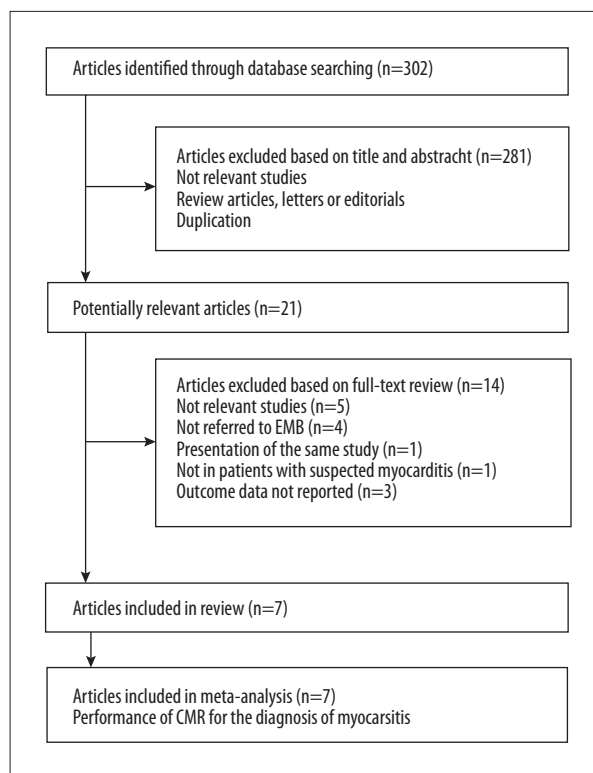


Figure 1. Flow diagram of search results and study selection.

4 did not use EMB as a referenced standard, 3 did not include the outcome data, 1 was not in patients with suspected MC, and 1 was a duplicate of an included study.

Study characteristics and quality evaluation

Overall, 7 studies including 614 patients with suspected MC were included in our meta-analysis [18–24]. Since 2 of the studies [22,24] included both the cohorts of AMC and CMC, 9 cohorts were included for subsequent quantitative analyses. The characteristics of the included studies are presented in Table 1. The mean age of the patients included in each cohort varied from 40.0 to 58.4 years, with the proportions of males ranging from 32.9% to 87.0%. All of the included patients underwent CMRI with a 1.5T scanner, and 1 study also provided CMRI data with a 3.0T scanner [22]. To keep the consistency of the CMRI technique applied and avoiding repeated inclusion of the same study cohort, only the CMRI data with the 1.5T scanner were included for analysis. Biventricular sampling was applied in EMB in 3 of the studies [18,20,24]. The quality of the eligible studies was assessed according to the QUADAS-2 criteria (Table 2). All of the studies were assessed as having a low risk of bias for patient selection, index test, and reference standard, although 3 studies did not report the time intervals between CMRI examination and EMB [18,19,22].

Table 1. Characteristics of included studies.

Author year	Country	Patients cohort	Number of participants	Mean age (years)	Male (%)	EMB sampling	Scanner brand	CMR variables analyzed
Mahrholdt 2006	Germany	Suspected MC	128	41.2	74.5	LGE region or BV	Siemens 1.5T	LGE
Yilmaz 2008	Germany	Suspected MC	69	58.4	32.9	RV, LV or BV	Siemens 1.5T	LGE
Gutberlet 2008	Germany	Suspected CMC	83	44.8	33.7	IVS	GE 1.5T	gRE, ER, LGE, LLC
Sramko 2013	Czech	Suspected CMC	42	43.9	71.4	RV	Siemens 1.5T	gRE, ER, LGE, LLC
Lurz 2014-AMC	Germany	Suspected AMC	70	44.0	87.0	LV	Philips 1.5T	gRE, ER, LGE, LLC
Lurz 2014-CMC	Germany	Suspected CMC	62	52.0	69.4	LV	Philips 1.5T	gRE, ER, LGE, LLC
Bohnen 2015	Germany	Suspected MC	31	51.0	77.0	RV or LV	Philips 1.5T	LGE, LLC
Lurz 2016-AMC	Germany	Suspected AMC	61	40.0	83.0	BV	Philips 1.5T	LGE, LLC
Lurz 2016-CMC	Germany	Suspected CMC	68	46.0	81.0	BV	Philips 1.5T	LGE, LLC

AMC – acute myocarditis; CMC – chronic myocarditis; MC – myocarditis; EMB – endomyocardial biopsy; CMR – cardiac magnetic resonance; ER – edema ratio; gRE – global relative enhancement; LGE – late gadolinium enhancement.

Table 2. Quality assessment of included studies with QUADAS-2 Scores.

Study	Risk of bias				Applicability concerns		
	Patient selection	Index test	Reference standard	Flow and timing	Patient selection	Index test	Reference standard
Mahrholdt 2006	Low	Low	Low	Unclear	Low	Low	Low
Yilmaz 2008	Low	Low	Low	Unclear	Low	Low	Low
Gutberlet 2008	Low	Low	Low	Low	Low	Low	Low
Sramko 2013	Low	Low	Low	Low	Low	Low	Low
Lurz 2014-AMC	Low	Low	Low	Unclear	Low	Low	Low
Lurz 2014-CMC	Low	Low	Low	Unclear	Low	Low	Low
Bohnen 2015	Low	Low	Low	Low	Low	Low	Low
Lurz 2016-AMC	Low	Low	Low	Low	Low	Low	Low
Lurz 2016-CMC	Low	Low	Low	Low	Low	Low	Low

Meta-analysis of LLC-based CMRI for diagnosis of MC

Four of the cohorts [19,21,22], comprising 257 patients with suspected MC, evaluated the performance of gRE-based CMRI for the diagnosis of MC. The summary sensitivity was 0.66 (95% CI: 0.51–0.78) and the specificity was 0.73 (95% CI: 0.30–0.94) (Figure 2A). The positive DLR was 2.40 (95% CI: 0.80–7.60) and the negative DLR was 0.47 (95% CI: 0.34–0.64). Significant

heterogeneity existed among the included studies for summary sensitivity and specificity ($I^2=61.0\%$ and 93.3% , respectively). The summary diagnostic odds ratio was 5.0 (95% CI: 1.0–21.0) and the summary AUC was 0.71 (95% CI: 0.67–0.75) according to the synthesized ROC curve (Figure 3A).

For the diagnostic efficacy of ER-based CMRI, 4 cohorts [19,21,22] comprising 257 patients with suspected MC were

included. The summary sensitivity was 0.52 (95% CI: 0.22–0.81) and the specificity was 0.73 (95% CI: 0.57–0.85) (Figure 2B). The positive DLR was 2.0 (95% CI: 1.3–3.0) and the negative DLR was 0.65 (95% CI: 0.36–1.16). Significant heterogeneity existed among the included studies for summary sensitivity and specificity ($I^2=90.5\%$ and 60.9% , respectively). The summary diagnostic odds ratio was 3.0 (95% CI: 1.0–8.0), and the summary AUC was 0.72 (95% CI: 0.68–0.76) according to the synthesized ROC curve (Figure 3B).

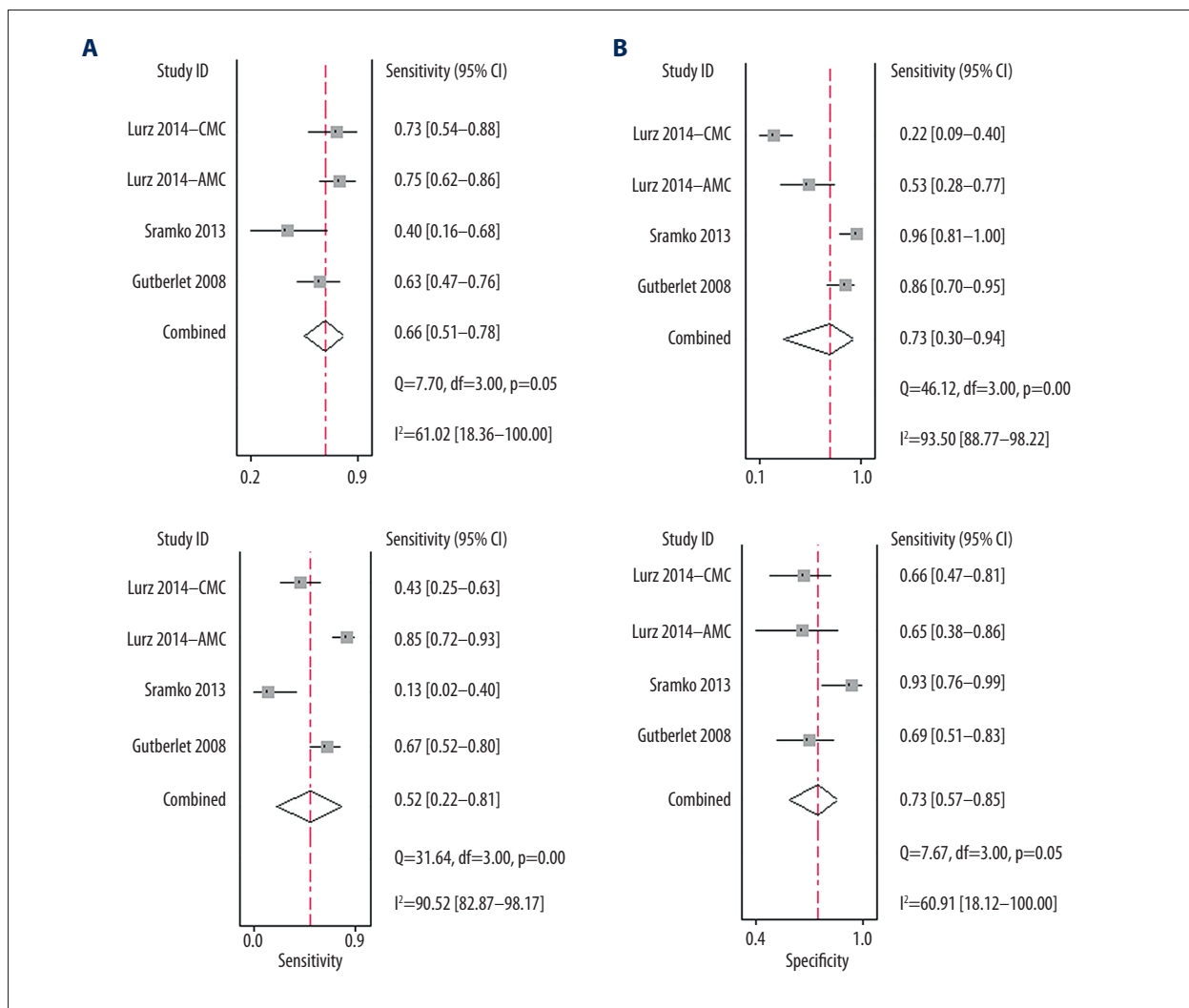
For the diagnostic efficacy of LGE-based CMRI, all of the 9 cohorts (614 patients) of suspected MC patients were included. The summary sensitivity was 0.70 (95% CI: 0.52–0.83) and the specificity was 0.57 (95% CI: 0.41–0.72) (Figure 2C). The positive DLR was 1.6 (95% CI: 1.1–2.4) and the negative DLR was 0.52 (95% CI: 0.30–0.92). Significant heterogeneity existed among the included studies for summary sensitivity and specificity ($I^2=91.2\%$ and 81.7% , respectively). The summary diagnostic odds ratio was 3.0 (95% CI: 1.0–8.0) and the

summary AUC was 0.67 (95% CI: 0.63–0.71) according to the synthesized ROC curve (Figure 3C).

For the diagnostic efficacy of LLC-based CMRI, 7 cohorts [19,21–24] (417 patients with suspected MC) were included. The summary sensitivity was 0.70 (95% CI: 0.62–0.76) and the specificity was 0.56 (95% CI: 0.31–0.78) (Figure 2D). The positive DLR was 1.6 (95% CI: 0.9–2.8) and the negative DLR was 0.54 (95% CI: 0.35–0.84). Significant heterogeneity existed among the included studies for specificity ($I^2=86.9\%$). The summary diagnostic odds ratio was 3.0 (95% CI: 1.0–8.0) and the summary AUC was 0.70 (95% CI: 0.66–0.74) according to the synthesized ROC curve (Figure 3D).

Subgroup analyses for LLC-based CMRI for diagnosis of AMC or CMC

Since only 1–4 cohorts were available for the evaluation of LLC and its individual component-based CMRI for the diagnosis AMC






Figure 2. Forest plots for the performance of LLC and its individual component-based CMRI for the diagnosis of MC. (A) Summary sensitivity and specificity for gRE; (B) Summary sensitivity and specificity for ER; (C) Summary sensitivity and specificity for LGE; (D) Summary sensitivity and specificity for LLC.

and CMC separately, we pooled the data for summary sensitivity, specificity, and diagnostic accuracy based on the included cohorts. The results are presented in Table 3. Generally, the sensitivities, specificities, and diagnostic accuracies of gRE-,

ER-, LGE-, and LLC-based CMRI seemed to be similar in patients with AMC and CMC.

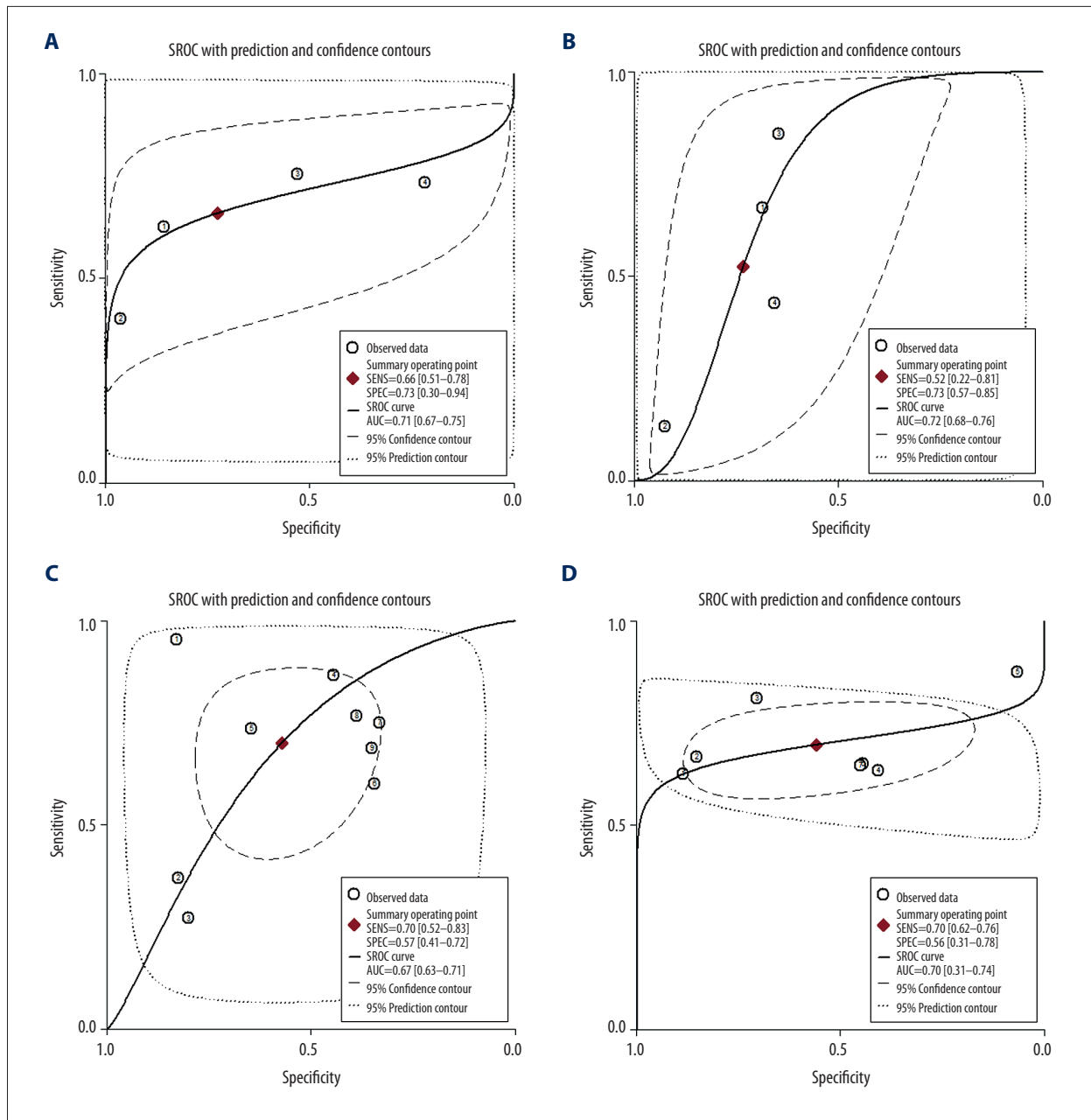


Figure 3. Summary ROC curves for the performance of LLC and its individual component-based CMRI for the diagnosis of MC. (A) Summary ROC curve for gRE; (B) Summary ROC curve for ER; (C) Summary ROC curve for LGE; (D) Summary ROC curve for LLC; Summary ROC curves were based on the bivariate random-effects model.

Publication bias

According to the Deeks' funnel plot asymmetry test, there was no significant publication bias among the studies for estimation of diagnostic efficacies of LGE- or LLC-based CMRI for MC ($P=0.10$ and 0.38 respectively; Figure 4). The publication biases the diagnostic efficacies of gRE- and ER-based CMRI were difficult to estimate because a limited number of studies were included.

Discussion

By pooling the results of 7 diagnostic studies using EMB as the referenced standard, our meta-analysis showed only moderate diagnostic efficacies of LLC and its individual component-based CMRI for MC. Specifically, the AUCs for gRE, ER, LGE, and LLC were 0.71, 0.72, 0.67, and 0.70 respectively. Moreover, subgroup analysis suggested that the sensitivities, specificities, and diagnostic accuracies of LLC and its individual component-based

Table 3. Subgroup analyses in patients with AMC or CMC.

	AMC			CMC		
	Sensitivity	Specificity	Accuracy	Sensitivity	Specificity	Accuracy
gRE	0.75	0.53	0.70	0.62	0.67	0.65
ER	0.85	0.64	0.80	0.51	0.74	0.63
LGE	0.75	0.51	0.69	0.55	0.51	0.53
LLC	0.74	0.57	0.69	0.64	0.67	0.65

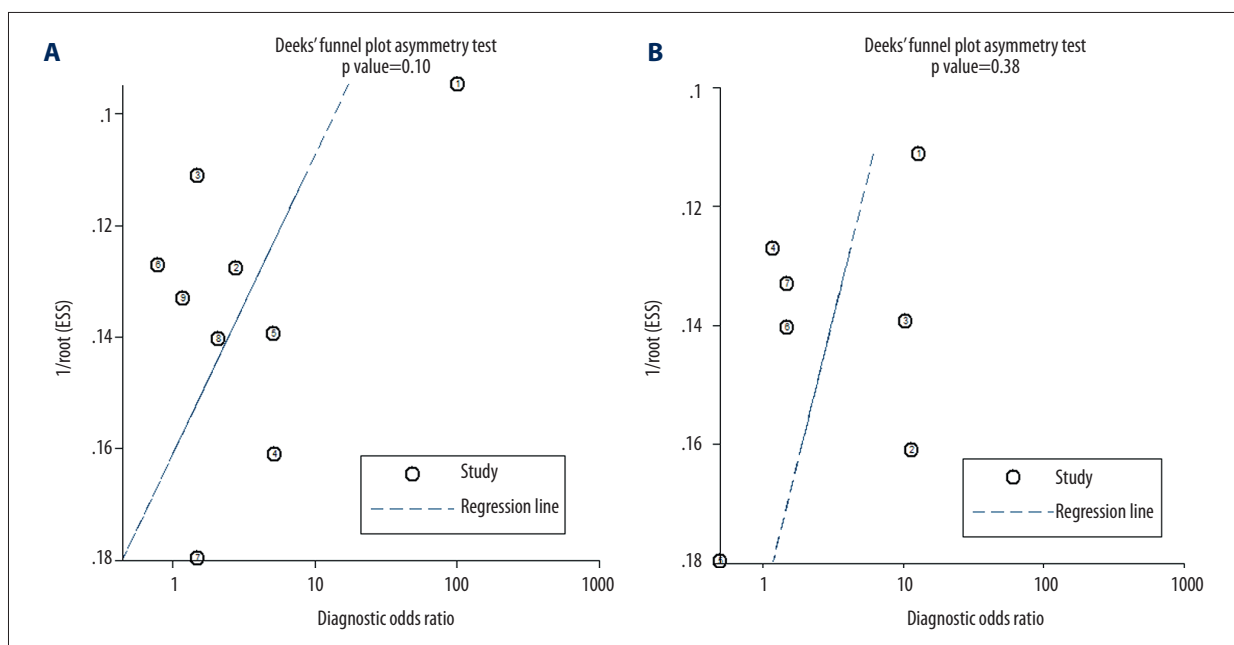


Figure 4. (A, B) Deeks' funnel plots for the assessment of publication biases for the estimations of the diagnostic efficacies of LGE- or LLC-based CMRI for MC.

CMRI seemed to be similar in patients with AMC and CMC. These results suggest that compared with EMB, the diagnostic performance of LLC and its individual component-based CMRI in patients with suspected MC is moderate. Our results highlight the need for development of novel CMRI-related parameters and novel imaging techniques for the diagnosis of MC.

Our study has clinical implications. To the best of our knowledge, this is the first meta-analysis to systematically evaluate the diagnostic performance of LLC-based CMRI in patients with suspected MC using EMB as the standard. Indeed, the previously proposed LLC for CMRI diagnosis of MC were based on small-scale studies, which mostly compared the CMRI results with clinical data [13–17]. The CMRI parameters used in the LLC were generally 3 histopathological features of myocardial inflammation, which may lack sensitivity and specificity for MC as compared with patients with other cardiovascular diseases [7,8,11]. Firstly, gRE, which indicates T1-weighted global relative enhancement and reflects myocardial hyperemia,

has been shown to be nonspecific for MC [30]. Because the signal intensity of skeletal muscle is used for the normalization of the gRE ratio, gRE in patients complicated with skeletal muscle diseases may become falsely negative [31]. Secondly, ER, which indicates the T2-weighted edema ratio and reflects the extent of myocardial edema, has also been suggested to be nonexclusive in MC and in other diseases with myocardial interstitial injury [32]. In addition, technique shortcomings, such as low signal-to-noise ratio, also limited the diagnostic accuracy of ER [33]. Lastly, LGE, which indicates late gadolinium enhancement in contrast CMRI and reflects myocardial necrosis and fibrosis, also lacks specificity and sensitivity. Since myocardial necrosis and fibrosis could be observed in many other cardiovascular diseases with myocardial injury and remodeling, LGE was not specific for MC [34,35]. Moreover, for patients with moderate MC, the extent of myocardial necrosis and fibrosis may be not significant enough to be detected by LGE. In summary, based on these limitations of the components of LLC, it was not surprising to find that CMRI based

on LLC and its components were moderately accurate for diagnosis in patients with suspected MC. Although a previous consensus proposed to combine these 3 techniques and apply 2 of 3 positive as the diagnostic standard to improve overall diagnostic accuracy [11], results of our meta-analysis did not support that CMRI based on LLC had better diagnostic efficacy than CMRI based on the individual components.

Some previous studies suggest that CMRI based on LLC may confer better diagnostic accuracy in patients with AMC than in those with CMC [22,24], because patients with AMC typically have more significant histopathological features of MC, such as myocardial hyperemia, edema, necrosis, and fibrosis. Although limited data could be included, our subgroup analyses by pooling the data from AMC and CMC studies did not support that CMRI based on LLC has better diagnostic performance in AMC, indicating that the diagnostic efficacy of LLC-based CMRI may be consistently moderate in AMC and CMC. These results should be interpreted with caution, and studies with adequate statistical power are needed to further confirm our findings.

Results of our study highlights the need to develop novel imaging strategies for the diagnosis of MC. Some recent studies have suggested that T1 and T2 mapping may be superior to the conventional LLC-based CMRI in patients with suspected MC [23,24], especially in those with CMC. Additionally, the performance of some other functional imaging methods, such as 19F MRI for the detection of immune cell infiltration [36], deserves further evaluation.

Our study has limitations which should be considered when interpreting the results. Firstly, although we used EMB as the referenced standard for the diagnosis of MC, this method has

possible limitations as a criterion diagnostic standard for MC, because the diagnostic efficacy of EMB has been shown to be hampered by the potential sampling error [37] and associated lower sensitivity of the diagnostic strategy [38], as well as the influence of high interobserver variability in the interpretation of biopsy samples [39]. To overcome these limitations, some of our included studies applied biventricular biopsy. Secondly, significant heterogeneities among the included studies were detected for most of the outcomes. Differences in study characteristics, such as the duration of symptom-onset of CMRI examination, comorbidities of the patients, and protocols for CMRI analysis, may have contributed to heterogeneity. Finally, the limited number of available studies and included patients prevent us from subsequently discovering the source of the heterogeneity, and the AUCs for the diagnostic efficacy of CMRI in patients with AM or CM could not be estimated separately because limited datasets were available. However, with the limitations of EMB used in clinical studies, performing a meta-analysis like ours is an important strategy to overview the diagnostic performance of LLC-based CMRI as compared with EMB.

Conclusions

Results of our meta-analysis show that CMRI based on LLC or its individual components seems to have moderate efficacy in the diagnosis of MC in clinical practice. Novel CMRI-related parameters and imaging techniques are still needed for the diagnosis of MC.

Conflict of interest

The authors declare that they have no conflicts of interest.

References:

- Schultheiss HP, Kuhl U, Cooper LT: The management of myocarditis. *Eur Heart J*, 2011; 32: 2616–25
- Caforio AL, Pankuweit S, Arbustini E et al: Current state of knowledge on aetiology, diagnosis, management, and therapy of myocarditis: A position statement of the European Society of Cardiology Working Group on Myocardial and Pericardial Diseases. *Eur Heart J*, 2013; 34: 2636–48, 2648a–2648d
- Gore I, Saphir O: Myocarditis; A classification of 1402 cases. *Am Heart J*, 1947; 34: 827–30
- Basso C, Calabrese F, Corrado D et al: Postmortem diagnosis in sudden cardiac death victims: Macroscopic, microscopic and molecular findings. *Cardiovasc Res*, 2001; 50: 290–300
- Mason JW, O'Connell JB, Herskowitz A et al: A clinical trial of immunosuppressive therapy for myocarditis. The Myocarditis Treatment Trial Investigators. *N Engl J Med*, 1995; 333: 269–75
- Towbin JA, Lowe AM, Colan SD et al: Incidence, causes, and outcomes of dilated cardiomyopathy in children. *JAMA*, 2006; 296: 1867–76
- Yilmaz A, Ferreira V, Klingel K et al: Role of cardiovascular magnetic resonance imaging (CMR) in the diagnosis of acute and chronic myocarditis. *Heart Fail Rev*. 2013; 18: 747–60
- Biesbroek PS, Beek AM, Germans T et al: Diagnosis of myocarditis: Current state and future perspectives. *Int J Cardiol*, 2015; 191: 211–19
- Pollack A, Kontorovich AR, Fuster V et al: Viral myocarditis – diagnosis, treatment options, and current controversies. *Nat Rev Cardiol*, 2015; 12: 670–80
- Sinagra G, Anzini M, Pereira NL et al: Myocarditis in clinical practice. *Mayo Clin Proc*, 2016; 91: 1256–66
- Friedrich MG, Sechtem U, Schulz-Menger J et al: Cardiovascular magnetic resonance in myocarditis: A JACC White Paper. *J Am Coll Cardiol*, 2009; 53: 1475–87
- Childs H, Friedrich MG: Cardiovascular magnetic resonance imaging in myocarditis. *Prog Cardiovasc Dis*, 2011; 54: 266–75
- Friedrich MG, Strohm O, Schulz-Menger J et al: Contrast media-enhanced magnetic resonance imaging visualizes myocardial changes in the course of viral myocarditis. *Circulation*, 1998; 97: 1802–9
- Laissy JP, Messin B, Varenne O et al: MRI of acute myocarditis: A comprehensive approach based on various imaging sequences. *Chest*, 2002; 122: 1638–48
- Abdel-Aty H, Boye P, Zagrosek A et al: Diagnostic performance of cardiovascular magnetic resonance in patients with suspected acute myocarditis: Comparison of different approaches. *J Am Coll Cardiol*, 2005; 45: 1815–22
- Yelgec NS, Dymarkowski S, Ganame J et al: Value of MRI in patients with a clinical suspicion of acute myocarditis. *Eur Radiol*, 2007; 17: 2211–17

17. Goitein O, Matetzky S, Beinart R et al: Acute myocarditis: Noninvasive evaluation with cardiac MRI and transthoracic echocardiography. *Am J Roentgenol*, 2009; 192: 254–58
18. Mahrholdt H, Wagner A, Deluigi CC et al: Presentation, patterns of myocardial damage, and clinical course of viral myocarditis. *Circulation*, 2006; 114: 1581–90
19. Gutberlet M, Spors B, Thoma T et al: Suspected chronic myocarditis at cardiac MR: diagnostic accuracy and association with immunohistologically detected inflammation and viral persistence. *Radiology*, 2008; 246: 401–9
20. Yilmaz A, Mahrholdt H, Athanasiadis A et al: Coronary vasospasm as the underlying cause for chest pain in patients with PVB19 myocarditis. *Heart*, 2008; 94: 1456–63
21. Sramko M, Kubanek M, Tintera J et al: Utility of combination of cardiac magnetic resonance imaging and high-sensitivity cardiac troponin T assay in diagnosis of inflammatory cardiomyopathy. *Am J Cardiol*, 2013; 111: 258–64
22. Lurz P, Eitel I, Klieme B et al: The potential additional diagnostic value of assessing for pericardial effusion on cardiac magnetic resonance imaging in patients with suspected myocarditis. *Eur Heart J Cardiovasc Imaging*, 2014; 15: 643–50
23. Bohnen S, Radunski UK, Lund GK et al: Performance of t1 and t2 mapping cardiovascular magnetic resonance to detect active myocarditis in patients with recent-onset heart failure. *Circ Cardiovasc Imaging*, 2015; 8(6): pii: e003073
24. Lurz P, Luecke C, Eitel I et al: Comprehensive cardiac magnetic resonance imaging in patients with suspected myocarditis: The MyoRacer-Trial. *J Am Coll Cardiol*, 2016; 67: 1800–11
25. Moher D, Liberati A, Tetzlaff J et al: Preferred reporting items for systematic reviews and meta-analyses: The PRISMA statement. *BMJ*, 2009; 339: b2535
26. Higgins J, Green S: *Cochrane Handbook for Systematic Reviews of Interventions* Version 5.1.0. The Cochrane Collaboration 2011; www.cochranehandbook.org
27. Whiting PF, Rutjes AW, Westwood ME et al: QUADAS-2: A revised tool for the quality assessment of diagnostic accuracy studies. *Ann Intern Med*, 2011; 155: 529–36
28. Takada T, Nishiwaki H, Yamamoto Y et al: The role of digital rectal examination for diagnosis of acute appendicitis: A systematic review and meta-analysis. *PLoS One*, 2015; 10: e0136996
29. Higgins JP, Thompson SG, Deeks JJ et al: Measuring inconsistency in meta-analyses. *BMJ*, 2003; 327: 557–60
30. Eitel I, Lucke C, Grothoff M et al: Inflammation in takotsubo cardiomyopathy: Insights from cardiovascular magnetic resonance imaging. *Eur Radiol*, 2010; 20: 422–31
31. Greaves K, Oxford JS, Price CP et al: The prevalence of myocarditis and skeletal muscle injury during acute viral infection in adults: Measurement of cardiac troponins I and T in 152 patients with acute influenza infection. *Arch Intern Med*, 2003; 163: 165–68
32. Shehab AM, Strohm O: Advanced tissue characterization in non-ischemic cardiomyopathies using contrast-enhanced cardiac magnetic resonance imaging. *Saudi Med J*, 2010; 31: 115–22
33. Eitel I, Friedrich MG: T2-weighted cardiovascular magnetic resonance in acute cardiac disease. *J Cardiovasc Magn Reson*, 2011; 13: 13
34. Hulten E, Agarwal V, Cahill M et al: Presence of late gadolinium enhancement by cardiac magnetic resonance among patients with suspected cardiac sarcoidosis is associated with adverse cardiovascular prognosis: A systematic review and meta-analysis. *Circ Cardiovasc Imaging*, 2016; 9: e005001
35. Kuruvilla S, Adenaw N, Katwal AB et al: Late gadolinium enhancement on cardiac magnetic resonance predicts adverse cardiovascular outcomes in nonischemic cardiomyopathy: A systematic review and meta-analysis. *Circ Cardiovasc Imaging*, 2014; 7: 250–58
36. Pinkert S, Westermann D, Wang X et al: Prevention of cardiac dysfunction in acute coxsackievirus B3 cardiomyopathy by inducible expression of a soluble coxsackievirus-adenovirus receptor. *Circulation*, 2009; 120: 2358–66
37. Hauck AJ, Kearney DL, Edwards WD: Evaluation of postmortem endomyocardial biopsy specimens from 38 patients with lymphocytic myocarditis: Implications for role of sampling error. *Mayo Clin Proc*, 1989; 64: 1235–45
38. Chow LH, Radio SJ, Sears TD et al: Insensitivity of right ventricular endomyocardial biopsy in the diagnosis of myocarditis. *J Am Coll Cardiol*, 1989; 14: 915–20
39. Shanes JG, Ghali J, Billingham ME et al: Interobserver variability in the pathologic interpretation of endomyocardial biopsy results. *Circulation*, 1987; 75: 401–5