

## Laparoscopic ultrasonography as an alternative to intraoperative cholangiography during laparoscopic cholecystectomy

Alexandra Dili, Claude Bertrand

Alexandra Dili, Claude Bertrand, Unit of Digestive, Endocrine and General Surgery, Department of Surgery, University Hospital - Godinne, Université catholique de Louvain, CHU UCL Namur, 5530 Yvoir, Belgium

**Author contributions:** Both authors equally contributed to this paper with conception and design of the study, literature review and analysis, drafting and critical revision and editing, and final approval of the final version.

**Conflict-of-interest statement:** No potential conflicts of interest.

**Data sharing statement:** These data were extracted from the referenced articles and are already in the public domain.

**Open-Access:** This article is an open-access article which was selected by an in-house editor and fully peer-reviewed by external reviewers. It is distributed in accordance with the Creative Commons Attribution Non Commercial (CC BY-NC 4.0) license, which permits others to distribute, remix, adapt, build upon this work non-commercially, and license their derivative works on different terms, provided the original work is properly cited and the use is non-commercial. See: <http://creativecommons.org/licenses/by-nc/4.0/>

**Manuscript source:** Invited manuscript

**Correspondence to:** Dr. Claude Bertrand, Unit of Digestive, Endocrine and General Surgery, Department of Surgery, University Hospital - Godinne, Université catholique de Louvain, CHU UCL Namur, Av. Docteur G. Thérassé 1, 5530 Yvoir, Belgium. [cl.bertrand@uclouvain.be](mailto:cl.bertrand@uclouvain.be)  
Telephone: +32-81-423051  
Fax: +32-81-423051

Received: January 30, 2017

Peer-review started: February 8, 2017

First decision: March 3, 2017

Revised: April 8, 2017

Accepted: June 19, 2017

Article in press: June 19, 2017

Published online: August 7, 2017

### Abstract

#### AIM

To assess the role of laparoscopic ultrasound (LUS) as a substitute for intraoperative cholangiography (IOC) during cholecystectomy.

#### METHODS

We present a MEDLINE and PubMed literature search, having used the key-words "laparoscopic intraoperative ultrasound" and "laparoscopic cholecystectomy". All relevant English language publications from 2000 to 2016 were identified, with data extracted for the role of LUS in the anatomical delineation of the biliary tract, detection of common bile duct stones (CBDs), prevention or early detection of biliary duct injury (BDI), and incidental findings during laparoscopic cholecystectomy. Data for the role of LUS *vs* IOC in complex situations (*i.e.*, inflammatory disease/fibrosis) were specifically analyzed.

#### RESULTS

We report data from eighteen reports, 13 prospective non-randomized trials, 5 retrospective trials, and two meta-analyses assessing diagnostic accuracy, with one analysis also assessing costs, duration of the examination, and anatomical mapping. Overall, LUS was shown to provide highly sensitive mapping of the extra-pancreatic biliary anatomy in 92%-100% of patients, with more difficulty encountered in delineation of the intra-pancreatic segment of the biliary tract (73.8%-98%). Identification of vascular and biliary variations has been documented in two studies. Although inflammatory disease hampered accuracy, LUS was still advantageous *vs* IOC in patients with obscured anatomy. LUS can be performed before any dissection and repeated at will to guide the surgeon especially when hilar mapping is difficult due to fibrosis and inflammation. In two studies LUS prevented conversion in 91% of patients with difficult scenarios. Considering

CBDS detection, LUS sensitivity and specificity were 76%-100% and 96.2%-100%, respectively. LUS allowed the diagnosis/treatment of incidental findings of adjacent organs. No valuable data for BDI prevention or detection could be retrieved, even if no BDI was documented in the reports analyzed. Literature analysis proved LUS as a safe, quick, non-irradiating, cost-effective technique, which is comparatively well known although largely under-utilized, probably due to the perception of a difficult learning curve.

### CONCLUSION

We highlight the advantages and limitations of laparoscopic ultrasound during cholecystectomy, and underline its value in difficult scenarios when the anatomy is obscured.

**Key words:** Intraoperative ultrasound; Laparoscopic cholecystectomy; Bile duct injury; Choledocolithiasis; Biliary anomalies

© The Author(s) 2017. Published by Baishideng Publishing Group Inc. All rights reserved.

**Core tip:** Laparoscopic ultrasound (LUS) during cholecystectomy allows a non-invasive study of the biliary tract, with an excellent ability to detect common bile duct stones and identify anatomy. Unlike intraoperative cholangiography, LUS can be performed before Calot's triangle dissection, which facilitates the mapping of biliary and hilar structures during difficult scenarios such as severe inflammation and fibrosis. Cheap, quick, and non-irradiating LUS can be repeated at will during the operation. Adjacent organs can also be examined, allowing incidental findings. Our review of the recent literature highlights the advantages of LUS, despite its underuse, particularly in difficult cholecystectomies when the anatomy is obscured.

Dili A, Bertrand C. Laparoscopic ultrasonography as an alternative to intraoperative cholangiography during laparoscopic cholecystectomy. *World J Gastroenterol* 2017; 23(29): 5438-5450 Available from: URL: <http://www.wjgnet.com/1007-9327/full/v23/i29/5438.htm> DOI: <http://dx.doi.org/10.3748/wjg.v23.i29.5438>

### INTRODUCTION

The last few decades have seen the increased adoption of minimally invasive surgery in various abdominal procedures. A drawback of this laparoscopic approach is the inability of the surgeon to palpate abdominal organs. This loss of tactile feedback, combined with technical difficulties and an extensive learning curve, may collectively explain the slow uptake of laparoscopic surgery in the field of hepatic-biliary-pancreatic surgery (HPB)<sup>[1]</sup>.

Cholecystectomy (LC) is the most common HPB

operation and possibly represents the first widely accepted "gold standard" laparoscopic approach<sup>[2]</sup>. LC is a relatively easy and safe operation, as long as the biliary duct is adequately mapped. Indeed, delineation and meticulous evaluation of the biliary tract is critical for the detection of common bile duct stones (CBDS), and for the prevention of bile duct injury (BDI).

Over the past few decades the advantages of LC vs the open procedure have been widely acknowledged, but with one glaring blemish, the higher rate of BDI<sup>[3]</sup>, despite a recent report describing a rate of BDI of 0.08%<sup>[4]</sup>. During LC the main cause of BDI is poor visibility of the biliary tract (71%-97% of patients) and inadequate surgical skills<sup>[5,6]</sup>.

In order to clarify biliary anatomy during LC, different techniques have been proposed. These include intraoperative cholangiography (IOC), cholecystocholangiography, dye cholangiography, light cholangiography, passive infrared cholangiography, near-infrared fluorescence cholangiography, hyper-spectral cholangiography, and laparoscopic ultrasound (LUS)<sup>[7]</sup>. Of these techniques, IOC is the most commonly used to determine bile duct anatomy and to diagnose CBDS. There has been much debate as to whether this examination helps to prevent, or improve the early detection of BDI. This controversy is of considerable importance to the patient, and their treatment<sup>[6]</sup>, with uncertainty as to whether IOC should be routinely or more sparingly used<sup>[8-11]</sup>.

The routine implementation of IOC poses several challenges. Practically, these include the need for dissection before IOC, which may be technically difficult (in acute or chronic inflammatory disease), together with cannulation of a short, thin, or tortuous cystic duct<sup>[12]</sup>, and the risk of avulsion during cannulation of an inflamed cystic duct<sup>[13]</sup>. Additionally, IOC lengthens the procedure time<sup>[14]</sup> and increases costs, imposes a learning curve in terms of correctly interpreting images<sup>[5]</sup>, and exposes the medical team and patient to ionizing radiation, even if this seems to be negligible concern for the adult population<sup>[15]</sup>.

Soon after the outset of LC use, authors proposed that LUS be used to substitute for the lack of tactile palpation during laparoscopy, such that the surgeon could identify subsurface structures. Prior to 2000, multiple reports emphasized the benefits of LUS, and its efficacy in assessing CBDS and anatomy during LC<sup>[16-35]</sup>.

Compared to IOC, LUS is described as less invasive, faster, cheaper, with no adverse events, and can be repeatedly used during the operation with no risk of irradiation, which is clearly preferable for pregnant or young patients. Nevertheless, despite these positives, the routine use of LUS during LC is virtually non-existent compared to IOC, with only 1% of surgeons using this technique<sup>[36]</sup>.

This report aims to review the role of LUS as a substitute for IOC for the anatomical delineation of the biliary tract, anatomical evaluation during acute

Table 1 Results of PubMed review

Author	Year	Type of study	Number of patients	Surgeon	Routine LUS use	Detailed anatomical description	CBDS report	Specific aims of the study other than LUS efficacy
Tranter	2001	PNR	367	Several	+	Poor	+	
Biffl	2001	PNR	248	Several	+	No	+	CBDI
Halpin	2002	PNR	380	Single	+	Yes	+	Comparison with IOC
Catheline	2002	PNR	900	ni	+	No	+	Comparison with IOC
Tranter	2003	PNR	135	Several	+	No	+	Comparison with IOC, measurement of duct diameter
Onders	2005	PNR	105	Single	-	No	+	
Perry	2007	PNR	236	Single	+	Poor	+	Comparison with IOC
Machi	2007	PNR	200	Several	+	Poor	+	Cost
Hakamada	2008	RSS	299	Several	<sup>1</sup>	Yes	+	Educational program
Machi	2009	RMS	1352	Several	+	No	+	
Hublet	2009	PNR	269	Single	+	Poor	+	
Li	2009	PRN	103	Several	+	Yes	+	
Hashimoto	2010	RMS	220	Several	+	Yes <sup>2</sup>	-	CBDI
Pfluke	2011	RSS	50	Several	+	Yes	+	
Nasu	2012	PNR	71	ni	+	Poor	+	
Kothari	2013	PNR	253	Several	+	Poor	-	Comparison with trans-abdominal US in obese patients
Gwinn	2013	PNR	44	Several	+	Poor	-	Impact of inflammatory disease
Shaaban	2014	RSS	70	Single	-	No	+	
Meta-analysis								
Aziz	2014	MA						
Jamal	2015	MA						

<sup>1</sup>Since instigation as part of an educational program ; <sup>2</sup>Focus on cystic duct-CBD junction. RSS: Retrospective single center study; RMS: Retrospective multicenter study; PNR: Prospective non-randomized study; MA: Meta-analysis; ni: No information; CBDS: Common bile duct stones; LUS: Laparoscopic ultrasound; IOC: Intraoperative cholangiography.

cholecystitis, CBDS detection, the prevention or early detection of BDI, and incidental findings during LC.

## MATERIALS AND METHODS

A literature search of the PubMed and MEDLINE database was performed using the following keywords: "intraoperative laparoscopic ultrasound" and "laparoscopic cholecystectomy". Overall, only English-language publications published between January 2000 and December 2016 were considered. All studies that contained material relevant to the topic were reviewed.

## RESULTS

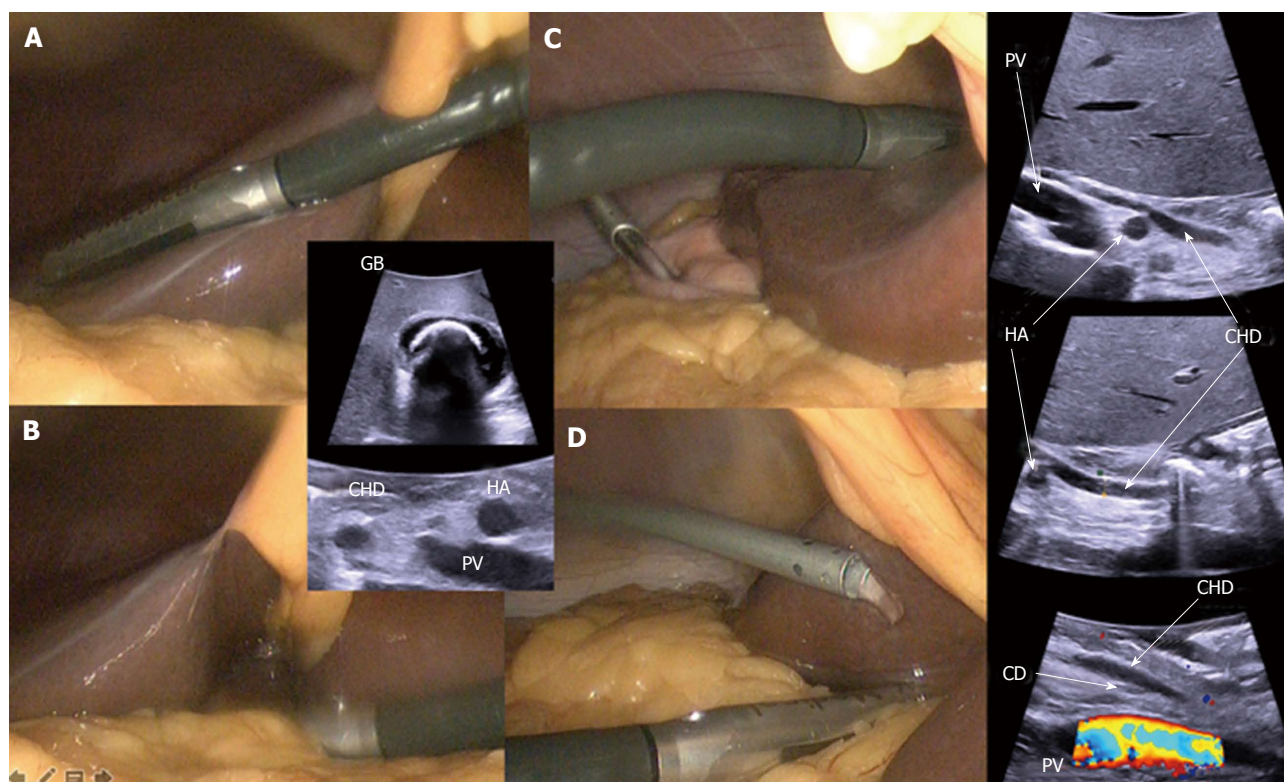
From 2000 to 2016, no randomized controlled trials were conducted. Eighteen reports were identified, 13 were prospective non-randomized trials, and 5 were retrospective trials. Two meta-analyses were found, one assessing the diagnostic accuracy of LUS in detecting CBDS vs IOC<sup>[37]</sup>, and a second, analyzing CBDS detection, together with costs, time taken for the examination, and ability to identify anatomical landmarks<sup>[38]</sup>. Table 1 shows the published studies, together with their respective methodologies and principal evaluated variables.

### LUS and anatomy

During LC, an appreciation of bile duct and vascular anatomy is mandatory in order to perform fine dissection and prevent bile duct and vascular injuries. Indeed,

errors whereby surgeons fix anatomical structures incorrectly, especially when the anatomy is obscured or where there is an anatomical variation, is the most common cause of injury<sup>[39]</sup>. The two structures that are most commonly misidentified as the cystic duct (neither of which are particularly rare) are the common bile duct, and an aberrant right hepatic duct that drains the posterolateral sector of the liver.

Izuishi *et al*<sup>[40]</sup> reported multi-slice-computed cholangiography of 113 patients and documented that a posterior inferior duct joined the common hepatic duct directly (parallel to the cystic duct) in 6% of patients, whereas a posterior segmental duct directly joined either the common bile duct in 7% of patients, or cystic duct in 1% of cases. An overall rate of anatomical variation of 16% was documented, which underlines the importance of accurately identifying all structures during LC. In a larger cohort study, anatomical variations of the bile duct were analyzed in 1094 direct cholangiograms by Yoshida *et al*<sup>[41]</sup>. The relative position of the right anterior (A), right posterior (P), right (R), left (L), and cystic ducts were documented. Arborizing patterns revealed that 67.7% were normal (*i.e.*, RL, a normal bile duct convergence), whereas 17.7%, 8%, and 6%, demonstrated APL (*i.e.*, trifurcation), A-PL (*i.e.*, low implantation of the right anterior duct), and P-AL (*i.e.*, low implantation of the right posterior duct), respectively. Cystic duct anomalies occurred in 1.6% of patients, the most frequent being the pattern (0.5%) in which the cystic duct merges with lower branch of the posterolateral



**Figure 1 Laparoscopic ultrasonography: technique.** Transversal approach - A: Through the liver; B: Directly on the hepatoduodenal pedicle. Longitudinal approach - C: Through the liver; D: Directly on the hepatoduodenal pedicle (isotonic solution's irrigation that improves acoustic coupling). CD: Cystic duct junction with the the common bile duct; CHD: Common hepatic duct; HA: Hepatic artery; PV: Portal vein; GB: Gallbladder with macrolithiasis.

segmental duct. This pattern has to be recognized correctly by the surgeon during LC in order to avoid misidentification and subsequent injury of the right posterior segmental duct.

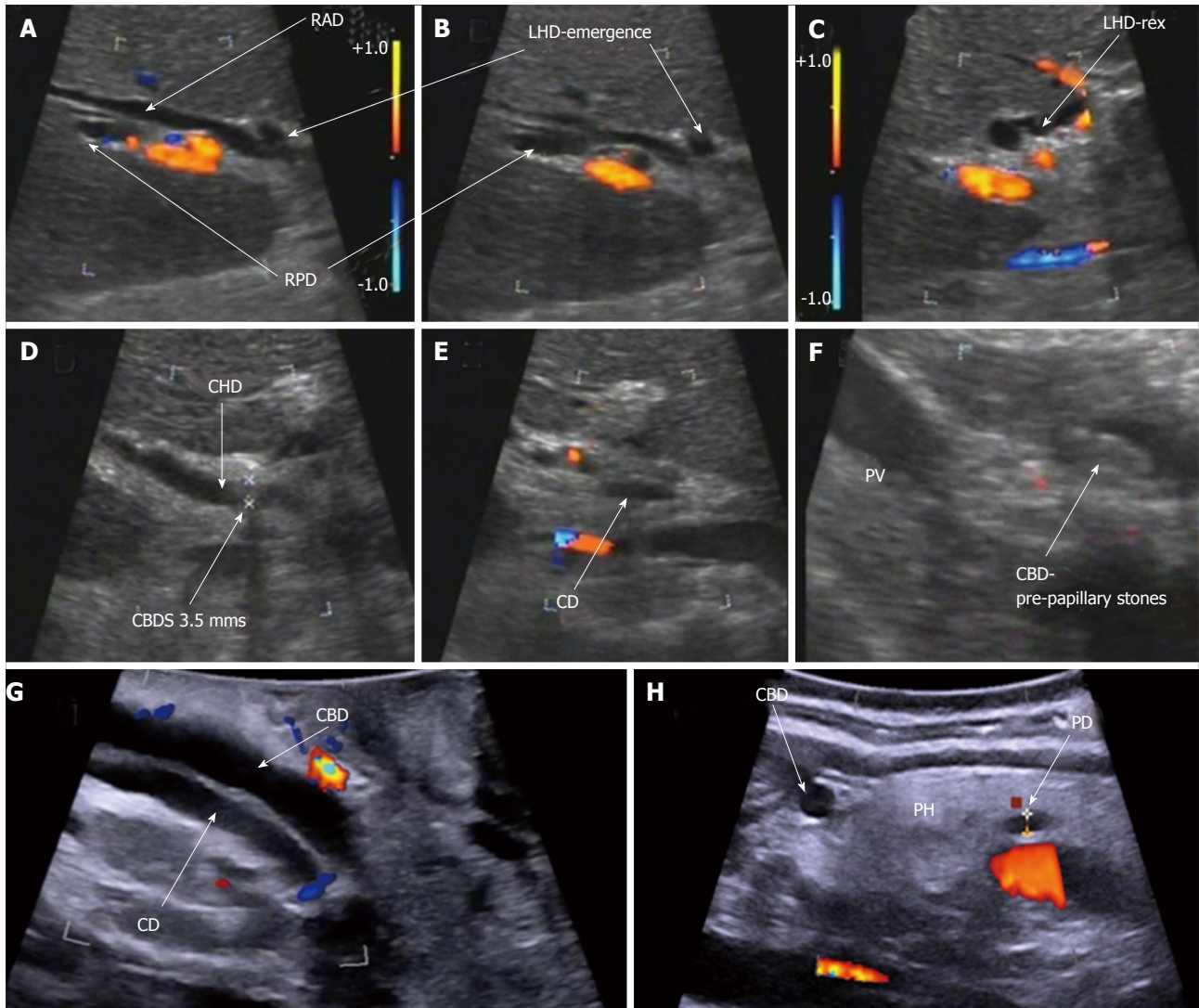
LUS with the color Doppler application and transverse scanning generates the characteristic "Mickey Mouse" appearance of the CBD, portal vein, and common hepatic artery<sup>[22]</sup>. Occasionally, a prominent cystic duct that is parallel to the CBD can be identified in a "four tube sign"<sup>[23]</sup>. Hashimoto *et al.*<sup>[42]</sup> studied the efficacy of LUS in identifying the cystic-common bile duct junction and found that LUS was inaccurate in 6% of patients, predominantly when the diameter of the CBD was less than 5 mm. In longitudinal scanning, LUS provides excellent anatomical information (Figure 1).

In order to complete a thorough examination of the biliary tract, the surgeon has to identify the biliary convergence with the left and right sectorial branches through the liver. Sequentially, the branch of the anterior right sector (direct extension of the CBD) is identified, followed by the posterior right sector duct. Then the gallbladder bed is visualized, followed by the walls of the gallbladder, then the transverse hepatic vein. This is a branch of the middle hepatic vein, tangential to the gallbladder bed, which is present in 15.38% of patients. When injured, this vein can provoke serious bleeding, mostly in cirrhotic patients<sup>[43-45]</sup>. A Doppler LUS is performed to identify

the vascular anatomy and hepatic blood flux. The hepatoduodenal ligament is irrigated with an isotonic solution that improves acoustic coupling between the screened surface and probe. This permits analyses of the CBD (its integrity and diameter), the cystic duct, the junction between the cystic duct and the CBD, and the common hepatic duct and its intra-pancreatic portion (Figure 2). Other interesting anatomical findings include vascular variation or injuries<sup>[46]</sup>, or even lymph nodes.

An advantage of LUS is that it can be used before or after dissection of the Calot's triangle, and, since it is not time consuming, can be repeated as needed. In the literature, 7 authors used LUS prior to dissection, and 7 after (Table 2). As shown in Table 2, LUS can be performed before or after dissection, according to perioperative findings, or before dissection to identify anatomy and systematically afterwards to confirm the correct dissection and absence of any injury. Considering the cystic duct-CBD junction, which is one of the most critical parts of the dissection, Hashimoto *et al.*<sup>[42]</sup>, in a retrospective multicenter trial, reports an improved identification rate (of 98%) after dissection of the Calot's triangle compared to 84% when LUS is completed before dissection. It is interesting to note that use of LUS at the end of the operation could be used to confirm the integrity of the common bile duct after clipping and transection of the cystic duct.

A review of the literature shows that most authors



**Figure 2** Laparoscopic ultrasonography: bile duct anatomy. A-C: Biliary convergence anatomy; D-F: Classical cystic duct junction with common bile duct stones; G and H: Intra-pancreatic bile duct. RAD: Right anterior sector duct; RPD: Right posterior sector duct; LHD: Left hepatic duct; LHD-rex: Left hepatic duct at Rex recessus; CBDS: Common bile duct stones; CD (E): Cystic duct; CHD: Common hepatic duct; CBD: Common bile duct; CD (G): Cystic duct with low implantation in the common bile duct; PD: Pancreatic duct; PH: Pancreatic head.

describe how to analyze the biliary tract, but very few provide details of the success with which each portion of the CBD is identified, which is essential in performing a safe LC. Table 3 provides data for the rates of “complete observation” and the ability of LUS to identify duct segments. According to these data, the rate of “complete observation” of the biliary tract with LUS ranged from 92%-100%, with very few reports providing an accurate rate of identification of each biliary duct segment. Complete anatomic analyses are reported in only four manuscripts<sup>[13,47-49]</sup>, with vascular identification and/or variation in three<sup>[47,48,50]</sup>. Anatomic vascular and/or biliary variations have been described such as a foreshortened cystic duct in 14% of patients in a retrospective single center trial reported by Pfluke<sup>[47]</sup>, atypical cystic-bile duct junctions<sup>[51]</sup>, aberrant hepatic ducts<sup>[47,51]</sup>, or an accessory right hepatic artery<sup>[47]</sup>.

Even if LUS imaging of the CBD provides excellent

accuracy (Table 3), visualization of the intra-pancreatic portion appears to be more challenging, with rates of complete delineation ranging from 73% to 100%<sup>[12,13,47-49]</sup>.

In a meta-analysis performed by Jamal *et al.*<sup>[38]</sup> there was no significant difference between IOC and LUS in identifying the extra-pancreatic CBD, but IOC appeared to be more efficient in delineating the intra-pancreatic CBD. Other authors report discontinuous mapping of the biliary tract. In a prospective non-randomized trial, Halpin *et al.*<sup>[13]</sup> reports discontinuous screening of the middle and/or distal CBD in 10% of patients. This agrees with other studies reporting rates of discontinuous mapping of the CBD of 4%-17%<sup>[20,52]</sup>. In Halpin’s experience, this did not translate into increased false negatives with LUS.

#### **LUS and acute or chronic inflammatory disease**

A major impediment to the conclusion of LC is the inability to identify, with surety, the location of the

**Table 2** laparoscopic ultrasound performed pre- or post-dissection

Author	Year	No. of patients	LUS pre-dissection	LUS post-dissection	
Tranter	2001	367	-	+	
Biffl	2001	248	+	+	
Catheline	2002	900	+	-	
Halpin	2002	380	-	+	
Tranter	2003	135	-	+	
Onders	2005	105	+	-	
Machi	2007	200	+	+	
Perry	2007	236	+	+	According to the situation
Hakamada	2008	299	+	+/-	After if necessary
Hublet	2009	269	-	+	
Li	2009	103	+	-	
Machi	2009	1352	+	+/-	After if necessary
Hashimoto	2010	220	+	+	
Pfluke	2011	50	-	+	
Nasu	2012	71	-	+	
Gwinn	2013	44	+	-	
Kothari	2013	253	+	-	
Shaaban	2014	70	-	+	

LUS: Laparoscopic ultrasound.

extra-hepatic bile duct and to assess its relationship with the gallbladder when the hepatoduodenal anatomy is obscured. Cholangitis or previous pancreatitis may render access to the biliary tract difficult. In such cases the risk of major bile duct and/or vascular injury is substantial, even for the most adept HPB surgeon. IOC is not possible without dissection. In such hazardous situations, LUS can be a valuable adjunct and can be performed before dissection, and repeated as needed to guide the surgeon. Many authors report their experience of LUS in scenarios of inflammatory disease (Table 4).

Gwinn *et al*<sup>[53]</sup>, in a prospective non randomized trial, reports a rate of 100% complete biliary tract analysis even with acute inflammation. In that study, LUS was critical in performing LC during acute cholecystitis in all 44 patients whose anatomy was obscured by acute or chronic cholecystitis, with a rate of 34.1% of gangrenous cholecystitis, but no mention of the fibrotic percentage. During the operation, for all cases, LUS was used to identify with precision the anatomy of the cystic duct, CBD, and the cystic duct-CBD junction. Indeed LUS was considered to be a crucial tool in avoiding conversion in 91% of patients<sup>[53]</sup>, with no BDIs observed. It seems that even when complete visualization of the biliary tract is difficult to achieve because of inflammatory disease or fibrosis, the most important dissection targets (cystic duct, CBD, and the cystic duct-CBD junction) can still be finely identified.

Machi *et al*<sup>[54]</sup>, in a multicenter study that included 1352 patients, reported a feasibility rate for LUS of 98%, even with 20.90% of cases presenting with inflammatory disease. In their report, LUS proved to be remarkably valuable, given that mapping of the biliary tract avoided conversion in 5.9% of patients with

anatomy obscured due to Mirizzi's syndrome, acute or chronic cholecystitis, or pancreatitis. Even though no comment was made in this report considering the particularly difficult situation of fibrosis, 79.1% of patients were considered to be in a state of chronic cholecystitis. Biffl *et al*<sup>[55]</sup> in a prospective non-randomized study showed that LUS provided an excellent guide for dissection as its routine use during acute cholecystitis allowed operations to be completed with lower conversion rates than seen with patients operated on without LUS ( $P = 0.09$ ). According to these data, LUS seems to play an essential role in mapping the biliary and hilar trunk when the anatomy is obscured such as in the fibrotic or inflammatory state. The possibility of identifying the anatomy before and/or during dissection could be one of this technique's most valuable aspects.

Conversely, other authors have suggested that inflammation may hinder LUS analysis<sup>[51]</sup>. For example, Hakamada *et al*<sup>[48]</sup>, in a retrospective single center study, reported a high analysis rate for the complete biliary tract in LC for cholelithiasis, which then fell according to the severity of inflammation, while preserving an excellent feasibility rate of 100%.

#### LUS and biliary duct injury

BDI is a dreaded complication during cholecystectomy. The incidence of BDI during LC remains at 0.3%-0.6%<sup>[3]</sup>, with a trend suggesting its diminution as surgical experience and expertise is acquired<sup>[4]</sup>. BDI combined with vascular injury is observed in 12% of patients, which may negatively impact treatment and recovery<sup>[56]</sup>.

BDIs are best prevented by fine dissection using different techniques as recommended for simple vs more complex LC cases<sup>[57,58]</sup>. Described by Strasberg *et al*<sup>[28]</sup> in 1995, the critical view of safety (CVS), a systematic dissection that skeletonizes the Calot's triangle and delineates the relationship of anatomic structures, has been suggested to play a protective role against BDI<sup>[59-61]</sup>. A drop in BDIs following the implementation of CVS as a dissection principle during LC was documented by Yamashita *et al*<sup>[62]</sup> in a Japanese report. Despite this evidence, CVS still appears to be underutilized by surgeons in current practice<sup>[36]</sup>, and may even be insufficient in terms of minimizing CBDI. Further, major CBDIs continue to occur, even for surgical teams that have adopted CVS as a standard dissection technique as reported by de Reuver *et al*<sup>[63]</sup>.

In 1996, Birth *et al*<sup>[18]</sup> reported a 100% recognition rate of BDIs using LUS in an experimental animal study without blinding (*i.e.*, surgeons knew that BDIs were present). These data may therefore be biased and should be interpreted with caution.

Data for LUS and the prevention or detection of BDIs are sparse. Across the studies reviewed (Table 1), no BDIs were reported with only 2 studies emphasizing the importance of combining CVS and LUS<sup>[12,47]</sup>. However, delineation of the CBD, the

Table 3 Identification of biliary anatomy and variations

Author	Year	No. of Patients	Complete observation	Intrahepatic BD	Bifurcation	CHD	CBD	CD-CBD junction	Intra-pancreatic BD	Vascular visualization	Biliary anomalies	Foreshortened cystic duct (< 1 cm)	Abnormal cystic duct anatomy	Aberrant vascular anatomy
Tranter	2001	367	92%			92%	99%							
Halpin	2002	380	90%				95%		94%					
Tranter	2003	135	97.7%											
Machi	2007	200	96.5%				98.5%							6.40%
Perry	2007	236	95.3%				88.6%-99.4% <sup>2</sup>	91.4%-100% <sup>2</sup>	88.6%-98.3% <sup>2</sup>	89.3%-100% <sup>2</sup>				
Hakamada	2008	299	100%	100% <sup>1</sup>	88.6%-97.1% <sup>2</sup>									
Hublet	2009	269	99%				98.9%		73.8%					
Li	2009	103		95.7%		98.9								
Machi	2009	1352	98%					94% <sup>3</sup>						
Hashimoto	2010	200	-				100%	98%	98%		40%	14%	8%	16% <sup>4</sup>
Pfluke	2011	50	96%	100%										
Gwinn	2013	44	100%											

<sup>1</sup>Not influenced by inflammation; <sup>2</sup>Influenced by inflammation; <sup>3</sup>Junction not identified when CBD < 5 mm; <sup>4</sup>Accessory RHA (right hepatic artery) 8%, replaced RHA 6%, anterior cystic artery 2%. CHD: Common hepatic duct; CBD: Common bile duct.

possibility to repeat LUS during the procedure either before or after dissection, and the ability of LUS to detect aberrant vascular anatomy<sup>[47]</sup> may collectively play a role in preventing bile duct and vascular injuries. As an example, using LUS, Hublet *et al.*<sup>[12]</sup> identified a stenosing clip placed too close to the junction between the CBD and CD, in a patient with a normal IOC. This underlines the fact that CBDI can still occur after IOC. Thanks to LUS performed at the very end of the operation, a diagnosis of CBD stenosis was made with subsequent repair, avoiding potential major postoperative complications.

### LUS and common bile duct stones

The presence or absence of CBDS can be predicted to some extent using preoperative criteria, but these fail to reach 100% accuracy<sup>[64,65]</sup>. Catheline *et al.*<sup>[20]</sup>, in a retrospective trial published in 1999, reported a perioperative CBDS detection rate of 9%. In this group of patients, 30% manifested no preoperative risk factors. Olsen *et al.*<sup>[24]</sup>, in a prospective non randomized study, recorded 12% of patients as having CBDS, even after preoperative clearance by endoscopic retrograde cholangiopancreatography (ERCP). Thanks to LUS, CBDS can be identified early during the procedure, which gives the operating room personnel time to set up the required CBDS exploration equipment.

The sensitivity and specificity provided by LUS in detecting CBDS is very good (Table 5). In 2003, Tranter *et al.*<sup>[66]</sup>, in a prospective non randomized study, reported specificity and sensitivity rates of 96% and 100%, respectively, compared to sensitivity and specificity rates of 86% and 99% in IOC. In another prospective non randomized study, Li *et al.*<sup>[69]</sup> also observed higher sensitivity rates for LUS vs IOC (82.1% vs 75%), and an equal specificity rate of 98.7%.

A meta-analysis of the literature performed by Jamal *et al.*<sup>[38]</sup> confirmed a sensitivity and sensitivity rate for LUS that was superior to IOC (0.90 and 0.99 for LUS vs 0.87 and 0.98 for IOC, respectively), with heterogeneity found to be insignificant. In agreement with this observation, Aziz *et al.*<sup>[37]</sup>, in another meta-analysis, suggested that LUS is very accurate in detecting CBDS (pooled sensitivity of 0.87, and specificity of 1.00) vs IOC (pooled sensitivity of 0.87, and specificity of 0.99).

The measurement of CBD diameter was performed and reported in several studies<sup>[13,66-68]</sup>. In 2001, Tranter *et al.*<sup>[68]</sup> observed that when dealing with a thin CBD (< 5 mm) there should be no concern regarding CBDS. In these circumstances, LUS could be an excellent negative predictor. Two years later, the same author reported<sup>[66]</sup> that for CBDs of between 6-10 mm in diameter, there was a large overlap between ducts with or without stones; 85% of ducts > 10 mm in width contained stones.

Considering sludge, defined as small areas (< 1 mm) of mobile echogenic material without acoustic shadowing, their clinical significance remains debatable, with some studies suggesting that sludge is related with acute pancreatitis<sup>[69,70]</sup> or cholangitis<sup>[71]</sup>. LUS appears to be more accurate in these diagnoses than IOC. Halpin *et al.*<sup>[13]</sup>, in

**Table 4** Reports of laparoscopic ultrasound used during acute or chronic cholecystitis

Author	Year	No. of patients	Inflammatory disease %	Comments
Biffl	2001	248	37.5	
Catheline	2002	900	28.2	
Onders	2005	105	6.3	
Machi	2007	200	28.5	
Perry	2007	236	5.5	LUS considered extremely valuable in 5.5%
Hakamada	2008	299	66.3	13.4% with severe inflammatory disease during 2 <sup>nd</sup> period of study
Machi	2009	1352	20.9	LUS considered extremely valuable in 5.9%
Pfluke	2011	50	66.0	
Gwinn	2013	44	100.0	

LUS: Laparoscopic ultrasound.

**Table 5** Common bile duct stones identification

Author	Year	No. of patients	Sensitivity %	Specificity %	Criteria to evaluate CBS LUS accuracy		
					IOC	ERCP/surgical exploration	Follow-up
Tranter	2001	367	92	100	Selective	+	+
Biffl	2001	248	100	96.23	ni		
Halpin	2002	380	97.5	100	Selective	+	+
Catheline	2002	900	80	99	Systematic		
Tranter	2003	135	96	100	Systematic		
Onders	2005	105	100	100	Selective	+	
Perry	2007	236	92.3	100	Selective	+	
Machi	2007	200	95	100	Selective	+	+
Hakamada	2008	299	76	99	Selective		
Machi	2009	1352	98.6	99.58	<sup>1</sup>	+	
Hublet	2009	269	100	99.6	Selective		+
Li	2009	103	82.1	98.7	Selective	+	+
Pfluke	2011	50	100	100	Selective		
Nasu	2012	71	100	96.2	Selective		
Shaaban	2014	70	92.3	98.2	No	+	+

<sup>1</sup>Selective or systematic, according to center. ni: No information; LUS: Laparoscopic ultrasound; IOC: Intraoperative cholangiography; ERCP: Endoscopic retrograde cholangiopancreatography.

a prospective non randomized study, detected 14% of patients with sludge in the LUS group, but no diagnoses were made for the IOC group. This allowed the surgeon to proceed to a non-invasive treatment, such as saline flush *via* the cystic duct combined with glucagon injection. On the other hand, Halpin's experience was that 62% of patients with sludge underwent no treatment, with no adverse events. Other authors also adopted a "wait and see" approach to sludge with good results<sup>[51]</sup>. The high detection rate of LUS agrees with reports observing a high accuracy of detection of microlithiasis by echoendoscopic examination<sup>[72]</sup>.

In IOC, a higher number of false positive examinations may be due to micro-bubbles<sup>[73]</sup> or Oddi's contractions. These drawbacks are not applicable to LUS. In LUS, only exceptional false positive examinations have been reported due to confusing pancreatic head micro-calcifications with CBDS<sup>[54]</sup>.

To conclude, this literature review suggests that LUS is, at the very least, equivalent to IOC in terms of detecting choledocholithiasis, and may be more specific, leading to fewer negative explorations. It is important to note that LUS and IOC may be complementary, as combining the 2 techniques maximizes the intraoperative detection of CBDS, with a sensitivity rate of 95% and a

specificity rate of 98%<sup>[73,49]</sup>.

### LUS and incidental findings

LUS has the benefit of substituting for the lack of tactile palpation during LC, and allows scanning of other organs such that additional underlying pathology can be identified. Liver abscesses or tumors, suspicious lesions in the gallbladder wall, or diverticulum of the common bile duct can be detected<sup>[25]</sup>. In 1995, in a prospective non randomized study, Stiegmann *et al*<sup>[19]</sup> reported the LUS identification of a large hilar lymph node, from which a frozen section was used to diagnose gallbladder carcinoma.

In the series published after 2000 (Table 6), Hublet *et al*<sup>[12]</sup>, in a prospective non randomized study, reported the diagnosis of one case with hemobilia (which could have been interpreted as a filling defect in IOC imaging), 1 pancreatic pseudocyst, 1 case of IPMN, 1 pancreas divisum, and 1 patient with micro-calcifications of the head of the pancreas. Other authors report the identification of gallbladder polyps<sup>[74]</sup>, Mirizzi syndrome<sup>[50]</sup>, lobar atrophy/hypertrophy, or rotational anomalies of the liver<sup>[54]</sup>. In a prospective non randomized study published in 2007, Machi *et al*<sup>[51]</sup> diagnosed cystic or solid tumors of the liver or



**Table 6** Incidental findings

Author	Year	No. of patients examined using LUS	Incidental findings
Machi	2007	200	Cystic or solid tumors of the liver or pancreas in 31 patients; 14 biopsies and aspirations, 6 radiofrequency ablations
Perry	2007	236	Atrophic/hypertrophic or rotational anomalies of the liver, Mirizzi syndrome, vascular anomalies Polyps
Hakamada	2008	299	
Hublet	2009	269	
Machi	2009	1352	1 hemobilia, 1 pancreatic pseudocyst, 1 IPMT, 1 pancreas divisum, 1 micro-calcification of the pancreatic head, 1 liver abscess, 1 liver tumor
Gwinn	2013	44	Atrophic/hypertrophic or rotational anomalies of the liver, Mirizzi syndrome, vascular anomalies 2 hepatic rotation anomalies
Kothari	2013	253	Polyps. Improved visualization of gallbladder walls in obese patient compared to trans-abdominal US

LUS: Laparoscopic ultrasound.

pancreas during systematic examination *via* LUS. Thus, LUS permitted the surgeon to proceed to biopsy or aspiration, and even radiofrequency ablation of tumors in 6 cases. Even if it remains unclear as to whether these tumors were incidental perioperative findings, or were diagnosed during the preoperative workup, LUS permitted localization of the disease, biopsy, and even treatment.

### Speed of the process

LUS can be completed more rapidly than IOC<sup>[38,48,73,75]</sup>. Catheline *et al*<sup>[73]</sup>, in a prospective non randomized study, reports a LUS duration of 9.8 min vs 17.6 min for IOC. Further, in order to perform IOC, a radiological device, together with a technician capable of operating the device are needed. While surgical experience in using LUS seemed to significantly influence the operating time for cholecystolithiasis<sup>[48]</sup>, Halpin *et al*<sup>[13]</sup> observed no differences when dealing with acute cholecystitis.

### Learning curve

The number of LUS examinations performed as part of the learning curve varied in reports<sup>[13,48,67]</sup>, with a broad agreement that the learning curve was greater than for IOC. What seems to be evident from the literature review is that surgeons that take the time and effort to perform LUS, not only become very efficient and accurate in their diagnoses, but also modify their practice. These surgeons use IOC more selectively and rarely<sup>[12,50]</sup>. Given that the accuracy of LUS improves with the expertise of the operator, standardization of the examination is essential.

### Costs

In 2016, Sun *et al*<sup>[76]</sup> evaluated the cost effectiveness of LUS, IOC for the investigation of silent CBDs during LC. The authors concluded that LUS is a more cost-effective strategy than IOC.

## DISCUSSION

During laparoscopic cholecystectomy, mapping of the dissection targets such as the common bile duct, cystic

duct, and hilar vascular structures, is crucial for safely completing the operation. While careful dissection avoids injury, this may be difficult to achieve in the presence of fibrosis or extensive inflammation, or when there is an aberrant biliary anatomy (and/or a very short cystic duct).

The debate is ongoing as to whether an analysis of the hilar anatomy during cholecystectomy may help to prevent injury and postoperative complications. Many surgeons perform no analyses given that the proposed "gold standard" technique (IOC) has its own drawbacks including irradiation of the patient and the surgical team, dissection of the Calot's triangle to identify the cystic duct, and cannulation of the cystic duct which may cause avulsion or perforation. IOC is also considered to be expensive and time-consuming.

On the other hand, LUS, which has a long history of use (> 30 years), allows a quick, repeatable, highly successful, non-irradiating, and non-invasive study of the biliary tract. In difficult scenarios, when anatomical structures are obscured, such as during inflammation or fibrosis, LUS can be pivotal to the success of the procedure, and is easily performed before the dissection in order to guide the surgeon. With the added advantage of re-use on demand during the operation as it is neither time-consuming nor expensive. Indeed, LUS provides an excellent analysis of the CBD, even if it would appear to be less accurate than IOC in the study of the intra-pancreatic segment of the bile duct.

Considering aberrant biliary anatomy, such as a cystic duct originating from the right posterior sector, very few authors provide detailed anatomical descriptions. More results for the precise anatomical evaluation, segment by segment, are warranted. Nevertheless, it seems that, in experienced hands, LUS can provide a precisely mapped biliary duct. When analyzing the cystic-common bile duct junction, a short cystic duct, or even Mirizzi's syndrome, LUS might be effective in clarifying the anatomy and even preventing conversion.

While no precise data concerning the prevention of BDIs were reported, the ability to delineate anatomy may have a protective role as no BDIs were described

in the reviewed series, even when patients with acute or chronic inflammatory disease were included.

The ability of LUS to detect CBDS and sludge is at least as good, if not better than IOC, and provides fewer false positive examinations. Moreover, LUS contributes to a complete examination of the adjacent organs, which allows for diagnoses of incidental pathology.

Finally, the use of LUS is not exclusive. IOC can be of importance in many situations. Consequently, any surgeon should be able to use both techniques, which are complementary in detecting common bile duct stones. Further, the advantages of LUS have led to the authors using this technique as a first line procedure.

A limitation of this review is that it is based on a relatively small number of non-randomized trials, with a limited number of patients, with heterogeneous, non-standardized criteria in terms of anatomical analysis. Unfortunately, no specific data could be found for the hazardous situation of fibrosis, which is instead necessarily included in a broader "difficult" category.

To conclude, a large panel of techniques has been described that clarify anatomy during laparoscopic cholecystectomy. However, of these techniques, LUS would appear to be the most suitable as it provides the greatest number of advantages and can be used during other types of operation. LUS is also, probably, the most cost-effective, which is an essential quality in an era of financial constraints. The principal hurdle for the adoption of LUS as a standard imaging technique of the CBD during LC appears to be the reticence of surgeons, probably because of its supposed lengthy learning curve. However, as ultrasound and laparoscopy become standard techniques in modern surgery, most surgical trainees and junior surgeons will be exposed to them, and will be more inclined to include them in their skill set. In this fashion, we envisage that the reluctance to use LUS will become obsolete. Moreover, surgeons should consider that implementation of LUS during LC could serve as a valuable exercise to gain familiarity with a technique that should prove useful for multiple operations.

## COMMENTS

### Background

The detection of common bile duct stones and bile duct injury prevention remain hot topics in laparoscopic cholecystectomy, more so now that the laparoscopic approach is standardly used, even in difficult cases with acute or chronic inflammation and fibrosis. As a companion technique, intraoperative cholangiography (IOC) is usually proposed as the "gold standard" analysis method. Laparoscopic ultrasonography (LUS) is much less evaluated.

### Research frontiers

LUS during cholecystectomy is a well-known technique described from more than 30 years ago. However as less than 1% of surgeons seem to adopt it probably due to its supposed longer learning curve. The specific benefits and the performance of the technique has to be evaluated.

### Innovations and breakthroughs

All manuscripts concerning the performance of LUS during laparoscopic

cholecystectomy from the year 2000 were reviewed by the authors with a view to the performance of anatomical mapping, even with background inflammation.

### Applications

This review confirmed the clinical benefits of LUS during cholecystectomy, especially in difficult situations. Compared to IOC, LUS remains under-used. Greater uptake of this technique by young surgeons, backed by large-scale studies to confirm its clinical impact, should help to eliminate the discrepancy between use and value.

### Peer-review

In this review the authors present a critical analysis of the literature, from the year 2000, for the use of LUS during cholecystectomy and its performance in mapping the anatomy of the bile duct, detecting common bile duct stones, and preventing bile duct injury. A particular emphasis has been placed on complex inflammatory situations.

## REFERENCES

- 1 **Wong-Lun-Hing EM**, Lodewick TM, Stoot JH, Bemelmans MH, Olde Damink SW, Dejong CH, van Dam RM. A survey in the hepatopancreatobiliary community on ways to enhance patient recovery. *HPB (Oxford)* 2012; **14**: 818-827 [PMID: 23134183 DOI: 10.1111/j.1477-2574.2012.00546.x]
- 2 Gallstones and laparoscopic cholecystectomy. NIH Consensus Development Panel on Gallstones and Laparoscopic Cholecystectomy. *Surg Endosc* 1993; **7**: 271-279 [PMID: 8503085 DOI: 10.1007/BF00594118]
- 3 **Hogan NM**, Dorcaratto D, Hogan AM, Nasirawan F, McEntee P, Maguire D, Geoghegan J, Traynor O, Winter DC, Hoti E. Iatrogenic common bile duct injuries: Increasing complexity in the laparoscopic era: A prospective cohort study. *Int J Surg* 2016; **33** Pt A: 151-156 [PMID: 27512909 DOI: 10.1016/j.ijssu.2016.08.004]
- 4 **Halbert C**, Pagkratis S, Yang J, Meng Z, Altieri MS, Parikh P, Pryor A, Talamini M, Telem DA. Beyond the learning curve: incidence of bile duct injuries following laparoscopic cholecystectomy normalize to open in the modern era. *Surg Endosc* 2016; **30**: 2239-2243 [PMID: 26335071 DOI: 10.1007/s00464-015-4485-2]
- 5 **Way LW**, Stewart L, Gantert W, Liu K, Lee CM, Whang K, Hunter JG. Causes and prevention of laparoscopic bile duct injuries: analysis of 252 cases from a human factors and cognitive psychology perspective. *Ann Surg* 2003; **237**: 460-469 [PMID: 12677139 DOI: 10.1097/01.SLA.0000060680.92690.E9]
- 6 **Connor S**, Garden OJ. Bile duct injury in the era of laparoscopic cholecystectomy. *Br J Surg* 2006; **93**: 158-168 [PMID: 16432812 DOI: 10.1002/bjs.5266]
- 7 **Buddingh KT**, Nieuwenhuijs VB, van Buuren L, Hulscher JB, de Jong JS, van Dam GM. Intraoperative assessment of biliary anatomy for prevention of bile duct injury: a review of current and future patient safety interventions. *Surg Endosc* 2011; **25**: 2449-2461 [PMID: 21487883 DOI: 10.1007/s00464-011-1639-8]
- 8 **Sajid MS**, Leaver C, Haider Z, Worthington T, Karanjia N, Singh KK. Routine on-table cholangiography during cholecystectomy: a systematic review. *Ann R Coll Surg Engl* 2012; **94**: 375-380 [PMID: 22943325 DOI: 10.1308/003588412X13373405385331]
- 9 **Slim K**, Martin G. Does routine intra-operative cholangiography reduce the risk of biliary injury during laparoscopic cholecystectomy? An evidence-based approach. *J Visc Surg* 2013; **150**: 321-324 [PMID: 23911201 DOI: 10.1016/j.jvisurg.2013.06.002]
- 10 **Ford JA**, Soop M, Du J, Loveday BP, Rodgers M. Systematic review of intraoperative cholangiography in cholecystectomy. *Br J Surg* 2012; **99**: 160-167 [PMID: 22183717 DOI: 10.1002/bjs.7809]
- 11 **Sheffield KM**, Han Y, Kuo YF, Townsend CM, Goodwin JS, Riall TS. Variation in the use of intraoperative cholangiography during cholecystectomy. *J Am Coll Surg* 2012; **214**: 668-679; discussion 679-681 [PMID: 22366491 DOI: 10.1016/j.jamcollsurg.2011.12.033]
- 12 **Hublet A**, Dili A, Lemaire J, Mansvelt B, Molle G, Bertrand C. Laparoscopic ultrasonography as a good alternative to intraoperative cholangiography (IOC) during laparoscopic cholecystectomy: results of prospective study. *Acta Chir Belg*

- 2009; **109**: 312-316 [PMID: 19943585 DOI: 10.1080/00015458.2009.11680431]
- 13 **Halpin VJ**, Dunnegan D, Soper NJ. Laparoscopic intracorporeal ultrasound versus fluoroscopic intraoperative cholangiography: after the learning curve. *Surg Endosc* 2002; **16**: 336-341 [PMID: 11967692 DOI: 10.1007/s00464-001-8325-1]
  - 14 **El Shallaly G**, Seow C, Sharp C, Mughrabi A, Nassar AH. Intraoperative cholangiography time in laparoscopic cholecystectomy: timing the radiographer. *Surg Endosc* 2005; **19**: 1370-1372 [PMID: 16228860 DOI: 10.1007/s00464-004-2242-z]
  - 15 **Karthikesalingam A**, Markar SR, Weerakkody R, Walsh SR, Carroll N, Praseedom RK. Radiation exposure during laparoscopic cholecystectomy with routine intraoperative cholangiography. *Surg Endosc* 2009; **23**: 1845-1848 [PMID: 19118424 DOI: 10.1007/s00464-008-0279-0]
  - 16 **Falcone RA**, Fegelman EJ, Nussbaum MS, Brown DL, Bebbe TM, Merhar GL, Johannigman JA, Luchette FA, Davis K, Hurst JM. A prospective comparison of laparoscopic ultrasound vs intraoperative cholangiogram during laparoscopic cholecystectomy. *Surg Endosc* 1999; **13**: 784-788 [PMID: 10430685 DOI: 10.1007/s004649901099]
  - 17 **Birth M**, Roblick U, Brugmans F, Weiser HF, Bruch HP. Laparoscopic ultrasonography reliably visualizes bile-duct injuries - a blind randomized porcine study. *Langenbecks Arch Surg* 1999; **384**: 360-365 [PMID: 10473856 DOI: 10.1007/s004230050214]
  - 18 **Birth M**, Carroll BJ, Delinikolas K, Eichler M, Weiser H. Recognition of laparoscopic bile duct injuries by intraoperative ultrasonography. *Surg Endosc* 1996; **10**: 794-797 [PMID: 8694939 DOI: 10.1007/BF00189535]
  - 19 **Stiegmann GV**, Soper NJ, Filipi CJ, McIntyre RC, Callery MP, Cordova JF. Laparoscopic ultrasonography as compared with static or dynamic cholangiography at laparoscopic cholecystectomy. A prospective multicenter trial. *Surg Endosc* 1995; **9**: 1269-1273 [PMID: 8629207 DOI: 10.1007/BF00190157]
  - 20 **Catheline J**, Rizk N, Champault G. A comparison of laparoscopic ultrasound versus cholangiography in the evaluation of the biliary tree during laparoscopic cholecystectomy. *Eur J Ultrasound* 1999; **10**: 1-9 [PMID: 10502634 DOI: 10.1016/S0929-8266(99)00028-2]
  - 21 **Wu JS**, Dunnegan DL, Soper NJ. The utility of intracorporeal ultrasonography for screening of the bile duct during laparoscopic cholecystectomy. *J Gastrointest Surg* 1998; **2**: 50-60 [PMID: 9841968 DOI: 10.1016/S1091-255X(98)80103-0]
  - 22 **Rijna H**, Eijssbouts QA, Barkhof F, de Brauw LM, Cuesta MA. Assessment of the biliary tract by ultrasonography and cholangiography during laparoscopic cholecystectomy: a prospective study. *Eur J Ultrasound* 1999; **9**: 127-133 [PMID: 10413748 DOI: 10.1016/S0929-8266(99)00018-X]
  - 23 **Siperstein A**, Pearl J, Macho J, Hansen P, Gitomirsky A, Rogers S. Comparison of laparoscopic ultrasonography and fluorochoangiography in 300 patients undergoing laparoscopic cholecystectomy. *Surg Endosc* 1999; **13**: 113-117 [PMID: 9918609 DOI: 10.1007/s004649900917]
  - 24 **Olsen AK**, Bjerkeset OA. Laparoscopic ultrasound (LUS) in gastrointestinal surgery. *Eur J Ultrasound* 1999; **10**: 159-170 [PMID: 10586020 DOI: 10.1016/S0929-8266(99)00053-1]
  - 25 **Ohtani T**, Kawai C, Shirai Y, Kawakami K, Yoshida K, Hatakeyama K. Intraoperative ultrasonography versus cholangiography during laparoscopic cholecystectomy: a prospective comparative study. *J Am Coll Surg* 1997; **185**: 274-282 [PMID: 9291406 DOI: 10.1016/S1072-7515(97)00030-6]
  - 26 **Soper NJ**. Intraoperative detection: intraoperative cholangiography vs. intraoperative ultrasonography. *J Gastrointest Surg* 2000; **4**: 334-335 [PMID: 11185446 DOI: 10.1016/S1091-255X(00)80003-7]
  - 27 **Santambrogio R**, Montorsi M, Bianchi P, Opocher E, Verga M, Panzera M, Cosentino F. Common bile duct exploration and laparoscopic cholecystectomy: role of intraoperative ultrasonography. *J Am Coll Surg* 1997; **185**: 40-48 [PMID: 9208959 DOI: 10.1016/S1072-7515(97)00013-6]
  - 28 **Strasberg SM**, Herti M, Soper NJ. An analysis of the problem of biliary injury during laparoscopic cholecystectomy. *J Am Coll Surg* 1995; **180**: 101-125 [PMID: 8000648]
  - 29 **Machi J**. Accuracy of intraoperative ultrasound and cholangiography. *Surg Endosc* 1996; **10**: 363-364 [PMID: 8779081 DOI: 10.1007/BF00187397]
  - 30 **Kelly SB**, Remedios D, Lau WY, Li AK. Laparoscopic ultrasonography during laparoscopic cholecystectomy. *Surg Endosc* 1997; **11**: 67-70 [PMID: 8994992 DOI: 10.1007/s004649900297]
  - 31 **Röthlin MA**, Schöb O, Schlumpf R, Largiadèr F. Laparoscopic ultrasonography during cholecystectomy. *Br J Surg* 1996; **83**: 1512-1516 [PMID: 9014663 DOI: 10.1002/bjs.1800831107]
  - 32 **Tomonaga T**, Filipi CJ, Lowham A, Martinez T. Laparoscopic intracorporeal ultrasound cystic duct length measurement: a new technique to prevent common bile duct injuries. *Surg Endosc* 1999; **13**: 183-185 [PMID: 9918627 DOI: 10.1007/s004649900935]
  - 33 **Kubota K**, Bandai Y, Sano K, Teruya M, Ishizaki Y, Makuuchi M. Appraisal of intraoperative ultrasonography during laparoscopic cholecystectomy. *Surgery* 1995; **118**: 555-561 [PMID: 7652693 DOI: 10.1016/S0039-6060(05)80373-3]
  - 34 **Barteau JA**, Castro D, Arregui ME, Tetik C. A comparison of intraoperative ultrasound versus cholangiography in the evaluation of the common bile duct during laparoscopic cholecystectomy. *Surg Endosc* 1995; **9**: 490-496 [PMID: 7676368 DOI: 10.1007/BF00206833]
  - 35 **Santambrogio R**, Bianchi P, Opocher E, Mantovani A, Schubert L, Ghelma F, Panzera M, Verga M, Spina GP. Intraoperative ultrasonography (IOUS) during laparoscopic cholecystectomy. *Surg Endosc* 1996; **10**: 622-627 [PMID: 8662399 DOI: 10.1007/BF00188514]
  - 36 **Daly SC**, Deziel DJ, Li X, Thaqi M, Millikan KW, Myers JA, Bonomo S, Luu MB. Current practices in biliary surgery: Do we practice what we teach? *Surg Endosc* 2016; **30**: 3345-3350 [PMID: 26541721 DOI: 10.1007/s00464-015-4609-8]
  - 37 **Aziz O**, Ashrafian H, Jones C, Harling L, Kumar S, Garas G, Holme T, Darzi A, Zacharakis E, Athanasiou T. Laparoscopic ultrasonography versus intra-operative cholangiogram for the detection of common bile duct stones during laparoscopic cholecystectomy: a meta-analysis of diagnostic accuracy. *Int J Surg* 2014; **12**: 712-719 [PMID: 24861544 DOI: 10.1016/j.ijsu.2014.05.038]
  - 38 **Jamal KN**, Smith H, Ratnasingham K, Siddiqui MR, McLachlan G, Belgaumkar AP. Meta-analysis of the diagnostic accuracy of laparoscopic ultrasonography and intraoperative cholangiography in detection of common bile duct stones. *Ann R Coll Surg Engl* 2016; **98**: 244-249 [PMID: 26985813 DOI: 10.1308/rcsann.2016.0068]
  - 39 **Babel N**, Sakpal SV, Paragi P, Wellen J, Feldman S, Chamberlain RS. Iatrogenic bile duct injury associated with anomalies of the right hepatic sectoral ducts: a misunderstood and underappreciated problem. *HPB Surg* 2009; **2009**: 153269 [PMID: 19753137 DOI: 10.1155/2009/153269]
  - 40 **Izuishi K**, Toyama Y, Nakano S, Goda F, Usuki H, Masaki T, Maeta H. Preoperative assessment of the aberrant bile duct using multislice computed tomography cholangiography. *Am J Surg* 2005; **189**: 53-55 [PMID: 15701492 DOI: 10.1016/j.amjsurg.2004.06.039]
  - 41 **Yoshida J**, Chijiwa K, Yamaguchi K, Yokohata K, Tanaka M. Practical classification of the branching types of the biliary tree: an analysis of 1,094 consecutive direct cholangiograms. *J Am Coll Surg* 1996; **182**: 37-40 [PMID: 8542087]
  - 42 **Hashimoto M**, Matsuda M, Watanabe G. Intraoperative ultrasonography for reducing bile duct injury during laparoscopic cholecystectomy. *Hepatogastroenterology* 2010; **57**: 706-709 [PMID: 21033214]
  - 43 **Shen BY**, Li HW, Chen M, Zheng MH, Zang L, Jiang SM, Li JW, Jiang Y. Color Doppler ultrasonographic assessment of the risk of injury to major branch of the middle hepatic vein during laparoscopic cholecystectomy. *Hepatobiliary Pancreat Dis Int* 2003; **2**: 126-130 [PMID: 14607664]
  - 44 **Yau HM**, Lee KT, Kao EL, Chuang HY, Chou SH, Huang MF.

- Color Doppler ultrasound detection and classification of the tangential hepatic vein before laparoscopic cholecystectomy. *Surg Endosc* 2005; **19**: 1377-1380 [PMID: 16228862 DOI: 10.1007/s00464-004-2251-y]
- 45 **Misawa T**, Koike M, Suzuki K, Unemura Y, Murai R, Yoshida K, Kobayashi S, Yamazaki Y. Ultrasonographic assessment of the risk of injury to branches of the middle hepatic vein during laparoscopic cholecystectomy. *Am J Surg* 1999; **178**: 418-421 [PMID: 10612541 DOI: 10.1016/S0002-9610(99)00202-0]
- 46 **Birth M**, Lossin P, Brugmans F, Weiser HF. Vascular injuries within the hepatoduodenal ligament: recognition by laparoscopic color Doppler ultrasound. *Surg Endosc* 2000; **14**: 246-249 [PMID: 10741442 DOI: 10.1007/s004640000028]
- 47 **Pfluke JM**, Bowers SP. Laparoscopic intraoperative biliary ultrasonography: findings during laparoscopic cholecystectomy for acute disease. *J Laparoendosc Adv Surg Tech A* 2011; **21**: 505-509 [PMID: 21675861 DOI: 10.1089/lap.2010.0280]
- 48 **Hakamada K**, Narumi S, Toyoki Y, Nara M, Oohashi M, Miura T, Jin H, Yoshihara S, Sugai M, Sasaki M. Intraoperative ultrasound as an educational guide for laparoscopic biliary surgery. *World J Gastroenterol* 2008; **14**: 2370-2376 [PMID: 18416464 DOI: 10.3748/wjg.14.2370]
- 49 **Li JW**, Feng B, Wu L, Wang ML, Lu AG, Zang L, Mao ZH, Dong F, Zheng MH. Intraoperative cholangiography in combination with laparoscopic ultrasonography for the detection of occult choledocholithiasis. *Med Sci Monit* 2009; **15**: MT126-MT130 [PMID: 19721408]
- 50 **Perry KA**, Myers JA, Deziel DJ. Laparoscopic ultrasound as the primary method for bile duct imaging during cholecystectomy. *Surg Endosc* 2008; **22**: 208-213 [PMID: 17721807 DOI: 10.1007/s00464-007-9558-4]
- 51 **Machi J**, Oishi AJ, Tajiri T, Murayama KM, Furumoto NL, Oishi RH. Routine laparoscopic ultrasound can significantly reduce the need for selective intraoperative cholangiography during cholecystectomy. *Surg Endosc* 2007; **21**: 270-274 [PMID: 17122981 DOI: 10.1007/s00464-005-0817-y]
- 52 **Catheline JM**, Turner R, Rizk N, Barrat C, Buenos P, Champault G. Evaluation of the biliary tree during laparoscopic cholecystectomy: laparoscopic ultrasound versus intraoperative cholangiography: a prospective study of 150 cases. *Surg Laparosc Endosc* 1998; **8**: 85-91 [PMID: 9566558 DOI: 10.1097/00019509-199804000-00001]
- 53 **Gwinn EC**, Daly S, Deziel DJ. The use of laparoscopic ultrasound in difficult cholecystectomy cases significantly decreases morbidity. *Surgery* 2013; **154**: 909-915; discussion 915-917 [PMID: 24074430 DOI: 10.1016/j.surg.2013.04.041]
- 54 **Machi J**, Johnson JO, Deziel DJ, Soper NJ, Berber E, Siperstein A, Hata M, Patel A, Singh K, Arregui ME. The routine use of laparoscopic ultrasound decreases bile duct injury: a multicenter study. *Surg Endosc* 2009; **23**: 384-388 [PMID: 18528611 DOI: 10.1007/s00464-008-9985-x]
- 55 **Biffl WL**, Moore EE, Offner PJ, Franciose RJ, Burch JM. Routine intraoperative laparoscopic ultrasonography with selective cholangiography reduces bile duct complications during laparoscopic cholecystectomy. *J Am Coll Surg* 2001; **193**: 272-280 [PMID: 11548797 DOI: 10.1016/S1072-7515(01)00991-7]
- 56 **Deziel DJ**. Complications of cholecystectomy. Incidence, clinical manifestations, and diagnosis. *Surg Clin North Am* 1994; **74**: 809-823 [PMID: 8047943]
- 57 **Zha Y**, Chen XR, Luo D, Jin Y. The prevention of major bile duct injuries in laparoscopic cholecystectomy: the experience with 13,000 patients in a single center. *Surg Laparosc Endosc Percutan Tech* 2010; **20**: 378-383 [PMID: 21150413 DOI: 10.1097/SLE.0b013e3182008efb]
- 58 **Hori T**, Oike F, Furuyama H, Machimoto T, Kadokawa Y, Hata T, Kato S, Yasukawa D, Aisu Y, Sasaki M, Kimura Y, Takamatsu Y, Naito M, Nakauchi M, Tanaka T, Gunji D, Nakamura K, Sato K, Mizuno M, Iida T, Yagi S, Uemoto S, Yoshimura T. Protocol for laparoscopic cholecystectomy: Is it rocket science? *World J Gastroenterol* 2016; **22**: 10287-10303 [PMID: 28058010 DOI: 10.3748/wjg.v22.i47.10287]
- 59 **Avgerinos C**, Kelgiorgi D, Touloumis Z, Baltatzis L, Dervenis C. One thousand laparoscopic cholecystectomies in a single surgical unit using the "critical view of safety" technique. *J Gastrointest Surg* 2009; **13**: 498-503 [PMID: 19009323 DOI: 10.1007/s11605-008-0748-8]
- 60 **Sanjay P**, Fulke JL, Exon DJ. "Critical view of safety" as an alternative to routine intraoperative cholangiography during laparoscopic cholecystectomy for acute biliary pathology. *J Gastrointest Surg* 2010; **14**: 1280-1284 [PMID: 20535578 DOI: 10.1007/s11605-010-1251-6]
- 61 **Strasberg SM**, Brunt LM. Rationale and use of the critical view of safety in laparoscopic cholecystectomy. *J Am Coll Surg* 2010; **211**: 132-138 [PMID: 20610259 DOI: 10.1016/j.jamcollsurg.2010.02.053]
- 62 **Yamashita Y**, Kimura T, Matsumoto S. A safe laparoscopic cholecystectomy depends upon the establishment of a critical view of safety. *Surg Today* 2010; **40**: 507-513 [PMID: 20496131 DOI: 10.1007/s00595-009-4218-z]
- 63 **de Reuver PR**, Rauws EA, Bruno MJ, Lameris JS, Busch OR, van Gulik TM, Gouma DJ. Survival in bile duct injury patients after laparoscopic cholecystectomy: a multidisciplinary approach of gastroenterologists, radiologists, and surgeons. *Surgery* 2007; **142**: 1-9 [PMID: 17629994 DOI: 10.1016/j.surg.2007.03.004]
- 64 **Sherman JL**, Shi EW, Ranasinghe NE, Sivasankaran MT, Prigoff JG, Divino CM. Validation and improvement of a proposed scoring system to detect retained common bile duct stones in gallstone pancreatitis. *Surgery* 2015; **157**: 1073-1079 [PMID: 25712200 DOI: 10.1016/j.surg.2015.01.005]
- 65 **Yang MH**, Chen TH, Wang SE, Tsai YF, Su CH, Wu CW, Lui WY, Shyr YM. Biochemical predictors for absence of common bile duct stones in patients undergoing laparoscopic cholecystectomy. *Surg Endosc* 2008; **22**: 1620-1624 [PMID: 18000708 DOI: 10.1007/s00464-007-9665-2]
- 66 **Tranter SE**, Thompson MH. A prospective single-blinded controlled study comparing laparoscopic ultrasound of the common bile duct with operative cholangiography. *Surg Endosc* 2003; **17**: 216-219 [PMID: 12457223 DOI: 10.1007/s00464-002-8911-x]
- 67 **Shaaban H**, Welch A, Rao S. Laparoscopic ultrasound for the diagnosis of choledocholithiasis: quick, safe, and effective. *Surg Laparosc Endosc Percutan Tech* 2014; **24**: 274-276 [PMID: 24710230 DOI: 10.1097/SLE.0b013e31828fa907]
- 68 **Tranter SE**, Thompson MH. Potential of laparoscopic ultrasonography as an alternative to operative cholangiography in the detection of bile duct stones. *Br J Surg* 2001; **88**: 65-69 [PMID: 11136312 DOI: 10.1046/j.1365-2168.2001.01622.x]
- 69 **Lee SP**, Nicholls JF, Park HZ. Biliary sludge as a cause of acute pancreatitis. *N Engl J Med* 1992; **326**: 589-593 [PMID: 1734248 DOI: 10.1056/NEJM199202273260902]
- 70 **Santambrogio R**, Bianchi P, Opocher E, Verga M, Montorsi M. Prevalence and laparoscopic ultrasound patterns of choledocholithiasis and biliary sludge during cholecystectomy. *Surg Laparosc Endosc Percutan Tech* 1999; **9**: 129-134 [PMID: 11757540 DOI: 10.1097/00129689-199904000-00010]
- 71 **Grier JF**, Cohen SW, Grafton WD, Gholson CF. Acute suppurative cholangitis associated with choledochal sludge. *Am J Gastroenterol* 1994; **89**: 617-619 [PMID: 8147369]
- 72 **Mirbagheri SA**, Mohamadnejad M, Nasiri J, Vahid AA, Ghadimi R, Malekzadeh R. Prospective evaluation of endoscopic ultrasonography in the diagnosis of biliary microlithiasis in patients with normal transabdominal ultrasonography. *J Gastrointest Surg* 2005; **9**: 961-964 [PMID: 16137592 DOI: 10.1016/j.gassur.2005.03.002]
- 73 **Catheline JM**, Turner R, Paries J. Laparoscopic ultrasonography is a complement to cholangiography for the detection of choledocholithiasis at laparoscopic cholecystectomy. *Br J Surg* 2002; **89**: 1235-1239 [PMID: 12296889 DOI: 10.1046/j.1365-2168.2002.02198.x]
- 74 **Kothari SN**, Obinwanne KM, Baker MT, Mathiason MA, Kallies KJ. A prospective, blinded comparison of laparoscopic ultrasound with transabdominal ultrasound for the detection of gallbladder pathology in morbidly obese patients. *J Am Coll Surg* 2013; **216**: 1057-1062

[PMID: 23571143 DOI: 10.1016/j.jamcollsurg.2013.02.009]

- 75 **Nasu M**, Yoshimura S, Uomori T, Takehara K, Tanaka R, Miyano S, Machida M, Kitabatake T, Fujisawa M, Kojima K. The efficacy of intraoperative ultrasonography during laparoscopic cholecystectomy. *Hepatogastroenterology* 2012; **59**: 1003-1005

[PMID: 22580648]

- 76 **Sun SX**, Kulaylat AN, Hollenbeak CS, Soybel DI. Cost-effective Decisions in Detecting Silent Common Bile Duct Gallstones During Laparoscopic Cholecystectomy. *Ann Surg* 2016; **263**: 1164-1172 [PMID: 26575281 DOI: 10.1097/SLA.0000000000001348]

**P- Reviewer:** Chang YC, Kanat BH, Paduani GF **S- Editor:** Gong ZM  
**L- Editor:** A **E- Editor:** Li D





Published by **Baishideng Publishing Group Inc**  
7901 Stoneridge Drive, Suite 501, Pleasanton, CA 94588, USA  
Telephone: +1-925-223-8242  
Fax: +1-925-223-8243  
E-mail: [bpgooffice@wjgnet.com](mailto:bpgooffice@wjgnet.com)  
Help Desk: <http://www.f6publishing.com/helpdesk>  
<http://www.wjgnet.com>



ISSN 1007-9327

