

# Paraneoplastic atypical scleromyxedema with advanced gastric cancer



Se Jin Oh, MD, Seung Hwan Oh, MD, Ji-Young Jun, MD, Ji-Hye Park, MD, Jong Hee Lee, MD, PhD, Dong-Youn Lee, MD, PhD, Joo-Heung Lee, MD, PhD, and Jun-Mo Yang, MD, PhD  
Seoul, Korea

**Key words:** gastric cancer; paraneoplastic syndrome; scleromyxedema.

## INTRODUCTION

Scleromyxedema is a rare, chronic and progressive disorder of unknown origin characterized by a generalized papular eruption and sclerodermoid induration, with histopathologic features of mucin deposition and fibroblast proliferation.<sup>1</sup> The disease is usually associated with a monoclonal gammopathy.<sup>1,2</sup> However, only a few cases associated with neoplasms have been reported.<sup>1,3</sup> We report a case of paraneoplastic scleromyxedema with advanced gastric cancer.

## CASE REPORT

A 58-year-old woman presented with a several months' history of an erythematous swelling on the neck. The edema started on the posterior side of the neck and later progressed to the face, upper back, and both hands.

A few weeks before she visited our department, the patient had exhibited an asymptomatic 4 × 3.5-cm-sized mass with an ulcer by esophagogastroduodenoscopy during a general medical examination with the Korean National Cancer Screening Program. Adenocarcinoma of the esophagogastric junction and regional metastatic lymph node were confirmed and her stage was determined to be advanced.

Before the operation, she consulted with our department because of a progressive swelling of the skin. On physical examination, marked thickening of the skin with prominent folds over the posterior neck was observed (Fig 1, A). Erythematous indurative plaques were seen on the forehead with numerous small papules.

Erythematous swelling of the eyelids and fingers were also observed.

An incisional skin biopsy from the posterior neck was done to rule out scleredema. Pathologic examination showed myxoid degeneration in the upper dermis, increased fibroblasts, and thickened collagen in the dermis (Fig 2). These microscopic features were characteristic of scleromyxedema. The patient had multiple papules in a widespread pattern involving the forehead and fingers and did not have diabetes mellitus or any acute infection before the skin eruption.

The combined clinical presentation and microscopic examination of skin tissue strongly suggested the presence of scleromyxedema. A full endocrine work-up, including serum thyroid-stimulating hormone, free thyroxine, adrenocorticotropic hormone, and 24-h cortisol urine test, were within normal limits. Autoantibody screening produced negative results. In addition, protein electrophoresis with immunofixation in blood was negative for a monoclonal component.

The patient underwent subtotal gastrectomy and adjuvant chemotherapy for treatment of adenocarcinoma. One month after surgery, the swelling on the neck partially improved and flat balloon-like wrinkles remained. Following 3-month cycles of chemotherapy with tegafur, gimeracil, and oteracil potassium, the skin lesion ameliorated (Fig 1, B).

## DISCUSSION

Scleromyxedema is characterized by an extensively symmetrical eruption of small, waxy papules,

From the Department of Dermatology, Samsung Medical Center, Sungkyunkwan University School of Medicine, Seoul.

Funding sources: None.

Conflicts of interest: None declared.

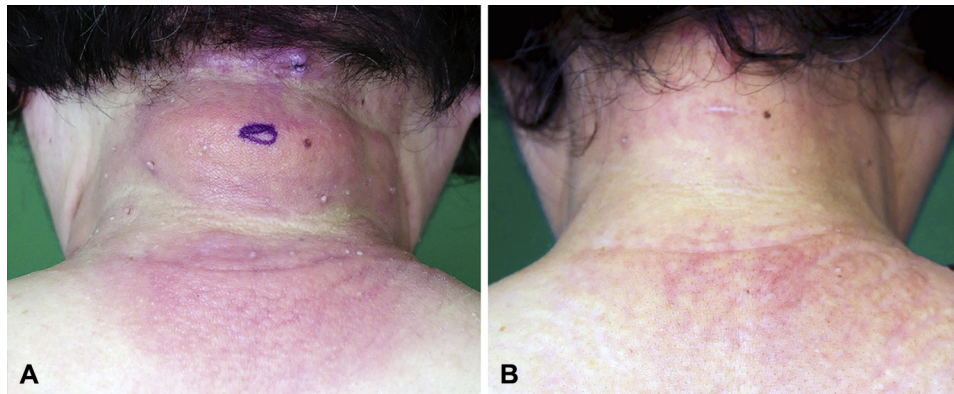
Correspondence to: Ji-Hye Park, MD, Department of Dermatology, Samsung Medical Center, Sungkyunkwan University School of Medicine, 81 Irwon Ro, Gangnam Gu, Seoul 06351, Republic of Korea. E-mail: [jh1204.park@samsung.com](mailto:jh1204.park@samsung.com).

JAAD Case Reports 2017;3:376-8.

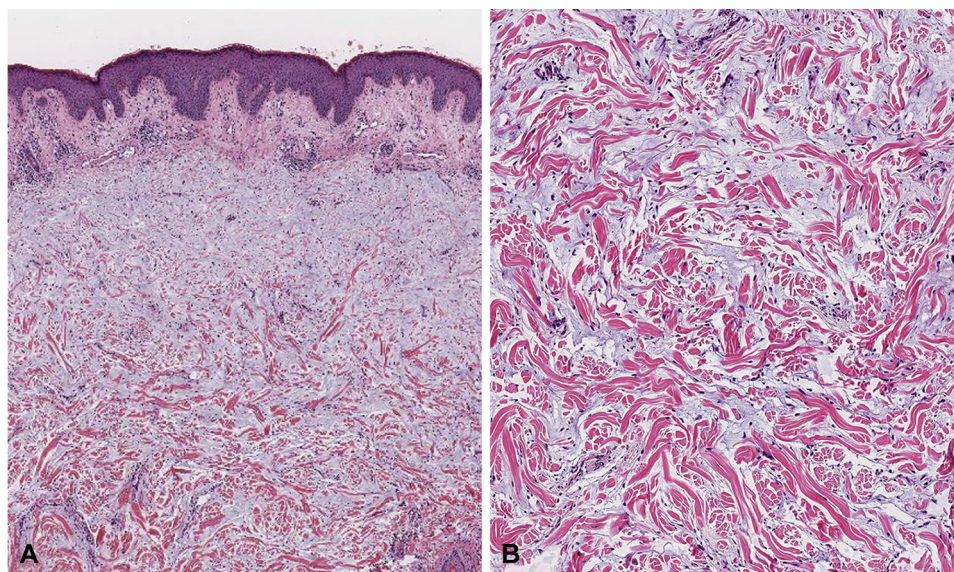
2352-5126

© 2017 by the American Academy of Dermatology, Inc. Published by Elsevier, Inc. This is an open access article under the CC BY-NC-ND license (<http://creativecommons.org/licenses/by-nc-nd/4.0/>).

<http://dx.doi.org/10.1016/j.jidcr.2017.04.005>



**Fig 1.** **A**, Skin lesions before treatment. Waxy papules on the scalp and indurated edema on the posterior neck. **B**, Improvement noticed after surgery.



**Fig 2.** **A**, Accumulation of large amounts of mucin. **B**, Thickened collagen in the dermis. (**A** and **B**, Hematoxylin-eosin stain; original magnifications: **A**,  $\times 40$ ; **B**,  $\times 100$ .)

which progress to sclerosis and induration of the skin, usually on the face, neck, upper trunk, arms, and thighs. In 2001, Rongioletti and Rebra<sup>3</sup> defined scleromyxedema, also known as generalized lichen myxedematosus using the following criteria: (1) generalized papular and sclerodermoid eruption; (2) mucin deposition, fibroblast proliferation, and fibrosis; (3) monoclonal gammopathy; and (4) the absence of thyroid disease. According to this classification, a case that shows typical clinical and histopathologic features without monoclonal gammopathy belongs to an atypical form of scleromyxedema.

Most patients with scleromyxedema have a monoclonal gammopathy, and other systemic manifestations are common. Disease presentation might involve gastrointestinal (eg, esophageal aperistalsis), musculoskeletal (eg, arthritis or myositis),

cardiovascular (eg, ischemic heart disease or cardiomyopathy), pulmonary (eg, obstructive or restrictive lung diseases), neurologic (eg, peripheral neuropathy), or ophthalmologic (eg, macular edema) problems.<sup>1</sup> However, the association between malignancy and scleromyxedema has rarely been described. Among the rare cases, multiple myeloma is the most commonly associated malignancy with scleromyxedema, followed by lymphoma and solid tumors.<sup>4-6</sup> To our knowledge, there is only 1 case reported showing an association of gastric cancer with scleromyxedema<sup>7</sup>; In this case report, a 44-year-old man with progressive thickening of the skin of his face, trunk, and extremities was found to have poorly differentiated metastatic carcinoma involving omentum 9 years after his skin eruption. The affected areas gradually increased, and he died 1 month after the detection of cancer. Thus,

the causal relationship between skin eruption and cancer was not obvious.

Gastric cancers might be associated with a variety of paraneoplastic disorders. Several paraneoplastic dermatoses, including acanthosis nigricans, florid cutaneous papillomatosis, and tripe palms, were reported to be associated with gastric cancer. Tumor production of transforming growth factor  $\alpha$  and epidermal growth factor is the proposed mechanisms for these disorders. Successful treatment of the underlying malignancy might result in improvement and occasionally resolution of the condition.<sup>8</sup> In our case, the patient's eruption improved after the removal of the tumor; thus, we propose the plausible attribution of paraneoplastic syndrome of gastric cancer. The pathogenesis of scleromyxedema with cancer is unknown. The correlation of serum paraprotein with the natural course of the disease is still debated. Also it has been suggested that a non-paraprotein circulating factor or altered immune regulation is involved in the course of the scleromyxedema.<sup>2,9</sup> Thus, it is likely that immune dysregulation associated with a malignant proliferation of cells could result in the pathogenesis of scleromyxedema.

Given the limited data regarding its course and prognosis due to its rare incidence, no standardized treatment of scleromyxedema exists. As a result, the therapeutic response varies greatly among patients. Systemic therapies, including high-dose dexamethasone, intravenous immunoglobulins, low- or high-dose melphalan, photopheresis, thalidomide, and autologous stem cell transplant, have been used.<sup>1</sup> Among patients with coexistent mucinosis and malignancy, treatment is known to be refractory and is highly dependent on the course of malignancy. Most of the treatments used resulted in poor outcomes; the skin lesions remained unchanged or had gotten worse.<sup>9</sup> However, several reports have described chemotherapy being given for the treatment of the primary cancer, resulting in the

regression of the skin lesions.<sup>1,5,6</sup> Also, there are 2 cases of scleromyxedema with malignancy that showed remission of skin lesions after surgery.<sup>9,10</sup> In our case, indurated cutaneous lesions improved spontaneously several weeks after surgery, and papules and swelling regressed during the course of chemotherapy. Thus, progressive improvement without treating the skin problem itself could suggest the paraneoplastic association.

In conclusion, clinicians should be aware of the potential associations of scleromyxedema with neoplasms. Paraneoplastic eruptions might have a better prognosis after surgery or chemotherapy.

#### REFERENCES

1. Rongioletti F, Merlo G, Cinotti E, et al. Scleromyxedema: a multicenter study of characteristics, comorbidities, course, and therapy in 30 patients. *J Am Acad Dermatol.* 2013;69:66-72.
2. Nofal A, Amer H, Alakad R, et al. Lichen myxedematosus: diagnostic criteria, classification, and severity grading. *Int J Dermatol.* 2017;56:284-290.
3. Rongioletti F, Rebora A. Updated classification of papular mucinosis, lichen myxedematosus, and scleromyxedema. *J Am Acad Dermatol.* 2001;44:273-281.
4. Krebs A, Muller A. [Lichen myxedematosus and multiple myeloma type IgG/kappa]. *Hautarzt.* 1980;31:649-653.
5. Gimenez Garcia R, Garcia SG, Suarez Vilela D, Moro Sanchez MJ. Scleromyxedema associated with non-Hodgkin lymphoma. *Int J Dermatol.* 1989;28:670-671.
6. Alberts AS, Schulz EJ, Falkson G, Simson IW, Coccia-Portugal MA. Normalization of skin appearance in a patient with scleromyxoedema after intensive chemotherapy for Hodgkin's disease. *Dermatologica.* 1989;178:221-224.
7. Farmer ER, Hambrick GW Jr, Shulman LE. Papular mucinosis. A clinicopathologic study of four patients. *Arch Dermatol.* 1982;118:9-13.
8. Yang YH, Zhang RZ, Kang DH, Zhu WY. Three paraneoplastic signs in the same patient with gastric adenocarcinoma. *Dermatol Online J.* 2013;19:18966.
9. Lo PY, Tzung TY. Lichen myxedematosus in a patient with hepatocellular carcinoma. *Br J Dermatol.* 2000;143:452-453.
10. Kubba R, McNeil NI, Rook A. Lichen myxoedematosus, Crohn's disease, and mucinous ovarian carcinoma. *Br J Dermatol.* 1975;93(Suppl):34-36.