



Uterine torsion in a full-term pregnant cat

Kohei Kuroda, Tomohiro Osaki, Kazuki Harada, Masamichi Yamashita, Yusuke Murahata, Kazuo Azuma, Takeshi Tsuka, Norihiko Ito, Tomohiro Imagawa and Yoshiharu Okamoto

Journal of Feline Medicine and Surgery Open Reports
1–4

© The Author(s) 2017

Reprints and permissions:

sagepub.co.uk/journalsPermissions.nav

DOI: 10.1177/2055116917726228

journals.sagepub.com/home/jfmsopenreports

This paper was handled and processed

by the European Editorial Office (ISFM)

for publication in *JFMS Open Reports*



Abstract

Case summary A 5-year-old intact female Maine Coon cat presented with a 2 day history of lethargy, anorexia and anaemia. The cat had bred 60 days previously and jumped from a height 3 days earlier, which was followed by a worsening of its condition. Ultrasonography revealed that two fetuses had died and one remained alive. Urgent surgical intervention was deemed necessary, and the cat underwent a blood transfusion and laparotomy. The right uterine horn was dark red in appearance and had rotated 360° in the clockwise direction at its base. Subsequently, an ovariohysterectomy and caesarean section were performed, and the fetus in the left uterine horn initially survived. Although the cat appeared to recover from anaemia and physical injury, the kitten died on postoperative day 1.

Relevance and novel information In cases involving only one twisted uterine horn, the fetuses located in the contralateral horn could potentially survive; however, many such fetuses do not survive, and only a few reports have described fetal survival in a pregnant cat with uterine torsion. In the present case, early surgical intervention and blood transfusion allowed us to save the cat. Our findings demonstrate the life-saving abilities of initial support treatment and early surgical intervention for both the pregnant cat and fetuses in cases of acute abdomen caused by uterine torsion.

Accepted: 13 July 2017

Introduction

Uterine torsion is defined as the twisting of a uterine horn or uterine body about the longitudinal axis.¹ Although this complication occurs frequently in cows, it has rarely been reported in other domestic animals, including cats. Uterine torsion is often related to pregnancy, and such cases occur during mid to late gestation.²

Although the aetiology of uterine torsion is unknown, broad ligament stretching caused by previous pregnancies, increased physical activity, uterine wall weakness, fetal movement and rough handling have been suspected as potential causes.³ For cats, if only one uterine horn is affected, fetuses located in the contralateral horn may, theoretically, survive. In practice, however, most previous reports have described the in utero deaths of fetuses in the unaffected horn; only a few authors have reported fetal survival in such cases.^{2,4} This report

describes a case of fetal survival in a full-term pregnant cat with uterine torsion.

Case description

A 5-year-old intact female Maine Coon cat presented at a local animal hospital with a 2 day history of lethargy, anorexia and pale mucous membranes (day 0). The cat had bred 60 days earlier and jumped from a height 3

Joint Department of Veterinary Clinical Medicine, Faculty of Agriculture, Tottori University, Tottori, Japan

Corresponding author:

Tomohiro Osaki DVM, PhD, Joint Department of Veterinary Clinical Medicine, Faculty of Agriculture, Tottori University, 4-101 Koyama-Minami, Tottori 680-8553, Japan
Email: tosaki@muses.tottori-u.ac.jp



Creative Commons Non Commercial CC BY-NC: This article is distributed under the terms of the Creative Commons

Attribution-NonCommercial 4.0 License (<http://www.creativecommons.org/licenses/by-nc/4.0/>) which permits non-commercial use, reproduction and distribution of the work without further permission provided the original work is attributed as specified on the SAGE and Open Access pages (<https://us.sagepub.com/en-us/nam/open-access-at-sage>).

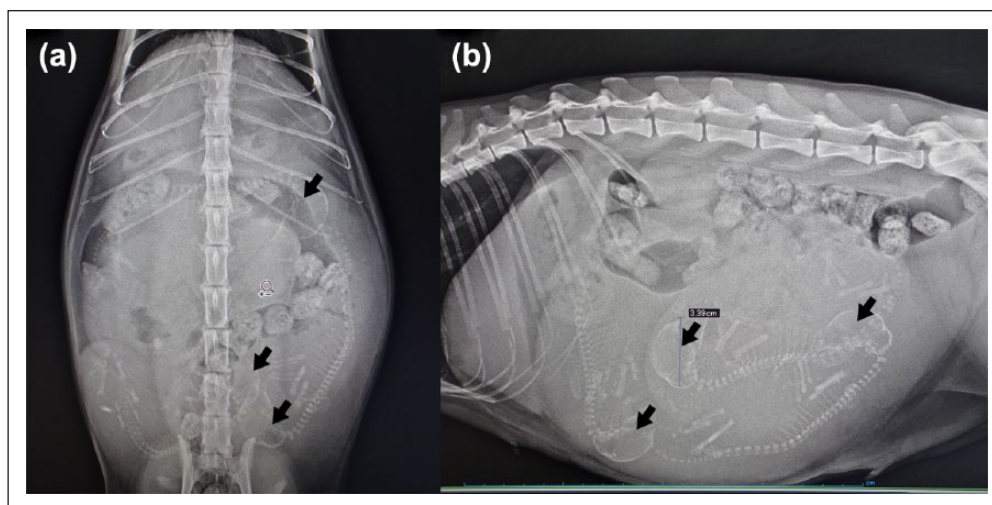


Figure 1 (a) Ventrodorsal and (b) lateral abdominal radiographs reveal three fetuses (arrows), large uterine horns and dorsally shifted bowels

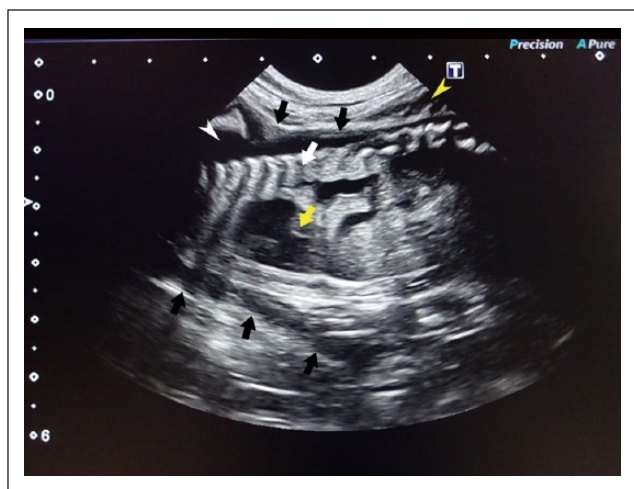


Figure 2 Ultrasonography reveals enlarged uterine horns (black arrows), free abdominal fluid (yellow arrowhead) and fetuses (white arrow). Movement of the heart was confirmed in one fetus (yellow arrow). Amniotic fluid exhibited relatively low echogenicity (white arrowhead)

days prior to presentation and experienced a subsequent worsening of its condition. The deaths of 2/3 fetuses were confirmed by ultrasonography, and the cat was treated with enrofloxacin (5 mg/kg SC; Baytril [Bayer]) and cefovecin sodium (8 mg/kg SC; Convenia [Zoetis Japan]).

The following day (day 1), the cat was referred to Tottori University Veterinary Medical Center for a caesarean section. Physical examination revealed rapid respiration and visibly pale mucous membranes, and laboratory blood tests revealed severe anaemia (red blood cells [RBCs] $213 \times 10^4/\mu\text{l}$; haemoglobin [HGB] 3.8 g/dl; haematocrit [HCT] 9.8%). An abdominal

radiograph revealed three fetuses, large uterine horns and bowels that had been shifted dorsally (Figure 1). A second ultrasonography examination revealed enlarged uterine horns, free abdominal fluid and fetuses (Figure 2). The amniotic fluid exhibited relatively low echogenicity. Although 2/3 fetuses were dead, a third surviving fetus was confirmed. Accordingly, an urgent surgical intervention was deemed necessary.

Preoperatively, the cat was premedicated with buprenorphine (0.02 mg/kg IV; Lepetan [Otsuka Pharmaceutical]), and general anaesthesia was induced with intravenous propofol (6 mg/kg; Propoflo [DS Pharma Animal Health]). After tracheal intubation, anaesthesia was maintained with isoflurane (Isoflu; DS Pharma Animal Health) and oxygen after tracheal intubation, and bupivacaine (1 mg/kg; Marcain 0.25% [AstraZeneca]) was administered epidurally for analgesia. The cat also received an intraoperative blood transfusion (50 ml).

A standard midline retroumbilical laparotomy revealed a moderate accumulation of dark-red haemoid ascites in the abdominal cavity (Figure 3a). The right uterine horn was dark red in colour (Figure 3b) and had rotated 360° in the clockwise direction around its base (Figure 3c,d). Although the left uterine horn remained in a normal position, it was pale in colour as a result of anaemia (Figure 3d). We incised both uterine horns and performed a caesarean section, after which the surviving fetus from the left horn began to breathe weakly. Subsequently, an ovariohysterectomy was performed without releasing uterine torsion to prevent the release of endotoxins into systemic circulation. The abdominal cavity was then washed with warm 0.9% saline, and the abdominal wall was closed routinely using 3-0 absorptive monofilament sutures (PDS Plus; Johnson & Johnson).

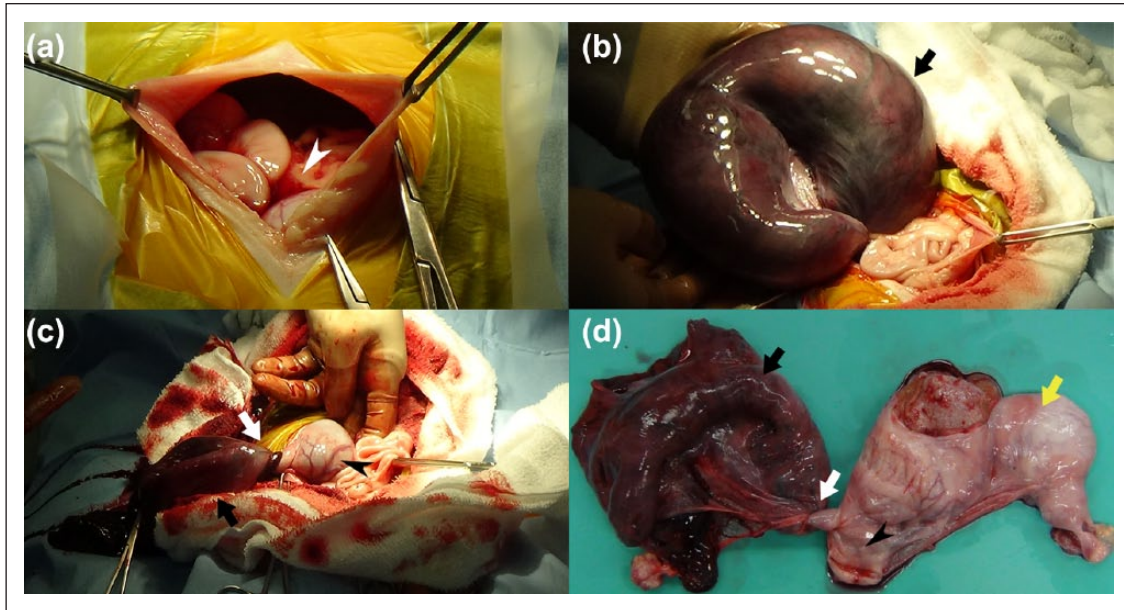


Figure 3 (a–c) Intraoperative and (d) postoperative photographs of uterine torsion. The accumulation of dark-red haemoid ascites (white arrowhead) in the abdominal cavity is visible. The right uterine horn (black arrow) is dark red in colour and exhibits 360° rotation in the clockwise direction (white arrow) around its base (black arrowhead). The left uterine horn is pale because of anaemia (yellow arrow)

Postoperatively, the kitten consumed a small amount of the cat's milk. However, the kitten's physical condition worsened progressively on day 2, leading to death. By contrast, the cat appeared likely to experience a recovery from anaemia (RBCs $376 \times 10^4/\mu\text{l}$, HGB 5.6 g/dl, HCT 17.0%) and restoration of physical condition. The cat was returned to the initial local animal hospital on postoperative day 3.

Discussion

In cats, uterine torsion is an uncommon and rarely reported event.⁵ In this case, an early surgical intervention and blood transfusion allowed us to save the cat. Furthermore, to our knowledge, this is the first report of uterine torsion in which a live fetus was born via caesarean section.

The preoperative diagnosis of uterine torsion is difficult or potentially impossible, according to some reports,^{1,2,4} and we were similarly unable to make a definitive diagnosis before surgery in the present case. However, clinical signs such as anorexia, lethargy, abdominal distention, abdominal pain and anaemia have been described in previous reports.^{2–6} In the present case, although the cat presented at the animal hospital with clinical anorexia and lethargy and laboratory-confirmed severe anaemia, these signs are not specific for uterine torsion and are also seen with pyometra, a condition included in the differential diagnosis of uterine torsion.⁷ Here, radiographic examination and ultrasonography, particularly colour Doppler, were essential for

determining the fetal status and presence of free fluid. However, these modalities did not confirm a definitive diagnosis of uterine torsion. In humans, uterine torsion is diagnosed using contrast-enhanced CT.^{8,9} Therefore, contrast-enhanced CT may also be required for veterinary cases of suspected uterine torsion.

In many reported cases of uterine torsion, fetuses in both the affected and unaffected horns failed to survive.^{1,2,4} Only one report describes a case of natural live birth wherein uterine torsion was diagnosed postpartum.¹⁰ In the present case, 1/3 fetuses was born live from the untwisted horn as a result of immediate surgical intervention. Unfortunately, the kitten died of unknown causes on the following day, although a uterine torsion-related maternal problem was considered potentially responsible.

It is important to point out in this case that the cat was treated with enrofloxacin at a local animal hospital. Enrofloxacin, however, has the risk of retinotoxicity and the potential for interfering with cartilage development. Therefore, alternative antibiotic choice might have been preferable in this case.

The mother cat in this case appeared to recover from anaemia and physical injury. According to previous reports, cats that receive initial supportive treatment and early surgical interventions tend to have good prognoses,⁶ and in the present case we were able to perform an immediate blood transfusion and surgical intervention. We recommend that surgical intervention be considered immediately for suspected cases of uterine torsion.

Conclusions

Our case is one of only a few reports of fetal survival in a full-term pregnant cat with uterine torsion. For suspected cases of uterine-related acute abdomen, initial support treatment and early surgical intervention are potentially life saving and required for a definitive diagnosis. Furthermore, fetal survival must be considered in cases involving late-term pregnant cats. However, we should fully consider the risk of neonatal death even if a fetus has been saved.

Conflict of interest The authors declared no potential conflicts of interest with respect to the research, authorship, and/or publication of this article.

Funding The authors received no financial support for the research, authorship, and/or publication of this article.

References

- 1 Biller DS and Haibel GK. **Torsion of the uterus in a cat.** *J Am Vet Med Assoc* 1987; 191: 1128–1129.
- 2 Thilagar S, Yew YC, Dhaliwal GK, et al. **Uterine horn torsion in a pregnant cat.** *Vet Rec* 2005; 157: 558–560.
- 3 Stanley SW and Pacchiana PD. **Uterine torsion and metabolic abnormalities in a cat with a pyometra.** *Can Vet J* 2008; 49: 398–400.
- 4 Bal-Bó ÍS, Corrêa TO, Ferreira MP, et al. **Uterine torsion in domestic feline – case report.** *Ars Vet Jabot* 2013; 29: 88–92.
- 5 Matsumoto H, Kakehata T and Hanada K. **A case of uterine torsion associated with uterine endometrial polyps in a non-gravid cat.** *J Anim Clin Med* 2009; 18: 35–40.
- 6 Ridyard A, Welsh EA and Gunn-Moore DA. **Successful treatment of uterine torsion in a cat with severe metabolic and haemostatic complications.** *J Feline Med Surg* 2000; 2: 115–119.
- 7 Agudelo CF. **Cystic endometrial hyperplasia-pyometra complex in cats. A review.** *Vet Q* 2005; 27: 173–182.
- 8 Jeong YY, Kang HK, Park JG, et al. **CT features of uterine torsion.** *Eur Radiol* 2003; 13: L249–L250.
- 9 Roy C, Bierry G, Ghali S El, et al. **Acute torsion of uterine leiomyoma: CT features.** *Abdom Imaging* 2004; 30: 120–123.
- 10 Young JD, Hillis GP and McKibbin ML. **Uterine torsion in a cat.** *Can Vet J* 1991; 32: 479.