

Defunctioning stoma- a prognosticator for leaks in low rectal restorative cancer resection: A retrospective analysis of stoma database



Haytham Abudeeb^{b, *}, Ahmed Hammad^d, Ajogwu Ugwu^c, Jamshid Darabnia^e,
Lee Malcomson^b, Min Maung^a, Khurram Khan^a, Clare Mclaughlin^a, Arijit Mukherjee^a

^a Hairmyres Hospital, South Lanarkshire NHS Trust, United Kingdom

^b The Christie Hospital, Christie NHS Trust, United Kingdom

^c Monklands Hospital, South Lanarkshire NHS Trust, United Kingdom

^d St. Thomas Hospital, Guy's & St. Thomas NHS Trust, United Kingdom

^e Dr Grey Hospital, NHS Grampian, United Kingdom

H I G H L I G H T S

- Case series to assess reduction of anastomotic leak with loop ileostomy in anterior resection.
- Loop ileostomy mitigates the risk of anastomotic leak and reduces consequence.
- Short and long-term complications are minimal with no extra risk.

A R T I C L E I N F O

Article history:

Received 22 March 2017

Received in revised form

16 July 2017

Accepted 17 July 2017

Keywords:

Low rectal cancer

Loop ileostomy

Anastomotic leak

Reversal

A B S T R A C T

Aims: Low anterior resection (LAR) has higher risk of anastomotic leak with its attendant morbidity-mortality. De-functioning loop ileostomy (DLI), claimed to mitigate the consequences of anastomotic leak, has been questioned in recent years. This study aims to evaluate the impact of ileostomy on LAR. **Methods:** A retrospective analysis of stoma database. 136 patients with stoma (March 2011–July 2015) were assessed. Data was analysed in respect to LAR anastomotic leak rate, impact on morbidity-mortality, short and long-term stoma complications, rate of ileostomy reversal and reasons for non-reversal.

Results: 45 patients had loop ileostomy for LAR. Male (28) to female (17) ratio was 1.65:1 with median age of 69 (IQR: 56–75.5). Only 3 anastomotic leaks (3/45, 6.5%) occurred, all treated conservatively with no mortality. 29 had reversal, average reversal time is 10 months (3–24) and 5 awaiting. Reasons for non-reversal included patients' choice (7), death from cardiac cause (1), chemotherapy (1), unfit for surgery (1) and failed reversal (1). Acute complications included high output & reversible AKI (1), bleeding (3) and minor complications (6) as skin excoriation, separation and appliance issues. Parastomal hernia was repaired during reversal (12/15).

Conclusions: De-functioning ileostomy for LAR is a safe procedure with low morbidity. Most stomas are reversible. Series highlights a late reversal contrary to the nationally recommended guidelines. Most interestingly, the study demonstrated de-functioning mitigated clinical consequences of anastomotic leak to an extent that reoperation was avoidable, in keeping with recent meta-analysis indicating a significantly low anastomotic leakage rates and reoperation. Larger study is invaluable to substantiate findings.

© 2017 The Authors. Published by Elsevier Ltd on behalf of IJS Publishing Group Ltd. This is an open access article under the CC BY-NC-ND license (<http://creativecommons.org/licenses/by-nc-nd/4.0/>).

1. Introduction

Anastomotic leak is still the most serious complication associated with anterior resection for rectal cancer. Even with all the advances in surgery, the risk is up to 14% [1] especially with low

* Corresponding author.

E-mail address: abudeeb.ha@gmail.com (H. Abudeeb).

anterior resection in post TME and neoadjuvant chemoradiotherapy era. Male gender, ASA grading, extensive tumour resection and emergency surgery are all considered independent risk factors [2] which increase the risk of anastomotic leaks yet cannot be altered. DLI, on the other hand is an appropriate option to reduce that risk or at least reduce the consequence of anastomotic leak.

There is still much controversy associated with loop ileostomy in recent literature with discussion about the risks versus benefits in relation to this operation. The question remains whether loop ileostomy, as an added procedure both formation and reversal, is cost effective and safe to perform in all patients or it is just an additional burden to the service. Many surgeons still wonder when to de-function with the ultimate questions of which anastomoses is at high risk for leak or should all mid/low anterior resections be de-functionalised. Does a DLI reduce the risk of leak or does it only reduce the consequence associated with the complication? If a loop ileostomy is to be used to mitigate the risk, do we need to prepare the bowel or would an unprepared bowel serve the same purpose. If bowel preparation is required then when such a decision is made or do we need to prepare all the anterior resections.

Available evidence shows that loop ileostomy mitigates the consequences of anastomotic leak, as shown in prospective randomized studies [1,3]. Additionally, a meta-analysis of 4 RCTs and 21 non-randomized studies with a sample size of 11,429 concluded that a de-functioning stoma decreases anastomotic leak and reoperation [4]. Some surgeons support this procedure as it is considered a safe, simple procedure with minimal complications and only requires a short hospital stay for the reversal. It is an exposure to another operation but it can be argued that whoever is fit for a major operation such as anterior resection should be fit enough for reversal with no added risks.

Others argue that the evidence is lacking and that loop ileostomy has not shown that it reduces the risk of a leak nor reduces the consequences. They feel that anastomotic leak is a recognised risk which we must expect regardless of the protective measures taken such as bowel preparation and de-functioning. Furthermore, it is considered inappropriate to give bowel preparation to all patients for anterior resection due to the high risk associated with it especially with enhanced recovery protocols. A selective approach to bowel preparation is a difficult one as surgeons might be able to anticipate difficult cases or high-risk ones, but not necessarily anastomotic leaks to the point where they will be able to decide which patients to prepare. Our study was designed to answer some of these questions with an attempt to standardize an approach to mid/low anterior resection that is safe, cost effective and based on medical evidence.

2. Method

Loop ileostomies have been used in our hospital for selective cases with anterior resections for many years. This study looked at

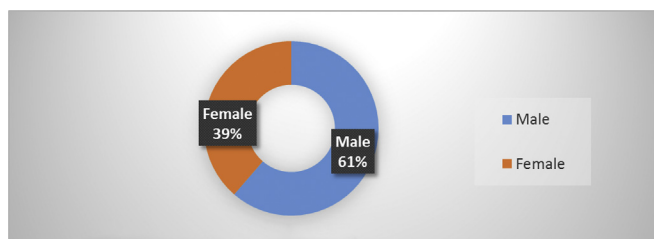


Fig. 1. Male–female distribution.

our colorectal cancer prospective database and extracted all cases of loop ileostomy as temporary DLI for LAR within this hospital who have been followed up by our stoma nurses. This is a case series which has been reported in line with the PROCESS criteria [5]. Cases have been collected from March 2011 to July 2015 and included open and laparoscopic anterior resections as well as reversal under consultant surgeons. Our main objective was to detect whether loop ileostomy reduces risk of anastomotic leak or at least mitigate the consequence of leak. We also assessed the short and long-term complications associated with loop ileostomy as procedure, both formation and reversal. All our patients were consented as anterior resection +/- loop ileostomy. Patients are pre-marked and given bowel preparation. Most patients are reviewed by a stoma nurse before the procedure and educated about stomas. Cases include open and laparoscopic anterior resections and stoma formations were all trephined at right iliac fossa with a spout. Patients were trained by the stoma nurse after the procedure and deemed stoma independent prior to discharge. The patient was reviewed regularly by both the surgical and stoma teams, and if no adjuvant chemotherapy was required, arrangements were made for reversal as soon as appropriate. Patients had contrast enema prior to reversal to assess the rectal anastomosis. All loop ileostomy reversals are admitted from day surgery unit and the reversal is carried out under general anaesthetic through an elliptical incision around the stoma using either a stapler or hand sewn anastomosis. All patients were reviewed in clinic as per colorectal follow up protocol thereafter. Our results were presented using a descriptive analysis.

3. Result

45 patients had a loop ileostomy for LAR. Male (28) to female (17) ratio was 1.65:1 (Fig. 1), median age 69 years (IQR: 56–75.5). Only 3 rectal anastomotic leaks (3/45, 6.7%) (Fig. 2) occurred, diagnosed with CT scan and based on clinical assessment and suspicious of leak. All were treated conservatively with no mortality. Of all the patients, 27 had their stoma reversed with an average reversal time of 10 months (3–24 months range) (Figs. 3 and 4). At the time of writing this piece, 5 are awaiting reversal. Reasons for non-reversal of stoma included patients' choice (7), death from cardiac cause (1), chemotherapy (1), unfit for surgery (1) and failed reversal (1).

Acute complications after initial anterior resection included high output & reversible AKI (1) & bleeding (3). Minor complications (6) included skin excoriation, muco-cutaneous separation, entero-cutaneous fistula & appliance issues. Parastomal hernias were repaired during reversal (12/15). Median follow up of 48 months.

Post reversal, no anastomotic leaks from either small bowel nor rectal anastomosis were noted. Minor infections from the stoma reversal wound which were treated conservatively with no delay in hospital discharge.

4. Discussion

Two recognised studies have shown that the anastomotic leak rate associated with low anterior resection is 10.3%. Mathiessen et al. [6], a multicentre randomized trial included 116 patients with 12 patients experiencing anastomotic leaks, while Phillips et al. [7] reported a 10.3% anastomotic leak rate but 8% clinical leak. Our case series has shown that we have an anastomotic leak of 6.5% (3/45) which is lower than what has been noted in previous trials. Interestingly, all 3 cases which had anastomotic leak in this study did not require surgical intervention and were discharged home with no further complications. Patients were diagnosed with CT scans on clinical suspicion. A multicentre study with large numbers

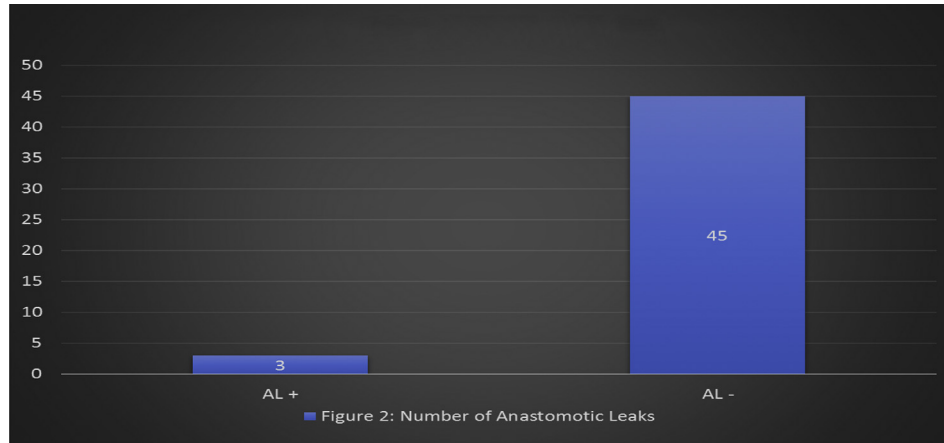


Fig. 2. Number of anastomotic leaks.

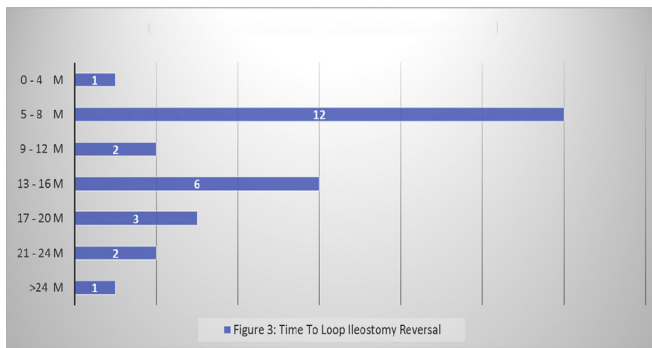


Fig. 3. Time to Loop ileostomy Reversal.

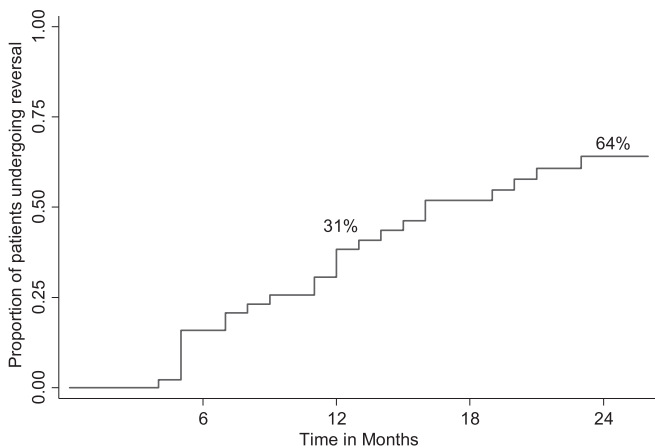


Fig. 4. Time to defunctioning loop reversal.

(n = 2729) of which 881 patients [1] received a protective stoma for LAR revealed similar anastomotic leak rates in those who received a stoma & those who did not (14.5 versus 14.2% respectively). However, DLI mitigated the consequences of an anastomotic leak as the incidence of leaks requiring surgical intervention was significantly lower (3.6 versus 10.1%; P < 0.001), as was the mortality rate. It is of great importance that the bowel is prepared for these patients as an unprepared colon would still have the same negative effect and the implication of anastomotic leak even after de-functioning and therefore all patients with mid/low anterior resection were given

bowel preparation.

Loop ileostomy reversal as an added procedure, in our study, did not cause any additional complications that prolonged the hospital stay or required a return to theatre in the immediate postoperative period. Bleeding was noted as a complication of loop ileostomy formation but the case was treated conservatively with observation only. All other minor complications were dealt with by the stoma nurses. A long-term complication was one patient with acute kidney injury requiring re admission. This was one incident which the department dealt with by increasing stoma education and strict stoma output protocol designed by surgical team, stoma team, dietetics and pharmacist in this hospital with no further complications observed. 15 patients developed parastomal hernias with no incident of strangulation. 12 patients had the hernia repaired on reversal and none of the cases required a mesh repair.

Minor complications that were noted included skin excoriation, mucocutaneous separation and appliance issues were all dealt with at stoma nurse level and addressed appropriately. No delay in discharge was noted from these complications and they were all dealt with in a timely manner with outpatient input at stoma clinics. The stoma service and input was available to all our patients pre-and postoperatively for both anterior resection and after reversal with appropriate support to all patients.

Our complication rate was almost 25%, which is similar to other studies [8,9] but were mainly minor complications which did not delay patient discharge on their initial admission for the anterior resection and similarly no major complications were noted following the reversal. Parastomal hernia were seen in 15 patients which 12 were repaired during reversal with simple closure. Our rate of parastomal hernia is higher than noted in literature but this can be due to delay in the reversal [10].

The department was proactive in arranging reversals of loop ileostomies and the patient had been listed for reversal as soon as deemed appropriate after recovery. All patients had a contrast enema prior to reversal to assess the rectal anastomosis.

A randomized study was carried out at York Teaching Hospital [11] during the period 2003–2007 to look at the feasibility of early reversal with a sample size of 26 patients, the study concluded that in carefully selected patients, early reversal of DLI is feasible, technically easier and has shorter operative time which can also lead to significant cost savings. 60% (27/45) of all patients in this series had their stoma reversed within 24 months with an average reversal time of 10 months. Of the 16 patients who were not reversed after 24 months, surprisingly, the most common cause of non-reversal was patient's choice. It is longer than the

recommended 3 months [11–13] but no complications were observed due to delay.

There were certain issues with our study. This is a retrospective case series and some of the data were not available requiring review of case notes in some cases. There was not a set protocol for this study and therefore no set follow up period has been stated. Most information was gathered by stoma nurses and specialist clinical nurses at the follow up clinic, mainly for colorectal cancer follow up. More serious complications were noted during the study, primarily the re admission for acute kidney injury due to high stoma output. This was a serious issue which the hospital dealt with in an appropriate manner. This can only be avoided with increasing cost by increasing education and input as well as medication use including loperamide, codeine and dioralyte. We might have been vigilant with addressing this issue but it is a serious complication with implications that cannot be ignored.

The most obvious limitation in our case series is that there is no compare group to provide us with a measurable statistical analysis to support our outcomes. A prospective multicentre randomized study would be most suitable for such comparison between de-functioned patients and non-de-functioned patients. A further comparison would be between open vs laparoscopic anterior resections with loop ileostomy, but our data lack good numbers in total and less laparoscopic case to open. Furthermore, our data are missing certain information including patients' co-morbidity and ASA, which would affect the accuracy of our outcome and conclusions, as young, fit patients are more likely to be reversed in comparison to elderly frail patients [14].

5. Conclusion

DLI for LAR is a safe procedure with acceptable morbidity compared with that from a possible anastomotic leak. This study highlights the fact that DLI with its known minor complications is possibly a better option than the attendant morbidity & mortality associated with an anastomotic leak which are well-known. Most interestingly, the study demonstrated DLIs mitigated clinical consequences of anastomotic leak to an extent that reoperation was avoidable, in keeping with recent meta-analysis indicating a significantly low anastomotic leakage and re-operation rate after de-functioning in low anterior resection. Larger prospective randomized study is invaluable to substantiate findings.

Most stomas are reversible & this series highlights a late reversal contrary to the nationally agreed policy of 90 days being often affected by service demands. Effective planning for dedicated stoma reversal lists could further reduce stoma related morbidity. We would strongly advocate for de-functioning loop ileostomy in all cases of low rectal cancer.

Ethical approval

No ethical approval required as it was a case notes review only.

Sources of funding

No funding provided for this study.

Author contribution

Haytham Abudeeb: study design, data collections, data analysis and writing.

Ahmed Hammad: Study design, data collection and data

analysis.

Ajogwu Ogwu: Data collection, data analysis and writing.

Jamished Darabnia: Data collection and data analysis.

Lee Malcomson: Data Analysis and writing.

Min Maung: Data collection.

Khurram Khan: Data collection.

Clare McLaughlin: Data collection.

Arijit Mukherjee: Study design, data analysis and writing.

Conflicts of interest

No conflict of interest from all authors.

Guarantor

Mr Haytham Abudeeb (abudeeb.ha@gmail.com).

Research registration unique identifying number (UIN)

Researchregistry2278.

References

- [1] I.1 Gasting, F. Marusch, R. Steinert, S. Wolff, F. Koeckerling, H. Lippert, Working Group 'Colon/Rectum Carcinoma'. Protective defunctioning stoma in low anterior resection for rectal carcinoma, *Br. J. Surg.* 92 (9) (2005 Sep) 1137–1142.
- [2] Bakker IS1, Grossmann I, Henneman D, Havenga K, Wiggers T. Risk Factors for Anastomotic Leakage and Leak-related Mortality after Colonic Cancer Surgery in a Nationwide Audit.
- [3] G.G.1 Chude, N.V. Rayate, V. Patris, M. Koshariya, R. Jagad, J. Kawamoto, N.J. Lygidakis, Defunctioning loop ileostomy with low anterior resection for distal rectal cancer: should we make an ileostomy as a routine procedure? A prospective randomized study, *Hepatogastroenterology* 55 (86–87) (2008 Sep–Oct) 1562–1567.
- [4] W.S.1 Tan, C.L. Tang, L. Shi, K.W. Eu, Meta-analysis of defunctioning stomas in low anterior resection for rectal cancer, *Br. J. Surg.* 96 (5) (2009 May) 462–472, <http://dx.doi.org/10.1002/bjs.6594>.
- [5] R.A. Agha, A.J. Fowler, S. Rammohan, I. Barai, D.P. Orgill, The PROCESS Group, The PROCESS statement: preferred reporting of case series in surgery, *Int. J. Surg.* 36 (Pt A) (2016) 319–323.
- [6] Pete Matthiessen, Olof Hallböök, Jörgen Rutegård, Göran Simert, Rune Sjö Dahl, Defunctioning stoma reduces symptomatic anastomotic leakage after low anterior resection of the rectum for cancer a randomized multicenter trial, *Ann. Surg.* 246 (2) (2007 Aug) 207–214.
- [7] B.R. Phillips, L.J. Harris, P.J. Maxwell, G.A. Isenberg, S.D. Goldstein, Anastomotic leak rate after low anterior resection for rectal cancer after chemoradiation therapy, *Am. Surg.* 76 (8) (2010 Aug) 869–871. PMID: 20726419.
- [8] E. Prskus, E. Kildusis, E. Smoklskas, M. Ambrazevicius, K. Strupas, Complication after loop ileostomy closure: a retrospective analysis of 132 patients, *Gastrointest. Med. Surg.* 30 (2014) 276–280.
- [9] A. El-Hussuna, M. Lauritsen, S. Bulow, Relatively high incidence of complications after loop ileostomy reversal, *Dan. Med. J.* 59 (10) (2012) A4517.
- [10] Suzanne Gillern, Joshua I.S. Bleier, Parastomal hernia repair and reinforcement: the role of biologic and synthetic materials, *Clin. Colon Rectal Surg.* 27 (4) (2014 Dec) 162–171.
- [11] K. Lasithiotakis, A. Aghahoseini, D. Alexander, Is early reversal of defunctioning ileostomy a shorter, easier and less expensive operation? *World J. Surg.* (2016 Feb 23) [Epub ahead of print].
- [12] Z.J.1 Cong, L.H.2 Hu, M.3 Zhong, L.3 Chen, Diverting stoma with anterior resection for rectal cancer: does it reduce overall anastomotic leakage and leaks requiring laparotomy? *Int. J. Clin. Exp. Med.* 8 (8) (2015 Aug 15) 13045–13055 eCollection 2015.
- [13] Zhi-Jie Cong, Liang-Hao Hu, Zheng-Qian Bian, Guang-Yao Ye, Min-Hao Yu, Yun-He Gao, Zhao-Shen Li, En-Da Yu, Ming Zhong, Systematic Review of Anastomotic Leakage Rate According to an International Grading System Following Anterior Resection for Rectal Cancer, September 25, 2013, <http://dx.doi.org/10.1371/journal.pone.0075519>.
- [14] A.J. Kuryba, N.A. Scott, J. Hill, J.H. van der Meulen, K. Walker, Determinants of stoma reversal in rectal cancer patients who had an anterior resection between 2009 and 2012 in the English National Health Service, *Colorectal Dis.* (2016 Mar 23), <http://dx.doi.org/10.1111/codi.13339>.