

# Prevalence of FAI radiographic hip abnormalities in elite soccer players: are there differences related to skeletal maturity?

Juan Monckeberg,<sup>1</sup> Tomas Amenabar,<sup>1,2</sup> Claudio Rafols,<sup>1</sup> Nicolas Garcia,<sup>1</sup> Roberto Yañez<sup>1</sup>

**To cite:** Monckeberg J, Amenabar T, Rafols C, *et al*. Prevalence of FAI radiographic hip abnormalities in elite soccer players: are there differences related to skeletal maturity?. *BMJ Open Sport Exerc Med* 2017;**2**:e000162. doi:10.1136/bmjsem-2016-000162

► Prepublication history is available. To view please visit the journal (<http://dx.doi.org/10.1136/bmjsem-2016-000162>).

Accepted 9 January 2017

## ABSTRACT

**Background:** Femoroacetabular impingement (FAI) can be a source of hip pain in young adults. Some reports have revealed that participation in high-impact sports may play a role in the development of cam deformity, and there is a higher prevalence of signs of cam impingement in asymptomatic adolescents who participate in soccer and basketball than in non-athlete controls; however, current evidence is scarce regarding the initiation and development of deformities.

**Purpose:** The aim of this study was to evaluate the prevalence of radiographic hip abnormalities related to FAI in young elite soccer players and compare this with findings in a group of adult elite soccer players.

**Subjects and methods:** Anteroposterior pelvic and cross-table hip radiographs were obtained for 75 young elite soccer players with skeletal immaturity (group 1) and for 75 adult elite soccer players (group 2), all of whom were previously asymptomatic and had no history of hip disease. After exclusion, group 1 included 72 patients, and group 2 included 70 patients. Radiological signs of FAI were evaluated.

**Results:** 34 subjects in groups 1 and 2 demonstrated cam morphology. The prevalence of pincer morphology was 30 in group 1 and 36 in group 2. However, these differences were not statistically significant.

**Conclusion:** We found no differences in the prevalence of FAI radiological signs between soccer players in their late adolescence and adult soccer players.

## INTRODUCTION

Femoroacetabular impingement (FAI) has been described as the main cause of hip pain, altered joint range and decreased exercise performance in athletes.<sup>1</sup> This condition is because of morphological alterations in the femoral head or acetabulum that leads to or predisposes labral and chondral injuries. Various conditions can lead to FAI presence, including congenital malformations, post-traumatic injuries, coxa profunda and acetabular retroversion and

## Key messages

- In light of our results, it seems that participation in high-performance soccer during skeletal immaturity would not be responsible for an increase in the prevalence of femoroacetabular impingement (FAI) hip deformities in the adult population.
- However, data from our study and previous articles have shown some conflicting results; therefore, we need a larger number of studies, ideally prospective and long term, to establish the natural history of hip deformities in high-performance athletes.
- We found a 47.2% prevalence of cam FAI radiological signs in asymptomatic skeletally immature athletes.
- We found a 41.6% prevalence of pincer FAI radiological signs in asymptomatic skeletally immature athletes.

protrusion.<sup>2</sup> These changes were initially described by Ganz *et al*,<sup>3</sup> who separated them into two main groups: cam impingement, in which there is an alteration in the sphericity of the femoral head, and pincer impingement, which is characterised by changes to the acetabulum.

The causes and time course of the development of deformities found in FAI are not entirely clear. Some reports<sup>4 5</sup> have revealed that participation in high-impact sports may play a role in the development of cam deformity; there is a higher prevalence of signs of cam impingement in asymptomatic adolescents who participate in soccer and basketball than in non-athlete controls.<sup>4 5</sup> Current evidence regarding the initiation and development of deformities is scarce. Agricola *et al*<sup>6</sup> observed a group of elite soccer players aged 12–19 years over a 2-year period who demonstrated that the prevalence of cam deformity progressively



CrossMark

<sup>1</sup>Department of Orthopedics, Clinica MEDS, Santiago, Chile

<sup>2</sup>Instituto Traumatologico, Santiago, Chile

### Correspondence to

Dr Tomas Amenabar; [tomasamenabar@gmail.com](mailto:tomasamenabar@gmail.com)

increased until physis closure, during which the prevalence tended to stabilise. Based on these observations, we hypothesised that the prevalence of radiological signs of FAI in young elite soccer players who are skeletally immature would be lower than in adult soccer players.

The aim of this study was to compare the prevalence of radiographic hip abnormalities related to FAI pathology in young elite soccer players with that in a group of adult elite soccer players.

### Subjects and methods

Research ethics board approval from our institution was obtained, and a prospective study was designed. One hundred and fifty elite footballers who belonged to a first-division club or the young national team were evaluated in two groups during the preseason period. Group 1 included 75 young players with incomplete skeletal maturity, and group 2 included 75 adult elite soccer players.

Inclusion criteria for group 1 were skeletal immaturity defined by an open femoral physis and less than stage 4 of Risser's iliac apophysis ossification.<sup>7</sup> The mean age in group 1 was 15.4 years (SD 0.8, range 12–16). Inclusion criteria for group 2 were adult elite soccer players. The average age in group 2 was 24 years (SD 3.3, range 19–36).

Exclusion criteria for both groups were incomplete data, presence of symptoms related to the hip or history of hip pain (ie, moderate-to-severe pain that prevented the athlete to play or train normally) despite being asymptomatic at the time of the study, history of hip pathology and bad-quality X-rays after two attempts.

Each subject signed a consent form and voluntarily participated in this study. Seven patients were excluded from group 1 due to skeletal maturity, bad-quality X-rays or incomplete data, and five patients were excluded from group 2. Finally, 72 footballers were included in group 1 and 70 in group 2.

Anteroposterior pelvic and cross-table hip radiographs were taken for each subject. A radiology technician was responsible for obtaining the images using the recommended protocols for each projection.<sup>8</sup> The quality of each image was analysed, and if it did not fulfil the requirements, it was repeated. A good radiograph was defined as the pelvis with the coccyx centred on the pubic symphysis, with both legs internally rotated 15°, and with bony landmarks (teardrop and lesser trochanter) clearly visible. A radiograph was considered unacceptable when the coccyx was >1 cm lateralised with respect to the centre of the pubic symphysis or >3 cm above or below the superior edge of the pubis, or the obturator foramina were asymmetric.<sup>8</sup> In cross-table hip radiographs, the anterior and posterior femoral head-neck junctions had to be clearly definable.<sup>8</sup> A radiologist, a specialist in

musculoskeletal radiology, analysed the films and evaluated signs of pincer or cam impingement (figure 1).

For pincer impingement, the lateral centre edge angle over was measured, and the presence of focal acetabular retroversion (in a figure-of-8 configuration, the 'cross-over' sign) was recorded.<sup>9</sup> The cross-over sign is defined as the anterior rim line being lateral to the posterior rim in the cranial part of the acetabulum and crossing the latter in the distal part of the acetabulum, showing as a figure-of-8 on the anteroposterior radiograph.<sup>9</sup> The lateral centre edge angle (Wiberg's angle) is calculated by measuring the angle between two lines: (1) a line through the centre of the femoral head, perpendicular to the transverse axis of the pelvis, and (2) a line through the centre of the femoral head, passing through the most superolateral point of the sclerotic weight-bearing zone of the acetabulum.<sup>8</sup>

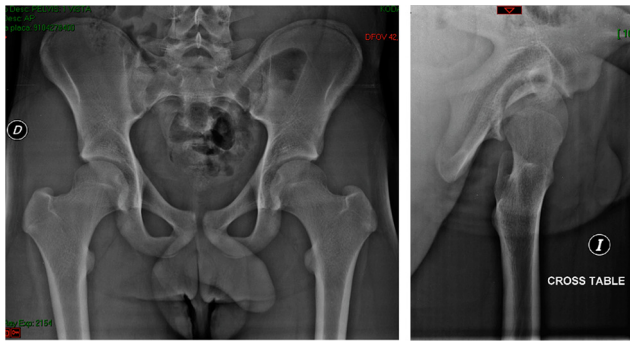
For cam impingement, the alpha angle and the anterior offset were measured.<sup>9</sup> For measurement, first, a line following the longitudinal axis of the femoral neck is drawn. The alpha angle is the angle between the femoral neck axis and a line connecting the head centre with the point at which the head-neck contour begins to become aspherical.<sup>8 9</sup> The anterior offset refers to the difference between the maximal anterior radius of the femoral head and the anterior radius of the adjacent femoral neck. To measure it, two lines parallel to the longitudinal axis are drawn. One must be tangential to the anterior border of the head, and the other must be tangential to the anterior border of the neck. The perpendicular distance between them corresponds to the anterior femoral offset.<sup>9 10</sup> The measures and evaluations of the images were performed using Kodak Carestream software, V.10.2 (Carestream Health, 2008, Rochester, New York, USA).

Positive radiographic signs of cam-type FAI were defined as the presence of an increased alpha angle (>55°) or decreased anterior femoral offset (<8 mm) in at least one of the examined hips. Positive radiographic signs of pincer-type FAI were defined as the presence of a cross-over sign or lateral centre edge angle >40° in at least one of the examined hips. Positive radiographic signs of FAI were defined as the presence of any of the above mentioned specific signs.

The  $\chi^2$  test was used for comparison between groups of the presence or absence of radiographic signs. The remaining data (alpha angle, anterior femoral offset and Wiberg's angle) were tested for normality using the D'Agostino-Pearson test and further analysed using Student's t-test. A significance level of  $p < 0.05$  was considered to be statistically significant. Statistical analyses were performed using SPSS 21 (SPSS).

### RESULTS

The overall prevalence of positive radiographic signs of FAI was 63.8% in group 1 and 75% for group 2, with no statistical difference ( $p = 0.12$ ).



**Figure 1** Anteroposterior pelvis and cross-table radiographs of a 14-year-old soccer player with skeletal immaturity and radiological signs of cam FAI. FAI, femoroacetabular impingement.

The results of cam impingement are shown in table 1. Thirty-four subjects (47.2%) in group 1 had positive signs of cam impingement, whereas 34 subjects (48.5%) in group 2 had positive signs. There was no statistically significant difference between the subjects with positive signs in groups 1 and 2. Furthermore, we did not find differences in the mean alpha angles or anterior femoral offset between groups.

The results for pincer impingement are shown in table 2. Thirty (41.6%) subjects were positive for pincer impingement radiological signs in group 1, whereas 36 (51.4%) subjects were positive in group 2, with no statistical difference ( $p=0.24$ ). In addition, the mean Wiberg's angle between groups showed no difference.

## DISCUSSION

These results suggest that our initial hypothesis may be rejected; that is, the prevalence of radiological signs of FAI in adult soccer players is not higher than in players with incomplete skeletal maturity. This hypothesis had been supported by observations in previous studies that demonstrated that the prevalence of deformities in the hip increases as the skeleton develops, with a tendency to stabilise once the physis closes, suggesting there would be a higher prevalence of deformities in adults (where all deformities have already developed) than in the immature skeleton

(where there is still time to develop morphological alterations).<sup>6</sup> Furthermore, this is supported by the observation made in the shoulder by Crockett *et al*,<sup>11</sup> which demonstrated gradually developing changes in the humeral version (retroversion) in children who played baseball, specifically pitchers, where the humeral physis is frequently exposed to twists and turns. The increasing number of young participants in elite sports, such as football, with workouts four to five times per week, involving twists and turns that lead to stress on the proximal femoral physis, could result in a similar phenomenon as that observed in the humerus. However, the results obtained in this study do not support this theory.

Moreover, Johnson *et al*<sup>12</sup> reported that participation in elite soccer during skeletal immaturity does not increase the risk of developing cam-type deformity in adulthood and suggests that participation in high-performance sports, at least in soccer, during skeletal immaturity would not be responsible for an increase in the prevalence of hip deformities in the adult population.

Considering that data from our study and previous articles have shown some conflicting results, a larger number of studies, ideally prospective and long term, to establish the natural history of hip deformities in high-performance athletes will be required.

With regard to the prevalence of radiological signs of FAI in soccer, Gerhardt *et al*<sup>13</sup> reported an incidence of 68% for cam impingement and 26.7% for pincer impingement on radiographs in 75 elite Major League Soccer (MLS) players (USA). These cam impingement values are higher compared with those found in the sample analysed in this study (47.2% and 48.5% in groups 1 and 2, respectively). This is probably because of the high number of MLS players who referred to a history of hip pain (41%). In this study, all players who were evaluated had no previous or current symptoms of the hip pain. The same explanation may apply to the difference observed in alpha angle between Gerhardt *et al*'s study (mean 66°) and this study (53° for the skeletally immature population and 56° for adults). Another study<sup>12</sup> reported a mean alpha angle of 56° for asymptomatic elite soccer players with

**Table 1** Comparison of cam deformity radiological signs, alpha angle and anterior offset between group 1 (incomplete skeletal maturity) and group 2 (skeletal maturity)

	Group 1	Group 2	p Value
Cam impingement positive signs, n (%)	34 (47.2%)	34 (48.5%)	0.87
Right alpha angle (°), mean (SD, range)	47.8 (SD 5.9, 37–62)	48 (SD 5.9, 37–62)	0.86
Left alpha angle (°), mean (SD; range)	47.3 (SD 6.1, 35–62)	47.7 (SD 6.1, 36–62)	0.75
Right anterior offset (mm), mean (SD, range)	8.4 (SD 1.6, 3.8–12.7)	8.3 (SD 1.4, 3.7–11.1)	0.59
Left anterior offset (mm), mean (SD, range)	8.7 (SD 1.9, 4.2–14.1)	8.6 (SD 1.7, 4.2–13.9)	0.66

**Table 2** Comparison of pincer radiological signs and lateral centre edge angle between group 1 (incomplete skeletal maturity) and group 2 (skeletal maturity)

	Group 1	Group 2	p Value
Pincer impingement positive signs, n (%)	30 (41.6%)	36 (51.4%)	0.24
Right lateral centre edge angle (°), mean (SD, range)	36.4 (SD 6, 25–52)	36.6 (SD 5.9, 25–51)	0.85
Left lateral centre edge angle (°), mean (SD, range)	35.8 (SD 6.8, 25–54)	36 (SD 6.9, 25–54)	0.84

incomplete skeletal maturity, which is reasonably close to the value observed in this study sample.

In relation to the prevalence of pincer impingement's positive signs reported by Gerhardt *et al*, we think that the difference between their reported value (26.7%) and this series (41.6% and 51.4% in groups 1 and 2, respectively) may be, in part, due to the lack of definition of what to consider a cross-over sign, thus allowing more variability among the observers.

There are some limitations to this study. First, no power calculation was done. Second, there was no non-soccer youth or adult control group. The comparisons were made only for elite soccer players; therefore, the results cannot be extrapolated to the general population, particularly when differences have been shown in the prevalence of radiographic hip abnormalities in athletes and non-athletes.<sup>4 5</sup> In addition, the mean age of our skeletally immature group was 15.4 years, and in spite of having skeletal immaturity as observed in the X-rays, we can not rule out that the cam deformity had developed earlier during the sports practice. In addition, some symptomatic patients were excluded, which can lead to some selection bias. Moreover, we did not have the exact data on hours participated in soccer for each group and during the years of growth, although as they played in lower divisions of professional clubs, the average activity was roughly 12 hours per week. Finally, all the measurements were done once by one musculoskeletal radiologist; therefore, no interobserver or intraobserver reliability was addressed.

## CONCLUSION

The prevalence of deformities related to FAI in elite soccer players is similar in soccer players with incomplete skeletal maturity and adults.

**Competing interests** None declared.

**Patient consent** Obtained from patients (group 2) or their parents (group 1) before X-rays and physical examination.

**Ethics approval** Obtained from Clinica MEDS.

**Provenance and peer review** Not commissioned; externally peer reviewed.

**Open Access** This is an Open Access article distributed in accordance with the Creative Commons Attribution Non Commercial (CC BY-NC 4.0) license, which permits others to distribute, remix, adapt, build upon this work non-commercially, and license their derivative works on different terms, provided the original work is properly cited and the use is non-commercial. See: <http://creativecommons.org/licenses/by-nc/4.0/>

© Article author(s) (or their employer(s) unless otherwise stated in the text of the article) 2017. All rights reserved. No commercial use is permitted unless otherwise expressly granted.

## REFERENCES

- Mölsä J, Airaksinen O, Näsman O, *et al*. Ice hockey injuries in Finland. A prospective epidemiologic study. *Am J Sports Med* 1997;25:495–9.
- Parvizi J, Leunig M, Ganz R. Femoroacetabular impingement. *J Am Acad Orthop Surg* 2007;15:561–70.
- Ganz R, Parvizi J, Beck M, *et al*. Femoroacetabular impingement: a cause for osteoarthritis of the hip. *Clin Orthop Relat Res* 2003;417:112–20.
- Agricola R, Bessems JH, Ginai AZ, *et al*. The development of Cam-type deformity in adolescent and young male soccer players. *Am J Sports Med* 2012;40:1099–106.
- Siebenrock KA, Ferner F, Noble PC, *et al*. The cam-type deformity of the proximal femur arises in childhood in response to vigorous sporting activity. *Clin Orthop Relat Res* 2011;469:3229–40.
- Agricola R, Heijboer MP, Ginai AZ, *et al*. A cam deformity is gradually acquired during skeletal maturation in adolescent and young male soccer players: a prospective study with minimum 2-year follow-up. *Am J Sports Med* 2014;42:798–806.
- Hacquebord JH, Leopold SS. In brief: The Risser classification: a classic tool for the clinician treating adolescent idiopathic scoliosis. *Clin Orthop Relat Res* 2012;470:2335–8.
- Clohisy JC, Carlisle JC, Beaulé PE, *et al*. A systematic approach to the plain radiographic evaluation of the young adult hip. *J Bone Joint Surg Am* 2008;90(Suppl 4):47–66.
- Tannast M, Siebenrock KA, Anderson SE. Femoroacetabular impingement: radiographic diagnosis—what the radiologist should know. *AJR Am J Roentgenol* 2007;188:1540–52.
- Beall DP, Sweet CF, Martin HD, *et al*. Imaging findings of femoroacetabular impingement syndrome. *Skeletal Radiol* 2005;34:691–701.
- Crockett HC, Gross LB, Wilk KE, *et al*. Osseous adaptation and range of motion at the glenohumeral joint in professional baseball pitchers. *Am J Sports Med* 2002;30:20–6.
- Johnson AC, Shaman MA, Ryan TG. Femoroacetabular impingement in former high-level youth soccer players. *Am J Sports Med* 2012;40:1342–6.
- Gerhardt MB, Romero AA, Silvers HJ, *et al*. The prevalence of radiographic hip abnormalities in elite soccer players. *Am J Sports Med* 2012;40:584–8.