

GUIDELINES AND RECOMMENDATIONS

Diagnosis and assessment of dilated cardiomyopathy: a guideline protocol from the British Society of Echocardiography

Thomas Mathew^{1,a}, Lynne Williams^{2,b}, Govardhan Navaratnam^{3,b}, Bushra Rana^{4,c}, Richard Wheeler^{5,d}, Katherine Collins⁶, Allan Harkness⁷, Richard Jones⁶, Dan Knight⁸, Kevin O’Gallagher⁹, David Oxborough¹⁰, Liam Ring¹¹, Julie Sandoval¹², Martin Stout¹³, Vishal Sharma¹⁴ and Richard P Steeds¹⁵, on behalf of the British Society of Echocardiography Education Committee

¹Cardiology, Nottingham University Hospital, Nottingham, UK

²Cardiology, Papworth Hospital, Cambridge, UK

³University Health Board, Cwm Taf Health Board, Abercynon, UK

⁴Cardiac Services Directorate, Papworth Hospital, Cambridge, UK

⁵Cardiothoracic, University Hospital of Wales, Cardiff, UK

⁶Cardiology, Portsmouth Hospitals NHS Trust, Queen Alexandra Hospital, Portsmouth, UK

⁷Cardiology Department, Colchester Hospital NHS Trust, Colchester, UK

⁸Centre for Cardiovascular Imaging, University College London, London, UK

⁹Cardiology, Kings College Hospital NHS Foundation Trust, London, UK

¹⁰Research Institute for Sports and Exercise Physiology, Liverpool John Moores University, Liverpool, UK

¹¹Cardiology Department, West Suffolk Hospital NHS Trust, Bury St Edmunds, UK

¹²Cardiac Ultrasound, Leeds Teaching Hospitals NHS Trust, Leeds, UK

¹³Cardiology Department, University Hospital South Manchester, Manchester, UK

¹⁴Cardiology, Royal Liverpool University Hospital, Liverpool, UK

¹⁵Cardiology, University Hospital Birmingham and University of Birmingham, Birmingham, UK

^a(T Mathew is the Lead Author)

^b(L Williams and G Navaratnam contributed equally)

^c(B Rana is the Education Committee Chair)

^d(R Wheeler is the Lead for Protocols)

Correspondence should be addressed to V Sharma

Email
vishalsharma76@gmail.com

Abstract

Heart failure (HF) is a debilitating and life-threatening condition, with 5-year survival rate lower than breast or prostate cancer. It is the leading cause of hospital admission in over 65s, and these admissions are projected to rise by more than 50% over the next 25 years. Transthoracic echocardiography (TTE) is the first-line step in diagnosis in acute and chronic HF and provides immediate information on chamber volumes, ventricular systolic and diastolic function, wall thickness, valve function and the presence of pericardial effusion, while contributing to information on aetiology. Dilated cardiomyopathy (DCM) is the third most common cause of HF and is the most common cardiomyopathy. It is defined by the presence of left ventricular dilatation and left ventricular systolic dysfunction in the absence of abnormal loading conditions (hypertension and valve disease) or coronary artery disease sufficient to cause global systolic impairment. This document provides a practical approach to diagnosis and assessment of dilated cardiomyopathy that is aimed at the practising sonographer.

Key Words

- ▶ dilated cardiomyopathy
- ▶ echocardiography
- ▶ left ventricular dysfunction

1. Introduction

1.1. The BSE Education Committee has previously published a minimum dataset for a standard adult transthoracic echocardiogram (TTE). These are published online in *Echo Research and Practice* (1). This document specifically states that the minimum dataset is usually only sufficient when the echocardiographic study is entirely normal. The aim of the Education Committee is to publish a series of appendices to cover specific pathologies to support this minimum dataset. This final document completes the cardiomyopathy series (hypertrophic (2), restrictive (3), ARVC (4) and dilated cardiomyopathies).

1.2. The intended benefits of such supplementary recommendations are to:

- Support cardiologists and echocardiographers to develop local protocols and quality control programmes for adult transthoracic study.
- Promote quality by defining a set of descriptive terms and measurements, in conjunction with a systematic approach to perform and report a study in specific disease states.
- Facilitate the accurate comparison of serial echocardiograms performed in patients at the same or different sites.

1.3. The views and measurements are focussed upon dilated cardiomyopathy and are supplementary to those outlined in the TTE minimum dataset. This document gives recommendations for the image and analysis dataset required in patients either being assessed for or with a known diagnosis of dilated cardiomyopathy.

1.4. When the condition or acoustic windows of the patient prevent the acquisition of one or more components of the supplementary dataset or when measurements result in misleading information (e.g. off-axis measurements) this should be stated.

1.5. This document is a guideline for echocardiography in dilated cardiomyopathy and will be updated in accordance with changes directed by publications or changes in practice.

2. Dilated cardiomyopathy

2.1. Dilated cardiomyopathy (DCM) is a progressive disease of the heart muscle. It is characterised by chamber enlargement and contractile dysfunction of the left ventricle in the absence of chronic pressure and/or volume overload. Although not essential for diagnosis, the right ventricle may similarly be affected. Dilated cardiomyopathy is the third most common cause of heart failure and is the commonest type of cardiomyopathy (5). The phenotype of ventricular dilatation and abnormal contractile dysfunction can be the result of a range of pathological conditions such as infection, toxins or autoimmune disease. However, in 50% of cases, the aetiology remains unknown and is termed 'idiopathic DCM'. It is recognised that between 20% and 35% of idiopathic cases may have a family history suggesting an inherited gene defect (6).

2.2. Echocardiography is the first-line imaging test in the assessment of patients with DCM. It provides pivotal information not only for diagnosis, risk stratification and guiding treatment, but also plays a key role in screening family members. This document provides recommendations for the acquisition of images and collection of a dataset to be analysed during echocardiography in the assessment of patients with suspected or known DCM.

2.3. In this document, the parameters used for diagnosis and risk stratification are set out systematically (Table 1). Appendix 1 provides additional information on some of these parameters, Appendix 2 describes the echocardiographic features that help to differentiate the commonly encountered conditions presenting as DCM and finally a list of useful references for further reading.

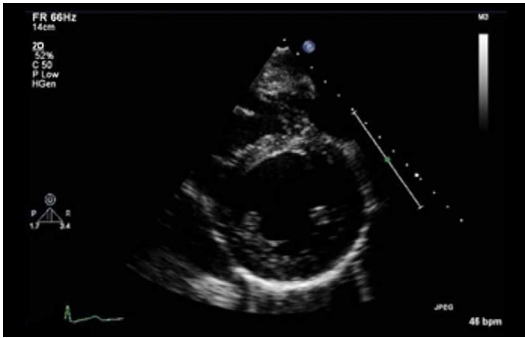
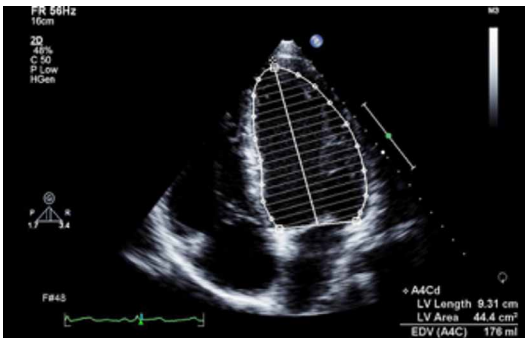
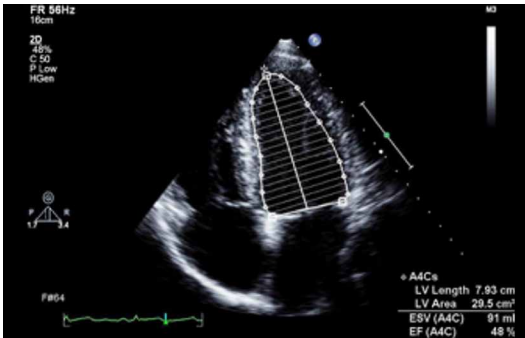
2.4. The diagnostic criteria for DCM require exclusion of chronic pressure overload (such as hypertension and left ventricular outflow obstruction), chronic volume overload states (intra-cardiac shunts and valvular regurgitation) and ischaemic heart disease.

Table 1 Parameters used for diagnosis and risk stratification.

View	Measurements	Explanatory note	Image
PLAX 2D/M-mode	LVIDd/s, IVSd, LVPWd	<p>LV cavity size, wall thickness and radial function. Measurements are taken just distal to the mitral valve tip</p> <p>If images are off axis, use 2D</p> <p>All measurements should be indexed to BSA (refer to chamber quantification guidelines for normal values) (7)</p>	
	Fractional shortening (FS)	<p>LVIDd >112% (2 s.d.) corrected for age and BSA is a diagnostic criterion for idiopathic DCM (refer to Appendix 1a)</p> <p><i>Value above 117% (2 s.d. plus 5%) increases the specificity and may be useful as a screening tool</i></p> <p>FS <25% is a criterion for the diagnosis of idiopathic DCM in the presence of a dilated ventricle</p>	
PLAX M-mode	MV E-Septal separation (EPSS)	<p>EPSS is defined as the minimal distance between E point (most anterior motion of the AML during diastole) and a line tangential to the most posterior excursion of the IVS within the same cardiac cycle</p> <p>Normal range 0–5.3 mm. Value above 7 mm is indicative of reduced systolic function but a normal value does not exclude LV dysfunction (8, 9)</p>	<p>EPSS in a normal ventricle</p> <p>EPSS in a patient with DCM</p>
		<p>Assess mechanism and severity of mitral regurgitation</p> <p>See Appendix 1a and MR dataset (10)</p>	
PLAX CFM	Mitral regurgitation		


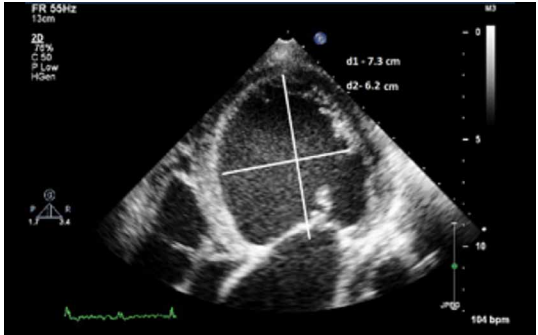
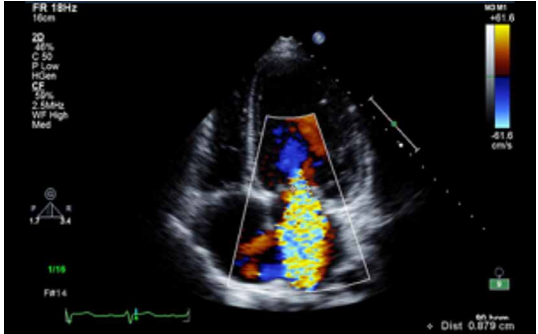
(Continued)

Table 1 Continued.

View	Measurements	Explanatory note	Image
PSAX base to apex 2D	Qualitative assessment of ventricular (LV and RV) structure and function with special reference to radial systolic function and to exclude regional wall motion abnormalities	Refer to Appendix 2	
A4C 2D	Qualitative assessment of ventricular (LV and RV) structure and function with special reference to radial and longitudinal function and regional wall motion abnormalities	Refer to Appendix 2	
LV volumes	Diastolic and systolic volumes indexed to BSA (see BSE chamber quantification guide (7)). 3DE is recommended as the optimal method if endocardial definition is adequate Consider use of echo contrast if poor endocardial definition		
Ejection fraction (EF)	Estimated using Bi-plane Simpsons. 3DE is the preferred modality for measurement of LVEF EF of less than 45% is a diagnostic criterion for idiopathic DCM in the presence of a dilated ventricle (see Appendix 1a)		

(Continued)

Table 1 Continued.

View	Measurements	Explanatory note	Image
	Sphericity index (SI)	Ratio between the length (mitral annulus to apex in the apical view) and width (mid-cavity level in the A4C view)	
		<p>With gradual dilatation, left ventricle becomes more spherical in DCM and the value approaches near 1 (normal >1.5)</p> <p>SI is a predictor of functional (exercise) capacity in patients with LV dysfunction and is an adverse prognostic marker (11)</p>	<p>SI of 1.8 (d1/d2) in a non dilated LV with normal EF</p> 
A4C CFM	Mitral regurgitation	Assess mechanism and severity of MR Refer to Appendix 1a and MR dataset (10)	<p>SI of 1.2 in a patient with DCM</p> 
A4C PW	LV inflow Doppler	E and A fusion is common in patients with DCM and indicates AV dyssynchrony in the absence of sinus tachycardia	

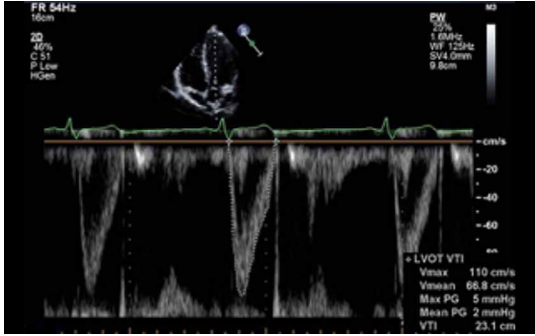
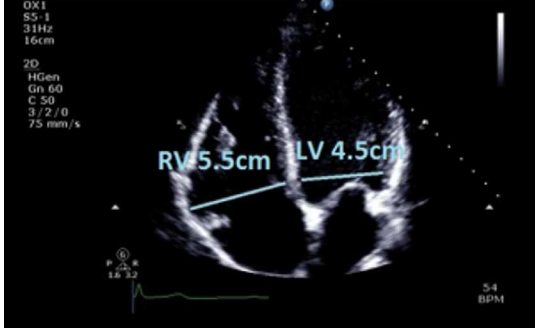
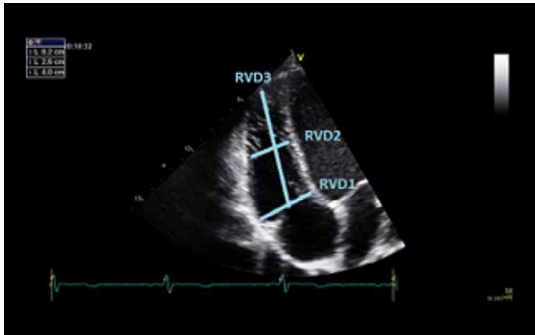
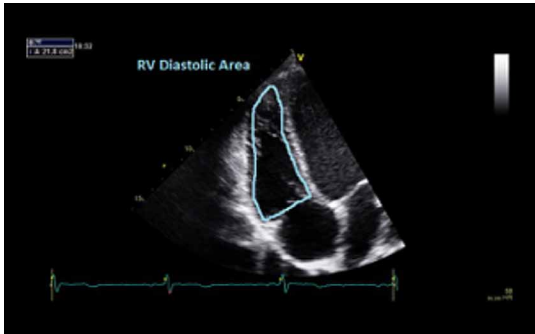
(Continued)

Table 1 Continued.

View	Measurements	Explanatory note	Image
	Diastolic dysfunction	In patients with EF less than 45%, diastolic dysfunction coexists. In this group, grading of diastolic dysfunction can be performed using mitral inflow pattern alone and provides additional prognostic information See <i>BSE diastolic function guidelines for further information (12)</i>	<p>Grade I</p> <p>Grade II</p> <p>Grade III</p>
A4C tdi	S and e' Calculate E/e' ratio	Both are decreased in DCM <i>Refer to diastolic function guidelines for age adjusted values (9)</i> e': an average from 2 sites (septal and lateral) is used for calculation of this ratio Value above 13 suggests raised LA pressure (12)	

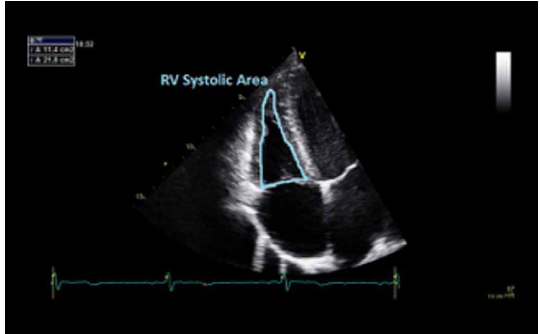
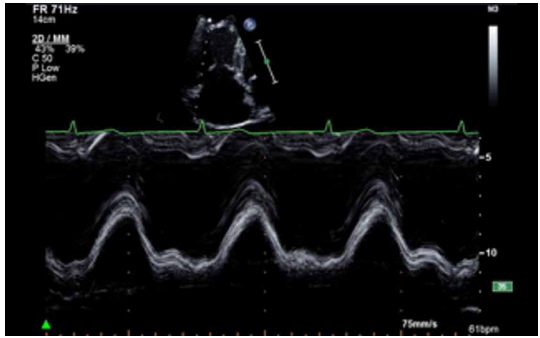

(Continued)

Table 1 Continued.

View	Measurements	Explanatory note	Image
A5C PW	Velocity time integral of LV outflow tract	<18 cm is an adverse prognostic marker (13) Indicative of a low flow state	
Focussed RV view 2D	Basal LV:RV ratio	Qualitative assessment of RV size A ratio of >0.66 suggests RV dilatation	
	RVD1 RVD2 RVD3	RVD1 >41 mm; RVD2 >35 mm; RVD3 >83 mm indicates RV dilatation Refer to BSE ARVC dataset for further information on RV measurements and assessment (4)	
	Fractional area change (FAC)	FAC of <35% indicates RV dysfunction RV dysfunction is not essential for the diagnosis of DCM but when present is an adverse prognostic marker (14)	

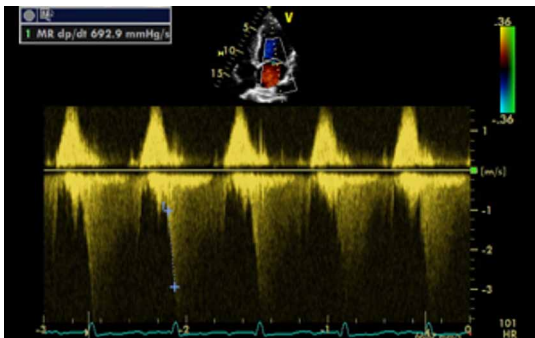
(Continued)

Table 1 Continued.

View	Measurements	Explanatory note	Image
			
Focussed RV view M-mode	TAPSE	TAPSE of <17 mm indicates RV systolic dysfunction	
Focussed RV view tdi	Tricuspid annulus S velocity	S velocity <9.5 cm/s indicates RV systolic dysfunction	
Useful additional measurements			
TR CW/CFM	Severity of TR and TR Vmax should be assessed in all views	See Appendix 1b <i>Raised PA pressure is an adverse prognostic marker (15)</i>	
LA 2D/M-mode	LA dimension and volume	Measured at end systole and BSA indexed. <i>LA dilatation suggests increased pressure and is an adverse prognostic marker (16) (please refer to BSE chamber quantification guidelines for reference values) (7)</i>	

(Continued)

Table 1 Continued.

View	Measurements	Explanatory note	Image
dp/dt CW	Measured from MR jet indicates change in LV pressure over time during systole	<p>Record MR spectral profile at a high sweep speed (typically 100 mm/s). The time interval between the points at which the velocity is 1 m/s and 3 m/s is measured. According to the Bernoulli equation, the pressure increase in the left ventricle between these points is 32 mmHg ($\Delta P = 4 \times V2^2 - 4 \times V1^2 = 4 \times 3^2 - 4 \times 1^2$). Thus, dp/dt (in mmHg/s) is calculated from the following formula:</p> <p>LV dp/dt max = 32 mmHg/time (s)</p> <p>dp/dt is a measure of global LV contractility</p> <p>Normal value: 1000–1200 mmHg/s</p> <p>dp/dt <600 mmHg/s is an adverse prognostic marker (17)</p> <p>See Appendix 1d</p>	
Dysynchrony indices M-mode	Septal to posterior wall delay	<p>Septal to posterior wall delay of more than 130 ms suggest intraventricular dysynchrony</p> <p>Value of more than 30 ms between right and left ventricular pre ejection time suggests inter ventricular dysynchrony</p>	
Dysynchrony indices PW	Difference between RV and LV ejection time	Average delay of more than 65 ms from onset of QRS to peak S wave from 4 basal segments suggests intra ventricular dysynchrony	
Dysynchrony indices TDI	Time from QRS onset to peak S wave from basal segments	Reduced aortic valve opening may be indicative of reduced stroke volume. However, if calcified may be due to primary AoV disease	
Aortic valve M-mode	Pattern of aortic valve opening	Spontaneous contrast is commonly seen in dilated, poorly functioning chambers and should prompt assessment for intra cardiac thrombus	
Thrombus 2D			

Abbreviations

Views	
A2C	Apical two chamber
A4C	Apical four chamber
A5C	Apical five chamber
A3C	Apical long axis or apical three chamber
PLAX	Parasternal long axis
PSAX	Parasternal short axis SC subcostal
SSN	Suprasternal
Modality	
CFM	Colour flow Doppler
CW	Continuous wave Doppler PW Pulse wave Doppler
TDI	Tissue Doppler imaging
Explanatory test	
2D	2-Dimensional echocardiography
3DE	3-Dimensional echocardiography
AML	Anterior mitral valve leaflet
ARVC	Arrhythmogenic right ventricular cardiomyopathy
AoV	Aortic valve
AV	Atrio-ventricular
BSA	Body surface area
BSE	British Society of Echocardiography
CRT	Cardiac resynchronisation therapy
DCM	dilated cardiomyopathy
dp/dt	LV pressure rise in systole divided by time (rate of pressure rise)
e'	Early myocardial diastolic velocity on tissue Doppler imaging
E/e'	Ratio of MV E Vmax/ tissue Doppler early myocardial relaxation velocity
EF	Ejection fraction
EPSS	E point septal separation
FAC	Fractional area change
FS	Fractional shortening
ICM	Ischaemic cardiomyopathy
IVS	Interventricular septum
IVSd	Interventricular septal thickness diastole
LA	Left atrium
LV	Left ventricle
LVIDd	Left ventricular internal dimension in diastole
LVIDs	Left ventricular internal dimension in systole
LVNC	Left ventricular non-compaction
LVPWd	Left ventricular posterior (inferolateral) wall thickness in diastole
MR	Mitral regurgitation
RV	Right ventricle
RVD1	Right ventricular internal dimension
SI	Sphericity index
S'	Peak myocardial systolic velocity on tissue Doppler imaging
TAPSE	Tricuspid annular plane systolic excursion
TR	Tricuspid regurgitation
PA	Pulmonary artery
RV	Right ventricle
RVD	Right ventricular dimension
RVSP	Right ventricular systolic pressure
TOE	Trans-oesophageal echocardiography

Appendix 1: Important additional considerations

- a. Diagnostic criteria: Diagnostic criteria of LV dilatation (>112% corrected to BSA and age) with reduced function (FS <25% and/or LVEF <45%) applies to 'idiopathic' DCM once secondary causes (hypertension, coronary artery disease, excess alcohol consumption, tachycardia-induced cardiomyopathy, systemic or pericardial disease, cor pulmonale and congenital heart disease) have been excluded (18, 19, 20). The value of 117% is equivalent to 2 s.d. from the upper normal limit corrected to age and BSA plus 5%. For the purposes of this guideline, it is recommended that a value above 2 s.d.s for age, sex and BSA should be used in diagnosis, using linear and volumetric methods, whether 2D or 3D.
- b. Mitral regurgitation: MR is common in patients with DCM and is due to disease of the ventricle rather than a primary lesion of the mitral valve leaflets. Functional MR results from tethering of the leaflets secondary to a change in LV geometry leading to a tenting pattern. Identification of the mechanism of MR is important because chronic MR due to primary mitral valve disease can also present with findings similar to DCM. Echocardiographic features that suggest functional MR include the following (in the absence of any obvious morphological abnormality of the leaflets):
 1. symmetric tenting of leaflets (asymmetric is more commonly seen in ischaemic CMP)
 2. reduced leaflet coaptation zone*
 3. central jet of MR
 4. increased coaptation depth*
 5. increased tenting area*
 6. dilated mitral valve annulus

*see European Association of Cardiovascular Imaging Valve Regurgitation Guidelines (21).

Transthoracic echocardiography usually differentiates primary from functional MR, but in a small proportion of patients, trans-oesophageal echocardiography may be required for further clarification.
- c. Tricuspid regurgitation (TR): Functional TR in DCM is a marker of RV dilatation, RV dysfunction or pulmonary hypertension. Pulmonary artery pressure measured from TR velocity provides additional prognostic information in patients with DCM and should be assessed in all cases. Peak TR velocity of more than 2.5 m/s is associated with increased mortality, increased hospitalisation and higher incidence of heart failure (15).
- d. Role of dyssynchrony indices: Mechanical dyssynchrony is common in patients with DCM and detection of

dysynchrony is important to identify patients who may benefit from cardiac resynchronisation therapy (CRT). Several echocardiographic parameters have been used to assess mechanical dysynchrony in small subsets of patients; however, the wider role of echocardiography in selecting patients for CRT is still debated. Currently, the role of echo is limited to patients with borderline QRS duration (120–149 ms) in which the presence of inter or intraventricular dysynchrony may provide additional information (22). Assessment of dysynchrony is therefore not part of the routine dataset for patients with DCM and should be used as an option in selected cases only.

- e. Stress echo and contractile reserve: Assessment of contractile reserve by low-dose dobutamine stress echocardiography may refine prognosis in patients with DCM and may be used when cardiopulmonary exercise stress testing is not available or in patients who are unable to exercise. An increase in LV EF from rest to peak stress by $\geq 5\%$ or a percentage change from baseline of $\geq 20\%$ indicates the presence of contractile reserve. Its absence is an adverse prognostic marker (23).
- f. Role of echo in family screening: Asymptomatic first-degree relatives of patients with idiopathic DCM should have an echocardiogram every 3–5 years or anytime signs or symptoms occur (24).

Appendix 2: Other related cardiomyopathic conditions

- a. Ischaemic cardiomyopathy (ICM): Ischaemic cardiomyopathy can be differentiated from dilated cardiomyopathy by echocardiography in the vast majority of cases. LV dilatation in ICM usually occurs due to adverse remodelling after transmural myocardial infarction. During echocardiography, this is manifested by thinned, akinetic myocardial segments in the infarcted territory with cavity dilatation and mild compensatory hypertrophy of the non-infarcted segments. Infrequently, ICM can present as global hypokinesis mimicking DCM. When this occurs, it is usually in the presence of severe three-vessel coronary artery disease. In these situations, further assessment with stress echocardiography, stress cardiac MRI, coronary angiography or CT coronary angiography can be considered to exclude an ischaemic cause.
- b. Left ventricular non-compaction cardiomyopathy (LVNC): LVNC is an unclassified cardiomyopathy and advanced cases can present with findings similar to DCM (i.e., a dilated and impaired left ventricle).

Similarly, patients with DCM may have some echocardiographic features of LVNC which, if not recognised, can lead to over diagnosis. Echocardiographic criteria for the diagnosis of non-compaction include (25):

1. A two-layer structure with a compacted epicardial and non-compacted endocardial layer with maximal end systolic ratio of non-compacted to compacted layers of >2 .
 2. Predominant localisation of pathology to the apex, mid-lateral and mid-inferior segments.
 3. Colour Doppler evidence of blood flow amid the myocardial wall deep recesses and LV cavity.
 4. Absence of any other coexisting cardiac abnormalities (e.g. primary valve disease).
- c. Peri-partum cardiomyopathy (PPCM): PPCM is an idiopathic cardiomyopathy that presents with heart failure secondary to left ventricular systolic dysfunction; usually seen towards the end of pregnancy or in the first 5 months after delivery; in the absence of any other cause of heart failure. A reduction in LV EF (usually $<45\%$) is required to establish the diagnosis but the left ventricle may or may not be dilated. Other features are similar to DCM.
 - d. Toxic causes: A number of substances can be directly toxic to cardiac myocytes and result in depressed cardiac function and a phenotype of DCM. Most common agents include alcohol and chemotherapeutic drugs used for the treatment of cancers. Alcoholic cardiomyopathy most typically affects men between the ages of 35 and 50 years although women can also be affected. There is usually a long and significant history of heavy alcohol use. In addition to standard heart failure treatment, it is essential that affected patients abstain completely from alcohol. If identified at an early stage, cardiac function can improve with abstinence from alcohol but if severe LV dysfunction has developed, the damage may be irreversible. Chemotherapeutic drugs such as trastuzumab (Herceptin), anthracyclines and cyclophosphamide are most commonly implicated in causing impaired LV function. Regular monitoring for cardiotoxicity with serial echocardiography is usually recommended, and the chemotherapeutic agent may need to be stopped or changed if signs of cardiotoxicity develop. In addition conditions that result in excess iron deposition within the heart can lead to a phenotype of DCM. These include conditions such as hemochromatosis (genetic condition that results in excessive iron absorption) or conditions in which repeated blood transfusions

are required (secondary iron overload). Treatment of this includes iron chelation agents, and in some cases, repeated venesection. Recreational drug use, particularly with cocaine can also result in DCM.

- e. Viral/infective causes: Viral infection can result in acute and chronic myocarditis with myocyte death. In the acute phase, this can be occasionally very severe with the development of severe LV dysfunction, occasionally necessitating mechanical circulatory support or cardiac transplantation. It has also been suggested that viral persistence is implicated in the development of idiopathic DCM (26). Infection with human immunodeficiency virus (HIV) can result in a number of cardiac manifestations including the development of DCM. If DCM develops in the context of HIV, it carries a particularly unfavourable prognosis.
- f. Systemic disease: A number of other systemic diseases can be associated with DCM. These include generalised muscles disease such as muscular dystrophy, connective tissue diseases and vasculitis. Again, the presence of cardiac involvement in these conditions is an adverse prognostic marker.

Declaration of interest

The authors declare that there is no conflict of interest that could be perceived as prejudicing the impartiality of this guideline.

Funding

This work did not receive any specific grant from any funding agency in the public, commercial, or not-for-profit sector.

References

- 1 Wharton G, Steeds R, Allen J, Phillips H, Jones R, Kanagala P, Lloyd G, Masani N, Mathew T, Oxborough D, et al. 2015 A minimum dataset for a standard adult transthoracic echocardiogram: a guideline protocol from the British Society of Echocardiography. *Echo Research and Practice* **2** G9–G24. (doi:10.1530/ERP-14-0079)
- 2 Smith N, Steeds RP, Masani N, Sandoval J, Sharton G, Allen J, Chambers R, Jones G, Lloyd B, Rana K, et al. 2015 A systematic approach to echocardiography in hypertrophic cardiomyopathy: a guideline protocol from the British Society of Echocardiography. *Echo Research and Practice* **2** G1–G7. (doi:10.1530/ERP-14-0115)
- 3 Knight D, Patel K, Whelan C, Steeds RP, Harkness A, Jones R, Kanagala P, Lloyd G, Mathew T, O’Gallagher K, et al. 2013 A guideline protocol for the assessment of restrictive cardiomyopathy. London, UK: British Society of Echocardiography. (available at: <http://www.bsecho.org/assessment-of-restrictive-cardiomyopathy/>)
- 4 Oxborough D, Zaidi A, Sharma S, Somauroo J, Steeds RP, Bradlow W, Carr A, Jones R, Kanagala P, Knight D, et al. 2013 The Echocardiographic Assessment of the Right Ventricle with particular reference to Arrhythmogenic Right Ventricular Cardiomyopathy – A Protocol of the British Society of Echocardiography. London, UK:

British Society of Echocardiography. (available at: <http://www.bsecho.org/arrhythmogenic-right-ventricular-cardiomyopathy/>)

- 5 Towbin JA, Lowe AM, Colan SD, Sleeper LA, Orav J, Clunie S, Messere J, Cox GF, Paul R, Lurie PR, et al. 2006 Incidence, causes, and outcomes of dilated cardiomyopathy in children. *JAMA* **296** 1867–1876. (doi:10.1001/jama.296.15.1867)
- 6 Hershberger RE, Morales A & Siegfried JD 2010 Clinical and genetic issues in dilated cardiomyopathy: a review for genetics professionals. *Genetics in Medicine* **12** 655–667. (doi:10.1097/GIM.0b013e3181f2481f)
- 7 Masani N, Wharton G, Allen J, Chambers J, Graham J, Jones R, Rana B, Steeds R & the British Society of Echocardiography Education Committee 2011 Echocardiography: Guidelines for Chamber Quantification. London, UK: British Society of Echocardiography (available at: https://www.bsecho.org/media/40506/chamber-final-2011_2_.pdf)
- 8 Lew W, Henning H, Schelbert H & Karliner JS 1978 Assessment of mitral valve E point-septal separation as an index of left ventricular performance in patients with acute and previous myocardial infarction. *American Journal of Cardiology* **41** 836–845. (doi:10.1016/0002-9149(78)90722-1)
- 9 McKaigney CJ, Krantz MJ, La Rocque CL, Hurst ND, Buchanan MS & Kendall JL 2014 E-point septal separation: a bedside tool for emergency physician assessment of left ventricular ejection fraction. *American Journal of Emergency Medicine* **32** 493–497. (doi:10.1016/j.ajem.2014.01.045)
- 10 Steeds RP, Rana B, Allen J, Chambers J, Jones R, Lloyd G, Smith N, Sandoval J & Wharton G 2011 A Guideline Protocol for the Assessment of the Mitral Valve With a View to Repair. London, UK: British Society of Echocardiography (available at: <http://www.bsecho.org/mitral-valve-repair>)
- 11 Tischler MD, Niggel J, Borowski DT & LeWinter MM 1993 Relation between left ventricular shape and exercise capacity in patients with left ventricular dysfunction. *Journal of the American College of Cardiology* **22** 751–757. (doi:10.1016/0735-1097(93)90187-6)
- 12 Mathew T, Steeds RP, Jones R, Kanagala P, Lloyd G, Knight D, O’Gallagher K, Oxborough D, Rana B, Ring L, et al. 2013 A Guideline Protocol for the Echocardiographic assessment of Diastolic Dysfunction. London, UK: British Society of Echocardiography. (available at: <http://www.bsecho.org/diastolic-dysfunction/>)
- 13 Ristow B, Na B, Ali S, Whooley MA & Schiller NB 2011 Left ventricular outflow tract and pulmonary artery stroke distances independently predict heart failure hospitalization and mortality: the Heart and Soul Study. *Journal of American Society of Echocardiography* **24** 565–572. (doi:10.1016/j.echo.2010.12.024)
- 14 de Groote P, Millaire A, Foucher-Hossein C, Nogue O, Marchandise X, Ducloux G & Lablanche JM 1998 Right ventricular ejection fraction is an independent predictor of survival in patients with moderate heart failure. *Journal of American College of Cardiology* **32** 948. (doi:10.1016/S0735-1097(98)00337-4)
- 15 Hung J, Koelling T, Semigran MJ, Dec GW, Levine RA & Di Salvo TG 1998 Usefulness of echocardiographic determined tricuspid regurgitation in predicting event-free survival in severe heart failure secondary to idiopathic-dilated cardiomyopathy or to ischemic cardiomyopathy. *American Journal of Cardiology* **82** 1301–1303, A10. (doi:10.1016/S0002-9149(98)00624-9)
- 16 Ferreira F, Galrinho A, Soares R, Branco L, Abreu J, Feliciano J, Papoila AL, Virella D, Leal A & Cruz Ferreira R 2013 Prognostic value of left atrial volume in patients with dilated cardiomyopathy. *Revista Portuguesa de Cardiologia* **32** 865–872. (doi:10.1016/j.repce.2013.10.028)
- 17 Kolia TJ, Aaronson KD & Armstrong WF 2000 Doppler-derived dp/dt and -dp/dt predict survival in congestive heart failure. *Journal of the American College of Cardiology* **36** 1594. (doi:10.1016/S0735-1097(00)00908-6)
- 18 Henry WL, Gardin JM & Ware JH 1980 Echocardiographic measurements in normal subjects from infancy to old age. *Circulation* **62** 1054–1061. (doi:10.1161/01.CIR.62.5.1054)
- 19 Manolio TA, Baughman KL, Rodeheffer R, Pearson TA, Bristow JD, Michels VV, Abelmann WH & Harlan WR 1992 Prevalence and etiology of idiopathic dilated cardiomyopathy (summary of a

- National Heart, Lung and Blood Institute Workshop). *American Journal of Cardiology* **69** 1459–1466. (doi:10.1016/0002-9149(92)90901-a)
- 20 Mestroni L, Maisch B, McKenna WJ, Schwartz K, Charron P, Rocco C, Tesson F, Richter A, Wilke A & Komajda M 1999 Collaborative research group of the European human and capital mobility project on familial dilated cardiomyopathy. Guidelines for the study of familial dilated cardiomyopathies. *European Heart Journal* **20** 93–102. (doi:10.1053/ehj.1998.1145)
- 21 Lancellotti P, Tribouilloy C, Hagendorff A, Popescu BA, Edvardsen T, Pierard LA, Badano L & Zamorano JL 2013 Recommendations for the echocardiographic assessment of native valvular regurgitation: an executive summary from the European Association of Cardiovascular Imaging. *European Heart Journal Cardiovascular Imaging* **14** 611–644. (doi:10.1093/ehjci/jet105)
- 22 Gorcsan J III, Abraham T, Agler DA, Bax JJ, Dadrumeaux G, Grimm RA, Martin R, Steinberg JS, Sutton MS & Yu CM 2008 Echocardiography for cardiac resynchronization therapy: recommendations for performance and reporting – a report from the American Society of Echocardiography Dyssynchrony Writing Group endorsed by the Heart Rhythm Society. *Journal of the American Society of Echocardiography* **2** 192–211.
- 23 Neskovic AN & Otasevic P 2005 Stress-echocardiography in idiopathic dilated cardiomyopathy: instructions for use. *Cardiovascular Ultrasound* **3** 1476–7120.
- 24 Hershberger RE, Lindenfeld J, Mestroni L, Seidman CE, Taylor MR & Towbin JA 2009 Genetic evaluation of cardiomyopathy – a Heart Failure Society of America practice guideline. Heart Failure Society of America. *Journal of Cardiac Failure* **15** 83. (doi:10.1016/j.cardfail.2009.01.006)
- 25 Jenni R, Oeschlin EN & van der Loo B 2007 Isolated ventricular non-compaction of the myocardium in adults. *Heart* **93** 11–15. (doi:10.1136/hrt.2005.082271)
- 26 Hazebroek M, Dennert R & Heymans S 2012 Idiopathic dilated cardiomyopathy: possible triggers and treatment strategies. *Netherlands Heart Journal* **20** 332–335. (doi:10.1007/s12471-012-0285-7)

Received in final form 10 January 2017

Accepted 23 March 2017