

# Superior Vena Cava as Gateway to Heart: Metastatic Breast Carcinoma Causing Ball in a Loop Metastasis to Right Atrium

HARPREET SINGH SANDHU<sup>1</sup>, SAMPATH KUMAR MAHADEVAPPA MAHENDRAKAR<sup>2</sup>, SULAIMAN SADRUDDIN LADHANI<sup>3</sup>, AZIZULLAH HAFIZULLAH KHAN<sup>4</sup>, YUNUS SHAFI LOYA<sup>5</sup>

## ABSTRACT

Breast carcinoma is the most common invasive cancer in women worldwide. It metastasizes commonly to bone, lungs, regional lymph nodes and brain. Cardiac metastasis of lung and breast cancers is a known but rare complication of advanced disease with tumour metastasising to pericardium via the locoregional lymphatic system. Here we present a case of 59-year-old female presenting with right upper limb oedema, facial puffiness and features of Superior Vena Cava (SVC) syndrome 15 years after mastectomy and adjuvant chemotherapy, radiotherapy for carcinoma of the right breast. Further evaluation revealed extensive thrombus invading the right internal jugular vein, subclavian vein, SVC with intraluminal extension into right atrium causing ball in a loop obstruction at tricuspid valve. Whole body Positron emission tomography scan confirmed the diagnosis of extensive metastatic disease and patient was managed on palliative therapy. Haematogenous spread and intraluminal growth of metastatic deposits from breast carcinoma 15 years ago is rare and clinical presentation as SVC obstruction has not been reported in our review of literature.

**Keywords:** Cardiac metastasis, Right atrial mass, Superior vena cava syndrome

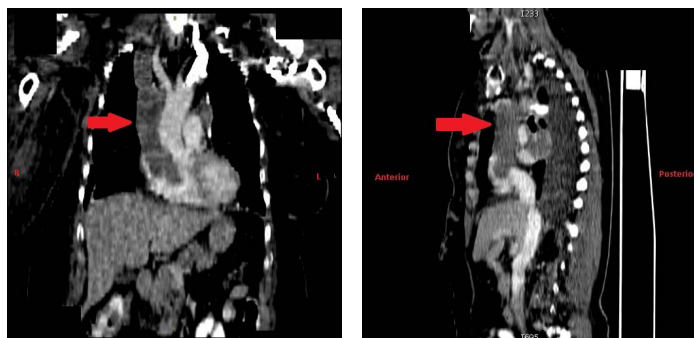
## CASE REPORT

A 59-year-old hypertensive lady with BMI of 26 kg/m<sup>2</sup> was admitted to the Intensive Care Unit (ICU) with chief complaint of cough, right upper limb swelling, facial puffiness and dyspnoea since last two months. Puffiness of face and swelling in her right upper limb was insidious in onset and dyspnoea gradually progressed from New York Heart Association (NYHA) Grade II to Grade IV at the time of admission. Patient was diagnosed with adenocarcinoma of the right breast in the year 2001 and underwent right Modified Radical Mastectomy (MRM) followed by adjuvant chemotherapy for six cycles of 5' Fluorouracil, Epirubicin, Cyclophosphamide (FEC regimen) and postmastectomy chest wall irradiation. In the year 2007 patient developed axillary lymph nodes for which she received re-irradiation followed by tab letrazole 2.5 mg till January 2013.

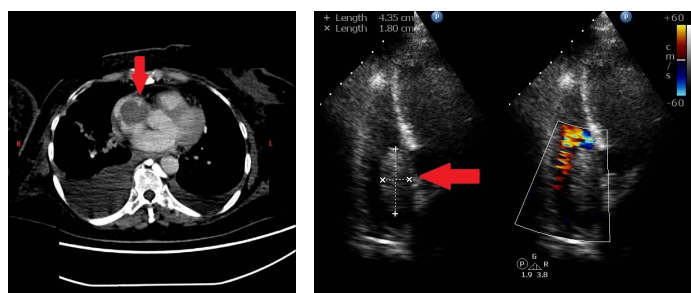
On admission in October 2016 she was conscious but had tachypneic with respiratory rate 28/minute. A heart rate 96 beats/minute, non-invasive blood pressure of 120/86 mmHg and oxygen saturation (SpO<sub>2</sub>) of 95% on two litres nasal oxygen was recorded. On examination the neck veins were engorged and there was gross swelling in the right arm up to shoulder and the movement

of the right arm was restricted due to swelling. Skin was warm and colour was normal. A significant facial puffiness with periorbital swelling was noticed. Bilateral basal crepitations were heard on lung auscultation while cardiovascular system was unremarkable. All peripheral pulses were palpable except right upper limbs due to gross oedema. Systemic examination was unremarkable for other systems.

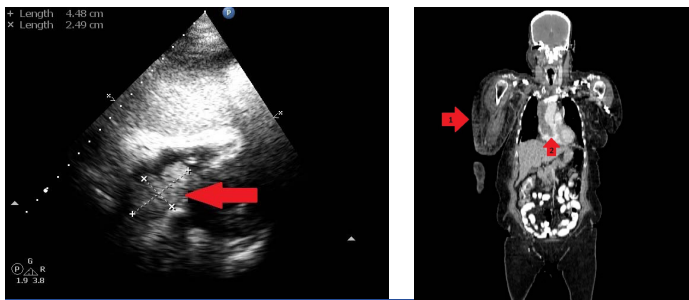
Routine blood investigations were normal and electrocardiogram showed sinus tachycardia. Portable chest roentgenogram revealed suspicious sub-centimetre nodules in bilateral lung fields and mediastinal lymphadenopathy. Ultrasonography of neck was performed which showed thrombus laden right Internal Jugular Vein (IJV) and right Subclavian Vein (SV) with absence of colour flow and spectral waveforms. On further evaluation a Contrast Enhanced Computed Tomography (CECT) scan was performed that revealed multiple enlarged mediastinal lymph nodes with the largest being 70x30 mm in sub-carinal region. Multiple well defined lobulated intensely enhancing solid nodules throughout bilateral lung parenchyma were also noted while there was large hypodense intraluminal filling defect in right IJV, right SV, right Axillary Vein (AV) extending into Right Atrium (RA) [Table/Fig-1-3]. Bedside transthoracic echocardiography (ECHO) revealed a large bi-lobulated mass lesion measuring 44x24 mm attached to the



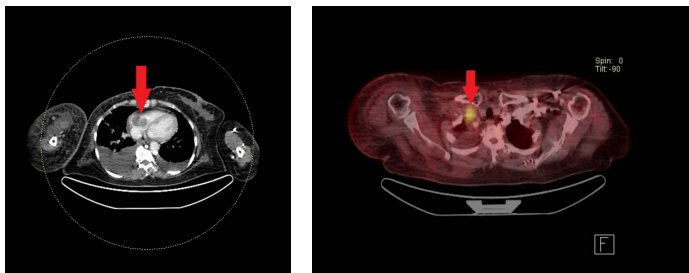
**[Table/Fig-1]:** CECT scan coronal view (reconstruction) showing extensive thrombus extending from SVC into RA (red arrow). **[Table/Fig-2]:** CECT scan sagittal view (reconstruction) showing extensive thrombus extending from SVC into RA (red arrow).



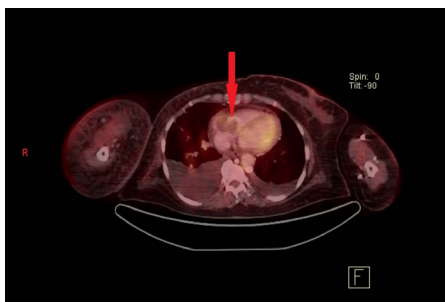
**[Table/Fig-3]:** CECT scan axial view at level of RA showing bi-lobulated intraluminal growth in RA (red arrow). **[Table/Fig-4]:** Four chamber view on ECHO showing intraluminal growth in RA (red arrow).



**[Table/Fig-5]:** Subcostal view on ECHO showing bi-lobulated growth in RA (red arrow). **[Table/Fig-6]:** PET scan coronal view (reconstruction) showing right upper limb oedema (arrow 1) and extensive thrombus extending from SVC into RA (arrow 2).



**[Table/Fig-7]:** PET scan axial view at level of RA showing bi-lobulated growth in RA (red arrow). **[Table/Fig-8]:** An  $^{18}\text{F}$ -FDG PET image showing selective uptake of Fludeoxyglucose in SVC (red arrow).



**[Table/Fig-9]:** An  $^{18}\text{F}$ -FDG PET image showing selective uptake of Fludeoxyglucose by RA mass (red arrow).

interatrial septum and prolapsing into the tricuspid valve. A normal ejection fraction of 65% and pulmonary artery systolic pressure of 30 mmHg was also noted [Table/Fig-4,5] [Video-1].

Based on the CECT and ECHO findings an initial diagnosis of diffusely metastatic disease with intraluminal thrombus extending to RA was made and she was started on enoxaparin 0.6 mg subcutaneously twice daily. Considering a large clot burden patient was started on intravenous urokinase 4400 IU/kg bolus followed by 4400 IU/kg/hr infusion over 24 hours as thrombolytic therapy. Patient was stable hemodynamically however, her facial puffiness and right upper limb oedema did not improve despite one week of therapeutic anticoagulation.

Whole body Positron Emission Tomography (PET) scan was performed which showed multiple bulky confluent and partially necrotic heterogeneously enhancing lymph nodes in the mediastinum. A linear enhancing filling defect showing uptake of Fludeoxyglucose ( $^{18}\text{F}$ -FDG) was seen in the SVC, caudally extending into the RA and rostrally extending into the right IJV for 11 mm with non opacification of the right SV suggestive of tumour thrombosis. Multiple solid discrete and partly confluent nodules were scattered over bilateral lung fields. There was no uptake of  $^{18}\text{F}$ -FDG at the site of surgery or in the axillary lymph nodes suggesting no loco-regional recurrence in the breast. No active liver, adrenal nodule or skeletal lesion could be seen in whole body [Table/Fig-6-9]. In view of the extensive disease with lung metastasis, mediastinal lymphadenopathy and widespread intravascular tumour thrombus extending to right atrium a palliative chemotherapy was considered. She was subsequently discharged on oral exemestane 25 mg daily

with other supportive measures. Patient has a stable disease with regression of symptoms at two months of follow up.

## DISCUSSION

Secondary or metastatic heart tumours are one of the most common heart tumours with an incidence of about 100 times more than primary tumours of the heart [1]. Most primary tumours of the heart are intracavitary in the left atrium and most are benign. Malignant melanoma has high propensity for hematogenous spread and has the highest rate of cardiac metastases. Intrathoracic malignancies like carcinoma of the lung, breast, oesophagus and lymphomas account for origin in rest of the cases of metastasis to the heart.

Cardiac metastases frequently occur in the sixth and seventh decade of life but are often overlooked and under diagnosed under the burden of advanced tumour disease [1,2]. Cardiac metastasis frequently contributes to the mechanism of death in such patients.

Breast carcinoma is the most common invasive cancer affecting approximately 12% of women in India and worldwide [3,4]. It is currently the leading cause of cancer deaths in women accounting for 15% deaths [3,4]. Fortunately early diagnosis and surgical intervention with neoadjuvant chemotherapy have improved the 10 year survival rates in such patients especially at tertiary care centres [5]. Lymphoedema secondary to treatment remains common cause for isolated limb swelling after therapy for breast carcinoma affecting approximately 17% survivors [6]. This presents as an isolated upper limb oedema in approximately three years after surgery or radiation. Breast carcinoma commonly metastatizes to bone, lungs, regional lymph nodes and brain. Cardiac metastasis is a rare complication of advanced breast carcinoma with 10 to 12% incidence [1,2]. Tumour cells first invade epicardial and then myocardial lymphatic system via mediastinal lymph nodes with pericardium being the most common site for cardiac metastasis in advanced cancers (64 to 69% cases) [1].

Haematogenous spread of metastasis from breast carcinoma to the heart chambers has been rarely reported. Intracavitary growth of metastasis is itself very unusual (3 to 5% cases at autopsy) but might have dramatic clinical presentations [1]. Involvement of SVC or IVC has been described as a prelude to endovascular metastasis in RA especially with renal cell carcinoma and hepatocellular carcinoma [1].

The differential diagnosis of right atrial mass includes a myxoma, a thrombus, metastasis or a primary malignant tumour [7]. The mass was initially diagnosed as a large thrombus load on CECT scan and anticoagulation was instituted. Features of this mass on ECHO like pedunculated nature and origin from interatrial septum gave an ECHO diagnosis of probable right atrial myxoma which itself is of rare occurrence [8].

The whole body PET scanning confirmed malignant tumour extending into RA from the SVC with no significant metabolically active lesion in the operative bed, axillary lymph nodes or any other site in the body. An  $^{18}\text{F}$ -FDG PET CT has superior accuracy than conventional CECT for detecting metastatic right heart tumours particularly for patients on long term follow up after resection of tumour, chemotherapy and/or radiotherapy [9,10]. It clinched the diagnosis and helped in deciding about the management plan and prognostication in this case.

Tumour cells do not necessarily spread from the primary tumour but can easily seed in a generalising site such as lungs and liver (primary level of dissemination). The tumour cells then might disseminate from these primary sites to distant organs hematogenously. The extensive metastasis through the venous system into the RA probably represents the secondary level of dissemination from the lungs [11,12].

Overall prognosis of tumours metastasizing to the heart remains poor with expected survival being less than six months from the

time of diagnosis [13]. Surgery is indicated for benign cardiac tumours with excellent prognosis and perioperative mortality less than 1.5% [14]. Palliative chemotherapy and/or radiotherapy is used as an initial line of management for malignant heart tumours.

Non small cell lung cancer, small cell lung cancer and lymphomas have been cited as commonest malignant causes of SVC syndrome in most cases (>80%) [15]. The clinical presentation in this case as limb oedema and features of SVC syndrome 15 years after the initial therapy is rare. Though cardiac metastasis is known complication of advanced metastatic breast cancer (10-12%) such extensive intraluminal growth of these metastatic deposits causing SVC syndrome has not been reported in our review of published literature. While the echocardiographic features of the growth suggested a ball in a loop myxoma like lesion, <sup>18</sup>F-FDG PET CT confirmed the diagnosis. Considering the widespread and unresectable malignant disease palliation was considered as the goal of our intervention and patient was discharged on chemotherapy and supportive care at home.

## CONCLUSION

In the present era of advanced surgical options, neoadjuvant chemotherapy and hormonal therapy, a clinician faces the challenge of encountering such cases of advanced metastatic disease even decades after initial therapy. A high index of suspicion along with meticulous clinical skills and imaging techniques are thus necessary for the early diagnosis and appropriate management.

## REFERENCES

- [1] Goldberg AD, Blankstein R, Padera RF. Tumors Metastatic to the Heart. *Circulation*. 2013;128(16):1790–94.
- [2] Bussani R, De-Giorgio F, Abbate A, Silvestri F. Cardiac metastases. *J Clin Pathol*. 2007;60(1):27–34.

- [3] McGuire A, Brown JAL, Malone C, McLaughlin R, Kerin MJ. Effects of age on the detection and management of breast cancer. *Cancers (Basel)*. 2015;7(2):908–29.
- [4] Agarwal G, Ramakant P. Breast Cancer Care in India: The Current Scenario and the Challenges for the Future. *Breast Care (Basel)*. 2008;3(1):21–27.
- [5] Gadgil A, Roy N, Sankaranarayanan R, Muwonge R, Sauvaget C. Effect of comprehensive breast care on breast cancer outcomes: a community hospital based study from Mumbai, India. *Asian Pac J Cancer Prev*. 2012;13(4):1105–09.
- [6] DiSipio T, Rye S, Newman B, Hayes S. Incidence of unilateral arm lymphoedema after breast cancer: a systematic review and meta-analysis. *Lancet Oncol*. 2013;14(6):500–15.
- [7] Ozer N, Deveci OS, Okutucu S, Demircin M. Asymptomatic right atrial myxoma originating from the inferior vena cava and right atrium junction in a patient with breast ductal adenocarcinoma. *Türk Kardiyol Dern Ars*. 2009;37(7):479–82.
- [8] Grebenc ML, Rosado-de-Christenson ML, Green CE, Burke AP, Galvin JR. Cardiac myxoma: imaging features in 83 patients. *Radiographics*. 2002;22(3):673–89.
- [9] Johnson TRC, Becker CR, Wintersperger BJ, Herzog P, Lenhard MS, Reiser MF. Images in cardiovascular medicine. Detection of cardiac metastasis by positron-emission tomography-computed tomography. *Circulation*. 2005;112(4):e61–62.
- [10] Orcurto MV, Delaloye AB, Letovanec I, Martins Favre M, Prior JO. Detection of an asymptomatic right-ventricle cardiac metastasis from a small-cell lung cancer by F-18-FDG PET/CT. *J Thorac Oncol*. 2009;4(1):127–30.
- [11] Katalinic D, Stern-Padovan R, Ivanac I, Aleric I, Tentor D, Nikolac N, et al. Symptomatic cardiac metastases of breast cancer 27 years after mastectomy: a case report with literature review--pathophysiology of molecular mechanisms and metastatic pathways, clinical aspects, diagnostic procedures and treatment modalities. *World J Surg Oncol*. 2013;11:14.
- [12] Weiss L. Cascade spread of blood-borne metastases in solid and non-solid cancers of humans. In: Weiss L, Gilbert H, editors. *Pulmonary metastasis*. Boston: Hall; 1978.
- [13] Ohnishi M, Niwayama H, Miyazawa Y, Kondo N, Imai H, Nishimoto Y, et al. [Echocardiography in patients with malignant metastatic neoplasms of the heart and great vessels]. *J Cardiol*. 1990;20(2):377–84.
- [14] Carrel T, Erdős G, Eberle B, Englberger L, Pfammatter JP, Schmidli J, et al. Surgical treatment of cardiac tumours - an overview and presentation of interesting cases. *Cardiovascular Medicine*. 2011;14(9):242–57.
- [15] Wilson LD, Dettterbeck FC, Yahalom J. Clinical practice. Superior vena cava syndrome with malignant causes. *N Engl J Med*. 2007;356(18):1862–69.

### PARTICULARS OF CONTRIBUTORS:

1. FNB Critical Care Medicine Trainee, Department of Intensive Care, Prince Aly Khan Hospital, Nesbit Road, Mazgaon, Mumbai, Maharashtra, India.
2. Intensivist, Department of Intensive Care, Prince Aly Khan Hospital, Nesbit Road, Mazgaon, Mumbai, Maharashtra, India.
3. Consulting Physician, Department of Pulmonary Medicine, Prince Aly Khan Hospital, Nesbit Road, Mazgaon, Mumbai, Maharashtra, India.
4. ICU Director, Department of Intensive Care, Prince Aly Khan Hospital, Nesbit Road, Mazgaon, Mumbai, Maharashtra, India.
5. Consulting Cardiologist, Department of Cardiology, Prince Aly Khan Hospital, Nesbit Road, Mumbai, Maharashtra, India.

### NAME, ADDRESS, E-MAIL ID OF THE CORRESPONDING AUTHOR:

Dr. Harpreet Singh Sandhu,  
FNB Critical Care Medicine Trainee, Department of Intensive Care, Prince Aly Khan Hospital, Nesbit Road, Mazgaon,  
Mumbai, Maharashtra-400010, India.  
E-mail: itallionstallion17@gmail.com

Date of Submission: **Dec 28, 2016**

Date of Peer Review: **Feb 13, 2017**

Date of Acceptance: **May 20, 2017**

Date of Publishing: **Jul 01, 2017**

FINANCIAL OR OTHER COMPETING INTERESTS: None.