



CLINICAL CASE

Hepatic Actinomycosis



Filipa Ávila^{a,*}, Vera Santos^b, Paulo Massinha^b, José Renato Pereira^b,
Rui Quintanilha^c, António Figueiredo^d, António Lázaro^d, Sofia Carrelho^e,
João Santos Coelho^e, Eduardo Barroso^e, Maria Antónia Duarte^a

^a Hospital do Divino Espírito Santo de Ponta Delgada, Ponta Delgada, Portugal

^b Gastroenterology Department, Hospital do Divino Espírito Santo de Ponta Delgada, Ponta Delgada, Portugal

^c Surgery Department, Hospital do Divino Espírito Santo de Ponta Delgada, Ponta Delgada, Portugal

^d Pathology Department, Hospital Curry Cabral, Lisboa, Portugal

^e Hepato-Bilio-Pancreatic and Transplantation Centre, Hospital Curry Cabral, Lisboa, Portugal

Received 7 April 2014; accepted 5 August 2014

Available online 7 January 2015

KEYWORDS

Actinomyces;
Granulomatous
Disease;
Actinomycosis;
Liver Diseases

Abstract

Actinomycosis is a rare disorder caused by an anaerobic gram-positive bacillus (*Actinomyces*), predominantly by the *Actinomyces israelii* species. Only 20% of cases show an abdominal manifestation, the appendix and ileocecal valve being the most frequent locations. Definitive diagnosis is based on microbiological cultures, microscopy or macroscopy examination. Nevertheless, histological examination of the percutaneous biopsy and blood microbiological cultures are rarely positives. Preoperative diagnosis is hampered by the lack of specific clinical and imaging manifestations, which often mimic malignancy. The rate of preoperative diagnosis is less than 10%, however, the outcome is excellent, with a low mortality rate. The authors describe the case of a patient who was diagnosed with primary hepatic actinomycosis only by a histological examination of the surgical specimen of left hepatectomy extended to segments V and VIII, for suspected malignant lesion. This case demonstrates the difficulties in diagnosing hepatic actinomycosis.

© 2014 Sociedade Portuguesa de Gastrenterologia. Published by Elsevier España, S.L.U. All rights reserved.

PALAVRAS-CHAVE

Actinomyces;
Actinomicose;
Doença
Granulomatosa;
Doenças do Fígado

Actinomicose Hepática

Resumo

A actinomicose é uma entidade clínica rara, causada por uma bactéria anaeróbia gram-positiva (*Actinomyces*), predominantemente da espécie *Actinomyces israelii*. Apenas em 20% dos casos apresenta manifestação abdominal, sendo o apêndice e a válvula ileocecal as

* Corresponding author.

E-mail address: filipaavila@gmail.com (F. Ávila).

localizações mais frequentes. Os autores descrevem o caso de um doente em que foi feito o diagnóstico de actinomicose hepática primária apenas pelo exame histológico da peça cirúrgica de hepatectomia esquerda alargada aos segmentos V e VIII, por suspeita de lesão maligna. Este caso demonstra a dificuldade diagnóstica da actinomicose hepática. O diagnóstico pré-operatório é dificultado pela falta de manifestações clínicas e imagiológicas específicas, muitas vezes simulando doença maligna. Para além disso, as culturas e o exame histológico de biópsia percutânea raramente são positivos. A taxa de diagnóstico pré-operatório é inferior a 10%, contudo o prognóstico é bom, apresentando uma taxa de mortalidade de cerca de 7,6%.

© 2014 Sociedade Portuguesa de Gastrenterologia. Publicado por Elsevier España, S.L.U. Todos os direitos reservados.

1. Introduction

Actinomycosis is a rare chronic, granulomatous infection caused by gram-positive bacilli of the genus *Actinomyces*. There are 13 different species, but only 6 are associated with human disease. The most common pathogenic specie in humans is *Actinomyces israeli*.¹ These microorganisms are prominent among the commensal flora of the oropharynx, gastrointestinal tract and female genital tract.² Actinomycosis is most frequently associated with cervicofacial infection. Only 20% of the cases present abdominal manifestations, the appendix and the ileocecal region being the most common affected sites.³ Liver involvement occurs in 15% of abdominal infections representing 5% of all cases of actinomycosis,⁴ and it is usually secondary to other intra-abdominal infection.⁵ The insidious course with nonspecific symptoms makes the diagnosis of this condition a challenging.

2. Case report

A 38-year-old man was referred to the Gastroenterology Department for a history of epigastric pain refractory to proton pump inhibitor therapy. He reported a 2 years history of night sweats and weight loss (12% of body weight). The patient denied other dyspeptic complaints, hematemesis or melena and systemic symptoms, including fever, malaise and anorexia. His past medical history included duodenal ulcer treated with proton pump inhibitor, 3 years ago. No history of previous surgeries. He was medicated with omeprazole 20 mg qd on regular basis. The physical examination was normal. Laboratory tests evidenced normocytic/normochromic anemia (Hb 12 g/dl, normal: 14–18), leukocytosis ($15.21 \times 10^3/\mu\text{L}$, normal: 4–11.5) with neutrophilia (80%, normal: 50–70), elevation of inflammatory parameters (C-reactive protein: 2.46 mg/dl (normal 0–0.3) and erythrocyte sedimentation rate 33 mm (normal 0–15) and mild elevation of alkaline phosphatase 170 U/L (normal: 40–129). The remaining analytical assessment was normal, including tumor markers and human immunodeficiency virus antibody test. Infection by *Mycobacterium tuberculosis* was excluded. Upper gastrointestinal endoscopy revealed pyloric substenosis, yet allowing the passage of the endoscope

to the duodenum, probably resulting from previous duodenal ulcer. Biopsies were performed in normal mucosa, which revealed chronic gastritis due to *Helicobacter pylori*. Gastroduodenal transit was normal. An abdominal ultrasound identified in segment IV of the liver a pseudonodular lesion, hypoechoic, heterogeneous with partially undefined limits with 45×33 mm (Fig. 1). A contrast-enhanced computed tomography (CT) scan showed the same lesion, presenting low enhanced in the arterial phase, with progressive enhanced in the late phase (Fig. 2). To further characterize the lesion a magnetic resonance imaging (MRI) was performed revealing the same nodular lesion with lobulated and undefined limits of 4 cm in its greatest diameter, hypointense signal on T1 and hyperintense signal on T2 (Fig. 3). These images were suggestive of cholangiocarcinoma but secondary deposit cannot be excluded. A CT-guided liver biopsy revealed an inflammatory pseudotumor/inflammatory myofibroblast tumor (Fig. 4). The patient was then referred to referral Hospital in hepatobiliary surgery where he underwent left hepatectomy extended to segments V and VIII. The histological examination of surgical tissue demonstrated abscesses due to *Actinomyces* (Fig. 5). The patient was treated with doxycycline for three months. Eighteen months after the surgery, he is completely asymptomatic.

3. Discussion

Actinomycosis is a rare cause of intra-abdominal infection. The main risk factors associated with this condition are loss of integrity of the gastrointestinal mucosa, previous abdominal surgery, intra-abdominal infection, gastrointestinal foreign body and immunosuppression.^{5,6} Liver involvement occurs by hematogenous spread via the portal vein from either a mucosal injury or infection.⁷ Sharma et al. conducted a study which found that about 17.5% of cases of abdominal actinomycosis were associated with previous abdominal or pelvic procedures performed within the last year.⁸ In this case, the time between diagnosis and the initiation of duodenal ulcer was one year. Despite the known major risk factors, hepatic actinomycosis is cryptogenic in 80% of cases and^{4,6} polymicrobial in 33%.⁹ As in our case, there is male predominance (70–74%) in immunocompetent

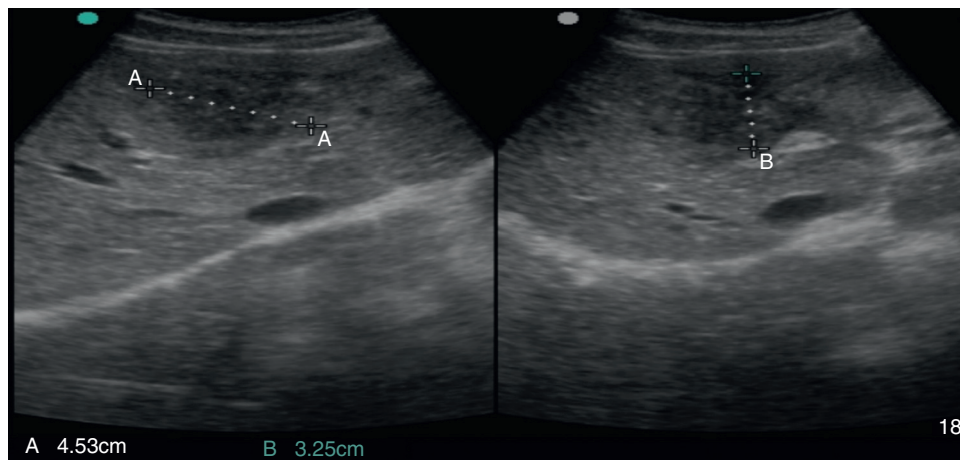


Figure 1 Abdominal ultrasound: pseudonodular lesion, hypoechoic, heterogeneous and partially undefined in segment IV of the liver.

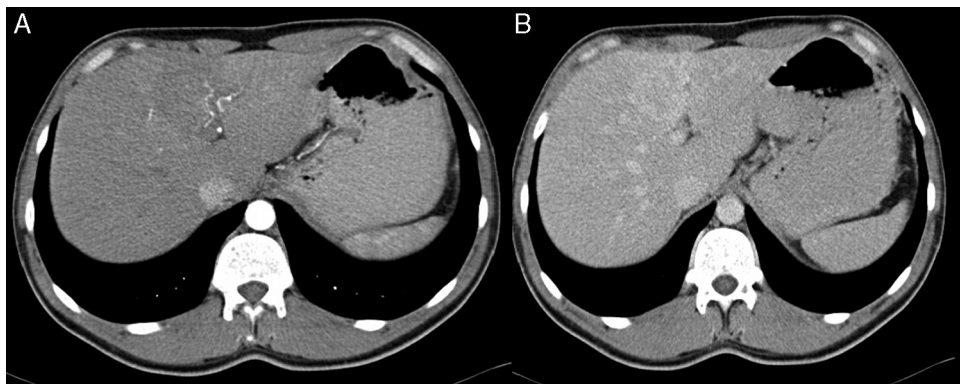


Figure 2 Contrast-enhanced computed tomography scan: low enhanced lesion in the arterial phase (A), with progressive enhanced in the late phase (B).

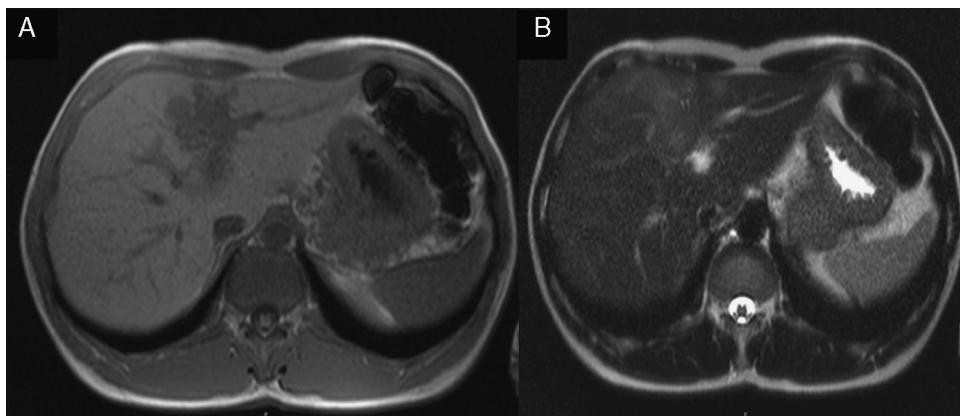


Figure 3 MRI: nodular lesion with lobulated and undefined limits, hypointense signal on T1 (A) and hyperintense signal on T2 (B).

adults, aged between 30 and 50 years.^{4,5,8} Due to an insidious course, it takes several weeks to months^{9,10} of symptoms to make the diagnosis with a range of 4 days to 18 months until presentation.¹⁰ In addition, both clinical and laboratory manifestations are nonspecific. The most frequent symptoms are fever (83.3%), abdominal pain (74.5%)

and weight loss (50.9%).^{11,12} Analytically presents with leukocytosis (75%), elevated alkaline phosphatase (83.3%) and erythrocyte sedimentation rate,^{6,8,13} as in this case. Some studies have demonstrated an association with elevated levels of CA 19.9, but with lower values than those described for malignant conditions.¹⁴

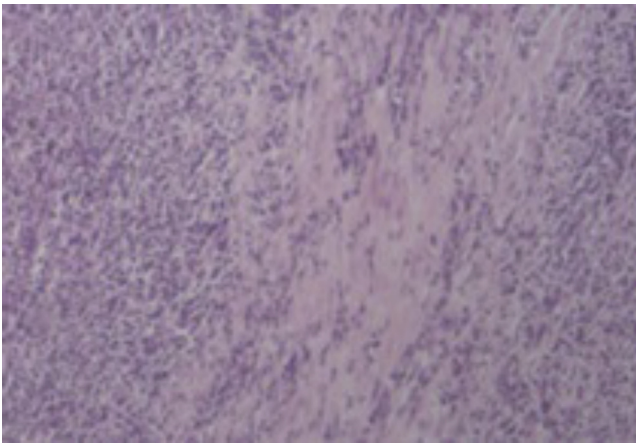


Figure 4 Histology of liver fragment: inflammatory pseudotumor (hematoxylin and eosin 100 \times).

In imaging studies, particularly in ultrasound, CT and MRI, hepatic actinomycosis presents with a single hypodense lesion in 66% of cases. In the remaining 33% it may present as multiple hepatic abscesses.^{2,5,10,15,16} Thus, it is necessary to distinguish it from both malignant lesions (primary or secondary tumor deposits) and benign lesions (cystic lesions, pyogenic abscesses, amebiasis or echinococcosis),⁵ taking into account the characteristics of the lesion. In about 44.7% of the cases mimics a malignant lesion^{5,9} and the right lobe is the most affected (56.5%).^{2,5,16} MRI is characterized by hypointense signal on T1- and hyperintense signal on T2.¹⁷ In our case, the lesion presents features of malignancy, including heterogeneous content and undefined limits which associated with MRI study requires differential diagnosis with cholangiocarcinoma, despite the young age of the patient. The diagnosis of hepatic abscess was also considered because the patient had fever for a long period, however the imagiologic studies did not support this hypothesis.

Definitive diagnosis is based on blood cultures,^{6,7,9} microscopy (percutaneous biopsy, laparoscopic or surgical

tissue specimens) and macroscopic examination, which reveal basophilic filament aggregates and yellow "sulfur granules".^{4,6,9} In our patient histological diagnosis of inflammatory pseudotumor probably corresponds to a fragment of the capsule of abscess, which is constituted by fibrous connective tissue with focal inflammatory infiltrate.

The rate of preoperative diagnosis is less than 10%,^{4,18} despite advanced imaging techniques. In addition, blood cultures are positive in only 15.4% of the cases^{4,8} and percutaneous biopsy diagnosis is not always conclusive.

Therapeutic options available are antibiotics, surgical resection and percutaneous drainage either alone or in combination.^{6,9} There are no current guidelines available, particularly in what pertains the indication for surgery. In the literature, are not described guidelines for therapy, particularly for surgery indication.⁹ Early initiation of antibiotics is usually effective.⁸ Surgery should be reserved for the cases in which percutaneous drainage is not possible and for larger lesions in which there is a greater amount of necrotic tissue and therefore lower penetrance of antibiotic.¹⁰

The recommended antibiotics are a penicillin derivative, tetracycline or clindamycin.⁶ Duration of treatment is variable with courses lasting from 3 to 6 months.^{5,10} Despite the usual delay in making the diagnosis and consequently in initiating therapy, the outcome is excellent, with a mortality rate of 7.6%.^{2,5,9,16,19}

In conclusion, primary hepatic actinomycosis is a rare disease and difficult to diagnosis, since its clinical and analytical presentation is nonspecific. The differential diagnosis is extensive encompassing both benign and malignant conditions. However, it has a good prognosis after appropriate treatment.

Ethical disclosures

Protection of human and animal subjects. The authors declare that no experiments were performed on humans or animals for this study.

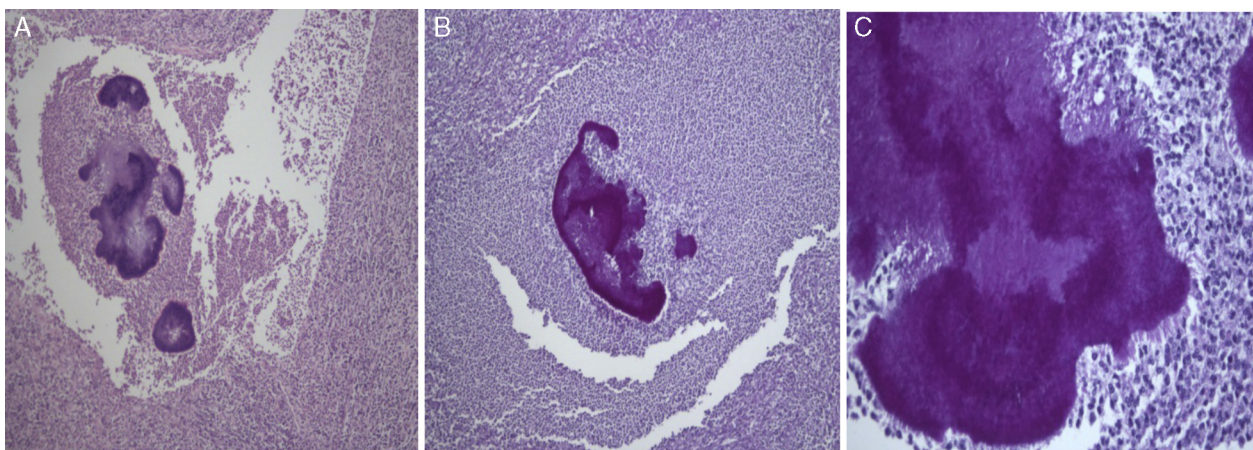


Figure 5 Histological examination allowed the observation of abscesses in several areas. A central zone with neutrophil granulocytes and necrotic tissue is surrounded by a band of fibrous connective tissue that constitutes the abscess capsule, showing the plugs of *Actinomyces* (A – hematoxylin and eosin, magnification 5 \times). At higher magnification, filamentous structures corresponding to aggregates of *Actinomyces* were identified (B and C – PAS 5 \times and 40 \times magnification respectively).

Confidentiality of data. The authors declare that they have followed the protocols of their work center on the publication of patient data.

Right to privacy and informed consent. The authors have obtained the written informed consent of the patients or subjects mentioned in the article. The corresponding author is in possession of this document.

Conflicts of interest

The authors have no conflicts of interest to declare.

References

1. Brook I. actinomycosis: diagnosis and management. *South Med J.* 2008;101:1019–23.
2. Wong JJ, Kinney TB, Miller FJ, Rivera SG. Hepatic actinomycotic abscesses: diagnosis and management. *Am J Roentgenol.* 2006;186:174–6.
3. Sakaguchi Y, Isowa N, Nakazaki H, Takeda K, Tokuyasu H, Saitoh Y, et al. Acute cardiac tamponade caused by extension of multiple hepatic actinomycotic abscesses. *Intern Med.* 2012;51:305–9.
4. Lall T, Shehab TM, Valenstein P. Isolated hepatic actinomycosis: a case report. *J Med Case Rep.* 2010;4:45.
5. Chen LW, Chang LC, Shie SS, Chien RN. Solitary actinomycotic abscesses of liver: report of two cases. *Int J Clin Pract.* 2006;60:104–7.
6. Christodoulou N, Papadokis I, Velegarakis M. Actinomycotic liver abscesses. Case report and review of the literature. *Chir Ital.* 2004;56:141–6.
7. Wayne MG, Naran R, Chauhdry A, Steele J. Hepatic actinomycosis mimicking an isolated tumor recurrence. *World J Surg Oncol.* 2011;9:70.
8. Sharma M, Briski LE, Khatib R. Hepatic actinomycosis: an overview of salient features and outcome of therapy. *Scand J Infect Dis.* 2002;34:386–91.
9. Kanellopoulou T, Alexopoulou A, Tanouli MI, Tiniakos D, Giannopoulos D, Koskinas J, et al. Primary hepatic actinomycosis. *Am J Med Sci.* 2010;339:362–5.
10. Lai AT, Lam CM, Ng KK, Yeung C, Ho WL, Poon LT, et al. Hepatic actinomycosis presenting as a liver tumour: case report and a literature review. *Asian J Surg.* 2004;27:345–7.
11. Islam T, Athar MN, Athar MK, Usman MH, Misbah B. Hepatic actinomycosis with infiltration of the diaphragm and right lung: a case report. *Can Respir J.* 2005;12:336–7.
12. Kanellopoulou T, Alexopoulou A, Tiniakos D, Koskinas J, Archimandritis AJ. Primary hepatic actinomycosis mimicking metastatic liver tumour. *J Clin Gastroenterol.* 2010;44:458–9.
13. Min KW, Paik SS, Han HH, Jang KS. Hepatobiliary and pancreatic: hepatic actinomycosis. *J Gastroenterol Hepatol.* 2012;27:844.
14. Soardo G, Bason L, Intini S, Avellini C, Sechi LA. Elevated serum CA 19-9 in hepatic actinomycosis. *Scand J Gastroenterol.* 2005;40:1372–3.
15. Ha KK, Lee HJ, Kim H, Ro HJ, Park YH, Cha SJ, et al. Abdominal actinomycosis: CT findings in 10 patients. *AJR.* 1993;161:791–4.
16. Felekouras E, Menenakos C, Griniatsos J, Deladetsima I, Kalaxanisi N, Nikiteas N, et al. Liver resection in cases of isolated hepatic actinomycosis: case report and review of the literature. *Scand J Infect Dis.* 2004;36:535–8.
17. Kim HS, Park NH, Park KA, Kang SB. A case of pelvic actinomycosis with hepatic actinomycotic pseudotumour. *Gynecol Obstet Invest.* 2007;64:95–9.
18. Brow JR. human actinomycosis: CT features. *J Comput Assist Tomogr.* 1986;10:335–7.
19. Lakshmana Kumar YC, Javherani R, Malini A, Prasad SR. Primary hepatic actinomycosis. *Trans R Soc Trop Med Hyg.* 2005;99:868–70.