



Contents lists available at ScienceDirect

## International Journal of Surgery Case Reports

journal homepage: [www.casereports.com](http://www.casereports.com)

# Spontaneous non-traumatic mediastinal hematoma associated with oral anticoagulant therapy: A case report and literature review



Masashi Mikubo\*, Dai Sonoda, Hirotsugu Yamazaki, Masahito Naito, Yoshio Matsui, Kazu Shiomi, Yukitoshi Satoh

Department of Thoracic Surgery, Kitasato University School of Medicine, 1-15-1, Kitasato, Minami-ku, Sagami-hara, Kanagawa 252-0374, Japan

## ARTICLE INFO

## Article history:

Received 15 June 2017

Received in revised form 18 August 2017

Accepted 18 August 2017

Available online 23 August 2017

## Keywords:

Spontaneous mediastinal hematoma

Anticoagulant therapy

Surgery

Case report

## ABSTRACT

**INTRODUCTION:** Mediastinal hematoma is usually caused by thoracic trauma or a ruptured aortic aneurysm. Spontaneous non-traumatic mediastinal hematomas are rare but potentially life-threatening conditions that can occur in patients taking anticoagulants.

**PRESENTATION OF CASE:** We report a case of 72-year-old man with a massive mediastinal hematoma associated with anticoagulant therapy. He had complained of acute chest discomfort and subsequent tarry diarrhea. Because he had been taking warfarin for paroxysmal atrial fibrillation, an upper gastrointestinal hemorrhage was initially suspected, but no bleeding was detected by upper endoscopy. A computed tomography scan revealed a massive posterior mediastinal hematoma and markedly compressed surrounding structures. The compression of the left atrium caused a congested lung and exacerbated respiratory and hemodynamic status despite conservative therapy. Therefore, we surgically removed the hematoma. Immediately after removal, the respiratory and hemodynamic conditions improved, and the postoperative course was uneventful.

**DISCUSSION:** Spontaneous mediastinal hematoma is rare but can occur in patients who are administered anticoagulants regardless of the therapeutic level of anticoagulation. Although conservative therapy is commonly effective, active surgical intervention should be considered for cases in which the hematoma is symptomatic or conservative therapy is ineffective.

**CONCLUSION:** To facilitate prompt and proper management, clinicians should be aware of this condition as a potential complication of anticoagulant therapy.

© 2017 The Authors. Published by Elsevier Ltd on behalf of IJS Publishing Group Ltd. This is an open access article under the CC BY-NC-ND license (<http://creativecommons.org/licenses/by-nc-nd/4.0/>).

## 1. Introduction

Mediastinal hematomas usually occur secondary to thoracic trauma or a ruptured aortic aneurysm [1,2], and spontaneous non-traumatic mediastinal hematomas are rare. Although anticoagulant therapy is one of the risk factors for hemorrhagic events, and because mediastinum is an unusual bleeding site and difficult to recognize in radiographic examinations in the early stage, mediastinal hemorrhage is easily missed in initial medical examinations. There have been only a few reports of mediastinal hemorrhage, and the clinical features and treatment strategy have not been elucidated. Here, we present a case of mediastinal hematoma as a

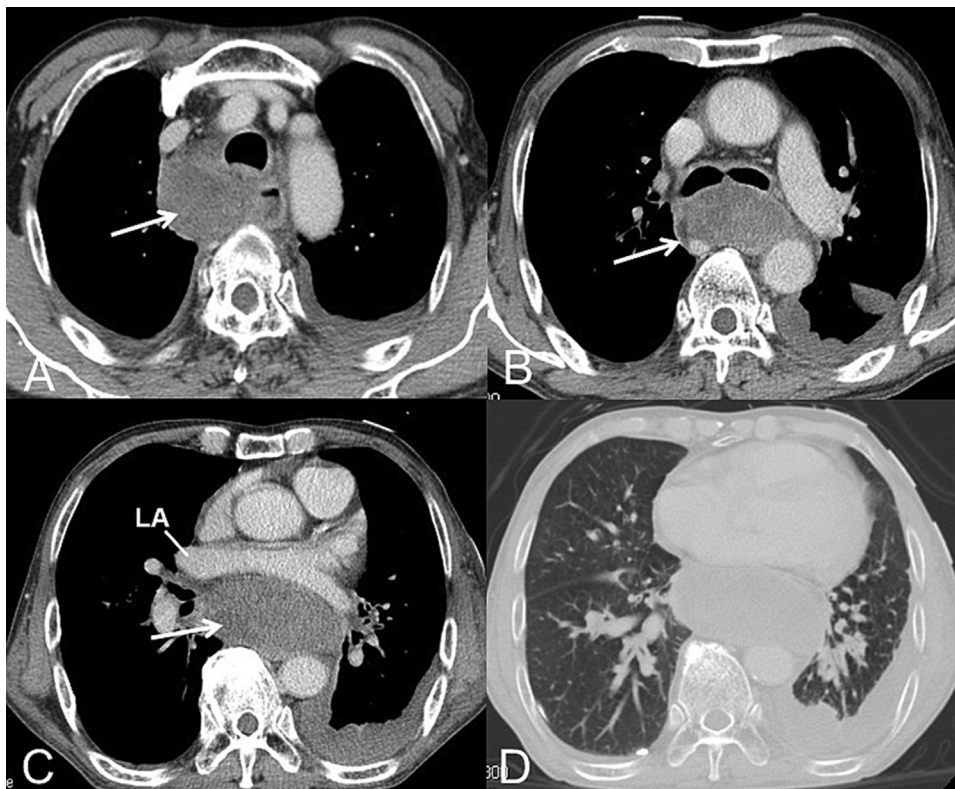
complication of warfarin that required surgical removal. This work has been reported in line with the SCARE criteria [3].

## 2. Presentation of case

A 72-year-old man had complained of chest discomfort and subsequent tarry diarrhea. He had a medical history of hypertension, chronic obstructive pulmonary disease (COPD) and paroxysmal atrial fibrillation, and he had been taking warfarin for arrhythmia. He had a smoking history of 20 pack-years and no family history of genetic disorders. The laboratory studies indicated anemia (hemoglobin 7.2 mg/dl) and a prolonged prothrombin time (PT-INR 5.9). Because gastrointestinal bleeding was suspected, an upper endoscopy was performed after the administration of vitamin K. There was only a mild degree of submucosal hemorrhage in the esophagus and no active bleeding. A computed tomography (CT) scan was performed to determine the cause of anemia and it demonstrated a mediastinal mass in the posterior mediastinum. The patient developed further chest discomfort and dyspnea after the examinations; therefore, he was referred to our institution for further investigation and treatment. A CT scan revealed a mas-

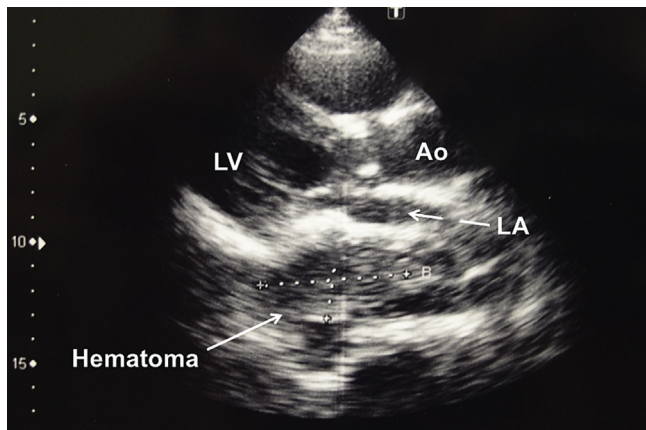
\* Corresponding author.

E-mail addresses: [m.mikubo1220@hotmail.com](mailto:m.mikubo1220@hotmail.com) (M. Mikubo), [a\\_boy\\_with\\_many\\_dreams@yahoo.co.jp](mailto:a_boy_with_many_dreams@yahoo.co.jp) (D. Sonoda), [ymzkhrtg@med.kitasato-u.ac.jp](mailto:ymzkhrtg@med.kitasato-u.ac.jp) (H. Yamazaki), [mnaitoh@med.kitasato-u.ac.jp](mailto:mnaitoh@med.kitasato-u.ac.jp) (M. Naito), [yoshiom@med.kitasato-u.ac.jp](mailto:yoshiom@med.kitasato-u.ac.jp) (Y. Matsui), [shiomi@med.kitasato-u.ac.jp](mailto:shiomi@med.kitasato-u.ac.jp) (K. Shiomi), [ysatoh@med.kitasato-u.ac.jp](mailto:ysatoh@med.kitasato-u.ac.jp) (Y. Satoh).



**Fig. 1.** Preoperative computed tomography scan findings.

A massive mediastinal hematoma extended from the superior to the posterior mediastinum (arrows). The trachea, main bronchi, and left atrium were extremely anteriorly displaced by the hematoma (A–C), and a congested lung was detected (D). LA, left atrium.



**Fig. 2.** Preoperative echocardiogram findings.

The left atrium was compressed and narrowed because of the hematoma. LA, left atrium; LV, left ventricle; Ao, aorta.

sive mediastinal mass extending from the superior to the posterior mediastinum and left pleural effusion. The trachea and left atrium were extremely displaced by the mass in the anterior direction, and the lungs were congested (Fig. 1). The mediastinal mass was compatible with a hematoma from the CT value. There were no abnormal findings in the cardiac and great vessels, and no bleeding lesions were identified other than lesions in the mediastinum. An aortogram did not indicate a feeding artery or extravasation. Echocardiography showed normal ventricular systolic function, but the left atrium was compressed and narrowed because of the hematoma (Fig. 2). Upon hospital admission, the patient's blood pressure was 120/80 mmHg, and his heart rate was 120 bpm with an irregular rhythm. An arterial blood gas analysis on 40% oxy-

gen revealed acidemia, hypoxemia, and hypercapnia (pH 7.17, PaO<sub>2</sub> 90.8 mmHg, and PaCO<sub>2</sub> 77.8 mmHg), and he was therefore placed on non-invasive positive-pressure ventilation. After admission, he developed further chest discomfort and dyspnea despite a blood transfusion and pleural effusion drainage. We theorized that the left atrium was compressed because of the hematoma and that left atrial overload was causing lung congestion and the worsening of both the respiratory and hemodynamic status. Therefore, we decided to perform a surgical intervention to decompress the left atrium.

Surgery was performed through a right posterolateral thoracotomy; the patient did not receive thoracoscopic surgery because his respiratory condition was poor, and one-lung ventilation made it difficult to maintain oxygenation. Thoracotomy revealed that the superior and posterior mediastinum was diffusely enlarged, and the mediastinal pleura was an abnormal dusky red. When we opened the posterior mediastinal pleura, we identified a large hematoma compressing the left atrium, esophagus, and trachea. A most part of the hematoma was coagulated, and collected blood could not be adequately drained from the incision of the mediastinal pleura. We therefore surgically removed as much of the hematoma as possible. Immediately after removal of the hematoma, the tachycardia improved, and respiratory and hemodynamic parameters were stabilized. We detected no active bleeding or abnormal vessels that might have caused the hematoma. The post-operative course was uneventful, and the patient was discharged 23 days after surgery. After a 4-year follow-up, the patient remains in good health, with no evidence of mediastinal hematoma recurrence.

### 3. Discussion

Several causes of mediastinal hematomas have been recognized, including traumatic vascular injury and a ruptured aortic

**Table 1**

Summary of clinical data from patients who developed spontaneous mediastinal hematomas while taking anticoagulants.

Author (years)	Age, Sex	Symptom	Comorbidity	Anticoagulant	Control	Treatment	Outcome
1) Packer [6]	39F	Chest pain	TP	Warfarin	Usual	CT	Alive
2) Turez [7]	74M	Dyspnea Chest pain	PE	Heparin	Usual	CT	Alive
3) Abaskaron [8]	54F	Chest pain	DVT	Warfarin	Usual	CT	Alive
4) Singh [9]	72M	Hoarseness Dysphagia	MI	Heparin Streptokinase	Excessive effect	CT	Alive
5) Mazziotti [10]	35F	Chest pain	TP	Warfarin	Usual	CT	Alive
6) Lawler [11]	66M	Chest pain Cough	Af	Warfarin	Unknown	Surgery	Alive
7) Suddes [1]	48M	Chest pain	MI	Heparin tPA	Unknown	CT	Alive
8) Kamiyoshihara [12]	59M	Back pain Cough	Brain infarction	Aspirin	Usual	CT	Alive
9) Jette [13]	64F	Chest pain Cough	DVT, PE	Warfarin	Usual	CT	Alive

Af, atrial fibrillation; CT, conservative therapy; DVT, deep vein thrombosis; MI, myocardial infarction; PE, pulmonary embolism; TP, thorombophlebitis; tPA, tissue plasminogen activator.

aneurysm [1,2]. However, spontaneous non-traumatic mediastinal hematoma is rare, and it has been reported to occur in association with three underlying conditions: (1) secondary to bleeding disorders or clotting abnormalities, such as hemodialysis, anticoagulants, or hemodyscrasia; (2) secondary to hemorrhage from mediastinal organs, cysts, or tumors; and (3) idiopathic hemomediastinum after a sudden increase in the intrathoracic pressure during coughing, sneezing, or vomiting [4]. Although anticoagulant therapy is widely used in the management of various cardiovascular diseases, and hemorrhage is a commonly recognized complication, most hemorrhages occur in the mucosal region, such as the gastrointestinal tract, urinary tract or gynecological organs [5]. Only nine cases of mediastinal hematomas associated with anticoagulant therapy have been reported in the literature (Table 1) [1,6–13]. The anticoagulant treatments involved a variety of drugs, including warfarin, heparin, thrombolytic agents, and aspirin. Although the effect of anticoagulation deviated from the therapeutic range in our case, six patients had appropriate levels of anticoagulation in previous reports, suggesting that mediastinal hematoma can occur in patients who are administered anticoagulants regardless of the therapeutic level. The most common symptom was chest pain, but the intensity varied from acute onset of severe to mild pain. Additionally, abnormal shadows in chest radiographs could not be observed until the hematoma became large. Therefore, it may be difficult to reach the correct diagnosis in an early state unless clinicians recognize and suspect the condition. In previous reports, cardiovascular events were suspected because of chest symptoms and the presence of comorbidities; bleeding from the gastrointestinal tract was considered a cause for anemia, and an upper endoscopy was performed before chest CT scan. Mediastinal hematomas were not actually suspected at the initial medical examination. For prompt diagnosis and treatment, we should be aware that mediastinal hematoma is within the differential diagnosis of patients who present with chest symptoms and are taking anticoagulant therapy. This information should be included in the examination plan.

As in our case, patients in previous reports did not experience bleeding other than the mediastinal hemorrhage. The source of bleeding and the reason why the hemorrhage was limited to the mediastinum are unclear. The postulated mechanism for a spontaneous mediastinal hematoma involves the rupture of small atherosclerotic vessels in the mediastinum after a specific trigger such as coughing or sneezing. In addition to the hemorrhagic diathesis that occurs as a result of anticoagulant therapy, the growth of capillary blood vessels and vascular fragility secondary to chronic inflammation and pulmonary hypertension caused by COPD may have contributed to the bleeding in our case.

Because acute arterial bleeding is uncommon, and most cases remain hemodynamically stable, conservative management, including the discontinuation of anticoagulant therapy is generally employed for spontaneous mediastinal hematomas. All reported

patients underwent conservative therapy, except one patient in whom a mediastinal tumor was suspected and exploratory surgery of the mediastinum was performed [11]. The prompt initiation of conservative therapy is crucial to avoid surgical intervention. In cases with mediastinal organs compressed by hematoma, subsequent exacerbation of respiratory and hemodynamic status, and worsening symptoms despite conservative therapy, surgical intervention is necessary. Since there is usually no active bleeding, and it is assumed that it takes time for the hematoma to enlarge, most parts of the hematoma are coagulated, incision of only the mediastinal pleura may be insufficient to release the compression.

#### 4. Conclusions

A spontaneous mediastinal hematoma is rare but can occur in patients who are administered anticoagulants, regardless of the therapeutic level of anticoagulation. Although conservative therapy is typically employed in cases that are diagnosed early, surgical intervention is necessary in cases in which the hematoma is symptomatic or conservative therapy is ineffective. To facilitate prompt and proper management, clinicians should be aware of this condition as a potential complication of anticoagulant therapy.

This is the first thorough review of cases of mediastinal hematomas associated with anticoagulant therapy and the first case report to describe its intraoperative findings and perioperative course. This report may provide useful information for the optimal management and surgical procedure of this rare complication.

#### Conflicts of interest

The authors have no conflicts of interest to disclose.

#### Funding

There are no sources of funding for this research.

#### Ethical approval

It is retrospective case report and no ethical approval was required.

#### Consent

Written informed consent was obtained from the patient for publication of this case report and accompanying images. Any patients' and volunteers' names, initials, or hospital numbers are not used in this manuscript.

### Authors' contributions

MM conducted a literature search and drafted the manuscript. MM, DS and KS performed the operation. All authors contributed during the patient management and participated in the design of the case report and coordination and helped draft the manuscript. All authors read and approved the final manuscript.

### Guarantor

Masashi Mikubo and Yukitoshi Satoh are guarantors.

### References

- [1] K.P. Suddes, R.D. Thomas, Mediastinal haemorrhage: a complication of thrombolytic treatment, *Br. Med. J.* 297 (1988) 527.
- [2] H. Abe, S. Funaki, K. Chiba, Y. Kitanaka, H. Makuuchi, Traumatic rupture of the false lumen in a patient with preexisting chronic dissection of the descending thoracic aorta, *Gen. Thorac. Cardiovasc. Surg.* 59 (2011) 559–562.
- [3] R.A. Agha, A.J. Fowler, A. Saeta, I. Barai, S. Rajmohan, D.P. Orgill, SCARE group: the SCARE statement: consensus-based surgical case report guidelines, *Int. J. Surg.* 34 (2016) 180–186.
- [4] S. Tanaka, K. Ueda, M. Hayashi, N. Tanaka, K. Hamano, Minimally invasive treatment for spontaneous mediastinal hematoma, *Surgery* 145 (2009) 248–249.
- [5] C.J. McDonald, L.M. Kalish Ellett, J.D. Barratt, et al., An international comparison of spontaneous adverse event reports and potentially inappropriate medicine use associated with dabigatran, *Pharmacoevid. Drug Saf.* 24 (2015) 399–405.
- [6] J.M. Packer, Radiologic seminar CXXI: hemomediastinum associated with anticoagulant therapy, *J. Miss. State Med. Assoc.* 13 (1972) 434–435.
- [7] F. Turez, H. Steinberg, A. Kahn, Spontaneous anterior mediastinal hematoma: a complication of cardiac catheterization, *JAMA* 226 (1973) 427–431.
- [8] M. Abaskaron, G. Peterson, T.Y. Huang, Anterior mediastinal hematoma and left haemothorax on well-controlled oral anticoagulant therapy, *Postgrad. Med. J.* 59 (1983) 95–97.
- [9] S. Singh, M.J. Ptacin, V.S. Bamrah, Spontaneous mediastinal hemorrhage: a complication of intracoronary streptokinase infusion for coronary thrombosis, *Arch. Intern. Med.* 143 (1983) 562–563.
- [10] A. Mazziotti, M. Bangash, J.W. Maun, Spontaneous mediastinal hemorrhage secondary to oral anticoagulation, *Tex. Heart Inst. J.* 13 (1986) 333–336.
- [11] S.S. Lawler, R. Reeve, Mediastinal hemorrhage—diagnostic and therapeutic problems, *Hawaii Med. J.* 43 (1984) 152–154.
- [12] M. Kamiyoshihara, T. Ibe, S. Kakegawa, A. Takise, I. Takeyoshi, Spontaneous mediastinal hematoma presenting as a mass, *J. Thorac. Oncol.* 2 (2007) 544–545.
- [13] L.A. Jette, A.S. Niven, N. Nieves-Robbins, Spontaneous mediastinal haematoma: a rare complication of warfarin therapy, *BMJ Case Rep.* 10 (2011) 1136.

### Open Access

This article is published Open Access at [sciedirect.com](http://sciedirect.com). It is distributed under the [IJSCR Supplemental terms and conditions](#), which permits unrestricted non commercial use, distribution, and reproduction in any medium, provided the original authors and source are credited.