

Comparison between digital and optical microscopy: Analysis in a mouse gut inflammation model

AIRTON PEREIRA E SILVA^{1,2}, SYLVIA MARIA NICOLAU CAMPOS¹,
ISABELLE MAZZA GUIMARÃES^{1,3} and GERLINDE AGATE PLATAIS BRASIL TEIXEIRA¹⁻³

¹Gastrointestinal Immunology Group, Department of Immunobiology, Institute of Biology,
Federal Fluminense University, Niterói, Rio de Janeiro 24020-150; ²Graduation Program in Pathology,
Medicine School, Antônio Pedro Hospital, Federal Fluminense University, Niterói, Rio de Janeiro 24033-900;
³Graduation Program in Science and Biotechnology, Federal Fluminense University, Niterói, Rio de Janeiro 24020-141, Brazil

Received May 5, 2017; Accepted June 28, 2017

DOI: 10.3892/br.2017.950

Abstract. Virtual microscopy is currently widely used for various purposes, such as teaching, archiving, collaborations and research. Although the cost of this technique has reduced, it continues to be expensive for the majority of laboratories in developing countries. The Graduate Program in Pathology at the Federal Fluminense University (Niterói, Brazil) has acquired equipment for virtual microscopy. However, this novel method faced prejudice, as students and technicians were skeptical about its reliability. Thus, the aim of the current study was to evaluate whether virtual microscopy is a reliable method of analysis for our research. Thus, a mouse gut inflammation model developed by our research group was used in the present study. Analysis was performed using optical microscopy and digital imaging using the APERIO scanning system and the ImageScope[®] software. Intestinal epithelial cells (IECs), intra epithelial leucocytes (IEL), and villi number and area were evaluated. No significant differences were observed in villi number, IEC and IEL; however, the villi area was significantly smaller when measured using the computer. Thus, the present study indicates that virtual microscopy is a trustworthy method for research purposes.

Introduction

The gold standard in pathology used to this day is slide analysis through optical microscopy, which was invented in the 17th century (1). Advancements in technology have enabled constant improvements in resolution and photography. The first electromagnetic lens was developed by Hans Busch in

the late 1920s (2), and similar to optical microscopy, it too experienced major developments as technology increased (3). Amongst the technological advancements of the mid 1980s, an important one was digital microscopy. However, it was not until the late 1990s (when personal computers finally became powerful enough to process and store the large quantities of information derived from glass slides) that digital microscopy became reliable to be used in medical practice and research worldwide (4-7).

With additional advancements, this technology became so trustworthy that scientific methods using informatics are now standard procedure (8). This is particularly true for contemporary trends, such as the construction of three-dimensional tissue models and *in vivo* imaging, for which optical microscopes were replaced by digital imaging (9,10). Scanners nowadays are able to create a digital image of the entire slide, which can then be viewed virtually on smartphones, tablets and laptops (11,12). The possibility of analyzing data on-the-go, or even on the other side of the planet, is a marked benefit of digital imaging and virtual microscopy (13). In this context, open-source software programs were developed featuring data availability, collaboration and providing more transparency in research, as researchers are able to assess the analysis of others more freely.

While the use of digital imaging has also contributed to the re-analysis of old biopsies, confirming or disproving diagnoses in clinical practice (9,14), digital imaging also benefits the teaching process (15). The image of a single scanned slide may be distributed to numerous students who may have access either in the same room or remotely. Thus, for teaching purposes, digital and virtual microscopy replace the box containing glass slides and the textbook images. Rather than having multiple boxes with similar tissue sections, virtual microscopy allows the creation of a more extensive library and the evaluation of numerous different cases. However, handling a microscope continues to be an important skill and this experience should be offered to students when possible (4,16).

One of the early important drawbacks of digital microscopy was the elevated cost of the equipment (17), limiting this method to larger research labs, particularly in underdeveloped countries. In recent years, however, the costs have rapidly reduced (11). A potential disadvantage of digital and virtual

Correspondence to: Dr Gerlinde Agate Platais Brasil Teixeira, Gastrointestinal Immunology Group, Department of Immunobiology, Institute of Biology, Federal Fluminense University, Barros Terra Avenue, Niterói, Rio de Janeiro 24020-150, Brazil
E-mail: gerlinde_teixeira@id.uff.br

Key words: virtual microscopy, optical microscopy, whole slide image, gut inflammation, mouse, digital

slides is the file size, which can be particularly large, thus requiring better and more expensive computers for optimal performance and transmission over the internet (4,5,11).

As prices have reduced in recent years and computers deal better with large size files, our graduate program (at the Federal Fluminense University, Niterói, Brazil) applied for and received a grant to purchase a slide scanner in 2014. Although this was a great achievement, the students and faculty were skeptical about its reliability when compared with traditional microscopy. This skepticism is also apparent in developed countries, although digital microscopy usage has been growing steadily in clinical practice (18). Thus, in the present study analysis of the duodenum of mice with normal and inflamed guts was compared when using traditional and digital microscopy.

Materials and methods

Tissue samples. A mouse model of gut inflammation developed by Teixeira *et al* (19) was used in the present study. Briefly, adult male C57BL/6 mice bred in the local animal facility of Federal Fluminense University (Rio de Janeiro, Brazil) were given free access to food and water. They were 2-months-old and weighed ~25 g at the beginning of the experiment. The animals were immunized subcutaneously twice (with a 21 day interval) with 100 µg specific protein with (primary) or without (booster) adjuvant, 1 mg aluminum hydroxide [Al(OH)₃]. Subsequent to immunization, the animals received a challenge diet containing only the allergenic protein for 30 days. They were maintained at the university's bioterium (temperature of 22°C, ~60% humidity and 12 h light/12 h dark cycle) and the number of animals per cage varied from 4-6. This study was approved by the Ethical Committee of the Federal Fluminense University (Niterói, Brazil).

Tissue preparation. The experiment was terminated after the challenge diet period, with an overdose of anesthetics, totaling 200 µl per animal (100 µl of xylazine + 100 µl of ketamine, concentrations at 60 mg/kg and 350 mg/kg, respectively, produced by Sespo Industries®, Paulinia, Sao Paulo, Brazil). After examining the peritoneal cavity, a 2 cm segment of the gastro-duodenum junction was collected for histopathology. These were fixed with 10% buffered formaldehyde, and stained for 5 min with hematoxylin and for 3 min with eosin at 23°C.

Tissue analyses. All microscopic analyses were performed using optical and digital microscopy. For optical microscopy (OM), an Olympus BX41 with magnifications of x480 (40X objective + 12X ocular) and x1,200 (100X objective + 12X ocular) was used. A reticle with a 100 µm ruler was placed in the eyepiece such that the image of the ruler was imposed onto the tissue sample. For the digital microscopy (DM), the slides were scanned using the APERIO ScanScope CS System® with a 20X objective lens. To evaluate the histological parameters, the ImageScope® software (v11.2.0.780; Leica Microsystems GmbH, Wetzlar, Germany) tools were used with a 7.2 digital zoom for cell counting. The evaluated parameters were as follows: Integrity of the intestinal structure, number of villi per field (OM) and per 4,000 µm tissue (DM); villi height, width and area; number of

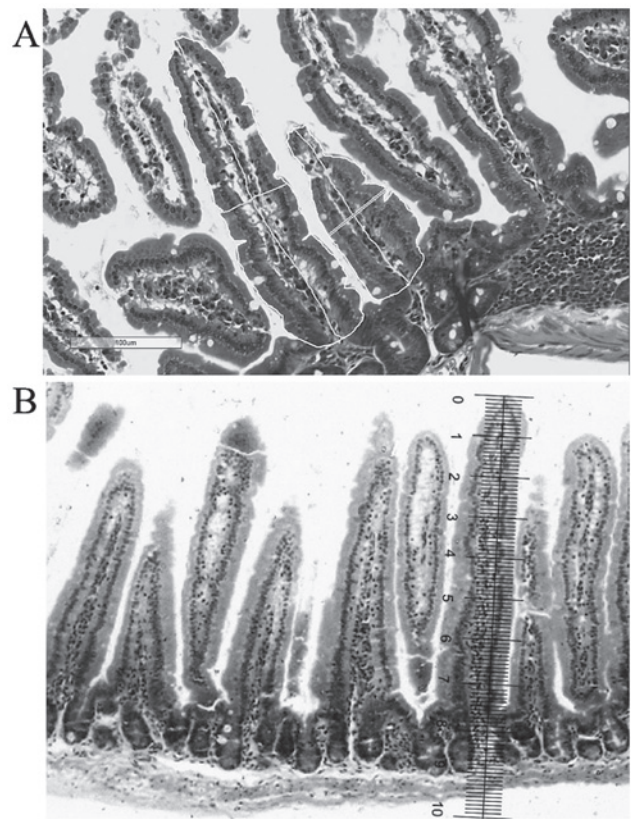


Figure 1. Images demonstrating examples of how the analysis of duodenum slides was performed in: (A) Digital microscopy (magnification x20), where each villus was framed using a trackpad, and the software calculated each villus area automatically. The authors used the same method to obtain the height and the width of each villus; and (B) optical microscopy (magnification x1,200), where a ruler was placed on the ocular lens, which was used to measure each villus height and width and therefore calculate the area of the villi. Both slides were stained with hematoxylin and eosin.

intestinal epithelial cells (IECs) and number of intraepithelial leukocytes (IELs). The software calculated the zoom and placed the ruler automatically.

Villi height, width and area. For OM analyses the height and width of all villi in the chosen field were measured. The width was measured approximately in the middle of the villus height. The villi area was obtained later by multiplying the height with the width of each villus.

For DM analyses the height and width of all villi in the 4,000 µm of chosen tissue were measured using a touch pen and a trackpad (Apple Inc., Cupertino, CA, USA). To calculate the area, the edge of each villus was traced using a touch pen and a trackpad (Fig. 1).

IEC and IEL counts. For OM, IEC and IEL counts were performed with a 100X immersion lens (magnification, x1,200), and immersion oil (1 ml; Newprov, Pinhais, Brazil) was placed on each slide. For DM, an iPhone 6 (Apple Inc.) application, Touch Counter® (v1.0; Nexbrain, Seoul, Korea) was used to count IECs and IELs (optical magnification of the scanner, 20x plus digital magnification in the software, 20x).

Statistical analysis. Data are expressed as means ± standard deviation. A two-way analysis of variance with Bonferroni

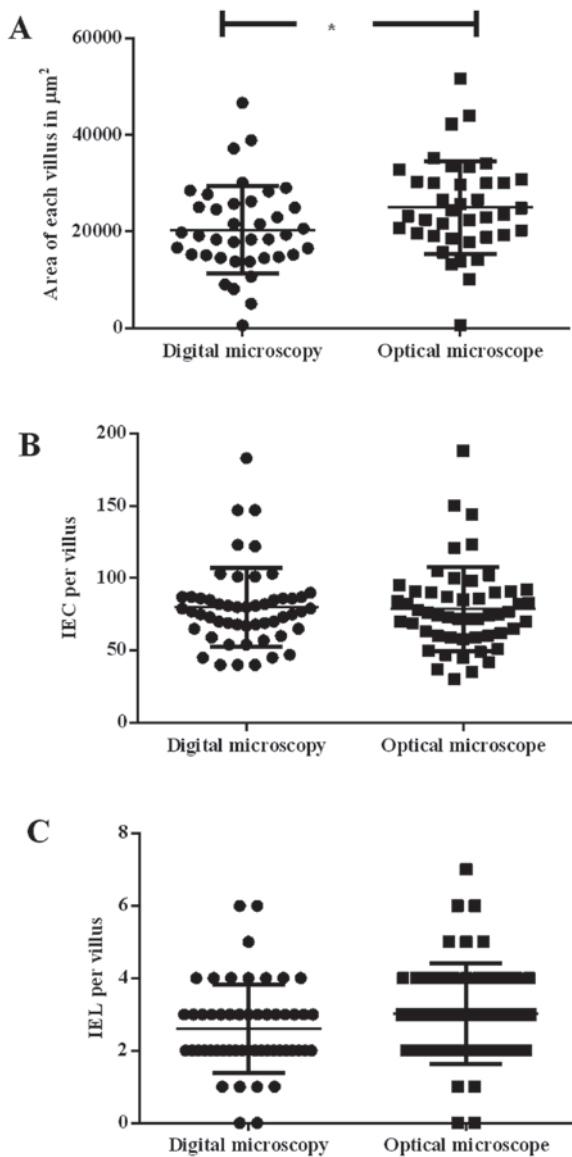


Figure 2. (A) Comparison between analysis of villi area using DM and OM. DM revealed a villi area significantly smaller than OM ($P < 0.05$). (B) Comparison between analysis of IECs per villus using DM and OM. (C) Comparison between analysis of IELs per villus using DM and OM. No statistically significant differences were observed in IEC and IEL counts ($P = 0.07$ and $P = 0.08$, respectively). DM, digital microscopy; OM, optical microscopy; IEC, intestinal epithelial cell; IEL, intra epithelial leucocytes.

post hoc test was used to determine the minimum significant difference using Graphpad Prism 6 Software (GraphPad Software, Inc., La Jolla, CA, USA). $P < 0.05$ was considered to indicate a statistically significant difference. All analyses were performed with a minimum of five animals per cage.

Results

Villi number. No significant differences were observed in villi number between either method of analysis (data not shown).

Villi area. It was observed that the measurements of villi area using DM ($20,391.87 \pm 9,064.49 \mu\text{m}^2$) were significantly smaller ($P < 0.05$) than those measured by OM ($24,996.54 \pm 9,620.67 \mu\text{m}^2$; Figs. 1A and 2A).

IECs and IELs. As shown in Fig. 2B and C, no significant differences were observed between the two methods, although counting using DM demonstrated a smaller deviation when compared with OM (DM, 79.90 ± 27.34 vs. OM, 78.71 ± 29.18) and (DM, 2.62 ± 1.22 vs. OM, 3.06 ± 1.32). Thus, no difference was observed for the ratio of IEC to IEL.

Discussion

The primary strategies used to diagnose a food allergy are evaluating clinical history and performing physical examination, whereas the definitive method is to submit the patient to an oral challenge with the suspected food and assess the allergic reactions at an organ level (20,21). For researchers, the state of the organs is particularly interesting to enable investigation of the pathological mechanisms of the disease and the development of novel treatment methods (21,22).

In the present study, we analyzed two methods of analysis (OM and DM) of the inflammatory status of the duodenum of mice submitted to a food allergy induction protocol was compared. Previous studies from our group reported the inflammatory milieu of the gut of allergic animals submitted to oral challenge, as well as the normal milieu of the gut of allergic animals that were not submitted to oral challenge (23,24). The analysis performed in these papers used either OM or DM; however, no comparison was performed. Historically, OM is considered to be the gold standard by many of the students and professors in the authors' department (Department of Immunobiology, Federal Fluminense University, Rio de Janeiro, Brazil) and in other universities in Brazil. Thus, all analyses were performed using this method. With the acquisition of a slide scanner by the Federal Fluminense University and the use of digital analysis software, a comparison between the two methods was considered to be mandatory. Thus, the present study reveals that digital imaging analysis a reliable method, and it a novel standard was established, as it is very accurate in determining the staging of the inflammatory state of the gut. As soon as slides have been digitalized, analyses may be performed wherever there is access to a good computer and/or internet. It is important to mention, however, that both methods (OM and DM) offer different perspectives to the user, therefore one is not better than the others. They are all complimentary to each other, allowing students and researchers to learn and discover novel methods of analysis.

The results described in the present study indicate that the two methods are largely equivalent, as the majority of the results were not statistically different. The most important disadvantages of OM are the lack of reproducibility due to operator bias (25,26) and the requirement of more than one high image quality microscope in the lab. However, Dee (5) identified numerous advantages of virtual microscopy over traditional microscopy, including accessibility, costs, and efficiency, amongst others.

The only result that demonstrated a statistically significant difference was the measurement of villi area, which may be explained by the operator bias involved in OM (14), as stated by Fisher and Parsons (27) when he compared his study to that of others (28). Another reason is that villi do not have regular borders, thus the fact that the villi (including the indents) are delimited with the pen explains the observed difference and

deviation. However, the small differences between the methods of analysis did not impact upon the diagnosis of gut inflammation when compared with the inflammatory status of the gut, which was established using the inflammation score developed by Marsh (29) and modified later by Oberhuber *et al* (30,31).

In conclusion, in our mouse model the usage of either method of intestine analysis did not differ significantly from each other, thus showing that digital imaging is a trustworthy method for study purposes.

Acknowledgements

The authors would like to thank Professor Maira Platais for the English review and the grant provided by FAPERJ (Fundação Carlos Chagas Filho de Amparo à Pesquisa do Estado do Rio de Janeiro - 'Carlos Chagas Filho Foundation for Supporting of Research of the State of Rio de Janeiro') (grant no. E-26/110/409/2011) and the doctorate fellowship provided by CNPq (Conselho Nacional de Desenvolvimento Científico e Tecnológico - 'National Council for Scientific and Technological Development').

References

- Boyce BF: Whole slide imaging: Uses and limitations for surgical pathology and teaching. *Biotech Histochem* 90: 321-330, 2015.
- Bogner A, Jouneau PH, Thollet G, Basset D and Gauthier C: A history of scanning electron microscopy developments: Towards 'wet-STEM' imaging. *Micron* 38: 390-401, 2007.
- Hawkes PW: The correction of electron lens aberrations. *Ultramicroscopy* 156: A1-A64, 2015.
- Banavar SR, Chippagiri P, Pandurangappa R, Annavaajjula S and Rajashekaraiyah PB: Image montage for creating a virtual pathology slide: An innovative and economical tool to obtain a whole slide image. *Anal Cell Pathol (Amst)* 2016: 9084909, 2016.
- Dee FR: Virtual microscopy in pathology education. *Hum Pathol* 40: 1112-1121, 2009.
- Silage DA and Gil J: Digital image tiles: A method for the processing of large sections. *J Microsc* 138: 221-227, 1985.
- Westerkamp D and Gahm T: Non-distorted assemblage of the digital images of adjacent fields in histological sections. *Anal Cell Pathol* 5: 235-247, 1993.
- Furness PN: The use of digital images in pathology. *J Pathol* 183: 253-263, 1997.
- Arena ET, Rueden CT, Hiner MC, Wang S, Yuan M and Eliceiri KW: Quantitating the cell: Turning images into numbers with ImageJ. *Wiley Interdiscip Rev Dev Biol*, 2016.
- Entenberg D, Rodriguez-Tirado C, Kato Y, Kitamura T, Pollard JW and Condeelis J: In vivo subcellular resolution optical imaging in the lung reveals early metastatic proliferation and motility. *Intravital* 4: 1-11, 2015.
- Indu M, Rathy R and Binu MP: 'Slide less pathology': Fairy tale or reality? *J Oral Maxillofac Pathol* 20: 284-288, 2016.
- Pantanowitz L, Valenstein PN, Evans AJ, Kaplan KJ, Pfeifer JD, Wilbur DC, Collins LC and Colgan TJ: Review of the current state of whole slide imaging in pathology. *J Pathol Inform* 2: 36, 2011.
- García-Rojo M, Sánchez J, de la Santa E, Durán E, Ruiz JL, Silva A, Rubio FJ, Rodríguez AM, Meléndez B, González L, *et al*: Automated image analysis in the study of lymphocyte subpopulation in eosinophilic oesophagitis. *Diagn Pathol* 9: S7, 2014.
- Higgins C: Applications and challenges of digital pathology and whole slide imaging. *Biotech Histochem* 90: 341-347, 2015.
- Rocha R, Vassallo J, Soares F, Miller K and Gobbi H: Digital slides: Present status of a tool for consultation, teaching, and quality control in pathology. *Pathol Res Pract* 205: 735-741, 2009.
- Hamilton PW, Wang Y and McCullough SJ: Virtual microscopy and digital pathology in training and education. *APMIS* 120: 305-315, 2012.
- Camparo P, Egevad L, Algaba F, Berney DM, Boccon-Gibod L, Compérat E, Evans AJ, Grobholz R, Kristiansen G, Langner C, *et al*: Utility of whole slide imaging and virtual microscopy in prostate pathology. *APMIS* 120: 298-304, 2012.
- Lundström C, Thorstenson S, Waltersson M, Persson A and Treanor D: Summary of 2(nd) Nordic symposium on digital pathology. *J Pathol Inform* 6: 5, 2015.
- Teixeira G, Paschoal PO, de Oliveira VL, Pedruzzi MM, Campos SM, Andrade L and Nóbrega A: Diet selection in immunologically manipulated mice. *Immunobiology* 213: 1-12, 2008.
- Yu W, Freeland DMH and Nadeau KC: Food allergy: Immune mechanisms, diagnosis and immunotherapy. *Nat Rev Immunol* 16: 751-765, 2016.
- Dogan S, Astvatsatourov A, Deserno TM, Bock F, Shah-Hosseini K, Michels A and Mösges R: Objectifying the conjunctival provocation test: Photography-based rating and digital analysis. *Int Arch Allergy Immunol* 163: 59-68, 2014.
- Bachert C, Borchard U, Wedi B, Klimek L, Rasp G, Riechelmann H, Schultze-Werninghaus G, Wahn U and Ring J: Allergic rhinoconjunctivitis. Guidelines of the DGAJ in association with the DDG. *J Dtsch Dermatol Ges* 4: 264-275, 2006 (In German).
- Campos SM, de Oliveira VL, Lessa L, Vita M, Conceição M, Andrade LA and Teixeira GA: Maternal immunomodulation of the offspring's immunological system. *Immunobiology* 219: 813-821, 2014.
- Paschoal PO, Campos SM, Pedruzzi MM, Garrido V, Bisso M, Antunes DM, Nobrega AF and Teixeira G: Food allergy/hypersensitivity: Antigenicity or timing? *Immunobiology* 214: 269-278, 2009.
- Casuccio GS, Janocko PB, Lee RJ, Kelly JF, Dattner SL and Mgebroff JS: The use of computer controlled scanning electron microscopy in environmental studies. *J Air Pollut Control Assoc* 33: 937-943, 1983.
- Apotheker H and Jako GJ: A microscope for use in dentistry. *J Microsurg* 3: 7-10, 1981.
- Fisher RB and Parsons DS: The gradient of mucosal surface area in the small intestine of the rat. *J Anat* 84: 272-282, 1950.
- Wood HO: The surface area of the intestinal mucosa in the rat and in the cat. *J Anat* 78: 103-105, 1944.
- Marsh MN: *Intestinal Manifestations of food hypersensitivity*. Vol 34. Raven Press, New York, NY, 1995.
- Oberhuber G, Granditsch G and Vogelsang H: The histopathology of coeliac disease: Time for a standardized report scheme for pathologists. *Eur J Gastroenterol Hepatol* 11: 1185-1194, 1999.
- Dickson BC, Streutker CJ and Chetty R: Coeliac disease: An update for pathologists. *J Clin Pathol* 59: 1008-1016, 2006.