

# Dengue Haemorrhagic Encephalitis: Rare Case Report with Review of Literature

ADITYA SINGH KUTIYAL<sup>1</sup>, CHETANYA MALIK<sup>2</sup>, GITIKA HYANKI<sup>3</sup>

## ABSTRACT

Dengue is an endemic arboviral infection prevalent especially in tropical countries including Southern and Southeast Asia. Central Nervous System (CNS) involvement in dengue infection is uncommon. Haemorrhagic encephalitis is a rare presentation in dengue. This is a case of a 58-year-old male who presented with fever, petechial rash and altered sensorium. Dengue serology IgM was reactive and MRI brain was suggestive of haemorrhagic encephalitis. Patient was managed in Intensive Care Unit (ICU) but eventually succumbed to his illness. We report this fatal outcome of a common viral infection with unusual neurological presentation to propose an association between dengue and neurotropism and the need to look at dengue infection beyond its classical features.

## CASE REPORT

A 58-year-old male presented to the casualty department with complaint of fever since five days with severe arthralgia, petechial rashes on all four limbs and trunk since three days and was brought in view of sudden loss of consciousness two hours back. There was no event of seizures or trauma, patient was a non-smoker and non-alcoholic and was a farmer by occupation. Patient had unremarkable medical history so far with no systemic illness and hospitalization till the current presentation. On examination patient was afebrile, unconscious with blood pressure of 120/68 mm Hg and pulse rate of 98 per minute. Neurological examination revealed no meningeal signs, bilateral planter response was extensor, petechial rashes were seen on all four limbs, more being on the lower limbs. Patient was investigated with various investigations and the following were the findings: Haemoglobin (Hb): 15.5 g/dl, Total Leucocyte Count (TLC): 2700 cells/cumm<sup>3</sup> and platelet count: 85000 cells/cumm<sup>3</sup>, haematocrit: 50. Patient had been investigated five days back when he was still febrile and the documented Hb was 16.2 g/dl, TLC 3200 cells/cumm<sup>3</sup> platelet count 18000 cells/cumm<sup>3</sup>. Renal and hepatic parameters of the patient were within normal range. Cerebro-Spinal Fluid (CSF) analysis revealed proteins 170 mg/dl, glucose 88 mg/dl, total number of cells 35 cells/ml with 90% lymphocytes, CSF Polymerase Chain Reaction (PCR) for Herpes Simplex Virus (HSV) 1 and 2 and for Japanese encephalitis (anti-JEV IgM antibody) was negative. CSF analysis for cryptococcal antigen was non reactive. HSV I and II-non reactive, Human Immunodeficiency Virus (HIV) I and II-non reactive, malaria antigen for vivax and falciparum-negative, HBsAg-non reactive. Anti-HCV-non reactive. Chikungunya IgM serology-non-reactive. Dengue serology IgM/IgG-reactive.

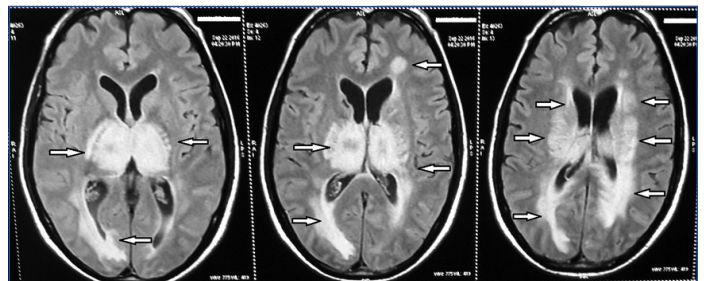
Patient was started on intensive management with broad spectrum antibiotics, decongestants and platelet transfusions with a goal of maintaining adequate hydration and urine output. MRI brain further revealed bilateral symmetrical diffuse confluent white matter hyper-intensity in both cerebral hemispheres in supra and deep periventricular white matter, bilateral thalami, posterior limb of internal capsule, brainstem and cerebellar hemispheres with patchy and punctate foci of restricted diffusion in aforesaid abnormal signal areas with further blooming on Gradient Echo (GRE) sequences including bilateral thalami. Findings were suggestive of haemorrhagic encephalitis [Table/Fig-1-3]. With extensive investigative workup patient was now diagnosed as a rare case of dengue haemorrhagic

**Keywords:** Arboviral infection, Fever, Neurotropic

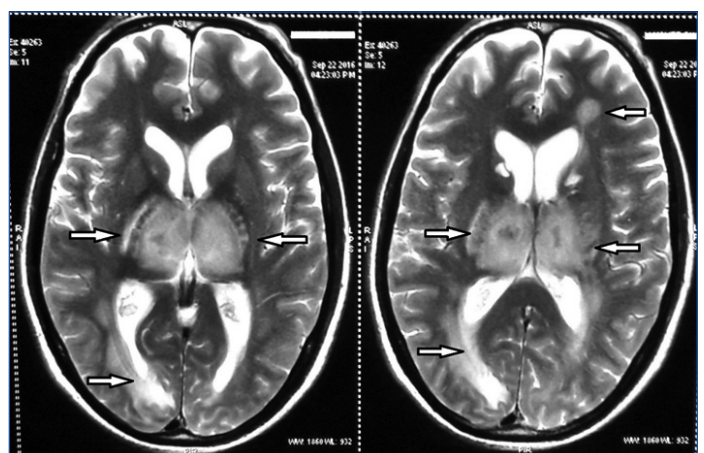
encephalitis. Patient's general condition deteriorated though there was improving trend in platelet count and there was no fresh bleeding manifestation and eventually patient succumbed to his illness on 10<sup>th</sup> day of admission.

## DISCUSSION

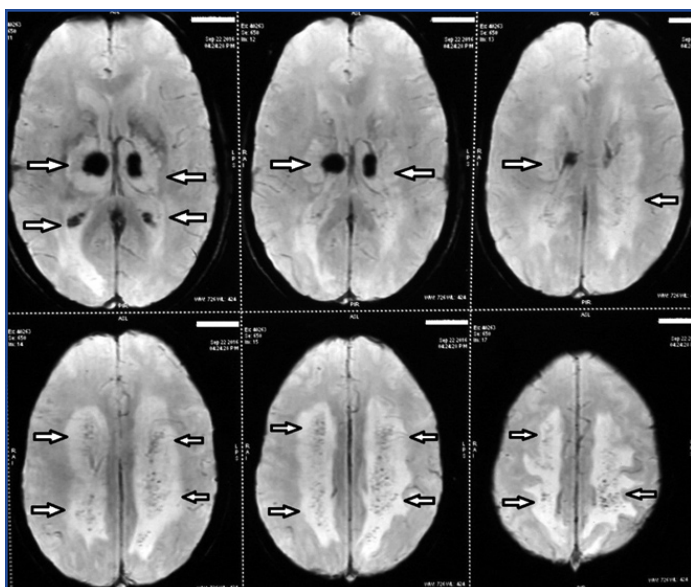
World Health Organization (WHO) report shows that global incidence of dengue infection is on rise with incidence in abundance from latitudes 35°N to 35°S. Incidence of dengue cases is 50 to 100 million infections worldwide every year. Dengue is a single-stranded RNA virus of the flavivirus genus transmitted by *Aedes aegypti* and



**[Table/Fig-1]:** MRI brain FLAIR sequence showing hyperintense lesions in bilateral ganglio-thalamic complex, periventricular and peritrigonal white matter. (MRI- Magnetic Resonance Imaging, FLAIR- Fluid-attenuated inversion recovery).



**[Table/Fig-2]:** MRI brain T2 weighted image sequence showing hyperintense lesions in bilateral ganglio-thalamic complex, periventricular and peritrigonal white matter. (MRI- Magnetic Resonance Imaging)



**[Table/Fig-3]:** MRI brain images showing multiple scattered foci of blooming on SWI sequence suggestive of bleed.  
(MRI- Magnetic Resonance Imaging, SWI - Susceptibility Weighted Imaging).

*Aedes albopictus* and is mainly prevalent in tropical regions. There are four viral serotypes, named DEN-1 to DEN-4 [1]. Dengue was earlier classified as classical dengue fever, dengue haemorrhagic fever and dengue shock syndrome and in 2009 WHO recognized two main clinical presentations of dengue and classified them as dengue fever with or without warning signs and severe dengue. Neurological manifestation in dengue is a rare phenomenon but incidence of unusual presentations and complications in this common viral infection is being observed on the rise [1]. DENV-2 and 3 are mainly associated with neurological complications [2]. Dengue is a common and endemic infection which usually presents with fever, retro-orbital pain, headache, arthralgia, myalgia, rashes and haemorrhagic complications. Though, dengue is classically known as a non-neurotropic virus, Sanguansermsri T et al., in 1976 had first noted correlation between dengue and CNS complication in a patient with encephalitis [3].

Murthy JMK classified neurological manifestations in dengue infection into three categories: 1) CNS complications resulting from direct neurotropic effect like meningitis, encephalitis and myelitis; 2) CNS manifestations from systemic and metabolic complications like encephalopathy, hypokalemic paralysis, stroke and 3) Post viral infection CNS complications like encephalomyelitis, optic neuritis and Guillain Barre Syndrome [4]. Encephalitis is a rare presentation of dengue infection. Its main symptoms are altered sensorium, headache, seizures and less than half of the affected patients present with the classical dengue infection symptomatology [5].

Neuropathogenesis of dengue virus infection is still under study and is poorly understood at present with direct viral infection of CNS, haemorrhagic and metabolic disturbance and autoimmune reaction being put forth as possible mechanisms in the pathogenesis [6]. Intracranial haemorrhage has been associated with endothelial damage and thrombocytopenia with increased vascular permeability resulting in capillary fluid leakage [7].

There are multiple investigations available for diagnosis of dengue infection based on detection of IgG and IgM antibodies, Non-Structural 1 (NS1) antigen, viral RNA in serum and CSF. The antibody detection of IgM using Enzyme Linked Immunosorbent Assay (ELISA) is the most widely used technique. It has high sensitivity of 92% and high specificity of 99% [8]. Detection of NS1 viral antigen is another widely used diagnostic test for its early detection. It has 52% sensitivity and 90% specificity in serum and 66% sensitivity and 100% specificity in plasma. Nucleic Acid Test (NAT) such as Reverse Transcriptase-Polymerase Chain Reaction (RT-PCR) is also used for detection of

genetic material with a sensitivity of 93%-100% depending on the serotype of the dengue virus when the test is done during the period of viremia. NAT test can be positive even before IgM and IgG become detectable. Dengue IgM detection in CSF has high specificity of 97%-100% but has low sensitivity [9]. But the gold standard for the diagnosis of dengue virus infection is the cell culture virus isolation followed by fluorescent antibody detection though it is not used in routine clinical practice.

In 2013 Carod-Artal FJ et al., gave a diagnostic criteria for dengue encephalitis proposed by the diagnostic criteria included: 1) CNS involvement with; 2) detection of dengue virus RNA, IgM or NS1 antigen in CSF; 3) CSF pleocytosis without other neuroinvasive pathogens [10]. But as the detection of IgM antibodies had high specificity but low sensitivity a new updated diagnostic criteria for dengue encephalitis was later suggested by Cristiane S and Marzia PS which was widely accepted. They proposed four point definition criteria for dengue encephalitis as : 1) Presence of fever; 2) CNS complications like altered sensorium, seizures or any focal neurological signs; 3) Reactive IgM antibody, NS1 antigen, dengue virus RNA detection in serum and or CSF; 4) Exclusion of other causes of encephalitis [11].

Incidence of CNS manifestation in a study in Southern Vietnam was 4.2% [5] and in a study in Jamaica the incidence was 13.5% [12]. The Jamaican study had divided incidence of meningitis (34%), seizures (11%), others (4%).

MRI findings in dengue encephalitis vary but in majority cases haemorrhages, focal abnormalities, oedema can be seen in hippocampus, basal ganglia and thalamic region. In few cases extensive lesions in mid brain, cerebellum and temporal region has also been seen [13]. Many studies suggest encephalitis in dengue as a benign condition while Misra UK et al., concluded encephalitis as a complicated condition with difficult recovery with significant mortality and morbidity [13,14].

Recently there has been no data reporting dengue encephalitis in adult with a fatal outcome from India. Therefore, we would like to report this case of dengue haemorrhagic encephalitis who eventually met mortality as a rare case who had not presented with classical dengue features and fulfilled the diagnostic definition of dengue encephalitis given by Cristiane S and Marzia PS with a rare CNS complication [11].

## CONCLUSION

Dengue infection should be kept as a possible aetiology in all patients of encephalitis even in absence of classical clinical features of dengue, especially in endemic zones and more so during the season of dengue outbreak. High level of suspicion can lead to rightful early diagnosis and prompt timely management leading to a significant improvement in mortality and morbidity in cases of neurological complications in dengue.

## REFERENCES

- [1] New Edition. Geneva, Switzerland: World Health Organisation; 2009. World Health Organization. Dengue: Guidelines for Diagnosis, Treatment, Prevention and Control.
- [2] Domingues RB, Kuster GW, Onuki-Castro FL, Souza VA, Levi JE, Pannuti CS. Involvement of the central nervous system in patients with dengue virus infection. *J NeuroSci*. 2008;267:36-40.
- [3] Sanguansermsri T, Poneprasert B, Phomphutkul B, Kulapongs P, Tantachamrun T. Acute encephalopathy associated with dengue infection. *Bangkok: Seameo Tropmed*. 1976:10-11.
- [4] Murthy JMK. Neurological complications of dengue infection. *Neurol India*. 2010; 58:581-84.
- [5] Solomon T, Dung NM, Vaughn DW, Kneen R, Thao LT, Raengsakulrach B, et al. Neurological manifestations of dengue infection. *Lancet*. 2000;355:1053-59.
- [6] Puccioni-Sohler M, Orsini M, Soares CN. Dengue: a new challenge for neurology. *Neurol Int*. 2012;4:65-70.
- [7] Yamamoto Y, Takasaki T, Yamada K, Kimura M, Washizaki K, Yoshikawa K, et al. Acute disseminated encephalomyelitis following dengue fever. *J Infect Chemother*. 2002;8:175-77.

- [8] Hu D, Di B, Ding X, Wang Y, Chen Y, Pan Y, et al. Kinetics of non-structural protein 1, IgM and IgG antibodies in dengue type 1 primary infection. *Virology* 2011;8:47.
- [9] Guzmán MG, Kourí G. Dengue diagnosis, advances and challenges. *Int J Infect Dis*. 2004;8:69-80.
- [10] Carod-Artal FJ, Wichmann O, Farrar J, Gascón J. Neurological complications of dengue virus infection. *Lancet Neurol*. 2013;12:906-19.
- [11] Cristiane S, Marzia PS. Diagnosis criteria of dengue encephalitis. *Arq Neuropsiquiatr*. 2014;72:263.
- [12] Jackson ST, Mullings A, Bennett F, Khan C, Gordon-Strachan G, Rhoden T. Dengue infection in patients presenting with neurological manifestations in a dengue endemic population. *West Indian Med J*. 2008;57:373-76.
- [13] Misra UK, Kalita J, Syam UK, Dhole TN. Neurological manifestations of dengue virus infection. *J Neurol Sci*. 2006;244:117-22.
- [14] Wiwanitkit V. Magnitude and pattern of neurological pathology in fatal dengue haemorrhagic fever: A summary of Thai cases. *Neuropathology*. 2005;25:398.

**PARTICULARS OF CONTRIBUTORS:**

1. Senior Resident, Department of Internal Medicine, Maulana Azad Medical College and Lok Nayak Hospital, New Delhi, India.
2. Senior Resident, Department of Internal Medicine, Maulana Azad Medical College and Lok Nayak Hospital, New Delhi, India.
3. Postgraduate Resident, Department of Pathology, Government Medical College, Haldwani, Uttarakhand, India.

**NAME, ADDRESS, E-MAIL ID OF THE CORRESPONDING AUTHOR:**

Dr. Aditya Singh Kutiyal,  
33, Binsar Apts., A.K. 4, Indrapuram-201010, Uttar Pradesh, India.  
E-mail: kutiyaladitya@gmail.com

Date of Submission: **Mar 28, 2017**Date of Peer Review: **Apr 28, 2017**Date of Acceptance: **May 24, 2017**Date of Publishing: **Jul 01, 2017****FINANCIAL OR OTHER COMPETING INTERESTS:** None.