

Early T-Cell Precursor Acute Lymphoblastic Leukaemia/Lymphoma: Immunohistochemical Evaluation of Four Lymph Node Biopsies

DIVYA SHELLY¹, SUMEET GUJRAL²**Keywords:** Cluster of differentiation 7, Immunophenotyping, Myeloid antigens

Dear Sir,

Early T-cell Precursor Acute Lymphoblastic Leukaemia/Lymphoma (ETP-ALL/LBL) is a recently described, rare, high risk subtype of T-cell Acute Lymphoblastic Leukaemia/Lymphoma (T-ALL/LBL), which is characterized by distinctive immunophenotype of CD1a negativity, CD8 negativity and CD5 weak positivity with stem cell or myeloid marker expression [1-3]. This entity is routinely diagnosed based on Flow Cytometric Immunophenotyping (FCI) of blasts in an extramedullary mass, peripheral blood and/or bone marrow. However, there is paucity of data in the literature regarding immunohistochemical profile of ETP-ALL/LBL, especially in the setting of extramedullary presentation. In this report, we describe three patients diagnosed as ETP-LBL on nodal biopsies, who were later confirmed to have bone marrow involvement. It is important to distinguish ETP-ALL/LBL from T-ALL/LBL, as the prognostic and therapeutic implications differ [3].

Four adult patients were included (two males and two females), with a median age of 24 years (range, 20-39 years). The sites of biopsy included cervical nodes (n=2), submandibular node (n=1), and supraclavicular node (n=1). The salient laboratory features at the time of diagnosis are summarized in [Table/Fig-1]. Histological examination revealed features of a blastic haematolymphoid neoplasm in all the four cases.

The immunoprofile of all cases has been presented in [Table/Fig-2,3]. One case expressed Anti-Myeloperoxidase (AMPO) on Immunohistochemistry (IHC) (Case 2) and thus was labeled as Mixed Phenotypic Acute Leukaemia (MPAL). All the four cases underwent staging bone marrow studies and FCI. All the cases were labeled as ETP-ALL on FCI (including the case labelled as

MPAL on node biopsy). However, on the review of node biopsy, bone marrow biopsy, and FCI, the final diagnosis rendered in case 2 was MPAL.

Biologically, ETP-ALL corresponds to an early stage of T-cell development, characterized by an absence of expression of many of T-cell associated antigen, whereas the ability to express stem cell and myeloid antigens is retained. Owing to the primitive and multipotent nature of ETP, these cases show poor response to standard chemotherapy protocols and thus it is important to identify this subtype, which constitutes 12%-14% of all T-ALL cases [3,4]. Our study recognized that the immunoprofile of ETP-ALL/LBL at extramedullary site is same as bone marrow. We found that CD3, which is considered as a lineage-specific pan T-cell marker, can be focal or weak in cases of ETP-ALL/LBL on IHC. Here lies the importance of CD7, which was found to be the most robust and strongly expressed marker in all the cases, irrespective of the weak/focal CD3 expression. Thus, CD7 becomes an extremely important stain in diagnosing such entities in extramedullary sites along with a panel including CD1a, CD4, CD8, CD5, c-kit, AMPO, and CD34.

One of our cases, which was diagnosed as ETP-ALL on FCI {AMPO negative (Beckman Coulter, clone; CLB-MPO-1)} showed strong AMPO positivity on immunohistochemistry (Dako; Polyclonal Rabbit Anti-Human Myeloperoxidase, dil:1:1500) and was relabelled as MPAL. One case was Terminal Deoxynucleotidyl Transferase (TdT) negative, a synchrony with data published by Zhou Y et al., where they found a higher association of TdT negative cases with ETP immunophenotype [5].

Thus, a comprehensive immunohistochemical panel is essential to diagnose ETP-ALL/LBL, especially in cases showing weak or

Case No.	Age/Sex	Tumour site	Hb (g/dl)	WBC count (x10 ⁹ /L)	Platelet count (x10 ⁹ /L)	LDH (U/l)	Blasts reported on peripheral blood smear (%)	Blasts reported on marrow (%)
1.	20/M	Cervical node	12.8	3.9	393	184	1	29
2.	24/F	Submandibular node	7.8	23	180	1770	6	49
3#.	39/M	Supraclavicular node	9.9	0.84	4	225	0 (Few mature lymphocytes only)	8
4.	25/F	Cervical node	9	19	140	429	8	36

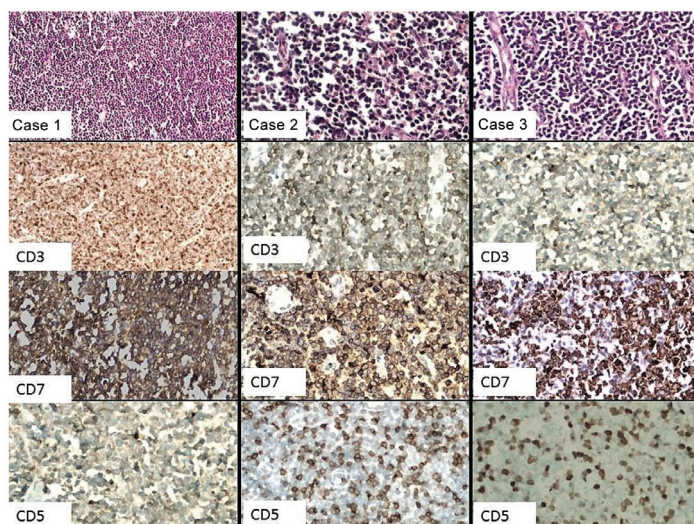
[Table/Fig-1]: Laboratory findings in patients at the time of diagnosis.

This patient was a referral case and was diagnosed as peripheral T-cell lymphoma elsewhere and was treated with 1 cycle of chemotherapy.

Case No.	CD3	TdT	CD34	c-kit	CD1a	CD2	CD5	CD7	CD4	CD8	CD20	AMPO	Ki-67 (%)
1.	++	++	+	-	-	+	+	++	-	-	-	-	70-80
2.	++	-	+	-	-	+	+	++	-	-	-	++	70-80
3.	+	++	+	-	-	++	+	++	-	-	-	-	50-60
4.	+	+	+	-	-	-	+	++	-	-	-	-	60-70

[Table/Fig-2]: Immunoprofile of the cases.

IHC: ++ (strongly positive), + (weak/focal positive), - (negative)



[Table/Fig-3]: Haematoxylin and eosin (H&E) and immunohistochemical analysis of three cases of Early T-cell precursor acute lymphoblastic leukaemia/lymphoma (ETP-ALL/LBL). First-panel showing variable expression of CD3 (from diffuse to focal), however; CD7 is strongly expressed in all the cases (second panel). CD5 staining was focal to negative in all cases (third panel; Normal T-cells served as internal control, original magnification, 40X).

negative staining for CD3 on IHC in biopsy samples. Under such circumstances, the additional panel including all T-cell markers is desirable. However, we recommend that in resource constrained countries like India at least CD7, CD8, CD1a, and AMPO should be included in the panel to identify ETP-ALL/LBL.

REFERENCES

- [1] Zhang J, Ding L, Holmfeldt L, Wu G, Heatley SL, Payne-Turner D, et al. The genetic basis of early T-cell precursor acute lymphoblastic leukaemia. *Nature*. 2012;481:157–63.
- [2] Coustan-Smith E, Mullighan CG, Onciu M, Behm FG, Raimondi SC, Pei D, et al. Early T-cell precursor leukaemia: a subtype of very high-risk acute lymphoblastic leukaemia identified in two independent cohorts. *Lancet Oncol*. 2009;10:147–56.
- [3] Jain N, Lamb AV, O'Brien S, Ravandi F, Konopleva M, Jabbour E, et al. Early T-cell precursor acute lymphoblastic leukaemia/lymphoma (ETP-ALL/LBL) in adolescents and adults: a high-risk subtype. *Blood*. 2016;127(15):1863–69.
- [4] Patel JL, Smith LM, Anderson J, Abromowitch M, Campana D, Jacobsen J, et al. The immunophenotype of T-lymphoblastic lymphoma in children and adolescents: a Children's Oncology Group report. *Br J Haematol*. 2012;159:454–61.
- [5] Zhou Y, Fan X, Routbort M, Cameron Yin C, Singh R, Bueso-Ramos C, et al. Absence of terminal deoxynucleotidyl transferase expression identifies a subset of high-risk adult T-lymphoblastic leukaemia/lymphoma. *Mod Pathol*. 2013;26:1338–45.

PARTICULARS OF CONTRIBUTORS:

1. Assistant Professor, Department of Pathology, Armed Forces Medical College, Pune, Maharashtra, India.
2. Professor, Department of Pathology and Hematopathology, Tata Memorial Hospital, Mumbai, Maharashtra, India.

NAME, ADDRESS, E-MAIL ID OF THE CORRESPONDING AUTHOR:

Dr. Divya Shelly,
Assistant Professor, Department of Pathology, Armed Forces Medical College, Solapur Road,
Pune-411040, Maharashtra, India.
E-mail: dshelly13@gmail.com

FINANCIAL OR OTHER COMPETING INTERESTS: None.

Date of Submission: **Apr 17, 2017**
Date of Peer Review: **May 04, 2017**
Date of Acceptance: **May 30, 2017**
Date of Publishing: **Jul 01, 2017**