

The Predictable Factors of the Postoperative Kyphotic Change of Sagittal Alignment of the Cervical Spine after the Laminoplasty

Jun Seok Lee, M.D.,^{1,2,3} Dong Wuk Son, M.D., Ph.D.,^{1,2,3} Su Hun Lee, M.D.,^{1,2,3} Dong Ha Kim, M.D., Ph.D.,^{1,2,3} Sang Weon Lee, M.D., Ph.D.,^{1,2,3}
Geun Sung Song, M.D., Ph.D.^{1,2,3}

Department of Neurosurgery,¹ Pusan National University Yangsan Hospital, Yangsan, Korea

Research Institute for Convergence of Biomedical Science and Technology,² Pusan National University Yangsan Hospital, Yangsan, Korea

Department of Neurosurgery,³ Pusan National University School of Medicine, Yangsan, Korea

Objective : Laminoplasty is an effective surgical method for treating cervical degenerative disease. However, postoperative complications such as kyphosis, restriction of neck motion, and instability are often reported. Despite sufficient preoperative lordosis, this procedure often aggravates the lordotic curve of the cervical spine and straightens cervical alignment. Hence, it is important to examine preoperative risk factors associated with postoperative kyphotic alignment changes. Our study aimed to investigate preoperative radiologic parameters associated with kyphotic deformity post laminoplasty.

Methods : We retrospectively reviewed the medical records of 49 patients who underwent open door laminoplasty for cervical spondylotic myelopathy (CSM) or ossification of the posterior longitudinal ligament (OPLL) at Pusan National University Yangsan Hospital between January 2011 and December 2015. Inclusion criteria were as follows : 1) preoperative diagnosis of OPLL or CSM, 2) no previous history of cervical spinal surgery, cervical trauma, tumor, or infection, 3) minimum of one-year follow-up post laminoplasty with proper radiologic examinations performed in outpatient clinics, and 4) cases showing C7 and T1 vertebral body in the preoperative cervical sagittal plane. The radiologic parameters examined included C2–C7 Cobb angles, T1 slope, C2–C7 sagittal vertical axis (SVA), range of motion (ROM) from C2–C7, segmental instability, and T2 signal change observed on magnetic resonance imaging (MRI). Clinical factors examined included preoperative modified Japanese Orthopedic Association scores, disease classification, duration of symptoms, and the range of operation levels.

Results : Mean preoperative sagittal alignment was 13.01° lordotic; 6.94° lordotic postoperatively. Percentage of postoperative kyphosis was 80%. Patients were subdivided into two groups according to postoperative Cobb angle change; a control group (n=22) and kyphotic group (n=27). The kyphotic group consisted of patients with more than 5° kyphotic angle change postoperatively. There were no differences in age, sex, C2–C7 Cobb angle, T1 slope, C2–C7 SVA, ROM from C2–C7, segmental instability, or T2 signal change. Multiple regression analysis revealed T1 slope had a strong relationship with postoperative cervical kyphosis. Likewise, correlation analysis revealed there was a statistical significance between T1 slope and postoperative Cobb angle change ($p=0.035$), and that there was a statistically significant relationship between T1 slope and C2–C7 SVA ($p=0.001$). Patients with higher preoperative T1 slope demonstrated loss of lordotic curvature postoperatively.

Conclusion : Laminoplasty has a high probability of aggravating sagittal balance of the cervical spine. T1 slope is a good predictor of postoperative kyphotic changes of the cervical spine. Similarly, T1 slope is strongly correlated with C2–C7 SVA.

Key Words : Laminoplasty · Spondylosis · Myelopathy · Kyphosis · Spinal cord diseases/surgery · Cervical vertebrae.

• Received : May 17, 2017 • Revised : June 30, 2017 • Accepted : July 3, 2017

• Address for reprints : Dong Wuk Son, M.D., Ph.D.

Department of Neurosurgery, Pusan National University Yangsan Hospital, 20 Geumo-ro, Mulgeum-eup, Yangsan 50612, Korea
Tel : +82-55-360-2126, Fax : +82-55-360-2156, E-mail : md6576@naver.com

This is an Open Access article distributed under the terms of the Creative Commons Attribution Non-Commercial License (<http://creativecommons.org/licenses/by-nc/4.0>) which permits unrestricted non-commercial use, distribution, and reproduction in any medium, provided the original work is properly cited.

INTRODUCTION

Laminoplasty is an effective surgical method for treating patients with cervical spondylotic myelopathy (CSM) and ossification of the posterior longitudinal ligament (OPLL). This procedure has some advantages compared with laminectomy or multilevel cervical corpectomy. For instance, cervical laminectomy can result in reduced stability of the cervical spine and aggravate cervical lordosis postoperatively. Similarly, multilevel cervical corpectomy may be associated with various complications of bone grafts and plating. Cervical laminoplasty is an indirect spinal cord decompression procedure that induces posterior shifting of the spinal cord with motion preservation. However, this procedure invades the cervical posterior muscular-ligament complex and it can inevitably worsen the cervical sagittal balance¹². Posterior surgical approach can lead to complications such as sustained neuro-pathic radiculopathy, axial neck pain, or postoperative deterioration of cervical lordotic curvature⁸. Maintaining cervical lordosis is an important factor in ensuring the success of the treatment.

Several studies have reported parameters for predicting the incidence of kyphotic deformity post laminoplasty. Suk et al.¹¹ suggested a preoperative lordosis angle of less than 10° or kyphotic angle during flexion greater than lordotic angle during extension were predictive of postoperative kyphosis in patients with CSM. Michael et al.⁹ demonstrated that beginning laminoplasty at the C3 level, rather than C4 level, accelerated the loss of the cervical lordosis.

Recently, T1 slope and C2–C7 sagittal vertical axis (SVA) have been suggested as predictors of kyphotic alignment change^{1,5,6}. T1 slope is a well-known radiologic parameter that may be useful in assessing the sagittal balance of the spine. It is also associated with cervical lordosis and potential cervical degeneration¹⁵. Many studies of T1 slope have reported that patients with a high T1 slope have a higher risk of cervical kyphosis after laminoplasty. In our study, we investigated various radiologic and clinical parameters leading to kyphotic deformity postoperatively and confirmed the relationships between these factors and the loss of cervical lordosis.

MATERIALS AND METHODS

Patient enrollment and surgical procedure

We retrospectively reviewed the medical records of 49 patients who underwent laminoplasty of the cervical spine at Pusan National University Yangsan Hospital between January 2011 and November 2015. The inclusion criteria were as follows : 1) all patients were diagnosed preoperatively with either OPLL or CSM, 2) no previous history of cervical spinal operations, cervical trauma, infection, or neoplasm, 3) all patients underwent a minimum 1-year follow-up period post laminoplasty with proper radiological examinations performed in outpatient clinics, and 4) only cases showing C7 and T1 vertebral body in the preoperative cervical sagittal plane examination.

All patients underwent expansive open door laminoplasty (Hirabayashi technique) performed by a single surgeon, using a plate fixation system. If the stenotic lesion invaded the C2 or C7 level of the cervical spine, we carefully performed the laminoplasty at C2 or C7 level. Though the interspinous ligaments were preserved during the procedures, we eliminated the tip of the C7 spinous process to avoid irritation of the nuchal muscle. Postoperatively, all patients were instructed to wear a philadelphia neck collar for four weeks with the aim of preventing postoperative kyphosis.

Radiologic and clinical assessment

Radiologic parameters including C2–C7 Cobb angle, T1 slope, C2–C7 SVA, range of motion (ROM) from C2–C7, segmental instability and T2 signal change were assessed using magnetic resonance imaging (MRI). The C2–C7 SVA, T1 slope, C2–C7 lordosis were assessed on cervical neutral lateral radiographs in the free-standing position, with the patient's head maintaining a horizontal gaze. The C2–C7 SVA was defined as the distance from the posterosuperior corner of C7 and the vertical line from the center of the C2 body. T1 slope was defined as the angle between a horizontal plane and a line parallel to the superior T1 endplate. C2–C7 lordosis was calculated as the Cobb angle between the lower endplate of C2 and C7. These measurement methods are presented in Fig. 1. The ROM of the cervical spine was assessed by measuring the difference in alignment at flexion and extension⁴. Range of motion was calculated by adding the Cobb angle at flexion and extension. Segmental instability was confirmed by preop-

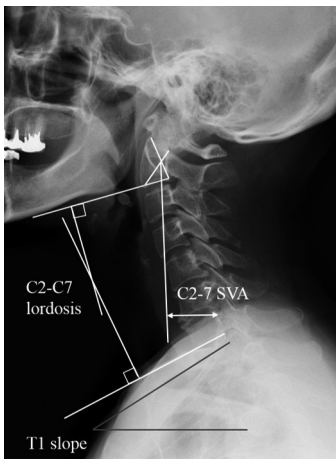


Fig. 1. Measurement of radiologic parameters, including C2–C7 SVA, C2–C7 lordosis and T1 slope in cervical lateral radiographs. SVA : sagittal vertical axis.

erative cervical lateral x-ray showing greater than a 3.5 mm horizontal displacement of one vertebra or more than 11° rotational difference to that of an adjacent vertebrae¹⁴). Radiologic data was calculated by two independent neurological spine surgeons, who were not involved in the study and blinded to all clinical information. All radiologic parameters were measured using commercial software (Marosis 5.0; INFINITT Healthcare, Seoul, Korea) respectively in preoperative phase and 1-year postoperative phase.

Clinical and operative factors including preoperative modified Japanese Orthopedic Association scores, visual analog scale, disease classification (CSM or OPLL), duration of symptoms, range of operation levels and whether the cephalad and caudal end of surgical sites were invaded at the C2 or C7 vertebrae.

Statistical analysis

Statistical analysis was performed using SPSS version 18.0 (SPSS Inc., Chicago, IL, USA). A *p*<0.05 was considered statistically significant. Normally distributed data was compared using unpaired Student’s t-tests and Mann-Whitney U tests for parametric and nonparametric continuous variables. Multiple logistic regression analysis was performed to determine the risk factor of complications. Pearson correlation coefficient analysis was used to confirm the relationship between the continuous variables Fisher’s exact test and chi-square test were used to analyze the categorical data. Receiver operating characteristic (ROC) curve analysis was used to determine a cut-off value, which was defined as the point corresponding to the maximum sum of the sensitivity and specificity.

Table 1. Postoperative changes in cervical alignment compared with preoperative cervical alignment

Postoperative cervical curvature	Preoperative cervical curvature			
	Lordosis	Straight	Kyphosis	Total
Lordosis	18	3	0	21
Straight	9	6	1	16
Kyphosis	6	4	2	12
Total	33	13	3	49

RESULTS

All 49 patients’ records were analyzed retrospectively. Our study population consisted of 29 male and 20 female patients with ages ranging from 37 to 84 years. The mean age was 62 years. The C2–C7 Cobb angle was used to define lordosis (Cobb’s angle <10°), straight (Cobb angle -10° to 0°), and kyphosis (Cobb angle >0°). Of the 49 patients, 33 had preoperative lordotic curvature. Thirteen patients had straight cervical curvature and only 3 patients had kyphotic cervical curvature. Mean sagittal alignment was 13.01° lordotic preoperatively and 6.94° lordotic postoperatively. The mean sagittal alignment change of cervical spine had deteriorated by 6.07° kyphotic. Among the 49 patients, 10 showed improved cervical alignment, the remaining 39 patients showed aggravated kyphotic changes. The percentage of postoperative kyphosis after laminoplasty was 79.6%. Of the cases with kyphotic changes, kyphotic angle change of more than 10° was observed in 13 cases, and kyphotic angle change between 5° to 10° was observed in 14 cases. Less than 5° angle change was seen in 12 cases. The changes Cobb angle, pre- to post- procedure are summarized in Table 1.

To evaluate the various preoperative predictors for postoperative kyphotic changes, the patients were subdivided into two groups based on postoperative change in Cobb angle C2–C7. Hence, the kyphotic group consisted of patients with more than 5° kyphotic angle change postoperatively. On the contrary, the control group consisted of patients with less than 5° kyphotic angle change. The demographics of the two groups are summarized in Table 2. The control group consisted of 22 patients and the kyphotic group consisted of 27 patients. Univariate analysis revealed no significant differences between the two groups for all of the variables analyzed.

Table 2. Comparisons of demographics, clinical, and radiologic preoperative data between the control group and kyphotic group

	Control group (n=22)	Kyphotic group (n=27)	p-value
Age (year)	59.80	63.78	0.077
Gender (male : female)	12 : 10	17 : 10	0.485
BMI (kg/m ²)	26.35	27.45	0.224
OPLL : CSM	15 : 7	17 : 10	0.454
Symptom duration	14.1 months	13.4 months	0.231
Pre VAS score	6.5	6.2	0.342
Pre JOA score	12.14	12.22	0.269
Signal change in T2 MRI	25/36	7/13	0.139
Preoperative Cobb angle (°)	-10.31	-15.21	0.362
Preoperative ROM (°)	36.6	31.59	0.421
Segmental instability	6/36 (16.6%)	4/13 (30.8%)	0.493
T1 slope (°)	26.93	31.46	0.471
C2–7 SVA (mm)	28.13	28.60	0.999
C2, 7 involvement	7/22 (31.8%)	4/27 (15%)	0.078

BMI : body mass index, OPLL : ossification of the posterior longitudinal ligament, CSM : cervical spondylotic myelopathy, VAS : visual analog scale, JOA : Japanese Orthopedic Association, MRI : magnetic resonance imaging, ROM : range of motion, SVA : sagittal vertical axis, CA : cobb angle

To evaluate the risk factors for postoperative kyphotic variation and to remove the confounding factors, we used multinomial regression analysis. The results indicated there were no statistically significant relationships between age, variation of Cobb angle, operation level, disease classification, ROM from C2–C7, segmental instability or T2 signal change on MRI. However, T1 slope had a strong relationship with postoperative cervical kyphosis ($p=0.006$). C2–C7 SVA was not statistically significant, although was revealed to be a meaningful factor ($p=0.053$). We considered T1 slope as a useful parameter for predicting postoperative kyphotic changes post laminoplasty and performed additional statistical tests.

Pearson correlation analysis showed that T1 slope had a significantly meaningful relationship with C2–C7 SVA, preoperative Cobb angle, and variation of Cobb angle. The relationships between T1 slope and variation of Cobb angle are shown in Fig. 2. Of the 3 factors, T1 slope was the most strongly correlated with C2–C7 SVA. These results are de-

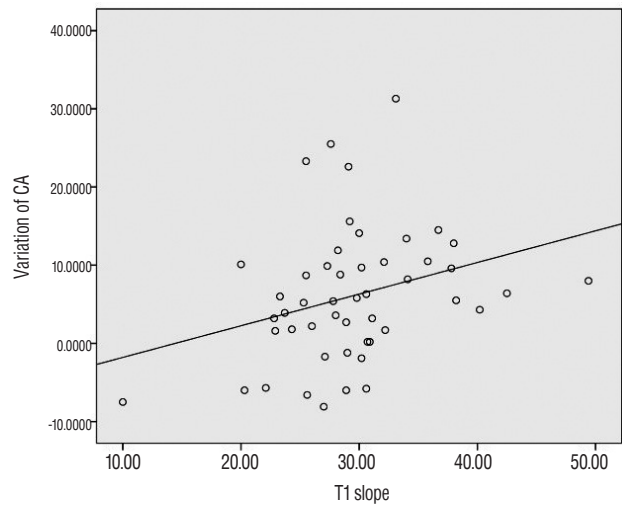


Fig. 2. Scatter plots showing a positive correlation between T1 slope and loss of cervical lordosis ($r=0.302$). CA : cobb angle.

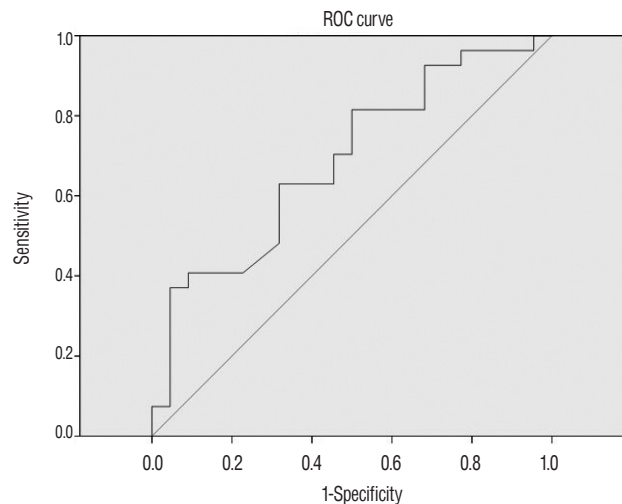


Fig. 3. ROC analysis was performed to determine the cut-off value of T1 slope that induced significant postoperative kyphotic change. T1 slope above 29° could serve as a threshold for significantly increased risk of postoperative kyphotic change ($p=0.026$, area under curve=0.687, sensitivity=63%, specificity=69%). ROC : receiver operating characteristic.

scribed in Table 3.

ROC curve analysis was used to identify the relationship between T1 slope and the kyphotic group (more than 5° kyphotic change postoperatively) (Fig. 3). The cut-off point was specified from the ROC curve using optimal intersection of specificity and sensitivity. Based on the ROC curve, the cut-off value was 29.05° at T1 slope ($p=0.026$, are under curve=0.687, sensitivity=63%, specificity=69%). Using this value, we converted the cases into a bifurcated variable (high

Table 3. Results of pearson correlations of included factors influencing postoperative kyphotic change

		T1 slope	C2–7 SVA	pre C2–7CA	Variation of CA
T1 slope	Pearson correlation	1	0.610*	-0.458*	0.302 [†]
	Significance (2-tailed)		0.000	0.001	0.03 ⁵
	Sample size	49	49	49	49
C2–7 SVA	Pearson correlation	0.610*	1	0.106	0.066
	Significance (2-tailed)	0.000		0.469	0.652
	Sample size	49	49	49	49
pre C2–7 CA	Pearson correlation	-0.458*	0.106	1	-0.219
	Significance (2-tailed)	0.001	0.469		0.131
	Sample size	49	49	49	49
Variation of CA	Pearson correlation	0.302 [†]	0.066	-0.219	1
	Significance (2-tailed)	0.035	0.652	0.131	
	Sample size	49	49	49	49

*Correlation is significant at the 0.01 level (2-tailed), [†]Correlation is significant at the 0.05 level (2-tailed). SVA : sagittal vertex axis, CA : cobb angle

T1 slope > 29° and low T1 slope < 29°) and assessed logistic regression analysis, which revealed that this threshold value was significantly associated with postoperative kyphosis ($p=0.033$, odds ratio=3.643, 95% confidence interval=1.109–11.969)

DISCUSSION

After the introduction of the laminoplasty, many studies reported postoperative kyphotic changes to the cervical spine^{2,3}. The results of the present study suggest that postoperative cervical spinal deformity is related to poor clinical outcomes. Uchida et al.¹³ insisted that kyphotic deformity may play an important role in neurologic dysfunction and careful attention should be paid to the selection of patients in surgery planning. According to the literature, the risk factors associated with postoperative kyphosis after laminoplasty are as follows: preoperative cervical curvature, the start point of the laminoplasty, the center of gravity of the head-C7 SVA and so on^{9,10}. Among the various factors, T1 slope is a recently introduced useful parameter and has already been shown to correlate with postoperative kyphotic degeneration after laminoplasty in many studies^{5,6}.

As a predictor of sagittal balance of the entire spine, T1 slope can provide useful information⁷. Sagittal imbalance in one region of the spine can influence other regions. The lower cervical spine is the most flexible region of the spine and the

cervical spine could easily compensate for disorders in other spinal regions. According to the literature, T1 slope is intrinsic to the individual and resembles pelvic incidence of the lumbosacral region¹. Hence, T1 slope can show the influence of the sagittal balance of the cervical spine.

Cho et al. reported that T1 slope was not associated with postoperative kyphotic deformity of the cervical spine and improvement of postoperative clinical outcomes¹. However, many more studies have reported a relationship between preoperative T1 slope and postoperative kyphosis. For patients with a high T1 slope, much greater lordotic demand was required to maintain the lordotic curve of the cervical spine and horizontal gaze in erect position. If these patients lost the lordotic curvature at the pathogenic states in comorbidity with CSM or OPLL of the cervical spine, the center of the gravity would move forward in order to maintain horizontal gaze and radiologic values such as C2–C7 SVA would be altered until adequate horizontal gaze was achievable. After the center of gravity of the cervical vertebra moved forward, the degenerative changes of the joint surface of the cervical vertebrae was accelerated and the changes of the vertebral joints were applied to work in favor of such kyphotic force (Fig. 4A). However, in patients with a low T1 slope, the forces that cause these changes are relatively low, and the movement of the cervical center of gravity is also low (Fig. 4B).

Laminoplasty originally performed on the posterior surface of the cervical spine, resulted in damage to the posterior spi-

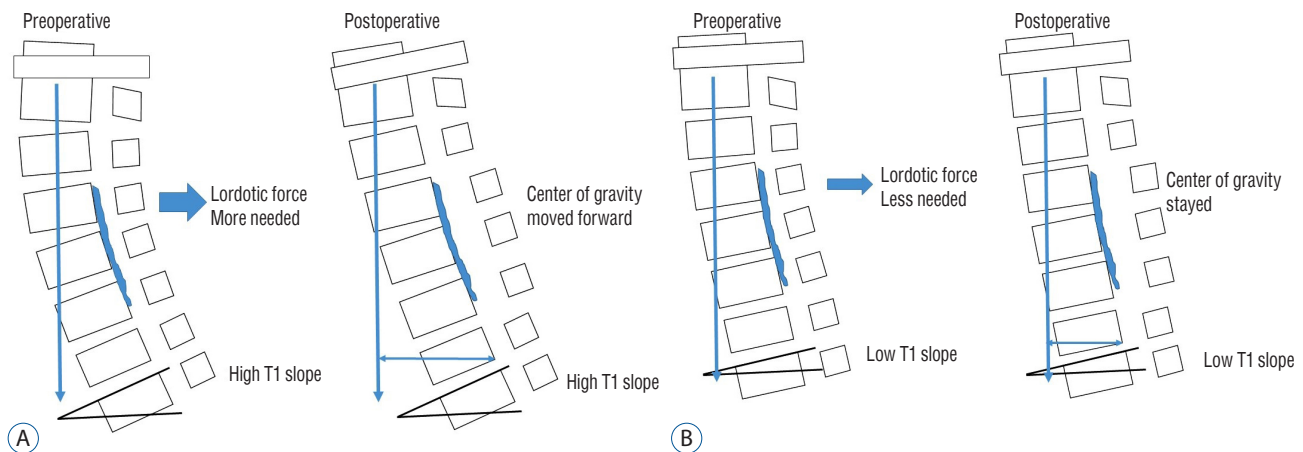


Fig. 4. Schematic image of alteration of cervical lordosis after laminoplasty in patients with OPLL. A : Patients with high T1 slope had needed more lordotic force. Postoperatively, center of gravity moved forward and cervical spine accelerated kyphotic. B : Patients with low T1 slope had relatively less influence of the operation than high T1 slope. OPLL : ossification of the posterior longitudinal ligament.

nal structures such as the nuchal ligament, various posterior neck muscles, and lamina, and in consequence, caused weakness of the posterior cervical structures. Patients with a high T1 slope are demanding more lordotic force than patients with a low T1 slope are; therefore, they are more susceptible to these changes postoperatively. Consequently, we believe that patients with a high T1 slope are more likely to develop posterior kyphotic deformity post procedure. In our study, of the 25 patients with low T1 slope, 7 cases showed improved cervical curvature in comparison to preoperative cervical sagittal alignment. However, of the 24 patients with high T1 slope, only 2 cases showed improvement in cervical curvature. We assumed that these procedures result in changes for the better to the narrowed cervical canal and therefore offset the effects of the invasion of posterior neck structures.

Using statistical analysis, and by dividing the high T1 group by the low T1 group, we regarded the cut-off point as 29°. In other studies regarding T1 slope and postoperative kyphosis, reference points to divide high or low were acquired based on the median preoperative point of T1 slope. Reference points of each study were within the range of 23.0° to 27.3°. We did not utilize the method of average points used by previous papers. Instead, we confirmed the cut-off value through ROC curve statistical analysis of our data. Our cut-off value was 29.05° and slightly higher than other results. We identified that patients with high T1 slope were approximately 3.5 times more vulnerable to kyphotic change than are patients with low T1 slope.

Other studies have suggested that preoperative lordosis

might be a factor in determining postoperative kyphosis changes on the base of the fact that preoperative lordosis made statistical curve similar to T1 slope. Therefore, there are some studies that statistical analysis of factors subtracting cervical lordosis from T1 slope (T1S-CL)⁵⁾. We also conducted our study using our statistics, but the T1 slope itself better explained the patient's kyphotic curvature change than the T1S-CL value. We think that T1 slope had the more meaningful clinical research value than T1S-CL because T1 slope is simple and easily calculated than T1S-CL.

Our study had several limitations. First, we established longer than 1-year duration as the period for the subjects, but the period was slightly shorter to confirm the postoperative deformity of cervical spine. Second, the study group comprised of a relatively small number of patients. Third, we performed laminoplasty on patients with OPLL and CSM. However, we did not classify each disease according to severity, type, or location. Hence, a more elaborate study with a long-term follow-up would be necessary for patents with OPLL and CSM. However, it has been shown that the degree of T1 slope plays an important role in cervical kyphosis after laminoplasty.

CONCLUSION

Laminoplasty can result in posterior cervical kyphosis with a relative high probability. We evaluated various factors associated with cervical kyphosis and found that T1 slope was sig-

nificantly associated with this deformity. T1 slope has a strong correlation with C2–C7 SVA and cervical kyphosis is increasing on the basis of a cut-off point of 29°. T1 slope can be a predictor of postoperative kyphotic changes in the cervical spine post laminoplasty. Hence, careful consideration must be given to these complications in patients with a high T1 slope.

References

1. Cho JH, Ha JK, Kim DG, Song KY, Kim YT, Hwang CJ, et al. : Does preoperative T1 slope affect radiological and functional outcomes after cervical laminoplasty? **Spine (Phila Pa 1976)** **39** : E1575-E1581, 2014
2. Dugoni DE, Mancarella C, Landi A, Tarantino R, Ruggeri AG, Delfini R : Post laminoplasty cervical kyphosis-case report. **Int J Surg Case Rep** **5** : 853-857, 2014
3. Ellwitz J, Roberto R, Gupta M, Mohan V, Klineberg E : Patient and surgeon factors associated with postoperative kyphosis after laminoplasty. **Evid Based Spine Care J** **2** : 53-54, 2011
4. Kang SH, Rhim SC, Roh SW, Jeon SR, Baek HC : Postlaminoplasty cervical range of motion: early results. **J Neurosurg Spine** **6** : 386-390, 2007
5. Kim B, Yoon DH, Ha Y, Yi S, Shin DA, Lee CK, et al. : Relationship between T1 slope and loss of lordosis after laminoplasty in patients with cervical ossification of the posterior longitudinal ligament. **Spine J** **16** : 219-225, 2016
6. Kim TH, Lee SY, Kim YC, Park MS, Kim SW : T1 slope as a predictor of kyphotic alignment change after laminoplasty in patients with cervical myelopathy. **Spine (Phila Pa 1976)** **38** : E992-E997, 2013
7. Knott PT, Mardjetko SM, Techy F : The use of the T1 sagittal angle in predicting overall sagittal balance of the spine. **Spine J** **10** : 994-998, 2010
8. Matsumoto M, Chiba K, Toyama Y : Surgical treatment of ossification of the posterior longitudinal ligament and its outcomes: posterior surgery by laminoplasty. **Spine (Phila Pa 1976)** **37** : E303-E308, 2012
9. Michael KW, Neustein TM, Rhee JM : Where should a laminoplasty start? The effect of the proximal level on post-laminoplasty loss of lordosis. **Spine J** **16** : 737-741, 2016
10. Sakai K, Yoshii T, Hirai T, Arai Y, Shinomiya K, Okawa A : Impact of the surgical treatment for degenerative cervical myelopathy on the preoperative cervical sagittal balance: a review of prospective comparative cohort between anterior decompression with fusion and laminoplasty. **Eur Spine J** **26** : 104-112, 2017
11. Suk KS, Kim KT, Lee JH, Lee SH, Lim YJ, Kim JS : Sagittal alignment of the cervical spine after the laminoplasty. **Spine (Phila Pa 1976)** **32** : E656-E660, 2007
12. Tang JA, Scheer JK, Smith JS, Deviren V, Bess S, Hart RA, et al. : The impact of standing regional cervical sagittal alignment on outcomes in posterior cervical fusion surgery. **Neurosurgery** **71** : 662-669; discussion 669, 2012
13. Uchida K, Nakajima H, Sato R, Yayama T, Mwaka ES, Kobayashi S, et al. : Cervical spondylotic myelopathy associated with kyphosis or sagittal sigmoid alignment: outcome after anterior or posterior decompression. **J Neurosurg Spine** **11** : 521-528, 2009
14. White AA 3rd, Panjabi MM : Update on the evaluation of instability of the lower cervical spine. **Instr Course Lect** **36** : 513-520, 1987
15. Yang BS, Lee SK, Song KS, Yoon SP, Jang G, Lee CC, et al. : The use of T1 sagittal angle in predicting cervical disc degeneration. **Asian Spine J** **9** : 757-761, 2015