



## Case report

## Acute respiratory distress syndrome; A rare complication caused by usage of ruxolitinib



Bugra Kerget\*, Omer Araz, Elif Yilmazel Ucar, Metin Akgun, Leyla Sağlam

Department of Pulmonary Diseases, Ataturk University School of Medicine, 25240, Erzurum, Turkey

## ARTICLE INFO

## Article history:

Received 9 May 2017

Received in revised form

7 September 2017

Accepted 9 September 2017

## Keywords:

Acute respiratory distress syndrome

Primary myelofibrosis

Ruxolitinib

## ABSTRACT

Ruxolitinib-associated acute respiratory distress has rarely been reported, mostly due to discontinuation of treatment. Herein we report a 58-year-old male patient with primary myelofibrosis who presented with malaise and dyspnea 15 days after initiation of the treatment. The patient was diagnosed as mild acute respiratory distress syndrome (ARDS). After excluding other potential causes such as infection and cardiac pathologies, it was considered secondary to ruxolitinib use. The medication was discontinued and 1 mg/kg methylprednisolone was given to prevent cytokine rebound syndrome and continuous positive airway pressure therapy was prescribed for ARDS. Symptomatic improvement and complete radiological resolution was observed. This case suggests that ARDS may develop secondary to ruxolitinib use and ARDS should be kept in mind in the cases with respiratory symptoms who were on treatment.

© 2017 The Authors. Published by Elsevier Ltd. This is an open access article under the CC BY-NC-ND license (<http://creativecommons.org/licenses/by-nc-nd/4.0/>).

## 1. Introduction

Ruxolitinib is a janus kinase (JAK) inhibitor used in the treatment of myelofibrosis and proven to be effective in alleviating the symptoms of this disease and treating splenomegaly [1]. Ruxolitinib may cause hematologic side effects, particularly anemia and thrombocytopenia; however, pulmonary complications such as pulmonary hypertension exacerbations, acute respiratory distress and pleural effusion are extremely rare [2].

Herein, we present a rare condition, ruxolitinib-associated acute respiratory distress syndrome in a patient with primary myelofibrosis who receiving ruxolitinib on 15th day.

## 2. Case report

A 58-year-old male patient presented with was malaise and dyspnea for 15 days following the initiation of ruxolitinib treatment due to primary myelofibrosis. The patient had the complaints of stomachache, weight loss, and malaise for five months. Physical examination revealed tachypnea (26 per min) and diffuse fine bibasilar crackles on auscultation. On hospital admission, the blood gas values were: pH = 7.35, arterial oxygen tension (PaO<sub>2</sub>)

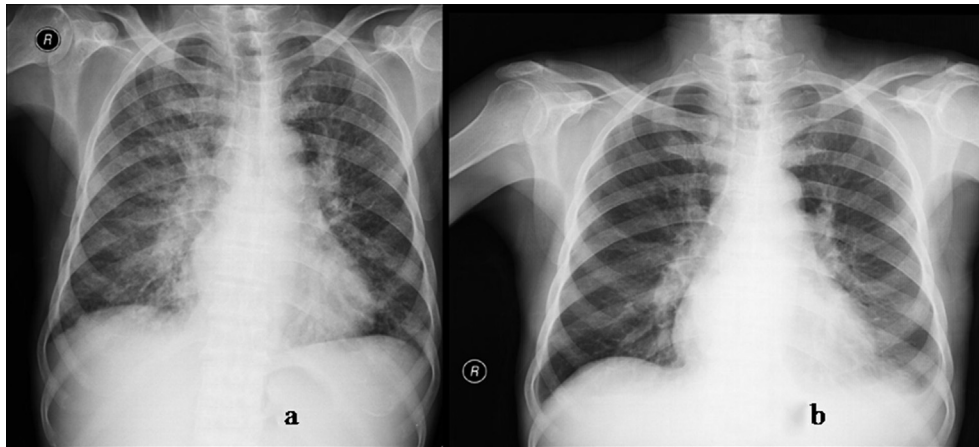
75 mmHg (FIO<sub>2</sub>:0.41), arterial carbon dioxide tension (PaCO<sub>2</sub>) 34 mmHg, bicarbonate (HCO<sub>3</sub>) 24 mEq/l and percent of arterial oxygen saturation (SaO<sub>2</sub>) 80%. The results of complete blood count (CBC) on admission were as follows; hemoglobin 7.8 g/dL, white blood cell count  $4.4 \times 10^9/L$ , and thrombocyte count  $84 \times 10^9/L$ . Chest x-ray revealed a perihilar distribution of increased reticular density, extending peripherally with sporadic air bronchograms. (Fig. 1a). On abdominal USG, the spleen dimensions were larger than normal (20 × 9 × 8 cm). On echocardiography, ejection fraction (EF) was 60% and mean pulmonary arterial pressure 40 mmHg, and there was a mild right cardiac dilatation. High-resolution computed tomography (HRCT) revealed complete and incomplete consolidation areas with alveolar distribution especially in the upper and middle lobes (Fig. 2).

Before treatment, physical exam was unremarkable. The CBC results were: hemoglobin 11.4 g/dL, white blood cell count  $5 \times 10^9/L$ , and thrombocyte count  $164 \times 10^9/L$ , respectively. The mutation of JAK2 V617F was positive. On abdominal ultrasonography (USG), the spleen dimensions were 25 × 10 × 10 cm. Pretreatment echocardiography findings were same. There was no pulmonary parenchymal and vascular abnormality to explain the increased pulmonary hypertension.

Because hematological and pulmonary involvement was suspected to be secondary to ruxolitinib treatment, the medication was discontinued. Treatment with 1 mg/kg methylprednisolone was initiated to prevent cytokine rebound syndrome. Because of mild acute respiratory distress, non-invasive mechanic ventilation

\* Corresponding author. Ataturk University, Faculty of Medicine, Department of Chest Disease, 25240, Yakutiye, Erzurum, Turkey.

E-mail address: [bjkerget1903@gmail.com](mailto:bjkerget1903@gmail.com) (B. Kerget).



**Fig. 1.** a) Increasing reticular density was observed starting from the bilateral hilar zone, extending peripherally and featuring sporadic air bronchograms. b) Revealed regression of the pulmonary consolidation.

(NIV) with continuous positive airway pressure (CPAP) was started. The cultures of sputum, blood and urine samples were negative. On the 8th day of treatment, the patient's respiratory symptoms completely resolved and chest x-ray revealed regression of the pulmonary consolidation (Fig. 1b). The methylprednisolone therapy was gradually tapered and discontinued.

### 3. Discussion

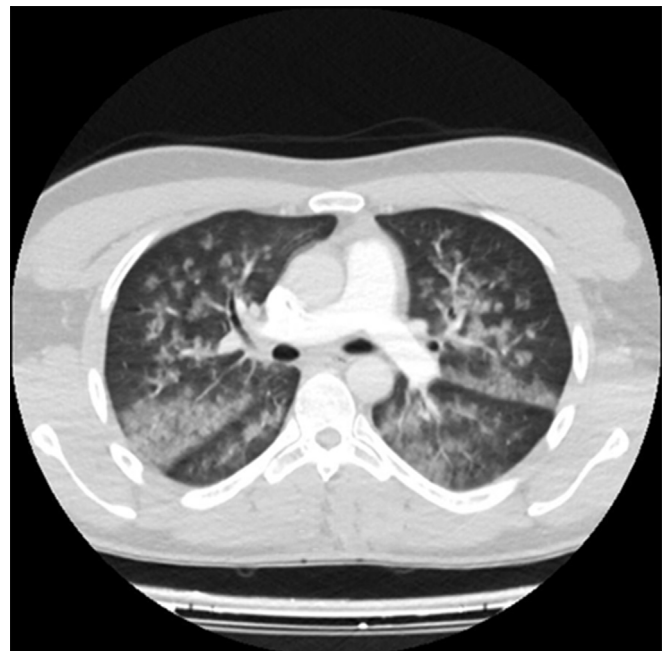Whit this case report, we aimed to share our experience on ruxolitinib-associated acute respiratory distress syndrome, which is very rare, in a patient with primary myelofibrosis that developed after 15 days of ruxolitinib treatment initiation and completely resolved with the discontinuation of medication.

Acute respiratory distress syndrome (ARDS) develops due to various reasons and is characterized by severe hypoxemia and pulmonary edema secondary to increased permeability of the alveolocapillary membranes [3]. It may be primarily lung-related, such as pneumonia, aspiration, chest trauma, and inhalation, or develop secondarily due to sepsis, acute pancreatitis, extrathoracic trauma, or medication [4,5]. The previously defined acute lung injury (ALI) term was replaced with the description of mild ARDS according to revised criteria in 2013 in a joint meeting of the American Thoracic Society and the European Society of Intensive Care Medicine [6]. Drug-induced ARDS is usually caused by high doses of aspirin, cocaine, opioids, phenothiazine, tricyclic antidepressants, or idiosyncratically by protamine, nitrofurantoin. In addition to these commonly implicated drugs, the chemotherapeutic agents induce ARDS. A diagnosis of drug-induced ARDS may be established after excluding a wide range of diseases including infections, autoimmune diseases, malignancy, and heart failure [7].

Ruxolitinib is a JAK inhibitor increasingly used to treat primary myelofibrosis patients with symptomatic splenomegaly. Although ruxolitinib is highly effective, it may lead to major side effects such as anemia and thrombocytopenia which require dosage adjustment or discontinuation of the drug. Ruxolitinib may also result in pulmonary complications such as the rarely observed ARDS, pulmonary hypertension exacerbations, and pleural effusion [2]. Although there are some cases of respiratory distress that associated with discontinuation of ruxolitinib [8–10], according to our knowledge, no report on treatment. Although both cytotoxic and immune mechanisms of action may be involved independently or in combination in the tissue expression of different forms of lung injury [11], the mechanism of ruxolitinib-associated acute respiratory

distress has not yet been clearly determined. The recommended treatment is to discontinue the drug and initiate symptomatic treatment as well as corticosteroid therapy to avoid the rebound effect of proinflammatory cytokines and inflammatory markers, which were reduced by ruxolitinib [8]. We considered our case as mild ARDS and initiated NIV treatment with CPAP for respiratory distress as well as methylprednisolone at a dose of 1 mg/kg. With the exception of superinfections that may develop in these cases, clinical improvement is expected in 1 week–10 days; our patient completely recovered within 8 days.

Although there are some reports of respiratory distress that occurred with the discontinuation of treatment, according to our best knowledge, this is the first report of ARDS in a patient with primary myelofibrosis who receiving ruxolitinib. Thus, ARDS should be considered in the cases who were on treatment with ruxolitinib who develop respiratory symptoms.



**Fig. 2.** Complete-incomplete consolidation with alveolar distribution was observed in both lungs especially in the upper and middle lobes.

### Conflict of interest

All authors disclosure no Conflict of Interest.

### References

- [1] A. Ganetsky, Ruxolitinib: a new treatment option for myelofibrosis, *Pharmacother. J. Hum. Pharmacol. Drug Ther.* 33 (1) (2013) 84–92.
- [2] M. Ayli, M. Özcan, G.C. Seval, Ruxolitinib treatment in a patient with primary myelofibrosis resistant to conventional therapies and splenectomy: a case report, *Turkish J. Hematol.* 32 (2) (2015) 180.
- [3] C. Hodgson, G. Carteaux, D.V. Tuxen, A.R. Davies, V. Pellegrino, G. Capellier, D.J. Cooper, A. Nichol, Hypoxaemic rescue therapies in acute respiratory distress syndrome: why, when, what and which one? *Injury* 44 (12) (2013) 1700–1709.
- [4] M. Akgun, A. Mirici, M. Meral, L. Saglam, H. Kaynar, M. Gorguner, E.Y. Ucar, A hypersensitivity pneumonitis case complicated with acute respiratory distress syndrome after bronchoscopy, *Respir. Med.* 99 (9) (2005) 1195–1197.
- [5] C.H. Goss, R.G. Brower, L.D. Hudson, G.D. Rubenfeld, Incidence of acute lung injury in the United States, *Crit. Care Med.* 31 (6) (2003) 1607–1611.
- [6] A.D.T. Force, Acute respiratory distress syndrome, *Jama* 307 (23) (2012) 2526–2533.
- [7] E. Kunter, T. Işitmangil, Acute respiratory distress syndrome, *Turkish J. Thorac. Cardiovasc. Surg.* 18 (3) (2010) 238–246.
- [8] Y. Beauverd, K. Samii, Acute respiratory distress syndrome in a patient with primary myelofibrosis after ruxolitinib treatment discontinuation, *Int. J. Hematol.* 100 (5) (2014) 498–501.
- [9] T. Dai, E.W. Friedman, S.K. Barta, Ruxolitinib withdrawal syndrome leading to tumor lysis, *J. Clin. Oncol.* 31 (29) (2013) e430–e432.
- [10] A. Tefferi, A. Pardanani, Serious adverse events during ruxolitinib treatment discontinuation in patients with myelofibrosis, in: *Mayo Clinic Proceedings Elsevier*, 2011, pp. 1188–1191.
- [11] O. Matsuno, Drug-induced interstitial lung disease: mechanisms and best diagnostic approaches, *Respir. Res.* 13 (1) (2012) 39.