

### Failure of long-term lamivudine prophylaxis in patients with resolved hepatitis B infection undergoing chemotherapy and allogenic hematopoietic stem cell transplantation for hematological malignancies: two case reports

Hepatitis B virus (HBV) reactivation is a well known complication in patients with resolved HBV infection, i.e., HBsAg negative, hepatitis B core antibody (anti-HBc) positive  $\pm$  antibodies against HBsAg (anti-HBs), undergoing chemotherapy (CT) and/or allogenic hematopoietic stem cell transplantation (HSCT) for onco-hematological diseases.<sup>1-3</sup> In these patients, this risk can be prevented by either “pre-emptive anti-HBV therapy”, based on the monitoring of HBV DNA and/or HBsAg, followed by rescue therapy with anti-HBV regimens, or by “anti-HBV prophylaxis” based on the administration of nucleos(t)ides analogs (NUCs) during immunosuppression and for a consolidation time after the end of immunosuppressive drugs. As per standard procedure in our centre, all patients with hematological malignancies and a resolved HBV infection receive lamivudine (LMV) prophylaxis at the time of CT or HSCT to be maintained for at least 18 months after the discontinuation of immunosuppressive drugs.

Herein, we describe two patients with resolved HBV infection who, following allogenic HSCT and repeated cycles of CT for hematological malignancies, developed HBsAg seroreversion due to the late emergence of LMV-resistance (R) during long-term LMV prophylaxis.

**Case A.** A 56-year-old Italian male was diagnosed with micromolecular IgG kappa multiple myeloma (MM) on June 2008. Since the virological profile was consistent with a resolved HBV infection with positive anti-HBe and anti-HBs (240 IU/L) and undetectable serum HBV DNA (<12 IU/mL), LMV prophylaxis was started concomitantly with CT initiation. Between January 2009 and December 2010, several cycles of CT were administered (Table 1 and Figure 1). In December 2010, a matched unrelated donor (MUD) HSCT was carried out (donor HBV profile: HBsAg negative, anti-HBs 715 IU/L, anti-HBc negative) and cyclosporin (CSA) as a prophylaxis and treatment of graft *versus* host disease (GvHD) was started to be progressively reduced and withdrawn in May 2012. However, in April 2012, MM relapsed requiring further cycles of CT without, nevertheless, achieving complete disease remission. In November 2015, the patient was enrolled in a phase I/II trial based on the co-administration of carfilzomib+pomalidomide+dexamethasone. Between 2008 and November 2015, the patient remained persistently negative for HBsAg, HBeAg

**Table 1.** Case A. Chemotherapy regimens and clinical outcomes.

Chemotherapy	Time	Cycles	Early discontinuation	Complications	Response
RD (Lenalidomide + dexamethasone)	1 July 08 - 23 Sept 08	4	No	None	No
Cyclophosphamide	21 Nov 08	1	Yes	Spontaneous 5° left rib fracture	na
Protocol “MPR <i>vs.</i> Mel 200” in MPR arm (Melphalan + prednisone + Lenalidomide)	15 Jan 09 - 04 Jun 09	6	Yes	Disease progression;	
10° left rib fracture after a sneeze	na				
VD (Bortezomib + dexamethasone)	30 Oct 09 - 11 Dec 09	3	Yes	Neutropenia	na
PAD (Bortezomib + doxorubicin + dexamethasone)	15 Jan 10 - 06 April 10	4	Yes	Pneumonia	na
VD-PACE (dexamethasone + Bortezomib + Platinum Agent + doxorubicin + Cyclophosphamide + Etoposide)	16 June 10 - 03 Aug 10	2	Yes	Mucositis I grade Folliculitis Acute bronchitis	na
Hematopoietic cell transplantation MUD (Matched Unrelated Donor)	15 Dec 10	na	na	Ocular GvHD; Cytomegalovirus reactivation.	13 April 12 reactivation of the disease
RD (Lenalidomide + dexamethasone) and RT (44 Gy)	23 May 12 - 16 Nov13 07 March13 - 09 April 13	17 22	Yes	Disease progression	na
Bendamustine	15 Jan 14 - 20 May 14	5	Yes	Disease progression	na
MP (Melphalan + prednisone)	25 June 14	1	Yes	No, but new protocol arrived	na
Fase I/II protocol LGH447 + BYL719	07 Aug 14 - 26 May15	11	Yes	Disease progression	na
Fase I/II protocol carfilzomib + pomalidomide + dexamethasone	15 Nov 15 - 25 Feb 16	7	Yes	Hepatitis B virus reactivation during Lamivudine prophylaxis	na

na: not applicable; GvHD: graft-*versus*-host disease.



report of very late onset of LMV-R developing in patients with resolved HBV infection following heavy immunosuppressive therapy for hematological malignancies.

HBV reactivation may hit patients with resolved HBV infection undergoing CT and/or HSCT, at a rate of up to 50%.<sup>1-3</sup> These patients, in fact, harbor low-level transcription and replication of HBV in the liver which may flare up on prolonged exposure to immunosuppressive therapies.<sup>4</sup> While management to prevent HBV reactivation in such patients is not standardized, two available options include “pre-emptive anti-HBV therapy” and “universal anti-HBV prophylaxis”. However, patients with lymphoma and with resolved HBV infection, HBV reactivation and severe HBV-related hepatitis were not fully prevented by “pre-emptive anti-HBV therapy” with entecavir (ETV).<sup>5,7</sup> Moreover, a randomized controlled study from Taiwan demonstrated a higher risk of HBV reactivation among the patients undergoing ETV as “pre-emptive

therapy” compared to those who received this nucleoside analog as “prophylaxis” (18% vs. 2.4%,  $P=0.027$ ).<sup>8</sup> Similar findings were confirmed in a Spanish randomized prospective open label study in which TDF was used.<sup>9</sup> Two Italian single center retrospective studies testing LMV as universal prophylaxis in patients with resolved HBV infection treated with Rituximab-based CT for NHL provided conflicting results. The former study demonstrated that LMV prophylaxis efficiently prevented HBV reactivation, both during and after withdrawal of CT, while the second showed a 10% risk of HBV reactivation.<sup>10,11</sup>

The risk of HBV reactivation in the onco-hematological settings requiring HSCT was investigated by a few studies. A recent Asian retrospective study of 173 patients with resolved HBV infection undergoing allogenic HSCT during a median follow up of 21 months showed no significant difference in the incidence of HBV reactivation

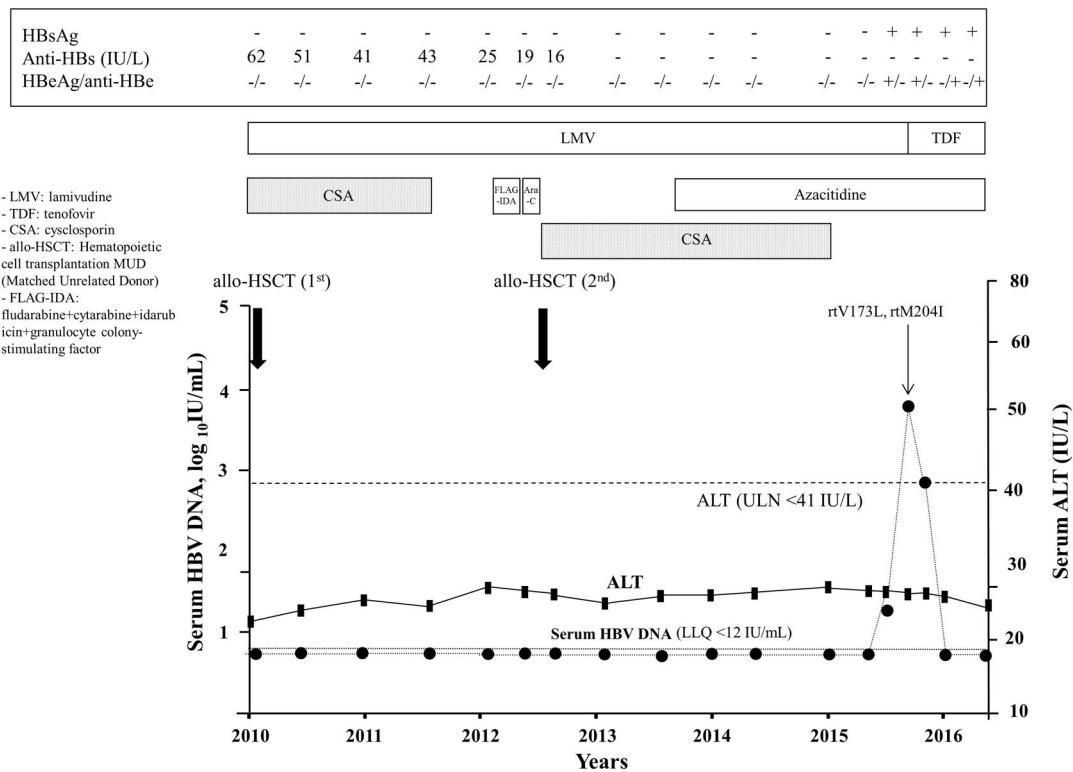


Figure 2. Time course of serum ALT and HBV DNA in Case B. CSA: cyclosporine; FLAG-IDA: fludarabine+cytarabine+idarubicin+granulocyte colony-stimulating factor; ARA-C: cytosine arabinoside high dose.

Table 2. Case B. Chemotherapy regimens and clinical outcomes.

Chemotherapy	Time	Cycles	Early discontinuation	Complications	Response
FLAG-IDA (Fludarabine+cytarabine +idarubicin +granulocyte colony-stimulating factor)	16 Oct 12 - 20 Jan 13	2	No	None	CR
ARA-C (Cytosine Arabinoside) high dose	20 Feb 13	1	No	None	CR
Azacitidine*	6 April 14 – 7 Nov 16	30	No	None	CR

between patients receiving “universal prophylaxis” with different NUCs and those managed with the “pre-emptive anti-HBV therapy” (5% vs. 5.3%).<sup>12</sup> Two studies among Italian patients with resolved HBV infection undergoing HSCT reported that LMV prophylaxis efficiently prevented HBV reactivation in the vast majority of cases.<sup>13,14</sup>

As recommended by Italian guidelines,<sup>15</sup> all patients referred to our Center due to a resolved HBV infection in need of CT for lymphoma, MM, AML, acute and chronic lymphocytic leukemia, and/or allogeneic HSCT were considered for LMV prophylaxis to be maintained for at least 18 months after the end of the immunosuppression. Up to now, 318 patients have been managed with this approach and, herein, we report the only two cases (0.6%) that experienced HBV reactivation. To the best of our knowledge, these are the first ever reported cases of LMV-R developing after up to 8 years of prophylaxis in patients with resolved HBV infection and onco-hematological malignancies.

The interesting aspect of our report is that despite having protective anti-HBs titers and undetectable serum HBV DNA at baseline, both patients failed LMV after many years of effective prophylaxis, an event that was heralded by anti-HBs titer decline during CT and after HSCT. Boosting the risk of HBV reactivation in our patients could have been a number of factors, including the underlying malignancies, the pre-HSCT conditioning regimen, the intense and repeated cycles of CT including carfilzomib, bortezomib, pomalidomide, fludarabine, not to speak of occurrence and severity of GvHD which required long-term CSA. By contrast, it is unlikely that the virological profile of the donors played any role in HBV reactivation as seroconversion occurred many years after HSCT.

Whether universal prophylaxis with LMV remains the best option in a setting like this where new potent molecular target drugs are being developed, where the duration of immunosuppression cannot be easily anticipated, and where multiple and highly immunosuppressive regimens may be required, remains unclear. Universal prophylaxis with third generation NUCs like ETV or TDF in these patients could be taken into consideration although this strategy would be more expensive and it is not currently refunded by many National Health Systems. Including ours. Only long-term prospective studies of large cohorts of such patients, aimed to define the risk and predictors of LMV failure, and the cost-effectiveness of LMV in comparison to ETV or TDF, will shed new light on this relevant issue.

In conclusion, universal prophylaxis with LMV monotherapy in patients with resolved HBV infection undergoing CT and/or HSCT for hematological malignancies is effective and safe but close, long-term virological and clinical monitoring is necessary to intercept and promptly rescue the few HBV reactivations due to virological breakthrough caused by LMV-resistance.

Selected onco-hematological patients with MM and leukemia and resolved HBV infection without oncologic response who need long-term chemotherapy or those who underwent HSCT requiring long-term immunosuppression due to chronic GvHD and, thereby, in need of long-term LMV prophylaxis, should be considered at very high risk of viral reactivation. These patients could be switched to third generation NUCs after 4 or 5 years of LMV prophylaxis, as no LMV-R has been reported before this time point in such a setting. Alternatively, third generation NUCs could be started as initial prophylaxis strategy.

Glenda Grossi,<sup>1</sup> Mauro Viganò,<sup>2</sup> Floriana Facchetti,<sup>1</sup> Sara Labanca,<sup>2</sup> Alessandro Loglio,<sup>1</sup> Anna Doderò,<sup>3</sup> Vittorio Montefusco,<sup>3</sup> Paolo Corradini,<sup>3</sup> Anna Cafro,<sup>4</sup> Roberto Cairoli,<sup>4</sup> Massimo Colombo<sup>5</sup> and Pietro Lampertico<sup>1</sup>

<sup>1</sup>A. M. and A. Migliavacca” Center for Liver Disease, Division of Gastroenterology and Hepatology, Fondazione IRCCS Cà Granda Ospedale Maggiore Policlinico, Università degli Studi di Milano;

<sup>2</sup>Division of Hepatology, Ospedale San Giuseppe, Università degli Studi di Milano; <sup>3</sup>Dept. Hematology & Pediatric Onco-Hematology, IRCCS Istituto Nazionale dei Tumori, Università degli Studi di Milano; <sup>4</sup>Dept. of Hematology and Oncology, Niguarda Cancer Center, Ospedale Niguarda Ca' Granda, Milan and <sup>5</sup>Center for Translational Hepatology Research, IRCCS Humanitas Hospital and University, Rozzano, Italy

Correspondence: [pietro.lampertico@unimi.it](mailto:pietro.lampertico@unimi.it)  
doi:10.3324/haematol.2017.168609

Information on authorship, contributions, and financial & other disclosures was provided by the authors and is available with the online version of this article at [www.haematologica.org](http://www.haematologica.org).

## References

- Seto WK. Hepatitis B virus reactivation during immunosuppressive therapy: Appropriate risk stratification. *World J Hepatol.* 2015; 7(6):825-830.
- Raimondo G, Allain JP, Brunetto MR. Statements from the Taormina expert meeting on occult hepatitis B virus infection. *J Hepatol.* 2008; 49(4):652-657.
- Viganò M, Serra G, Casella G, Grossi G, Lampertico P. Reactivation of hepatitis B virus during targeted therapies for cancer and immune-mediated disorders. *Expert Opin Biol Ther.* 2016;16(7):917-926.
- Raimondo G, Pollicino T, Cacciola I, Squadrito G. Occult hepatitis B infection. *J Hepatol.* 2007;46(1):160-170.
- Kusumoto S, Tanaka Y, Suzuki R, et al. Monitoring of hepatitis B virus (HBV) DNA and risk of HBV reactivation in B-cell lymphoma: a prospective observational study. *Clin Infect Dis.* 2015;61(5):719-729.
- Tamori A, Hino M, Kawamura E, et al. Prospective long-term study of hepatitis B virus reactivation in patients with hematological malignancy. *J Gastroenterol Hepatol.* 2014;29(9):1715-1721.
- Hsu C, Tsou HH, Lin SJ, et al. Chemotherapy-induced hepatitis B reactivation in lymphoma patients with resolved HBV infection: A prospective study. *Hepatology.* 2014;59(6):2092-2100.
- Huang YH, Hsiao LT, Hong YC, et al. Randomized controlled trial of entecavir prophylaxis for rituximab-associated hepatitis B virus reactivation in patients with lymphoma and resolved hepatitis B. *J Clin Oncol.* 2013;31(22):2765-2772.
- Buti M, Manzano ML, Morillas RM, et al. Prevents HBV reactivation with tenofovir in anti-HBc positive patients with hematological malignancies treated with rituximab. Results final visit 18-months (PREBELIN STUDY). *J Hepatol.* 2016;64(suppl):S369.
- Viganò M, Grossi G, Borsotti E, et al. Lamivudine prophylaxis prevents hepatitis B reactivation in HBsAg-negative/anti-HBc-positive patients undergoing Rituximab-based chemotherapy for non-Hodgkin's B cell lymphoma. *J Hepatol.* 2015;6(suppl):S566.
- Castelli R, Ferraris L, Pantaleo G, et al. High rate of hepatitis B viral breakthrough in elderly non-Hodgkin lymphomas patients treated with Rituximab based chemotherapy. *Dig Liver Dis.* 2016; 48(11):1394-1397.
- Yoo JJ, Cho EJ, Cho YY, et al. Efficacy of antiviral prophylaxis in HBsAg-negative, anti-HBc positive patients undergoing hematopoietic stem cell transplantation. *Liver Int.* 2015;35(12):2530-2536.
- Giaccone L, Festuccia M, Marengo A, et al. Hepatitis B virus reactivation and efficacy of prophylaxis with lamivudine in patients undergoing allogeneic stem cell transplantation. *Biol Blood Marrow Transplant.* 2010;16(6):809-817.
- Cerva C, Colagrossi L, Maffongelli G, et al. Persistent risk of HBV reactivation despite extensive lamivudine prophylaxis in haematopoietic stem cell transplant recipients who are anti-HBc-positive or HBV-negative recipients with an anti-HBc-positive donor. *Clin Microbiol Infect.* 2016;22(11):946.e1-946.e8.
- Marzano A, Angelucci E, Andreone P, et al. Prophylaxis and treatment of Hepatitis B in immunocompromised patients. *Dig Liver Dis.* 2007;39(5):397-408.