

Sacral Fractures and Associated Injuries

Ricardo Rodrigues-Pinto, MD, PhD, FEBOT¹, Mark F. Kurd, MD²,
Gregory D. Schroeder, MD², Christopher K. Kepler, MD, MBA²,
James C. Krieg, MD², Jörg H. Holstein, MD, PhD³, Carlo Bellabarba, MD⁴,
Reza Firoozabadi, MD⁴, F. Cumhuri Oner, MD, PhD⁵,
Frank Kandziora, MD, PhD⁶, Marcel F. Dvorak, MD⁷, Conor P. Kleweno, MD⁸,
Luiz R. Vialle, MD, PhD⁹, S. Rajasekaran, MD, PhD¹⁰,
Klausa J. Schnake, MD¹¹, and Alexander R. Vaccaro, MD, PhD, MBA²

Abstract

Study Design: Literature review.

Objective: The aim of this review is to describe the injuries associated with sacral fractures and to analyze their impact on patient outcome.

Methods: A comprehensive narrative review of the literature was performed to identify the injuries associated with sacral fractures.

Results: Sacral fractures are uncommon injuries that result from high-energy trauma, and that, due to their rarity, are frequently underdiagnosed and mistreated. Only 5% of sacral fractures occur in isolation. Injuries most often associated with sacral fractures include neurologic injuries (present in up to 50% of sacral fractures), pelvic ring disruptions, hip and lumbar spine fractures, active pelvic/ abdominal bleeding and the presence of an open fracture or significant soft tissue injury. Diagnosis of pelvic ring fractures and fractures extending to the lumbar spine are key factors for the appropriate management of sacral fractures. Importantly, associated systemic (cranial, thoracic, and abdominopelvic) or musculoskeletal injuries should be promptly assessed and addressed. These associated injuries often dictate the management and eventual outcome of sacral fractures and, therefore, any treatment algorithm should take them into consideration.

Conclusions: Sacral fractures are complex in nature and often associated with other often-missed injuries. This review summarizes the most relevant associated injuries in sacral fractures and discusses on their appropriate management.

Keywords

sacral fractures, associated injuries, neurologic injuries, musculoskeletal injuries, systemic injuries, diagnosis, management

¹ Centro Hospitalar do Porto, Hospital de Santo António, Porto, Portugal

² Rothman Institute, Thomas Jefferson University, Philadelphia, PA, USA

³ Institute for Clinical & Experimental Surgery, University of Saarland, Homburg/Saar, Germany

⁴ Harborview Medical Center, University of Washington School of Medicine, Seattle, WA, USA

⁵ University Medical Center, Utrecht, Netherlands

⁶ Berufsgenossenschaftliche Unfallklinik Frankfurt, Center for Spinal Surgery and Neurotraumatology, Frankfurt am Main, Germany

⁷ University of British Columbia, Vancouver, British Columbia, Canada

⁸ R. Adams Cowley Shock Trauma Center, University of Maryland School of Medicine, Baltimore, MD, USA

⁹ Cajuru University Hospital, Catholic University of Parana, Curitiba, Brazil

¹⁰ Ganga Hospital, Coimbatore, Tamil Nadu, India

¹¹ Schön Klinik Nürnberg Fürth, Center for Spinal Surgery, Fürth, Germany

Corresponding Author:

Ricardo Rodrigues-Pinto, Department of Orthopaedics, Centro Hospitalar do Porto, Hospital de Santo António, Largo Prof. Abel Salazar, Porto 4099-001, Portugal.

Email: ric_pinto@hotmail.com



Introduction

Sacral fractures are complex in nature and pose diagnostic challenges and technical difficulties for treatment. Because of their relative rarity and heterogeneous nature, they are frequently misdiagnosed and not properly treated. Adding to the complexity of these fractures there is little supporting literature on diagnosis and management, with no level 1 or 2 studies published to date and a myriad of classification systems available. For this reason, treatment is often determined on a case-by-case basis, and this may be influenced significantly by the attending surgeons training (ie, spine surgeon vs orthopedic trauma surgeon). One of the critical differences between sacral fractures and other fractures of the spinal column is that sacral fractures rarely occur in isolation. Only 5% of sacral fractures occur as isolated injuries, and up to 45% occur with a concomitant pelvic ring injury.¹ Furthermore, the associated injuries are often one of the critical factors that determine the outcome of patients with sacral fractures.² Because of this, it is essential that any treatment algorithm for sacral fractures account for these injuries. The purpose of this article is to review the evaluation of sacral fractures briefly and to identify the most common injuries that are associated with sacral fractures.

The Sacrum

The sacrum is the mechanical nucleus of the axial skeleton, located at the base of the lumbar spine and acts as the keystone at the center of the pelvic ring. The origin of its name has been suggested to derive from ancient cultures where the sacrum, being the seat of the organs of procreation, was the part of the animal offered for sacrifice, although it has also been suggested that this interpretation is erroneous, with the name deriving from a mistranslation of the Greek *hieron osteon* ("strong bone").

The sacrum transmits axial loads from the trunk to the lower limbs and protects the lumbosacral (L4-S1) and sacral (S2-S4) plexi and iliac vessels. It is a kyphotic structure formed by the fusion of 5 sacral vertebrae, with an angulation that varies from 10° to 90°. This angulation contributes to the inclination of the superior endplate of the sacrum and to the pelvic incidence, which then influence the lordosis of the lumbar spine.³

Sacral stability is highly dependent on the strong ligamentous structures of the pelvic ring. The soft tissue envelope around the sacrum is relatively thin, consisting of the multifidus muscle and the lumbosacral fascia, making this region particularly susceptible to infection, skin breakdown, and hardware-related complications.

The neural structures at risk after a sacral fracture are the cauda equina, filum terminale, the sacral plexus, and the sciatic nerve. Additionally, while the L5 nerve root exits the spinal canal cephalad to the sacrum, it travels along the anterior surface of the S1 vertebral body and sacral ala, so it is also commonly injured during injuries to the sacrum.

The sacral spinal canal is large, providing sufficient space for the cauda equina. The sacral foramina are also relatively

large in comparison with the sacral nerve roots; the S1 and S2 nerve roots occupy approximately one-third to one-fourth of their corresponding foramina, and the S3 and S4 nerve roots occupy approximately one-sixth of their respective foramina. For this reason, the S1 and S2 nerve roots are at higher risk of injury after a sacral fracture compared with the S3 and S4 roots.⁴ Importantly, an injury to the anterior rami of S2 to S5 nerve roots can lead to significant morbidity, as these nerves are critical in bowel and bladder control (parasympathetic innervation) as well as sexual function. Comparatively, an injury to the posterior rami of the sacral nerve roots is less debilitating, as the primary function of the posterior rami is to provide sensation to the buttocks via the cluneal nerves.^{4,5}

Sacral Fractures

Epidemiology

Sacral fracture incidence follows a bimodal distribution. They can occur as a result of high-energy trauma or as a result of low-energy trauma in patients with metabolic or neoplastic processes and elderly patients suffering from osteoporosis. Fifty-seven percent of these fractures are the result of motor vehicle accidents, 18% from motor vehicles striking pedestrians, 9% from fall from heights, 9% from motorcycle accidents, and 4% from crush injuries to the pelvis.^{4,6}

Clinical Presentation

A high index of suspicion should be maintained in the presence of high-energy trauma and/or pelvic pain or lacerations, bruising, swelling or ecchymosis.

Because of the frequent high-energy nature of these injuries, isolated sacral fractures are rare⁷ and associated life-threatening injuries dominate the initial clinical picture; their assessment should follow the advanced trauma life support (ATLS) protocols.⁸

A thorough pelvic examination should be conducted by assessing the stability of the pelvis and applying gentle rotational forces to the iliac wings⁹ and by comprehensively and repeatedly performing a neurologic examination. It should, however, be noted that due to the nature of these fractures, neurologic testing is frequently delayed as a large proportion of patients are intubated at the time of admission.¹⁰

Rectal examination should include maximum voluntary rectal sphincter contraction, assessment of pinprick and light touch sensation along the perianal region (S2-S5). The following reflexes should be tested: perianal wink and bulbocavernosus and cremasteric reflexes in men; in women with a concomitant anterior ring injury, a vaginal examination should also be performed to ensure there is no communication between the fracture and the vagina. Cauda equina injury should be excluded by assessing the rectal tone, perianal sensation, as well as a full lower extremity motor and sensory exam. A mechanical injury to the genitourinary system as seen in pelvic ring disruptions should also be evaluated. If injury is

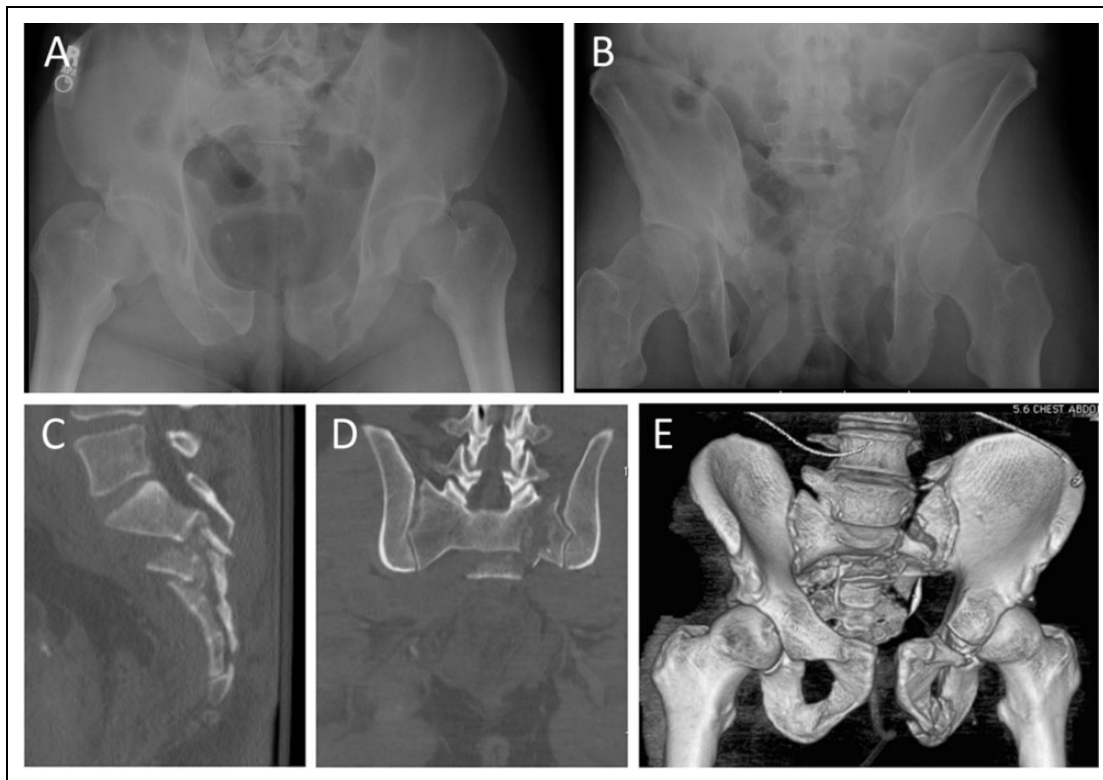


Figure 1. (A, B) Plain radiographs of a 53-year-old male with an unstable pelvis fracture. While it is visible on the radiographs, the complexities of the fracture are much more apparent on the sagittal (C), coronal (D), and 3-dimensional reconstruction (E) images from a computed tomography scan.

found or suspected, urologic and gynecologic consultations should be obtained.

Because of the close proximity of the sacrum with the iliac vessels, vascular examination of the lower extremities should be performed, especially in the setting of a neurologic injury. This examination should include evaluation of distal pulses and the measurement of ankle-brachial indexes. If a difference is noted, a lower extremity angiogram should be performed.

Diagnosis and Imaging Modalities

Denis et al⁴ in their seminal retrospective study of 236 sacral fractures, found that 30% of all sacral fractures were missed or diagnosed late; fractures were more commonly identified when associated with a neurological injury (76% detection rate) with only 51% of those fractures being detected in neurologically intact patients. Misdiagnosis, however, leads to progressive deformity, loss of function, and neurologic deterioration,¹¹ and delayed treatment is often associated with less favorable results.¹² Hence, appropriate diagnosis and treatment of sacral fractures and its associated injuries is paramount to restore function in these patients.

ATLS guidelines recommend an anteroposterior (AP) radiograph of the pelvis in the setting of a suspected sacral fracture.⁸ However, given the inclination of the sacrum, this view provides limited appreciation of osseous anatomy of the sacrum. Roult and colleagues¹² have recommended performing inlet

and outlet pelvic ring views as better imaging modalities for assessing pelvic and sacral trauma. Nork and colleagues¹³ identified a fracture of the L5 transverse process in 61% of patients with sacral fractures and a paradoxical inlet view in the supine AP radiograph of 92% of patients with sacral fractures, and in almost all sacral fractures with a transverse component. While significant literature has been dedicated to identifying sacral fractures on radiographs, a computed tomography (CT) scan is mandatory as plain radiographs may miss up to 50% of sacral fractures, and even if a sacral fracture is identified on radiographs, the complexities of the fracture are much more clearly seen on a CT scan (Figure 1).^{3,14} CT scans should not only be reviewed for bony injuries but they should also be assessed for soft tissue findings. Morel-Lavellée lesions and air on pelvic CT scan should increase suspicion for soft tissue injuries that need to be addressed.¹⁵

Associated Injuries

Sacral fractures are often associated with other injuries, some of which may endanger the patient's life. In a prospective study analyzing 100 patients with pelvic fractures, Lunsjo and colleagues² found that the associated injuries (assessed by the Injury Severity Score) and not fracture stability were the most important predictors in defining mortality in these patients. For that reason, adequate assessment of such associated injuries and their prompt treatment is mandatory, as the management

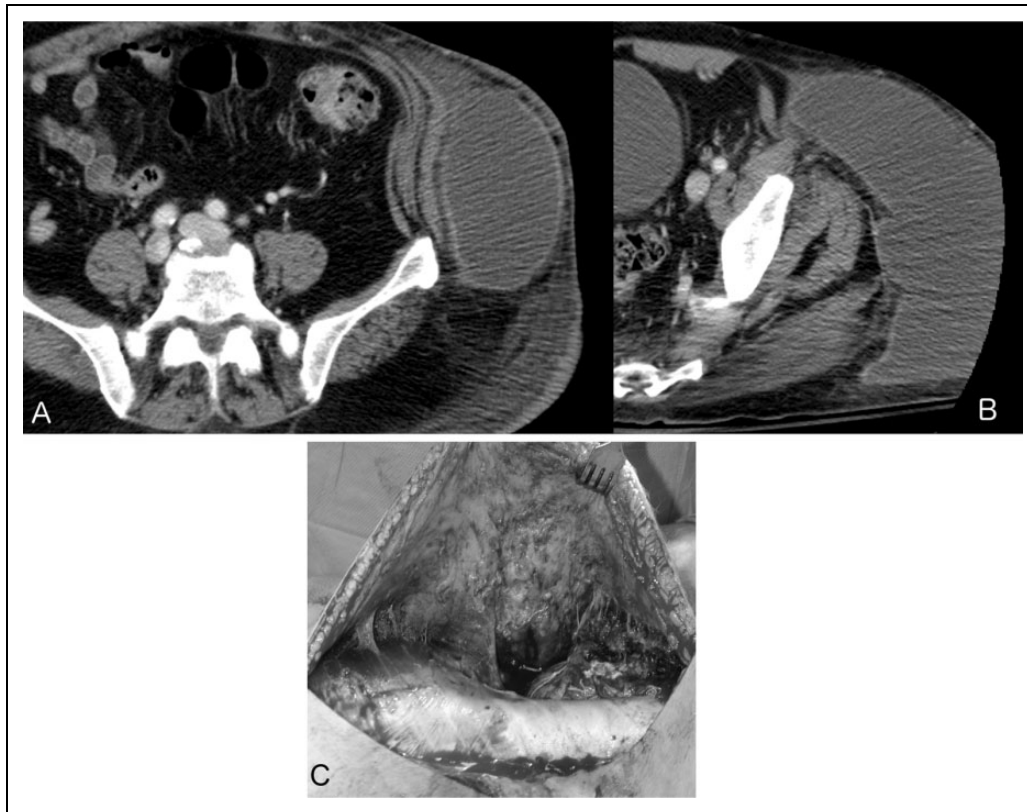


Figure 2. Maurel-Lavellee lesion: Images (A) and (B) demonstrate a large fluid collection associated with the fascial degloving on axial compute tomography scan. It is important to note that this lesion is much better seen on the soft tissue window as opposed to the bone windows, which are used to evaluate the fracture. Image (C) demonstrates the intraoperative findings of a Maurel-Lavellee lesion.

of sacral fractures cannot be dissociated from the management of such associated injuries.

Active Bleeding

Because of close proximity to the sacrum, iliac vessels, the anterior perisacral venous plexus and the superior gluteal artery may be injured in a sacral fracture, leading to hemodynamic instability.¹⁶ Hemodynamic assessment of the patient with a suspected sacral/pelvic fracture and prompt management is, therefore, mandatory.

Provisional stabilization of the pelvic ring may aid in controlling hemorrhage and in resuscitating the patient. However, because of the association between sacral fractures and injury to other structures, it may be difficult to dissociate fracture bleeding from that of other structures. Thoraco-abdomino-pelvic CT, often with intravenous contrast, as well as abdominal ultrasonography may be helpful in identifying additional sources of bleeding. However, intravenous contrast may obfuscate radiographs of the pelvis until the contrast dye is cleared from the bladder. If no other source of bleeding is identified in a patient in shock, immediate pelvic stabilization should be performed with a sheet, pelvic binder, or a pelvic clamp. When patients require surgery for open wounds or intra-abdominal bleeding, pelvic stabilization should be performed under the same anesthesia with the use of external fixators. For those

patients with persistent hemodynamic instability after pelvic stabilization and exclusion of an additional source of bleeding, selective embolization, pelvic packing, or both, should be employed.^{17,18}

Presence of Open Fracture or Significant Soft Tissue Injury

Because of the vulnerable soft tissue coverage around the pelvis and the high-energy nature of sacral fractures, they may be associated with substantial soft tissue injuries or even frank open fractures. Open sacral fractures are frequently type IIIA,³ as described by Gustilo and Anderson.¹⁹ An open sacral fracture is in direct communication with the skin, rectum, or vagina and, for this reason, as part of the patient assessment, a rectal and vaginal examination should be performed to detect occult open fractures. Violation of the rectal or vaginal vault or contamination from a concomitant urogenital injury occurs in severe open injuries and such injuries must be detected early so prompt irrigation and debridement can be performed. Treatment involves bladder drainage by cystostomy and bowel diversion by colostomy.^{20,21}

A particular type of soft tissue injury is the Morel-Lavellée lesion (Figure 2),²² which is a fascial degloving which occurs in response to a shearing force. In this lesion, the skin and subcutaneous fat tissue separate from the underlying fascia

creating a cavity that is filled with blood, serous fluid, or necrotic tissue. The vascular supply to the skin becomes compromised and dependent solely on the subdermal plexus, making the skin prone to infection and necrosis. While these are technically closed injuries, they are challenging to treat and pose a significant risk of infection.²² Although there is no high-level evidence to guide the treatment of this soft tissue injury, a recent systematic review suggested that surgical intervention was better than nonoperative measures, and that surgery should consist of local suction drainage or open debridement with dead space closure during fracture fixation.²³

Neurological Injury

Neurologic injury is the major determinant of the patient's quality of life following sacral trauma.^{3,24} Additionally, the severity of neurologic injury is often an indicator of the extent of the sacral injury, as high-energy mechanisms are required to disrupt the strong osseoligamentous sacral anatomy protecting the cauda equina and the lumbosacral and sacral plexi.²⁵ Furthermore, neurologic status may be the single most important factor determining surgical intervention, as the presence of progressive neurologic impairment is an indication for immediate surgery.²⁵ However, because of the complex nature of sacral fractures, the fact that neurologic deficits in this region can spare the lower extremities and involve only less obvious dysfunction of the bowel and bladder, the unclear benefit of a direct decompression and because life-threatening injuries often dominate the initial clinical picture, neurologic status is frequently overlooked.

Neurological injury, however, can occur in up to one-fourth of patients with sacral fractures^{1,4} and may range from isolated nerve root injuries to cauda equina syndrome. Injury to the L5 nerve root as it exits above the S1 vertebra or along the anterior aspect of the sacral ala can lead to motor deficits in foot dorsiflexion as well as sensory changes in the lateral calf and foot dorsum. Injury to the S1 and S2 nerve roots leads to motor deficits in hip abduction and ankle plantar flexion, as well as sensory changes in the posterior thigh, leg, sole, and lateral aspect of the foot and genitalia. The S2 to S5 nerve roots have little contribution for lower limb movement and sensation. Lesions to these nerve roots are manifested by bowel, bladder, and sexual impairment. For this reason, these lesions are frequently underdetected during the initial trauma evaluation and only become evident days or weeks after the injury.²⁶ The ventral rami of S2, S3 and S4 contribute to the pudendal nerve, which provides sensation to the external genitalia, to the skin around the anus and perineum, as well as motor control of the urethral sphincter and external anal sphincter.²⁷ The S3 nerve root is also involved in the sensation of the upper medial thigh. S2 to S4 nerve roots are also involved in the parasympathetic control of bladder and rectal function and sympathetic control of urethral and anal sphincter contraction.

In their study, Denis et al⁴ divided fractures into 3 zones based on their relationship to the neuroforamen. Zone I fractures are located lateral to the foramen; zone II fractures

Table 1. Gibbons Classification of Neurologic Injury.³⁰

Type	Neurologic deficit
1	None
2	Paresthesias only
3	Lower extremity motor deficit
4	Bowel/bladder dysfunction

traveling through the foramen, and zone III fractures traveling medial to the foramen. They identified neurological injuries in 51 of 236 patients (21.6%). Injuries were more frequent in Denis Zone III (56.7%) fractures, followed by zone II (28.4%) and zone I (5.9%). In agreement with the findings by Denis et al, Ebraheim and colleagues²⁸ found that 7 out of 8 patients with zone III fractures had complete loss of bowel and bladder function and 5 out of 8 had sexual dysfunction. Importantly, almost all fractures medial to the foramen associated with neurologic injuries contain a transverse fracture pattern; while rare (1.4% of all sacral fractures), sagittal fractures medial to the foramen without a transverse component rarely lead to neurologic injuries.²⁹

The type of neurologic impairment is also associated with the fracture geometry and orientation. While fractures involving the foramina can be associated with radiculopathy, particularly at S1 and S2, transverse sacral fractures are more frequently associated with cauda equina syndrome or lumbosacral or sacral plexus dysfunction.^{11,26,28} For bladder dysfunction to occur, however, bilateral sacral nerve root injuries must occur. Vertical sacral fractures are less frequently associated with neurologic injury, possibly due to the propensity to occur in the lateral alar zone. The Gibbons classification of neurologic injury is frequently used to classify the degree of neurologic deficit in sacral fractures (Table 1).³⁰

Most neurologic injuries may improve with time (although often not completely), independent of the choice of treatment. While some authors have reported that a posterior sacral laminectomy may provide the best chance for neurologic recovery,^{4,31} no high-level study directly comparing a formal sacral laminectomy to an indirect decompression through fracture reduction has been published to date.

Associated Pelvic Ring and Spinal Injuries

Isolated sacral fractures are uncommon, and most sacral fractures occur in association with pelvic ring or with other spinal injuries. Sacral fractures occur in association with some form of pelvic fracture in 80% to 90% of cases. Pelvic ring fractures have been extensively studied and several classifications such as the Letournel,³² Tile,⁹ Young and Burgess,³³ and the AO-ASIF exist. Importantly, when significant instability of the pelvic ring exists, immediate provisional fixation is indicated to stabilize the fracture and minimize blood loss.

Spinal injuries should always be ruled out in the presence of sacral fractures, particularly after high-energy trauma. A prevalence of up to 62% of associated spinal fractures has been

reported in transverse sacral fractures, with the most common being compression or dislocation fractures at the thoracolumbar junction (25%), followed by compression or dislocation fractures of the lower lumbar spine (11%).³⁴

Injuries at the lumbosacral junction require high-energy trauma, capable of disrupting the strong lumbosacral ligaments. Lumbosacral injuries should be suspected in all sacral fractures traversing the neural foramina, especially those that are displaced. In such cases, the lumbar sacral junction should be evaluated using CT scan. Displacement can range from lumbosacral subluxation to complete lumbopelvic dissociation. Isler³⁵ was the first to report the occurrence of such injuries and stated that they were found in relation to vertical fractures running medially or directly through the articular process of S1. He reported that these lesions occur in 38% of vertical unstable sacral fractures and in 3.5% of the sacral fractures exhibiting rotatory instability. Isler classified such lesions into type A (lateral to the L5-S1 facet joint), type B (extending through the L5-S1 facet joint) and type C (violating the spinal canal). Type A fractures may affect pelvic ring stability but almost never affect lumbosacral stability, type B fractures are associated with a variety of displacements and neurological injuries and type C fractures are unstable and require surgical stabilization.

Lumbosacral dislocations are often fatal lesions that may occur in association with sacral fractures and are characterized by a traumatic anterolisthesis of L5 on S1.³⁶ There are only a few cases of such fractures reported to date, but any patient who suffers this injury requires surgical stabilization.

Associated Systemic and Musculoskeletal Injuries

Besides the aforementioned neurologic injuries, sacral fractures may be associated with injuries caused by direct trauma to intrapelvic structures and organs in the vicinity of the sacrum, such as the rectum and sigmoid colon and the bladder and urethra. Associated injuries may be more distant and be inherent to the high-energy trauma, such as a brain injury, lower and upper extremity fractures, chest wall injuries, pulmonary and cardiac trauma, and noncontiguous spine fractures.^{37,38} As sacral injuries can vary from a low energy insufficiency fracture to a U-type fracture with lumbopelvic dissociation, the associated injuries are largely dependent on the type of sacral fracture. Pubic rami fractures are among the most frequently associated musculoskeletal injuries associated with sacral insufficiency fractures, with Aretxabala et al³⁹ reporting 78% of patients have pubic rami fractures concomitantly with sacral insufficiency fractures. In a study of 25 patients with sacral insufficiency fractures, Schindler et al⁴⁰ reported that 14 patients had an associated pubic ramus fracture, and one patient had an associated fracture of the ilium, but no extremity or visceral injuries were reported. Comparatively, in a study investigating associated injuries in 32 patients with unstable sacral fractures that required surgical stabilization, Totterman and colleagues¹⁰ identified that they were most frequently associated with lower limb and visceral injuries

(15 patients), followed by upper limb (13 patients), spine (10 patients), and head and chest (7 patients) injuries. The most frequent lower limb injuries were femur (4 patients), tibia (4 patients), acetabulum (3 patients), ankle (3 patients), and calcaneus (3 patients) fractures. Trauma to the abdominal viscera involved the liver (5 patients), kidney (4 patients), and spleen (3 patients). Most frequent upper limb injuries were humeral (5 patients), scapular (4 patients), and forearm fractures (4 patients). Injuries affecting the spine were located in the thoracolumbar region in all but one patient. The most frequently identified head injuries were cerebral contusion (3 patients) and subdural hematoma (2 patients). Finally, injuries to the chest wall were most frequently a pneumothorax (3 patients) or a pulmonary contusion (3 patients).¹⁰ The likelihood of having a significant associated injury is increased further in U-shaped sacral fractures. Schildhauer et al⁴¹ reported on 19 patients with displaced sacral fractures associated with lumbopelvic dissociation, and 63% had an associated extremity fracture; 52% had an anterior pelvic ring fracture, and 47% had a noncontiguous spinal fracture. Additionally, 42% had an injury to the abdominal viscera; 37% had a thoracic injury and 21% had a closed head injury.⁴¹ Additionally, in a study analyzing 7 patients with U-shaped sacral fractures, Porrino and colleagues⁴² identified associated pubic ramus fractures in 5, spine fractures in 4, visceral injuries in 3, lower limb fractures in 3, and upper limb fractures in 2 patients.

Treatment

General Principles

Treatment of sacral fractures should always take into consideration associated systemic or musculoskeletal injuries, osteoporosis, the presence of brain injury, obesity, the patient's physiological age, and past medical history. Aggressive surgical treatment may lead to surgical blood loss and hemodynamic instability, cardiopulmonary compromise, soft tissue breakdown, and an increased infection risk in the metabolically challenged patient. Only a multidisciplinary approach between the trauma team and subspecialists will dictate the most appropriate management for these patients, and recent data has shown that best outcomes are obtained when these fractures are cared for at level 1 trauma centers.⁴³

Assessment of associated injuries at the time of initial evaluation is mandatory and may dictate patient management. Importantly, it should be assessed whether the treatment of the sacral fracture will have an impact on the associated injuries and whether the treatment of the associated injury will affect the outcome of the sacral injury (protected weightbearing, for example).

Mehta and colleagues⁶ recommended that treatment of sacral fractures should be determined by the following clinical considerations: (1) associated stable or unstable pelvic ring fracture, (2) associated lumbosacral facet injury, (3) associated lumbosacral dislocation, and (4) neurologic injury and cauda equina or spinal cord compression.

Associated Pelvic Ring Injuries

When instability of the pelvic ring is present temporary reduction (with skeletal traction, c-clamp, external fixator, or a pelvic binder) is indicated to minimize blood loss. Sacral fractures with a stable pelvic ring and without neurological injuries are often treated conservatively with initial bed rest followed by progressive weightbearing.⁶

Associated Lumbosacral Facet Injuries

Lumbosacral injuries, which should be sought for in the presence of transforaminal sacral fractures should be treated surgically as failure to recognize and treat these injuries may lead to lumbosacral incongruence and pain.^{44,45}

Associated Lumbosacral Dislocation

Lumbosacral dislocation is a rare and often fatal injury that results in a traumatic lumbosacral spondylolisthesis. Only small series of cases have been described in the literature and, therefore, no standardized treatment can be defined. Nork and colleagues¹³ describe a series of 13 cases in which the fracture was stabilized in situ with percutaneous screws.

Associated Neurologic Injury

While surgical decompression is recommended in the presence of a neurologic deficit,⁶ 80% of neurological improvement has been reported regardless of the type of operative or nonoperative management.³

Treatment needs to be determined on an individual basis and the potential benefits of neural decompression, stabilization and patient mobilization should be carefully weighed against the risks inherent to surgery in these patients, such as blood loss, infection, and anesthesia-related complications.

Despite optimal management, sacral fractures are associated with considerable morbidity, particularly neurologic sequelae, bladder dysfunction and chronic pain. Adelved et al,⁴⁶ in a long-term follow-up of 13 patients with traumatic lumbosacral dissociation, found low SF-36 (Short Form-36 health questionnaire) scores and frequent reports of limitations in sexual activities.

Conclusion

In conclusion, sacral fractures are complex and frequently overlooked. Late identification and inadequate treatment may, however, lead to painful deformity and neurologic dysfunction. Sacral fractures rarely occur in isolation, being frequently associated with other injuries, particularly active bleeding, neurologic injury, pelvic and lower extremity fractures, open fractures, and soft tissue injuries, as well as injuries to intra-abdominal and pelvic organs and thoracic and brain injuries. The assessment and management of these associated injuries are mandatory, since they may pose life-threatening risks to the patient. The timing and type of treatment (conservative or

surgical, with or without neural decompression and/ or fixation) should be dictated not only by the pattern and stability of the sacral fracture but also by the associated injuries in a multidisciplinary manner.

Declaration of Conflicting Interests

The author(s) declared no potential conflicts of interest with respect to the research, authorship, and/or publication of this article.

Funding

The author(s) received no financial support for the research, authorship, and/or publication of this article.

References

1. Bonnin JG. Sacral fractures and injuries to the cauda equina. *J Bone Joint Surg.* 1945;27:113-127.
2. Lunsjo K, Tadros A, Hauggaard A, Blomgren R, Kopke J, Abu-Zidan FM. Associated injuries and not fracture instability predict mortality in pelvic fractures: a prospective study of 100 patients. *J Trauma.* 2007;62:687-691.
3. Vaccaro AR, Kim DH, Brodke DS, et al. Diagnosis and management of sacral spine fractures. *Instr Course Lect.* 2004;53:375-385.
4. Denis F, Davis S, Comfort T. Sacral fractures: an important problem. Retrospective analysis of 236 cases. *Clin Orthop Relat Res.* 1988;(227):67-81.
5. Sasso RC, Vaccaro AR, Chapman JR, Best NM, Zdeblick TA, Harris MB. Sacral fractures. *Instr Course Lect.* 2009;58:645-655.
6. Mehta S, Auerbach JD, Born CT, Chin KR. Sacral fractures. *J Am Acad Orthop Surg.* 2006;14:656-665.
7. Pohlemann T, Gänsslen A, Tschern H. The problem of the sacrum fracture. Clinical analysis of 377 cases [in German]. *Orthopade.* 1992;21:400-412.
8. Radvinsky DS, Yoon RS, Schmitt PJ, Prestigiacomo CJ, Swan KG, Liporace FA. Evolution and development of the Advanced Trauma Life Support (ATLS) protocol: a historical perspective. *Orthopedics.* 2012;35:305-311.
9. Tile M. Pelvic ring fractures: should they be fixed? *J Bone Joint Surg Br.* 1988;70:1-12.
10. Totterman A, Glott T, Madsen JE, Roise O. Unstable sacral fractures: associated injuries and morbidity at 1 year. *Spine (Phila Pa 1976).* 2006;31:E628-E635.
11. Schmidek HH, Smith DA, Kristiansen TK. Sacral fractures. *Neurosurgery.* 1984;15:735-746.
12. Routt ML Jr, Simonian PT, Swiontkowski MF. Stabilization of pelvic ring disruptions. *Orthop Clin North Am.* 1997;28:369-388.
13. Nork SE, Jones CB, Harding SP, Mirza SK, Routt ML Jr. Percutaneous stabilization of U-shaped sacral fractures using iliosacral screws: technique and early results. *J Orthop Trauma.* 2001;15:238-246.
14. Rommens PM, Vanderschot PM, Broos PL. Conventional radiography and CT examination of pelvic ring fractures. A comparative study of 90 patients. *Unfallchirurg.* 1992;95:387-392.
15. Scolaro JA, Wilson DJ, Routt ML, Firoozabadi R. Use of the initial trauma CT scan to aid in diagnosis of open pelvic fractures. *Injury.* 2015;46:1999-2002.

16. Teebken OE, Lotz J, Gansslen A, Pichlmaier AM. Bilateral iliac artery dissection following severe complex unstable pelvic fracture. *Interact Cardiovasc Thorac Surg.* 2008;7:515-516.
17. Suzuki T, Smith WR, Moore EE. Pelvic packing or angiography: competitive or complementary? *Injury.* 2009;40:343-353.
18. Langford JR, Burgess AR, Liporace FA, Haidukewych GJ. Pelvic fractures: part 1. Evaluation, classification, and resuscitation. *J Am Acad Orthop Surg.* 2013;21:448-457.
19. Gustilo RB, Anderson JT. Prevention of infection in the treatment of one thousand and twenty-five open fractures of long bones: retrospective and prospective analyses. *J Bone Joint Surg Am.* 1976;58:453-458.
20. Bjurlin MA, Fantus RJ, Mellett MM, Goble SM. Genitourinary injuries in pelvic fracture morbidity and mortality using the National Trauma Data Bank. *J Trauma.* 2009;67:1033-1039.
21. Ferrera PC, Hill DA. Good outcomes of open pelvic fractures. *Injury.* 1999;30:187-190.
22. Hak DJ, Olson SA, Matta JM. Diagnosis and management of closed internal degloving injuries associated with pelvic and acetabular fractures: the Morel-Lavallee lesion. *J Trauma.* 1997;42:1046-1051.
23. Shen C, Peng JP, Chen XD. Efficacy of treatment in peri-pelvic Morel-Lavallee lesion: a systematic review of the literature. *Arch Orthop Trauma Surg.* 2013;133:635-640.
24. Gribnau AJ, van Hensbroek PB, Haverlag R, Ponsen KJ, Been HD, Goslings JC. U-shaped sacral fractures: surgical treatment and quality of life. *Injury.* 2009;40:1040-1048.
25. Lehman RA Jr, Kang DG, Bellabarba C. A new classification for complex lumbosacral injuries. *Spine J.* 2012;12:612-628.
26. Fountain SS, Hamilton RD, Jameson RM. Transverse fractures of the sacrum. A report of six cases. *J Bone Joint Surg Am.* 1977;59:486-489.
27. Shafik A, el-Sherif M, Youssef A, Olfat ES. Surgical anatomy of the pudendal nerve and its clinical implications. *Clin Anat.* 1995;8:110-115.
28. Ebraheim NA, Biyani A, Salpietro B. Zone III fractures of the sacrum. A case report. *Spine (Phila Pa 1976).* 1996;21:2390-2396.
29. Bellabarba C, Stewart JD, Ricci WM, DiPasquale TG, Bolhofner BR. Midline sagittal sacral fractures in anterior-posterior compression pelvic ring injuries. *J Orthop Trauma.* 2003;17:32-37.
30. Gibbons KJ, Soloniuk DS, Razack N. Neurological injury and patterns of sacral fractures. *J Neurosurgery.* 1990;72:889-893.
31. Taguchi T, Kawai S, Kaneko K, Yugue D. Operative management of displaced fractures of the sacrum. *J Orthop Science.* 1999;4:347-352.
32. Letournel E. Surgical fixation of displaced pelvic fractures and dislocations of the symphysis pubis (excluding acetabular fractures) (author's translation) [in French]. *Rev Chir Orthop Reparatrice Appar Moteur.* 1981;67:771-782.
33. Burgess AR, Eastridge BJ, Young JW, et al. Pelvic ring disruptions: effective classification system and treatment protocols. *J Trauma.* 1990;30:848-856.
34. Robles LA. Transverse sacral fractures. *Spine J.* 2009;9:60-69.
35. Isler B. Lumbosacral lesions associated with pelvic ring injuries. *J Orthop Trauma.* 1990;4(1):1-6.
36. Vialle R, Wolff S, Pauthier F, et al. Traumatic lumbosacral dislocation: four cases and review of literature. *Clin Orthop Relat Res.* 2004;(419):91-97.
37. Albert TJ, Levine MJ, An HS, Cotler JM, Balderston RA. Concomitant noncontiguous thoracolumbar and sacral fractures. *Spine (Phila Pa 1976).* 1993;18:1285-1291.
38. Lykomitros VA, Papavasiliou KA, Alzeer ZM, Sayegh FE, Kirkos JM, Kapetanios GA. Management of traumatic sacral fractures: a retrospective case-series study and review of the literature. *Injury.* 2010;41:266-272.
39. Aretxabala I, Fraiz E, Perez-Ruiz F, Rios G, Calabozo M, Alonso-Ruiz A. Sacral insufficiency fractures. High association with pubic rami fractures. *Clin Rheumatol.* 2000;19:399-401.
40. Schindler OS, Watura R, Cobby M. Sacral insufficiency fractures. *J Orthop Surg (Hong Kong).* 2007;15:339-346.
41. Schildhauer TA, Bellabarba C, Nork SE, Barei DP, Routt ML Jr, Chapman JR. Decompression and lumbopelvic fixation for sacral fracture-dislocations with spino-pelvic dissociation. *J Orthop Trauma.* 2006;20:447-457.
42. Porrino JA Jr, Kohl CA, Holden D, Taljanovic M, Rogers LF. The importance of sagittal 2D reconstruction in pelvic and sacral trauma: avoiding oversight of U-shaped fractures of the sacrum. *AJR Am J Roentgenol.* 2010;194:1065-1071.
43. Morshed S, Knops S, Jurkovich GJ, Wang J, MacKenzie E, Rivara FP. The impact of trauma-center care on mortality and function following pelvic ring and acetabular injuries. *J Bone Joint Surg Am.* 2015;97:265-272.
44. Connolly PJ, Esses SI, Heggeness MH, Cook SS. Unilateral facet dislocation of the lumbosacral junction. *Spine (Phila Pa 1976).* 1992;17:1244-1248.
45. Oransky M, Gasparini G. Associated lumbosacral junction injuries (LSJIs) in pelvic fractures. *J Orthop Trauma.* 1997;11:509-512.
46. Adelved A, Totterman A, Glott T, Hellund JC, Madsen JE, Roise O. Long-term functional outcome after traumatic lumbosacral dissociation. A retrospective case series of 13 patients. *Injury.* 2016;47:1562-1568.