

PENTOXIFYLLINE AMELIORATES GLOMERULAR BASEMENT MEMBRANE ULTRASTRUCTURAL CHANGES CAUSED BY GENTAMICIN ADMINISTRATION IN RATS

NENAD STOJILJKOVIĆ^{1*}, SLAVIMIR VELJKOVIĆ¹,
DRAGAN MIHAILOVIĆ², MILAN STOILJKOVIĆ³,
GORAN RANKOVIĆ¹, IVAN JOVANOVIĆ⁴, PAVLE RANDJELOVIĆ¹

¹ Department of Physiology, Faculty of Medicine, University of Niš,
Bulevar Dr. Zoran Djindjić 81, 18000 Niš, Serbia

² Department of Pathology, Faculty of Medicine, University of Niš,
Bulevar Dr. Zoran Djindjić 81, 18000 Niš, Serbia

³ Department of Pharmacology and Toxicology, Faculty of Medicine,
University of Niš, Bulevar Dr. Zoran Djindjić 81, 18000 Niš, Serbia

⁴ Department of Anatomy, Faculty of Medicine, University of Niš,
Bulevar Dr. Zoran Djindjić 81, 18000 Niš, Serbia

* Corresponding author

ABSTRACT

Gentamicin is commonly used for the treatment of severe gram negative bacterial infections but inevitably cause renal failure during prolonged use. The aim of our study was to emphasize protective effects of pentoxifylline on glomerular basement membrane (GBM) alterations induced by gentamicin in rats. Experiments were done on 40 male Wistar rats divided in three experimental groups. GM-group was treated daily with gentamicin in dose of 100 mg/kg during 8 days. PTX-group was treated daily with pentoxifylline in dose of 45 mg/kg and the same dose of gentamicin as in GM-group during 8 days. The control group received 1 ml/day saline intraperitoneally. Morphometric parameter measured during the analysis was glomerular basement membrane thickness. In GM-group of animals glomeruli were enlarged and GMB was diffusely and unequally thickened with neutrophil cells infiltration. In proximal tubules epithelial cells, vacuolization of cytoplasm with coagulation-type necrosis were observed. In PTX-group of animals glomeruli were somewhat enlarged and GBM was thickened only in some segments. Coagulation-type necrosis was not found. Blood urea and serum creatinine concentration in GM-group were significantly elevated in comparison with PTX-group while potassium level was decreased. Our results suggest that PTX has protective effects on GBM and proximal tubules in GM-treated rats.

KEY WORDS: gentamicin, pentoxifylline, glomerular basement membrane, morphometry, rats.

INTRODUCTION

Gentamicin (GM) is an aminoglycoside antibiotic commonly used as an agent for the treatment of severe Gram-negative infections (1). Although nephrotoxicity as a major side effect of aminoglycosides accounting for 10–15% of all acute renal failure cases (2), the exact mechanisms of this adverse action still remain unclear. GM has been shown to enhance the generation of reactive oxygen species (ROS) (3, 4) which are putative causative agents of cell death in different pathological conditions including various models of renal diseases (5, 6, 7, 8). Accordingly, the administration of several compounds with antioxidant activity has been successfully used to prevent or ameliorate GM-induced nephrotoxicity (9, 10, 11, 12). The usage of gentamicin in clinical practice would be undoubtedly increased if potent protective agent for its undesirable kidney side effects could be found. Thus, a potential therapeutic approach to protect or reverse renal gentamicin damage would have very important clinical consequences (13). Pentoxifylline (PTX) is a hemorheological agent used in the treatment of peripheral vascular diseases. Recently, PTX has gained considerable interest as a ROS scavenger. Several in vitro studies have confirmed the potential antioxidant effects of this drug (14, 15, 16). Although its mechanism of action is not well understood, pentoxifylline decreases blood viscosity by altering erythrocyte deformability (17), reducing platelet aggregability and fibrinogen levels (18), and increasing neutrophil mobility (19). Also, pentoxifylline is a potent stimulator of prostacyclin in vascular beds (18) and like other xanthines such as theophylline, is an adenosine receptor antagonist (20). Therefore, PTX is a potent anti-inflammatory agent capable of ameliorating kidney inflammation by acting on various targets including the synthesis of pro-inflammatory cytokines and chemokines, as well as the growth and activation of inflammatory mononuclear cells. The aim of our experimental investigation was to determine the potential protective effect of pentoxifylline on glomerular basement membrane ultrastructural changes caused by gentamicin in rats.

MATERIAL AND METHODS

All studies were performed on adult male Wistar rats, weighing 250 – 300 g. Animals were housed in a central facility under controlled conditions (12 h light/dark cycle and room temperature of $20^{\circ}\text{C} \pm 2^{\circ}\text{C}$) and with free access to food and water. All experimental procedures were conducted in accordance with

the principles for the care and use of laboratory animals in research. The investigation conforms to the regulations of the European Union and USA Guide for the Care and Use of Laboratory Animals published by the National Institute of Health (National Academy of Science Press, Washington, DC, 1996).

Experimental protocol

The total number of 40 animals was divided in 3 groups, one of which was used as a sham control. The experimental group of animals or GM-group (15 rats) received gentamicin (Galenika AD, Belgrade, Serbia) intraperitoneally in a daily dose of 100 mg/kg.

PTX-group animals (15 rats) were treated daily with pentoxifylline (Jugoremedija A.D. Niš, Serbia) intraperitoneally in dose of 45 mg/kg and the same dose of gentamicin as in GM-group. The control group of animals or C-group (10 rats) received 1 ml/day saline intraperitoneally. Both experimental and control group were treated over the period of 8 consecutive days. Following the last application, nine days after the beginning of the experiment, all animals were anaesthetized using 80mg/kg ketamine (Ketamidol 10%, Richter Pharma AG, Wels, Austria) and then sacrificed. Immediately after vivisection 2ml blood from aorta was taken for biochemical analysis.

Histological analysis

The kidneys were sectioned and fixed in 10% paraformaldehyde (in 0,1 mol/dm³ phosphate buffer saline), dehydrated in graded alcohols and processed for paraffin wax embedding. Then, kidney slices were cut on 5 μm thick sections using HistoRange microtome (model: LKB 2218, LKB-Produkter AB, Bromma, Sweden) and stained with hematoxylin-eosin (HE), PAS (Periodic Acid Schiff) and Jones methenamine silver according to conventional staining protocols as described by Bancroft and Stevens (21).

Morphometric analysis

Histological slides were analyzed using light microscope (Olympus BX50, Tokyo, Japan) and Micro Image 3.0 (Olympus, Tokyo, Japan) image analysis and processing software were used for the morphometric analysis. Spatial calibration, by object micrometer (1:100), as well as optical density calibration was performed before each analysis. Morphometric parameter measured during the analysis was glomerular basement membrane thickness (μm). The glomerular basement membrane thickness was estimated as a mean distance after manual tracing of two lines along both sides of

the basement membrane. In each animal at least 20 glomeruli were measured, excluding columns of Bertin.

Biochemical analysis

As previously mentioned, after finishing the experiment, blood samples were taken from aorta and analyzed for markers of renal impairment. Plasma creatinine, blood urea, sodium and potassium concentrations were measured using an automatic biochemical analyzer (A25 Biosystems, Barcelona, Spain).

Statistical analysis

Statistical analysis included estimation of mean values and standard deviation (SD) for parameters obtained during the morphometric and laboratory analysis. The statistical significance for the differences between the experimental and control group of animals' parameters was tested by Student's t – test using NCSS statistical software (NCSS Kaysville, Utah). In all cases, statistical significance was inferred for $p < 0,05$.

RESULTS

1. Histological analysis

The kidney sections taken from the experimental GM-group of animals showed areas of proximal tubule epithelial cells necrosis and apoptosis, vacuolization of cytoplasm and epithelial desquamation (Figure 1). Glomeruli were enlarged, glomerular basement membrane was irregularly thickened, with neutrophil cell infiltration. In the cytoplasm of viable proximal tubule epithelial cells numerous black dots ("myeloid bodies") were found in the sections stained with silver methenamine (Figure 2). In PTX-group of animals glomeruli were somewhat enlarged, and the glomerular basement membrane was thickened only in some segments of the glomer-

uli. Coagulation-type necrosis was not found. In some epithelial cells of proximal tubules dark inclusions and cytoplasm vacuolization were observed (Figure 3).

2. Morphometric analysis

The morphometric analysis of glomerular basement membrane thickness between animals from the experimental GM, PTX and control groups are presented in the (Table 1).

Variable	GM group	PTX group	Control group
Glomerular basement membrane thickness (μm)	0,84 \pm 0,18*#	0,639 \pm 0,08	0,57 \pm 0,15

Data are presented as mean \pm SD. * $p < 0,001$ vs. Control # $p < 0,001$ vs. PTX-group

TABLE 1. Glomerular membrane thickness (μm) in experimental and control group of rats.

Morphometric analysis of glomerular basement membrane thickness showed statistically significant differences between the control and the experimental GM and PTX groups (Table 1). The mean glomerular membrane thickness was significantly greater in gentamicin treated group of animals compared to PTX and control group of rats ($p < 0,001$) (Table 1). Glomerular basement membrane thickness of PTX-group of animals was greater than in control group of rats, but without statistical significance (Table 1).

3. Biochemical analysis

Using multivariate t-test, statistically significant differences were found for values of BUN and creatinine ($p < 0,001$). The mean values of BUN and creatinine serum concentrations found in GM and PTX groups of rats were statistically significantly elevated in comparison to the control group of rats ($p < 0,001$). The

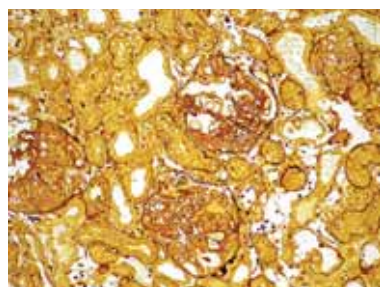


FIGURE 1. Necrosis and apoptosis, vacuolization of cytoplasm and epithelial desquamation of proximal tubule epithelial cells in GM-group of animals. Silver-methenamine staining method (magnification x 40).

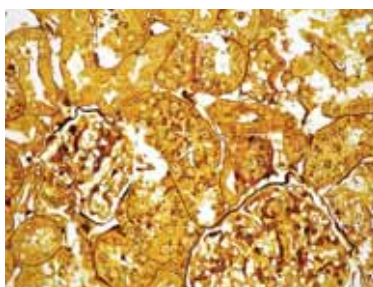


FIGURE 2. Enlarged glomeruli, glomerular basement membrane irregularly thickened and proximal tubules epithelial cells with numerous black dots ("myeloid bodies") in GM-group of animals. Silver-methenamine staining method (magnification x 40).

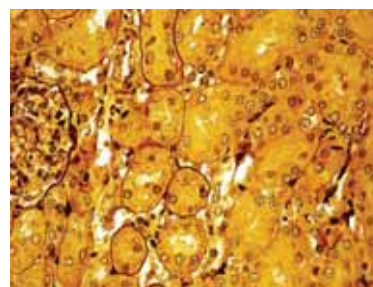


FIGURE 3. Somewhat enlarged glomeruli, glomerular basement membrane thickened only in some segments and dark inclusions in certain epithelial cells of proximal tubules in PTX-group of animals. Silver-methenamine staining method (magnification x 40).

mean values of serum potassium concentrations in GM-group were statistically significantly reduced in comparison with PTX and control groups ($p < 0,001$). The values of BUN and serum creatinine in GM-group were significantly elevated in comparison with PTX-group ($p < 0,001$).

Parameter	GM group	PTX group	Control group
Sodium (mEq/dm ³)	143,66±6,01	148,78±6,40	148,53±4,28
Potassium (mEq/dm ³)	4,16±0,83*#	5,80±0,45	5,71±0,36
BUN (µmol/dm ³)	47,58±6,69*#	19,79±4,24*	6,93±0,68
Creatinine (µmol/dm ³)	472,24±59,34*#	280,70±45,92*	62,55±7,08

Data are presented as mean ± SD. * $p < 0,001$ vs. Control # $p < 0,001$ vs. PTX-group

TABLE 2. Serum concentration of sodium, potassium, BUN, and creatinine in experimental and control groups of rats.

DISCUSSION

Because of its strong bactericidal effect, gentamicin is widely used antibiotic in the treatment of infections caused by gram-negative microorganisms. However, the ample data also speak of its nephrotoxic effect demonstrated in a numerous experimental studies in which gentamicin acute renal insufficiency was induced (22, 23). Oxidative stress is probably the most common pathogenic factor of cell damage in the complex pathogenesis of gentamicin nephrotoxicity. The data obtained from experiments suggest that both vascular (glomerular) and tubular targets are involved in drug-induced nephrotoxicity (24). In our study, gentamicin given in a supratherapeutic dose (100mg/kg) induced acute renal insufficiency (ARI) in rats. Pentoxifylline penetrates the kidney tissue, where it reduces the production of free oxygen radicals due to its anti-oxidant effect. When it is applied alone or together with the vitamin E, pentoxifylline shows satisfactory effects on renal damage (25, 26). The increased production of TNF-alpha which induces apoptosis (27) and other cytotoxins which are important factors of cellular proliferation and ECM synthesis of mesangial cells of glomeruli and interstitial fibroblasts can be prevented with pentoxifylline (28). These data suggest that pentoxifylline has an ameliorative effect on the course of experimental ARI, which is in accordance with the results of other authors (29, 30). The mechanism of amelioration probably involves the stimulation of renal vasodilator prostaglandins as well as the prevention of vascular congestion (31). On the other hand, it has been shown that PTX affects calcium homeostasis and inhibits calcium entry in the human erythrocyte (32). It

has been reported that calcium channel blockers are effective in the prevention of GM-induced nephrotoxicity (by inhibiting calcium accumulation in the kidney) (33). The most important effect of PTX in gentamicin nephrotoxicity is the increased blood flow through blood vessels which leads to significant improvement of the renal microcirculation. It also reduces the tubular dysfunction and glomerular filtration, which leads to the reduction of BUN and creatinine in plasma. The histopathological changes observed in GM-group of animals consisted of enlargement of glomeruli and glomerular basement membrane alterations with unequal thickness in some of its segments (34). The neutrophilic leucocytes were present in some glomeruli capillaries. The changes in the proximal tubules were dominant and manifested in the form of segmented necrosis of the coagulation type, cytoplasm vacuolization of tubular epithelial cells with preserved nuclei and multitude of dark inclusions ("myeloid body"). The structural changes in the distal tubules were not found. These changes mostly coincide with the changes already described by other authors (35, 36). The presence of neutrophils in the glomerular capillaries confirms that the renal microcirculation and glomerular hemodynamics were impaired by the administration of gentamicin. If the changes in the kidneys and glomeruli are primarily due to changed microcirculation and hemodynamics in the capillaries, the removal of those would abolish gentamicin effects in renal nephrotoxicity. The PTX-group of rats showed lesser morphological and functional kidney damage in comparison to the rats treated with gentamicin only. Glomeruli were insignificantly enlarged and the basement membrane of glomerular capillaries was thickened only in some segments of glomeruli. There were no signs of necrosis in the proximal tubules, but only vacuolization and the presence of dark inclusions were noted in the cytoplasm of some cells, which points out the protective effect of pentoxifylline. The glomerular basement membrane (GBM) is progressively formed by two membranes: the lamina rara interna (LRI; formed from the endothelial cells) and the lamina rara externa (LRE; formed from the pedicels of the epithelial cells), which fuse and generate a common lamina densa (LD) in the central part. In the rat neonate, all these stages can be observed, the first differentiated (older) nephrons being in the juxta - medullary area. The urine is formed in mature glomeruli by filtration through the GBM, which stops the large molecules, such as proteins. This permselectivity of the GBM is considered to be mainly due to an electrostatic shield made of highly negatively charged heparan sulfate proteoglycans con-

stituting the anionic sites situated in the LRI and LRE. Quantifying the GBM layers and anionic sites and dosing components of the extracellular matrix, Smaoui et al. (37) found that the developing GBM was abnormal in the treated neonates, and that morphological and functional alterations of the GBM were still present in the juxtamedullary glomeruli of the adult animals, i.e., 12-month-old rats, prenatally exposed to gentamicin. In the early stages of GBM maturation, the fibrillar material appeared more important in the LRE and LRI before they joined to form the LD; in later stages, the LD itself looked larger and denser. Morphometric analysis showed that the GBM layers were different from those of controls in treated neonates: the LRI and LRE were thinner while the LD was enlarged. The counting of anionic sites showed an increase of their number per square micrometer of the LRE or LRI and thus an increased density; glycosaminoglycans were more sulfated and quantita-

tively more abundant than in controls (37). Our results revealed that glomerular basement membrane thickness was significantly larger in gentamicin treated rats than in the control group, as previously described (34). Morphometric analysis revealed that GMB was highly significantly thickened in GM-group of rats, compared to control and PTX groups. The thickness of GBM was higher in PTX-group compared to control group of rats, but this difference was not statistically significant. In the GM-group of animals, the biochemical analysis showed the most significant increase in serum urea and creatinine as a sign of the functional alterations of kidney. This is rather customary having in mind that the above laboratory parameters and electrolytes are secreted predominantly by glomerular filtration. The values of serum creatinine and BUN in the PTX-group of rats were enhanced in relation to the control group but reduced in relation to the GM-group.

CONCLUSION

Our results suggest that PTX has ameliorative effects on GBM and proximal tubules in GM-treated rats.

Acknowledgment

This work was supported by the Ministry of Science Republic of Serbia grant 145004.

List of Abbreviations

GM	-	Gentamicin
PTX	-	Pentoxifylline
BUN	-	Blood urea nitrogen
ARI	-	Acute renal insufficiency
GBM	-	Glomerular basement membrane
LRI	-	Lamina rara interna
LRE	-	Lamina rara externa
LD	-	Lamina densa

REFERENCES

- (1) Ali B.H. Gentamicin Nephrotoxicity in humans and animals: some recent research. *Gen. Pharmac.* 1995; 26(7): 1477-1487.
- (2) Shifow A.A., Kumar K.V., Naidu M.U.R., Tarnakar K.S. Melatonin, a pineal hormone with antioxidant properties, protects against gentamicin-induced nephrotoxicity in rats. *Nephron.* 2000; 85: 167-174.
- (3) Cuzzocrea S., Mazzon E., Dugo L., Serraino I., Di Paola R., Britti D., De Sarro A., Pierpaoli S., Caputi A., Masini E., Salvemini D. A role for superoxide in gentamicin-mediated nephropathy in rats. *Eur. J. Pharmacol.* 2002; 450: 67-76.
- (4) Yanagida C., Ito K., Komiya I., Horie T. Protective effect of fosfomicin on gentamicin-induced lipid peroxidation of rat renal tissue. *Chem. Biol. Interact.* 2004; 148:139-147.
- (5) Shah S.V. Effect of enzymatically generated reactive oxygen metabolites on the cyclic nucleotide content in isolated rat glomeruli. *J. Clin. Invest.* 1984; 74: 393-401.
- (6) McCord J. M., Roy R. S., Schaffer S. W. Free radicals and myocardial ischemia. The role of xanthine oxidase. *Adv. Myocardiol.* 1985; 5: 183-189.
- (7) Grune T., Sommerburg O., Petras T., Siems W. G. Postanoxic formation of aldehydic lipid peroxidation products in human renal tubular cells. *Free. Radic. Biol. Med.* 1995; 18: 21-27.
- (8) Baliga R., Ueda N., Walker P. D., Shah S. V. Oxidant mechanisms in toxic acute renal failure. *Drug. Metab. Rev.* 1999; 31: 971-997.

- (9) Kopple J. D., Ding H., Letoha A., Ivanyi B., Qing D. P.-Y., Dux L., Wang H.-Y., Sonkodi S. L-carnitine ameliorates gentamicin-induced renal injury in rats. *Nephrol. Dial. Transplant.* 2002; 17(12): 2122-2131.
- (10) Pedraza-Chaverri J., Gonzalez-Orozco A. E., Maldonado P. D., Barrera D., Medina-Campos ON, Hernandez-Pando R. Diallyl disulfide ameliorates gentamicin induced oxidative stress and nephropathy in rats. *Eur. J. Pharmacol.* 2003; 473: 71-78.
- (11) Parlakpınar H., Tasdemir S., Polat A., Bay-Karbulut A., Vardi N., Ucar M., Yanilmaz M., Kavaklı A., Acet A. Protective effect of chelerythrine on gentamicin-induced nephrotoxicity. *Cell. Biochem. Funct.* 2006; 24(1): 41-48.
- (12) Mazzon E., Britti D., De Sarro A., Caputi A. P., Cuzzocrea S. Effect of N-acetylcysteine on gentamicin-mediated nephropathy in rats. *Eur. J. Pharmacol.* 2001; 424: 75-83.
- (13) Pedraza-Chaverri J., Maldonado P.D., Medina-Campos O., Oliveares-Corichi I. M., Grandos-Silvestre M. R., Hernandez-Pando R., Ibarra-Rubio M. E. Garlic ameliorates gentamicin nephrotoxicity: relation to antioxidant enzymes. *J. Free Radic. Biol. Med.* 2000; 29: 602-611.
- (14) Horvath B., Marton Z., Halmosi R., Alexy T., Szapary L., Vekasi J., Biro Z., Habon T., Kesmarky G., Toth K. In vitro antioxidant properties of pentoxifylline, piracetam, and vinpocetine. *Clin. Neuropharmacol.* 2002; 25(1): 37-42.
- (15) Bhat V. B., Madyastha K. M. Antioxidant and radicals scavenging properties of 8-oxo derivatives of xanthine drugs pentoxifylline and lisofylline. *Biochem. Biophys. Res. Commun.* 2001; 288(5): 1212-1217.
- (16) Freitas J. P., Filipe P., Guerra-Rodrigo F. Potential antioxidative effects of pentoxifylline. *CRSeances Soc. Biol. Fil.* 1995; 189(3): 401-405.
- (17) Bילו Y. Y., Player M., Stuart J. Rheological action of oxpentifylline and structurally-related xanthine derivatives on human erythrocytes. *Clin. Hemorheol.* 1988; 8: 213-221.
- (18) Weithmann K. U. Reduced platelet aggregation by pentoxifylline stimulated prostacyclin release. *VASA.* 1981; 10: 249-252.
- (19) Crocket K. Y., Lackie I. M., Rogers A. A. Effect of pentoxifylline on neutrophil behavior: stimulation of movement without adhesion changes. *Biomed. Pharmacother.* 1988; 42: 117-120.
- (20) Churchill P. C., Bidani A. K. Hypothesis: adenosine mediates hemodynamic changes in renal failure. *Med. Hypothesis.* 1982; 8: 275-285.
- (21) Bancroft J.D., Stevens A. *Theory and Practice of Histological Techniques*, Churchill Livingstone, Nottingham, 1996
- (22) Ademuyiwa O., Ngaha E.O., Ubah F.O. Vitamin E and selenium in gentamicin nephrotoxicity. *Hum. Exp. Toxicol.* 1990; 9: 281-288.
- (23) Kavutcu A., Canbolat O., Ozturk S., Olcay E., Ulutepe S., Ekinci C., Gokhun I.H., Durak I. Reduced enzymatic antioxidant defense mechanism in kidney tissues from gentamicin treated guinea pigs: Effects of vitamin E and C. *Nephron.* 1996; 72: 269-274.
- (24) Rodriguez-Barbero A., L'Azou B., Cambar J., Lopez-Novoa J.M. Potential use of isolated glomeruli and cultured mesangial cells as in vitro models to assess nephrotoxicity. *Cell. Biol. Toxicol.* 2000; 16: 145-153.
- (25) Brunner L.J., Vadiei K., Iyer L.V., Luke D.R. Prevention of cyclosporine-induced nephrotoxicity with pentoxifylline. *Ren. Fail.* 1989; 11(2-3): 97-104.
- (26) Akpolat T., Akpolat I., Ozturk H., Sarikaya S., Coşar A.M., Bedir A., Kandemir B. Effect of vitamin E and pentoxifylline on glycerol-induced acute renal failure. *Nephron.* 2000; 84(3): 243-247.
- (27) Kim Y.K., Choi T.R., Kwon C.H., Kim J.H., Woo J.S., Jung J.S. Beneficial effect of pentoxifylline on cisplatin-induced acute renal failure in rabbits. *Ren. Fail.* 2003; 25(6): 909-922.
- (28) Strutz F., Ziesberg M., Hemmerlein B. Basic fibroblast growth factor (FGF-2) expression is increased in human renal fibrogenesis and may mediate autocrine fibroblast proliferation. *Kidney Int.* 2000; 57: 1521-1538.
- (29) Kaputlu I., Sadan G., Karayalcin B., Boz A. Beneficial effects of pentoxifylline on cyclosporine-induced nephrotoxicity. *Clin. Exp. Pharmacol. Physiol.* 1997; 24(5): 365-369.
- (30) Savic V., Vlahovic P., Djordjevic V., Mitic-Zlatkovic M., Avramovic V., Stefanovic V. Nephroprotective effects of pentoxifylline in experimental myoglobinuric acute renal failure. *Pathol. Biol.* 2002; 50(10): 599-607.
- (31) Vadiei K., Brunner L.J., Luke D.R. Effects of pentoxifylline in experimental acute renal failure. *Kidney Int.* 1989; 36(3): 466-470.
- (32) Ellory J.C., Culliford S.J., Honvitz E.R., Mojiminiyi F.B.O., Stuart J. Oxpentifylline-induced inhibition of calcium entry into human erythrocytes. *Clin. Hemorheol.* 1994; 14: 545-555.
- (33) Stojiljković N., Veljković S., Mihailović D., Stoiljković M., Radovanović D., Randelović P. The effect of calcium channel blocker verapamil on gentamicin nephrotoxicity in rats. *Bosn. J. Basic Med. Sci.* 2008; 8(2): 170-176.
- (34) Stojiljkovic N., Mihailovic D., Veljkovic S., Stoiljkovic M., Jovanovic I. Glomerular basement membrane alterations induced by gentamicin administration in rats. *Exp. Toxicol. Pathol.* 2008; 60: 69-75.
- (35) Gilbert N. Aminoglycosides. In: *Principles and Practice of Infectious Disease*, 5th ed. (Eds. G.L. Mandell, J.E. Bennett, R Dolin.), pp. 307-336.
- (36) Churchill Livingstone, New York, 2000 Mingeot-Leclercq M.P., Tulkens P.M. Aminoglycosides: nephrotoxicity. *Antimicrob. Agents. Chemother.* 1999; 43: 1003-1012.
- (37) Smaoui H., Mallie J.P., Schaefferbeke M., Robert A., Schaefferbeke J. Gentamicin administered during gestation alters glomerular basement membrane development. *Antimicrob. Agents Chemother.* 1993; 37: 1510-1517.