

The evaluation of risk-benefit ratio for gut tissue sampling in HIV cure research

Vikram Mehraj^{1,2}, Peter Ghali³, Rayoun Ramendra^{1,2}, Cecilia Costiniuk^{1,2}, Bertrand Lebouché^{1,2,4}, Rosalie Ponte^{1,2}, Robert Reinhard⁵, Jose Sousa⁶, Nicolas Chomont^{7,8}, Eric A Cohen^{8,9}, Petronela Ancuta^{7,8} and Jean-Pierre Routy^{1,2,10*}

¹ Research Institute of the McGill University Health Centre, Montreal, QC, Canada

² Chronic Viral Illness Service, McGill University Health Centre, Montreal, QC, Canada

³ Division of Gastroenterology and Hepatology, McGill University Health Centre, Montreal, QC, Canada.

⁴ Department of Family Medicine, McGill University, Montreal, QC, Canada

⁵ Community Liaison, Canadian HIV Cure Enterprise (CanCURE), Montreal, QC, Canada

⁶ Community Advisory Committee, CIHR/CTN, Canada

⁷ Centre de recherche du CHUM, Montreal, QC, Canada

⁸ Department of Microbiology, Infectiology and Immunology, Université de Montréal, Montreal, QC, Canada

⁹ Laboratory of Human Retrovirology, Institut de Recherches Cliniques de Montréal (IRCM), Montreal, QC, Canada

¹⁰ Division of Hematology, McGill University Health Centre, Montreal, QC, Canada

Abstract

Introduction: Antiretroviral therapy (ART) does not cure HIV infection due to the persistence of HIV reservoirs in long-lived memory CD4 T cells present in the blood, lymph nodes, intestinal tract, and other tissues. Interest grows in obtaining gut-tissue samples for HIV persistence studies, which poses an ethical challenge to provide study volunteers with adequate information on risks and benefits. Herein we assess the risks and benefits of undergoing gut biopsy procedures for HIV pathogenesis and reservoir studies.

Methods: A group discussion was organised with physicians and community representatives on performing either a flexible sigmoidoscopy or a colonoscopy. Consensus was reached on conducting colonoscopy in persons ≥ 50 years. Thirty HIV-infected, ART-treated and nine uninfected participants were recruited. Colonoscopy was performed to collect 30 gut mucosal biopsies. When present, polyps were removed and abnormal mucosal findings were biopsied for pathological analysis. Participants were interviewed on potential discomfort following colonoscopic examination.

Results: The HIV-infected and uninfected groups were comparable in terms of age and gender with more men who have sex with men (MSM) in the former group. Abnormal colonoscopic findings were observed in 43.6% of all the participants and did not differ by HIV status. In total, 24 polyps were removed with a higher mean number of polyps removed in HIV-infected versus uninfected participants (1.7 vs 1.0, $P=0.013$). The number of polyps marginally correlated with inverted CD4:CD8 ratio. Based on our findings, colonoscopic examination was safe to use for gut biopsy procedures where almost half of the participants had polyps removed.

Conclusion: Participation in the study provided colon cancer screening as an ancillary benefit that participants could have received in standard medical care, thus mitigating burdens of invasive procedures. Dialogue between community representatives and clinical researchers can increase participation and advance HIV cure research.

Keywords: HIV cure research, colonoscopy, risks/benefits, polyps, gut mucosal biopsy, ageing

Introduction

Antiretroviral therapy (ART) has transformed the lives of individuals living with HIV by controlling viral replication, preventing the development of AIDS, and partially reducing the risk for inflammatory non-AIDS events [1,2]. Despite controlling plasma viraemia with suppressive ART, latent HIV reservoirs persist in blood and tissues representing the major barrier to an HIV cure.

Viral reservoirs consist of replication-competent proviruses that remain in long-lived latently infected CD4 T cells and possibly in myeloid cells of ART-treated individuals [3,4]. The size of the latent reservoir is influenced by several factors that include the nadir CD4 T cell count [5], the CD4:CD8 ratio [6], the time between infection and initiation of ART [7–10] and to a lesser extent, the duration of therapy [11].

Knowledge of HIV reservoirs has been acquired principally through studies on peripheral blood samples, whereas the majority of cells comprising the latent reservoir reside in solid tissues [12,13], with a potential of lower drug penetration [12–14]. Poles *et al.* have

reported more than twice the number of lymphoid cells in the gut-associated lymphoid tissue (GALT) compared with blood that contain potentially replication-competent HIV-1 DNA in individuals receiving ART [15]. They further reported a lack of decay of HIV-1 in GALT, which was similar to the blood. Recently, results from tissue-reservoir studies have suggested that the predominant total body reservoir may be composed of lymph node and intestine [16,17]. The intestine represents a unique site for HIV persistence as CD4 T cells are constantly exposed to the gut microbiota and express high levels of immune activation. Moreover, we have previously shown that CD4 T cells (Th-17) in the gut, specialised in host defence, are preferentially infected and constitute a significant reservoir [16].

Therefore, owing to the unmet need of the HIV cure agenda to understand persistence, efforts must increase to elucidate HIV reservoirs in tissues in order to design tissue-targeted immune intervention. The quest to access tissues in humans has been attempted by a few groups at different phases of infection. Such attempts included a handful of patients treated during the acute and chronic phases of infection [8], and a very few post mortem [18,19]. Chiu *et al.* recently characterised the safety of flexible sigmoidoscopies in clinical trial participants and reported no serious adverse events [20]. They further reported an adverse event rate of 1.6% per procedure that involved abdominal pain, diarrhoea, bleeding, flatulence and bloating.

*Corresponding author: Jean-Pierre Routy, McGill University Health Centre: Glen site
Research Institute, Block E, Suite EM 3-3232, Mezzanine 3M
1001 Boulevard Décarie, Montréal, QC H4A 3J1, Canada
Email: jean-pierre.routy@mcgill.ca

The growing need for the study of HIV reservoirs in tissues for more general and widespread research and with the help of numerous volunteers poses an ethical challenge when participants face uncertainty with respect to the risks and benefits in clinical studies aiming at viral eradication. Willingness to participate in HIV cure research may be influenced by type of intervention and tissue sampling. Determinants of participation have been generally assessed outside of the particulars of individual study designs in a large survey [21]. These preliminary results indicate the awareness of people living with HIV (PLWH) for potential personal and social benefits, in addition to future – albeit uncertain – clinical benefits. These findings also underscore the degree of commitment in participation, the motivation of altruism and the important roles for involvement of community representatives in study design [22].

In order to assess the risks and benefits of undergoing gut biopsy procedures to understand the persistence of HIV reservoirs, we organised a group discussion on performing either a flexible sigmoidoscopy or a colonoscopy with community representatives and physicians specialising in HIV medicine. While in Canada both approaches are considered acceptable for colon cancer screening [23,24], full colonoscopy affords an evaluation of the right side of the colon and may be slightly more effective in reducing colorectal cancer rates, with only a very modest decrease in cost effectiveness [25]. Approximately one in four polyps may be missed by limiting endoscopic evaluation to the splenic flexure [26]. Although the individual cost of flexible sigmoidoscopy is cheaper than colonoscopy, programmatic screening by colonoscopy may in fact be more cost effective than sigmoidoscopy [27]. Other considerations include the following: colonoscopy preparation, duration of the procedure, potential risks of multiple colon mucosal biopsies and potential benefits for screening polyps (Table 1). Taking all these factors into account, a consensus was reached on conducting colonoscopy to obtain gut mucosal biopsies while providing full colon cancer screening. We then wanted to document that the argument justifying the use of colonoscopy was confirmed by clinical practice. We show safety and tolerability to undergo 30 gut mucosal biopsies in the descending colon in HIV-treated patients and healthy controls. In addition to their altruistic commitment, the participants obtained ancillary benefits for colon cancer screening using colonoscopy over flexible sigmoidoscopy performed in a research setting.

Methods

Group discussion

In September 2014, a group discussion among HIV-treating physicians, immunologists, virologists and community representatives was organised in Montreal. The objective was to discuss the optimal strategy for the collection of a greater number of gut mucosal biopsies to study HIV pathogenesis and reservoirs. Advantages and limitations of conducting either a flexible sigmoidoscopy or a colonoscopy were presented to the participants (Table 1). Consensus was reached on using colonoscopy, which, although requiring more preparation, time and resources than sigmoidoscopy, would provide full colon cancer screening as an ancillary potential benefit to participants.

Study population

Thirty HIV-infected ART-treated asymptomatic adults aged ≥ 50 years, with an undetectable

viral load (VL) and nine age-matched uninfected volunteers were invited to participate in this study from March 2015 to May 2017 at the Chronic Viral Illness Services, McGill University Health Centre, Montreal, Canada. HIV-infected individuals were contacted through their treating physician and HIV-uninfected volunteers were identified at the gastroenterology service where they were scheduled for the colon cancer screening programme for persons aged ≥ 50 years [28].

Clinical procedures

Participants were instructed to adhere to a clear-liquid diet 24 hours before the procedure to begin a bowel preparation regimen to clear the bowels. On the day of the examination, participants were offered the choice of conscious sedation. Only one healthy control among all participants elected not to receive conscious sedation. Colonoscopy was then performed with a high-definition colonoscope inserted to the caecum, followed by slow withdrawal and careful examination of the mucosa. When present, polyps were removed by snare polypectomy and were sent for pathological assessment; abnormal mucosal findings were biopsied. Sigmoid biopsies (30 biopsies) were then collected from the descending colon [29] for the study. These were collected from the normal mucosa of the descending colon at least 30 cm from anal margin to perform an immunological investigation and HIV reservoir measurements. Briefly, we previously reported that CD4 T cell subsets expressing the chemokine receptor CCR6 are enriched in HIV DNA compared to their CCR6- counterparts in both colon and blood of HIV-infected individuals receiving ART [16]. It has been reported that the colon CCR6 CD4 T cells in ART-treated individuals express higher levels of CCR5, integrin $\beta 7$ and phosphorylated mTOR [30]. Such findings highlight the potential beneficial use of mTOR inhibitors in decreasing HIV reservoirs and restoring Th17-mediated immunity.

Matched peripheral blood samples (100 mL/donor) were collected from participants on the same day as the colonoscopy. Plasma VL was measured using the Amplicor HIV-1 monitor ultrasensitive method (Roche Diagnostics Systems, Branchburg, NJ, USA). The day after the procedure, each participant was contacted by telephone by a research nurse to inquire about their wellbeing including abdominal pain, discomfort and presence of blood in stool.

Data collection and statistical analyses

Socio-demographic data including age, sex, ethnicity and past medical history were recorded from the patient's medical chart. For each participant, data were extracted from colonoscopic and pathological reports. Univariate analysis was conducted using appropriate statistical tests including Student's *t*-test, chi-squared

Table 1. Comparative characteristics of performing sigmoidoscopy versus colonoscopy to obtain multiple gut biopsies

Characteristics	Sigmoidoscopy	Colonoscopy
Bowel preparation	Limited, only during the procedure	Yes, oral laxative
Estimated duration of the procedure	15 minutes	30 minutes
Analgesic medication	No	Yes
Possible polyp removal	≤ 50 cm of anal margin	Throughout colon
Time for multiple biopsies	Shorter	Longer
Post-biopsy side effects	Infrequent	Infrequent
Ability to drive back home	Yes	No (for 4 hours)
Estimated cost in Canada	Less costly ~ CA\$ 450	More costly ~ CA\$ 580

(χ^2) test, Fisher's exact test, and Spearman rank correlation test at 5% level of significance using GraphPad 7.0 and SPSS 23.0.

Ethical considerations

The study was conducted in compliance with the principles included in the Declaration of Helsinki and received approval from the Institutional Review Board of the McGill University Health Centre. All study participants signed a written informed consent for study participation.

Results

Participant characteristics

A total of 39 individuals participated in the study with a mean age of 58.4±6.0 years. The majority of the participants (92.3%) were male, white (92.3%), and belonged to the HIV-infected group (76.9%). The mean age ($P=0.614$), gender ($P=0.127$) and ethnic background ($P>0.999$) of both groups was similar. The majority (86.7%) of the HIV-infected participants were MSM in comparison to only one MSM (11.1%) amongst the HIV-uninfected participants ($P<0.001$). A history of smoking, alcohol and family history of colon cancer were comparable between the two groups ($P>0.05$) (Table 2). Mean duration of ART in the HIV-positive group was 15.3±6.2 years.

HIV-infected participants receiving long-term ART had a significantly lower mean CD4 T cell count (532±205 vs 757±247 cells/mm³; $P=0.012$), a higher CD8 T cell count (790±343 vs 346±130 cells/mm³; $P<0.001$) and a lower CD4:CD8 ratio

(0.75±0.35 vs 2.3±0.6; $P<0.001$; Table 2) It has been reported that the risk of AIDS or other clinical events becomes significantly reduced in persons with CD4 T cell counts above 500 cells/mm³ while on ART [31]. In addition, our study included asymptomatic ART-treated PLWH. Gut biopsy samples collected from these ART-treated individuals generated significant results. We demonstrated that the CD4 T cell subsets expressing the chemokine receptor CCR6+ versus CCR6- are enriched in HIV DNA in both colon ($P=0.0014$; median 2.8-fold increase) and blood ($P=0.026$; median 1.5-fold increase) of HIV-infected individuals receiving ART [16]. We next reported that CCR6+ versus CCR6- CD4 T cell infiltrating the colon in ART-treated individuals express a distinctive molecular signature that includes higher levels of CCR5, integrin $\beta 7$ expressions and enhanced mTOR phosphorylation [30]. These results identify mTOR as a druggable key regulator of HIV persistence in gut homing CCR6+ CD4 T cells.

Effect of the procedure on participants

No serious side effects were reported during or after the procedure. None of the participants was hospitalised within 3 months of the procedure and no documented complications were observed following the procedure either after a telephone call by the nurse and/or consultation of patient charts during this period. To further assess the acceptability of undergoing colonoscopy, participants were contacted by telephone at least 3 months after the procedure to assess whether they would undergo another medically required colonoscopy. Among the 19 reachable participants, all agreed that they would undergo another colonoscopy for medical reasons. Based on our findings, colonoscopy was safe to use for gut biopsy procedures where almost half of the participants – all of them over 50 years of age – had polyps removed.

Abnormal colonoscopic findings

Abnormal colonoscopic findings, including polyps and in one case asymptomatic patchy colitis in the sigmoid colon, in relation to lymphoid follicular hyperplasia were observed in 17 (43.6%) of the participants and were not associated with age, gender, ethnicity, risk group, CD4 and CD8 T cell counts and CD4:CD8 ratio ($P>0.05$). Similarly, a history of smoking and alcohol use was not associated with abnormal colonoscopic findings. However, a family history of cancer was significantly associated with abnormal colonoscopic findings ($P=0.030$), irrespective of HIV status. The proportion of participants with abnormal colonoscopic findings in HIV-infected and uninfected groups was similar (43.3% vs 44.4%; $P=0.953$). A total of 24 polyps were removed, 1–3 polyps in each participant, with a higher mean number of polyps removed in HIV-infected versus uninfected participants (1.7 vs 1.0; $P=0.013$). Ten participants had one polyp and six had two or more polyps removed. All the participants with two or more polyps belonged to the HIV-infected group (Figure 1). Overall, the number of polyps inversely correlated with the CD4:CD8 ratio with a marginal statistical significance ($r=-0.495$; $P=0.051$) (Figure 2). Anatomical sites where polyps were located included rectum (one polyp), sigmoid colon (nine polyps),

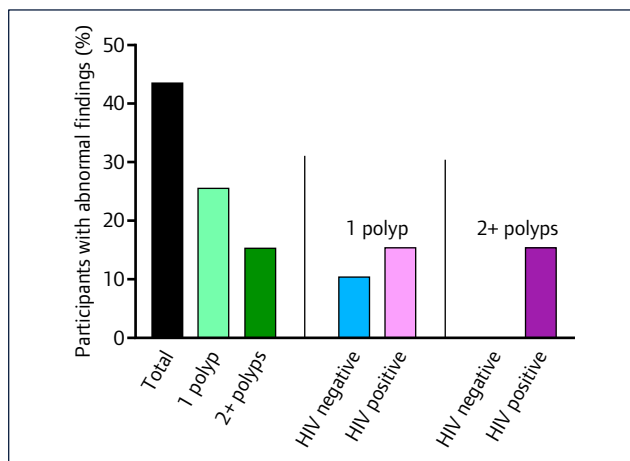
Table 2. Socio-demographic, behavioural and clinical characteristics of study participants ($n=39$)

Characteristics	HIV positive $n=30$	HIV negative $n=9$	<i>P</i>
Age in years, (mean ±SD)	58.2 ± 6.3	59.3 ± 5.0	0.614
Sex			0.054
Male, <i>n</i> (%)	29 (96.7)	7 (77.8)	
Female, <i>n</i> (%)	1 (3.3)	2 (22.2)	
Ethnic background			>0.999
Non-white, <i>n</i> (%)	3 (10.0)	0 (0.0)	
white, <i>n</i> (%)	27 (90.0)	9 (100.0)	
Exposure group			<0.001
Heterosexual, <i>n</i> (%)	4 (13.3)	8 (88.9)	
MSM, <i>n</i> (%)	26 (86.7)	1 (11.1)	
Smoking			0.749
Yes, <i>n</i> (%)	13 (43.3)	3 (33.3)	
No, <i>n</i> (%)	17 (56.7)	6 (66.7)	
Alcohol use			0.706
Yes, <i>n</i> (%)	17 (56.7)	4 (44.4)	
No, <i>n</i> (%)	13 (43.3)	5 (55.5)	
Family history of cancer			0.169
Yes, <i>n</i> (%)	7 (23.3)	0 (0.0)	
No, <i>n</i> (%)	23 (76.7)	9 (100.0)	
CD4 T cell count (cells/mm ³ , mean ± SD)	532 ± 205	757 ± 247	0.012*
CD8 T cell count (cells/mm ³ , mean ± SD)	790 ± 343	346 ± 130	<0.001
CD4/CD8 ratio (mean ± SD)	0.75 ± 0.35	2.3 ± 0.60	<0.001
VL, log ₁₀ copies/mL (mean ± SD)	<1.7	–	–

* $P<0.05$

Table 3. Location of polyps. One participant from the HIV-positive group had asymptomatic colitis in the sigmoid colon. The polyps in bold ($n=13$) are those which would have not been detected/removed if sigmoidoscopy was used

ID	Number of polyps	Location of first polyp	Location of second polyp	Location of third polyp	Group (HIV positive/negative)
Biposy#3	1	5 mm from sigmoid colon	–	–	Negative
Biposy#4	1	5–9 mm from sigmoid colon	–	–	Negative
Biposy#7	1	5–9 mm from rectum	–	–	Negative
Biposy#9	1	<5 mm from caecum	–	–	Negative
Biposy#15	1	5–9 mm from hepatic flexure	–	–	Positive
Biposy#17	3	5 mm from caecum	5–9 mm from caecum	10–15 mm from ascending colon	Positive
Biposy#19	1	5 mm from sigmoid colon	–	–	Positive
Biposy#21	2	5 mm from transverse colon	10–15 mm from hepatic flexure	–	Positive
Biposy#22	1	5–9 mm from sigmoid colon	–	–	Positive
Biposy#23	2	5–9 mm from sigmoid colon	<5 mm from rectosigmoid junction	–	Positive
Biposy#27	3	10–15 mm from sigmoid colon	0.1 cm×0.1 cm from ascending colon	0.1 cm×0.1 cm from terminal ileum	Positive
Biposy#28	2	10–15 mm from descending colon	5–9 mm from ascending colon	–	Positive
Biposy#29	1	5 mm from sigmoid colon	–	–	Positive
Biposy#31	1	<5 mm from sigmoid colon	–	–	Positive
Biposy#37	2	<5 mm from caecum	<5 mm from caecum and diverticulum	–	Positive
Biposy#38	1	<5 mm from caecum	–	–	positive

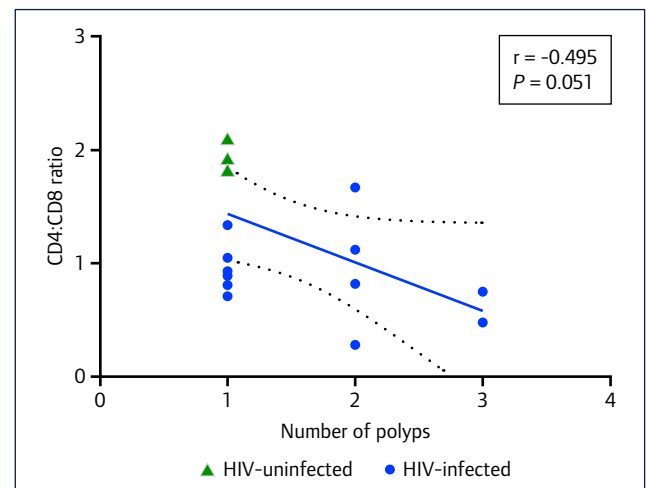
**Figure 1.** Distribution of abnormal colonoscopic findings in HIV-infected and uninfected participants. One participant from the HIV-infected group had asymptomatic colitis in the sigmoid colon

descending colon (one polyp), transverse colon (one polyp), hepatic flexure (two polyps), ascending colon (three polyps), terminal ileum (one polyp) and caecum (six polyps) (Table 3).

An estimation was made that if flexible sigmoidoscopy had been performed instead of colonoscopy, it would have been possible to screen for polyps in the first 50 cm after the anal margin. This would have detected an estimated 11 polyps representing only 46% of the total polyps removed with colonoscopy. Such findings justify the use of colonoscopy over sigmoidoscopy for identification and removal of polyps.

Discussion

The past 20 years have witnessed the evolution of HIV research in understanding the mechanisms by which HIV persists despite effective ART [12]. Persistence of HIV reservoirs in hard-to-reach tissues has emerged as the central focus for eradication strategies [13]. To this end, we have previously shown enrichment of

**Figure 2.** Correlation of number of polyps with CD4:CD8 ratio in the study participants. All the participants with two or more polyps belonged to HIV-infected group. The correlation coefficient was calculated using Spearman's rank correlation test

replication-competent HIV DNA in CCR6+ CD4 T cells in blood and the colon in 13 ART-treated participants [16]. Access to tissue samples remains a challenge from a clinical and ethical point of view owing to the potential risks of tissue sampling, especially in the context of preliminary proof of principle or exploratory HIV eradication studies [21].

In order to address this question, we first organised a group discussion between various stakeholders including community representatives, researchers and physicians to assess the usefulness and acceptability of performing sigmoidoscopy versus colonoscopy for the collection of gut biopsy samples in the descending colon for HIV cure research. After reaching a consensus, two recommendations were made: (1) to use colonoscopy; and (2) to invite participants 50 years and over to select the population that may benefit most from participation in the context of colon cancer screening. In this study, we report that colonoscopic examination

to collect gut mucosal biopsies was safe, well tolerated and provided the ancillary benefits of colon cancer screening.

A total of 39 individuals over 50 years of age participated in the study and underwent colonoscopy. No major side effects were reported during or after the procedure and abnormal colonoscopic findings including polyps were observed in almost half of the participants. Intestinal polyps are usually non-cancerous growths but if left untreated some can develop into colorectal cancer over time [32]. Also, based on 1.2-fold higher number of polyps located in the right versus left colon [33], our study estimates 11 polyps removed from the right colon in comparison to 13 from the left colon. Right-sided colon cancer when compared to left, has been associated with older age, advanced stages and with poor prognosis, as recently reviewed [34].

The study participants were categorised into two groups based on HIV status and the groups were comparable in terms of age, sex, socio-demographic and behavioural characteristics with the exception of a higher proportion of MSM in the HIV-infected group. This is one study limitation as composition of gut microbiota may differ in MSM compared with non-MSM. Noguera-Julian *et al.* have reported MSM versus non-MSM individuals to have a significantly richer and more diverse faecal microbiota, rich in *Prevotella* species regardless of HIV status [35]. A reduction in bacterial richness was observed with HIV infection despite dominance of genus *Prevotella* and has been linked with inflammation [35,36]. Such differences may explain the differences in the abnormal colonoscopic findings seen in our study and need further exploration. As expected, a lower CD4 T cell count and a lower CD4:CD8 ratio were observed in HIV-infected participants who were on ART for an average time of 15 years.

In the ART era, HIV has become a chronic infection rendering HIV-infected persons susceptible to developing non-AIDS conditions including lung and colorectal cancer at a higher rate than the general population [37]. We did not find an association between HIV status and abnormal colonoscopic findings in our study. Our results are comparable to a US population-based retrospective study on 5473 HIV-patients where risk-adjusted outcomes of colorectal surgery in patients with HIV did not differ significantly from the general population. Of note, compared to the general population, a significantly lower age of HIV-infected participants presenting with abnormal colonoscopic findings including polyps was reported in this study [37]. We, however, selected participants aged 50 years or over in the two groups, and therefore, adjusted for age at the study design.

We observed an association between family history of cancer and abnormal colonoscopic findings confirming the role of genetic factors alongside environmental factors [38–40]. An association between abnormal colonoscopic findings with a history of smoking or alcohol use was not found, both of which are risk factors for the development of colon cancer [41]. This could be attributed to the small sample size in our study with the majority comprising ART-treated HIV-infected individuals. Of note, smoking and alcohol abuse are comparatively higher among PLWH than the general population, further increasing their risk for colon cancer.

To our knowledge, no previous study analysed the association between CD4:CD8 ratio and the number of polyps, which showed a marginally significant negative correlation in our study. This could be related to higher HIV-associated gut damage, gut dysbiosis and immune dysfunction [42–44], predisposing these participants to polyp development. This hypothesis-generating finding justifies a prospective study to confirm such an observation.

Our study has several limitations that need to be considered while interpreting the results. First, the generalisability of study findings

is limited by a small sample size, predominantly white male population, and the age of the participants. However, with advancements in healthcare, ageing has emerged as an important issue in the general population and is considered to be accelerated in PLWH [45]. Furthermore, our HIV-infected patients mainly comprised MSM individuals, a group that has been shown to have distinct gut microbiota [35] and, therefore, could potentially influence our study findings. In terms of the initial group discussion, we do not know whether similar conclusions would have emerged if the study had recruited significant numbers of women (including transwomen), other ethnicities or representatives of Canada's Indigenous peoples and non-MSM individuals. We recommend that future studies pay close attention to these issues of community demographics. Our study highlights the need for colonoscopic examination in the ageing population. Owing to the small sample size, we conducted only univariate analyses to determine associations and such analysis is prone to confounding. Therefore, large-scale studies will be required to further confirm these associations using multivariable modelling. Nevertheless, our study reports significant findings from the colonoscopic examination of HIV-infected persons.

Globally, colonoscopic examination of HIV-infected persons for obtaining multiple gut mucosal biopsies for HIV cure research was safe and well tolerated. In addition, polyps were identified throughout the colon for half of the participants and were removed during the procedure. Participation in the study provided ancillary benefits that participants could have received in standard medical care, thus mitigating burdens of undergoing colon mucosa multiple biopsies, a relatively invasive procedure. Dialogue between community representatives, physicians, and researchers can optimise participation in research studies on tissue samples to augment clinical care while also facilitating HIV cure research.

Acknowledgements

The authors are grateful to the study participants for their contribution, Josée Girouard for her outstanding nursing care and data collection and Angie Massicotte for administrative assistance (McGill University Health Centre). Mario Legault (Centre de recherche du Centre Hospitalier de l'Université de Montréal – Réseau SIDA/Maladies infectieuses du Fonds de Recherche du Québec-Santé (FRQ-S) for gut mucosa in HIV infection study co-ordination.

Conflicts of interest

The authors have no competing interests to declare.

Source of funding

This work was supported by the FRQ-S: Réseau SIDA/Maladies infectieuses; the Canadian Institutes of Health Research (CIHR; grant MOP 103230); the Vaccines and Immunotherapies Core of the CIHR Canadian HIV Trials Network (CTN; grant CTN 257); the Canadian Foundation for AIDS Research (CANFAR; grant 02-512); and the Canadian HIV Cure Enterprise Team Grant (HIG-133050) awarded by the CIHR in partnership with CANFAR. VM is supported by an FRQ-S Postdoctoral Fellowship Award. RP is supported by the H. Grenville Smith Fellowship from the Research Institute of the McGill University Health Centre. J-PR is the holder of the Louis Lowenstein Chair in Hematology and Oncology, McGill University.

References

1. Deeks SG, Lewin SR, Ross AL *et al.* International AIDS Society global scientific strategy: towards an HIV cure 2016. *Nat Med* 2016; **22**: 839–850.
2. World Health Organization. 2016. Prevent HIV, test and treat all – WHO support for country impact. Available at: <http://www.who.int/hiv/pub/progressreports/2016-progress-report/en/> (accessed September 2017).

3. Chomont N, El-Far M, Ancuta P *et al.* HIV reservoir size and persistence are driven by T cell survival and homeostatic proliferation. *Nat Med* 2009; **15**: 893–900.
4. Mehraj V, Jenabian MA, Vyboh K, Routy JP. Immune suppression by myeloid cells in HIV infection: new targets for immunotherapy. *Open AIDS J* 2014; **8**: 66–78.
5. Boulassel MR, Chomont N, Pai NP *et al.* CD4 T cell nadir independently predicts the magnitude of the HIV reservoir after prolonged suppressive antiretroviral therapy. *J Clin Virol* 2012; **53**: 29–32.
6. Lu W, Mehraj V, Vyboh K *et al.* CD4:CD8 ratio as a frontier marker for clinical outcome, immune dysfunction and viral reservoir size in virologically suppressed HIV-positive patients. *J Int AIDS Soc* 2015; **18**: 20052.
7. Ananworanich J, Chomont N, Eller LA *et al.* HIV DNA set point is rapidly established in acute HIV infection and dramatically reduced by early ART. *EBioMedicine* 2016; **11**: 68–72.
8. Ananworanich J, Schuetz A, Vandergeeten C *et al.* Impact of multi-targeted antiretroviral treatment on gut T cell depletion and HIV reservoir seeding during acute HIV infection. *PLoS One* 2012; **7**: e33948.
9. Buzon MJ, Martin-Gayo E, Pereyra F *et al.* Long-term antiretroviral treatment initiated at primary HIV-1 infection affects the size, composition, and decay kinetics of the reservoir of HIV-1-infected CD4 T cells. *J Virol* 2014; **88**: 10056–10065.
10. Josefsson L, von Stockenström S, Faria NR *et al.* The HIV-1 reservoir in eight patients on long-term suppressive antiretroviral therapy is stable with few genetic changes over time. *Proc Natl Acad Sci U S A* 2013; **110**: E4987–4996.
11. Siliciano JD, Kajdas J, Finzi D *et al.* Long-term follow-up studies confirm the stability of the latent reservoir for HIV-1 in resting CD4+ T cells. *Nat Med* 2003; **9**: 727–728.
12. Boritz EA, Douek DC. Perspectives on human immunodeficiency virus (HIV) cure: hiv persistence in tissue. *J Infect Dis* 2017; **215**: S128–S133.
13. Lorenzo-Redondo R, Fryer HR, Bedford T *et al.* Persistent HIV-1 replication maintains the tissue reservoir during therapy. *Nature* 2016; **530**: 51–56.
14. Fletcher CV, Staskus K, Wietgreffe SW *et al.* Persistent HIV-1 replication is associated with lower antiretroviral drug concentrations in lymphatic tissues. *Proc Natl Acad Sci U S A* 2014; **111**: 2307–2312.
15. Poles MA, Boscardin WJ, Elliott J *et al.* Lack of decay of HIV-1 in gut-associated lymphoid tissue reservoirs in maximally suppressed individuals. *J Acquir Immune Defic Syndr* 2006; **43**: 65–68.
16. Gosselin A, Wiche Salinas TR, Planas D *et al.* HIV persists in CCR6+CD4+ T cells from colon and blood during antiretroviral therapy. *AIDS* 2017; **31**: 35–48.
17. Khoury G, Fromentin R, Solomon A *et al.* Human immunodeficiency virus persistence and t-cell activation in blood, rectal, and lymph node tissue in human immunodeficiency virus-infected individuals receiving suppressive antiretroviral therapy. *J Infect Dis* 2017; **215**: 911–919.
18. Gianella S, Taylor J, Brown TR *et al.* Can research at the end of life be a useful tool to advance HIV cure? *AIDS* 2017; **31**: 1–4.
19. Lamers SL, Rose R, Maidji E *et al.* HIV DNA is frequently present within pathologic tissues evaluated at autopsy from combined antiretroviral therapy-treated patients with undetectable viral loads. *J Virol* 2016; **90**: 8968–8983.
20. Chiu WK, Brand RM, Camp D *et al.* The safety of multiple flexible sigmoidoscopies with mucosal biopsies in healthy clinical trial participants. *AIDS Res Hum Retroviruses* 2017; **33**: 820–826.
21. Dube K, Evans D, Sylla L *et al.* Willingness to participate and take risks in HIV cure research: survey results from 400 people living with HIV in the US. *J Virus Erad* 2017; **3**: 40–50.
22. Balfour L, Corace K, Tasca GA *et al.* Altruism motivates participation in a therapeutic HIV vaccine trial (CTN 173). *AIDS Care* 2010; **22**: 1403–1409.
23. Atkin WS, Edwards R, Kralj-Hans I *et al.* Once-only flexible sigmoidoscopy screening in prevention of colorectal cancer: a multicentre randomised controlled trial. *Lancet* 2010; **375**: 1624–1633.
24. Canadian Task Force on Preventive Health C, Bacchus CM, Dunfield L *et al.* Recommendations on screening for colorectal cancer in primary care. *CMAJ* 2016; **188**: 340–348.
25. O’Leary BA, Olynyk JK, Neville AM, Platell CF. Cost-effectiveness of colorectal cancer screening: comparison of community-based flexible sigmoidoscopy with fecal occult blood testing and colonoscopy. *J Gastroenterol Hepatol* 2004; **19**: 38–47.
26. Patel K, Hoffman NE. The anatomical distribution of colorectal polyps at colonoscopy. *J Clin Gastroenterol* 2001; **33**: 222–225.
27. Vijan S, Hwang EW, Hofer TP, Hayward RA. Which colon cancer screening test? A comparison of costs, effectiveness, and compliance. *Am J Med* 2001; **111**: 593–601.
28. Sharara N, Nolan S, Sewitch M *et al.* Assessment of a colonoscopy triage sheet for use in a province-wide population-based colorectal screening program. *Can J Gastroenterol Hepatol* 2016; **2016**: 4712192.
29. Von Renteln D, Bouin M, Barkun AN. Current standards and new developments of colorectal polyp management and resection techniques. *Expert Rev Gastroenterol Hepatol* 2017; **11**: 835–842.
30. Planas D, Zhang Y, Monteiro P *et al.* HIV-1 selectively targets gut-homing CCR6+CD4+ T cells via mTOR-dependent mechanisms. *JCI Insight* 2017; **2**.
31. Nakanjako D, Kiragga AN, Musick BS *et al.* Frequency and impact of suboptimal immune recovery on first-line antiretroviral therapy within the International Epidemiologic Databases to Evaluate AIDS in East Africa. *AIDS* 2016; **30**: 1913–1922.
32. Mayo Clinic. Colon polyps: disease and conditions. Available at: www.mayoclinic.org/diseases-conditions/colon-polyps/home/ovc-20346918 (accessed September 2017).
33. Qumseya BJ, Coe S, Wallace MB. The effect of polyp location and patient gender on the presence of dysplasia in colonic polyps. *Clin Transl Gastroenterol* 2012; **3**: e20.
34. Haase AT, Henry K, Zupancic M *et al.* Quantitative image analysis of HIV-1 infection in lymphoid tissue. *Science* 1996; **274**: 985–989.
35. Noguera-Julian M, Rocafort M, Guillen Y *et al.* Gut microbiota linked to sexual preference and HIV infection. *EBioMedicine* 2016; **5**: 135–146.
36. Gootenberg DB, Paer JM, Luevano JM, Kwon DS. HIV-associated changes in the enteric microbial community: potential role in loss of homeostasis and development of systemic inflammation. *Curr Opin Infect Dis* 2017; **30**: 31–43.
37. Gahagan JV, Halabi WJ, Nguyen VQ *et al.* Colorectal surgery in patients with HIV and AIDS: trends and outcomes over a 10-year period in the USA. *J Gastrointest Surg* 2016; **20**: 1239–1246.
38. Henrikson NB, Webber EM, Goddard KA *et al.* Family history and the natural history of colorectal cancer: systematic review. *Genet Med* 2015; **17**: 702–712.
39. Jo WS, Bandipalliam P, Shannon KM *et al.* Correlation of polyp number and family history of colon cancer with germline MYH mutations. *Clin Gastroenterol Hepatol* 2005; **3**: 1022–1028.
40. Kerber RA, Slattery ML, Potter JD *et al.* Risk of colon cancer associated with a family history of cancer or colorectal polyps: the diet, activity, and reproduction in colon cancer study. *Int J Cancer* 1998; **78**: 157–160.
41. Cho S, Shin A, Park SK *et al.* Alcohol drinking, cigarette smoking and risk of colorectal cancer in the Korean Multi-center Cancer Cohort. *J Cancer Prev* 2015; **20**: 147–152.
42. Mehraj V, Jenabian MA, Ponte R *et al.* The plasma levels of soluble ST2 as a marker of gut mucosal damage in early HIV infection. *AIDS* 2016; **30**: 1617–1627.
43. Ponte R, Mehraj V, Ghali P *et al.* Reversing gut damage in HIV infection: using non-human primate models to instruct clinical research. *EBioMedicine* 2016; **4**: 40–49.
44. Vyboh K, Jenabian MA, Mehraj V, Routy JP. HIV and the gut microbiota, partners in crime: breaking the vicious cycle to unearth new therapeutic targets. *J Immunol Res* 2015; **2015**: 614127.
45. Rasmussen LD, May MT, Kronborg G *et al.* Time trends for risk of severe age-related diseases in individuals with and without HIV infection in Denmark: a nationwide population-based cohort study. *Lancet HIV* 2015; **2**: e288–298.