

Video-assisted thoracoscopic surgery bronchial sleeve lobectomy

Fabio Davoli¹, Luca Bertolaccini¹, Alessandro Pardolesi², Piergiorgio Solli^{1,2}

¹Thoracic Surgery, AUSL Romagna, S. Maria delle Croci Teaching Hospital, Ravenna, Italy; ²Thoracic Surgery, AUSL Romagna, Morgagni-Pierantoni Teaching Hospital, Forlì, Italy

Contributions: (I) Conception and design: F Davoli, L Bertolaccini, P Solli; (II) Administrative support: L Bertolaccini, P Solli; (III) Provision of study materials or patients: F Davoli, L Bertolaccini, A Pardolesi; (IV) Collection and assembly of data: F Davoli; (V) Data analysis and interpretation: F Davoli, L Bertolaccini; (VI) Manuscript writing: All authors; (VII) Final approval of manuscript: All authors.

Correspondence to: Fabio Davoli. Thoracic Surgery Unit, AUSL Romagna, S. Maria delle Croci Teaching Hospital, Viale Vincenzo Randi, 5, Ravenna, Italy. Email: fabio.davoli@auslromagna.it.

Abstract: A sleeve lobectomy (SL) is considered a valid option instead of a pneumonectomy in patients affected by central non-small cell lung cancer (NSCLC). In the last few years, the improvement of video-assisted thoracoscopic surgery (VATS) has allowed experienced surgeons to carry out this challenging operation by a minimally invasive approach. A full pre-operative assessment enclosing a flexible fiber-optic bronchoscopy evaluation and a multidisciplinary team discussion of the clinical case must be accomplished. There is no strictly an indication for the number of thoracoscopic ports: VATS SL is reported from 1 to 3–4 incisions. A significant variability in the technique of the anastomosis is documented and depends on the personal use and ability of the surgeon. However the operational principles are the same of an open SL: free bronchial margins at the frozen section examination, tension-free anastomosis, avoid luminal disparity and en-bloc resection. Due to the extent of the tumour, VATS SL can be associated to other complex resections like arterioplasty, or double sleeve (bronchial and artery) mainly on the left side. A patient underwent a VATS SL must be enrolled in an enhanced recovery pathway (ERP): physiological rehabilitation is a key point to achieve good outcomes and avoid complications.

Keywords: Non-small lung cell cancer (NSCLC); video-assisted thoracic surgery (VATS); sleeve lobectomy (SL)

Received: 11 February 2017; Accepted: 23 February 2017; Published: 31 March 2017.

doi: 10.21037/jovs.2017.03.03

View this article at: <http://dx.doi.org/10.21037/jovs.2017.03.03>

Introduction

Since the first sleeve bronchial resection for a pulmonary carcinoid was reported in 1947 by Sir Clement Price Thomas, surgeon to the Westminster and the Brompton hospitals in London (1), sleeve lobectomy (SL) has been considered a more valid therapeutic option for central non-small cell lung cancer (NSCLC) comparing with pneumonectomy, with a better long-term survival and quality of life without increasing the morbidity and mortality (2,3).

In the video-assisted thoracic surgery (VATS) era, SL is still considered a contraindication to minimally invasive surgery for many surgeons. This because of SL is a challenging procedure that requires an open approach in

expert hands also.

However, a lot of experience in VATS major resection was acquired from the first VATS lobectomy documented by Roviario in the early 90s (4), till the first case report of a uniportal VATS SL by Diego Gonzalez-Rivas *et al.* in 2013 (5); nowadays some case series also can prove the feasibility of VATS SL (6-9).

Despite this encouraging results, VATS SL remains a challenging operating technique that should be reserved to high VATS volume centres and experienced surgeons.

Patient selection and workup

The lesions in the hilum of the right upper (RU) lobe

detected at the Chest Computed Tomography (CT) Scan represent the most common indication for a SL, related to the anatomic structure of the right main stem and the intermedium bronchi. Anyway, all lobes may be suitable for parenchymal-sparing bronchoplastic procedures.

At the beginning of the bronchoplastic experience, it was commonly accepted that a patient candidate to a SL had to tolerate also a pneumonectomy. Nowadays the belief of modern thoracic surgeons is that parenchymal-sparing resections, if necessary to avoid a pneumonectomy, are the best option for selected patients with or without compromised lung function (10).

The indication of a SL in an N1+ patient is very controversial; more in general, despite a negative CT or PET imaging, all the patients with central neoplastic lesions required a mini-invasive mediastinal staging by Endobronchial Ultrasound-TransBronchial Needle Aspiration (EBUS-TBNA) to catch unforeseen N2 (11).

Regarding VATS technique, there is no strictly recommendations for the number of ports to be chosen, but both the patient than the full operating room equipe (surgeons, nurses, anesthesiologist) must be informed about the risk of a thoracotomic conversion and a potential pneumonectomy.

We feel free to stress the importance of a multidisciplinary team workup of this complex patients to minimise risk of conversion, pneumonectomy or, worse, unnecessary thoracotomic exploration.

Flexible bronchoscopy and surgical strategy

Flexible bronchoscopy plays a central role in the pre-operative evaluation of a patient candidate to a SL and may influence surgical planning. It is impossible for a surgeon to define a SL without an endobronchial direct look correctly. For this reason, we advocate the surgeon himself to perform the exam or his active presence during the pneumology bronchoscopic session.

Flexible bronchoscopy may provide useful information about the real extent of the tumour, from the sublobar bronchi to the lobar origin, the potential involvement of the carina or the main stem bronchus, real length of the planned hypothetic anastomotic stumps.

Under the suspect of peribronchial tumour infiltration of the main stem bronchus (left or right makes no difference) or the carina, a TBNA mapping could be performed to rule out the risk of intra-operative positive margins at the frozen-section examination by the pathologist.

Pre-operative preparation

VATS SL is not a contraindication to include the patient into an enhanced recovery pathway (ERP). As already shown by McKenna *et al.* (12) an ERP can be achieved in patients underwent major VATS pulmonary resections such as SL with minimal complication, pain relief and control, less duration of the chest tube placement, hospital stay and reduced costs. We advocate epidural patient-controlled analgesia (EPCA) because of the risk of conversion in this kind of VATS procedures. If not present at the multidisciplinary team discussion, it is better to pre-alert an expert lung pathologist that intraoperative frozen-section examination will be needed.

Equipment preference card

A VATS SL can be performed with the conventional instruments for a simple VATS lobectomy, the well-known dedicated instrumentation such as high definition 30° cameras, articulated staplers and forceps, vascular clips, endoscopic clamps and energy devices.

Furthermore, an endoscopic needle holder, a long scalpel and a knot pusher are needed.

A paediatric flexible bronchoscope must always be available, mainly to check the suture before closure and to toilette the distal bronchial stump.

Procedures

Basic surgical principles

A VATS SL must accomplish the same oncologic and surgical principles of a “traditional” open SL that can be summarised as follow: (I) disease-free margins of the bronchial stump confirmed by intraoperative frozen sections; [for NSCLC a free margin of 5 mm is needed, for less malignant tumours 3 mm is enough (13)]; (II) “en bloc” resection; (III) well-shaped bronchial stumps avoiding luminal disparity; (IV) tension-free end-to-end anastomosis”.

The patient is positioned in standard lateral decubitus, general anaesthesia and optimal split ventilation with a double-lumen tube is mandatory. A possible alternative to a double-lumen is the use of endobronchial blockers. The intra-operative management must be planned before by the leading surgeon and the anaesthesiologic team. For left VATS SL it is better to use a right-sided double lumen tube.

The number of thoracoscopic ports is not an



Figure 1 VATS right upper lobe bronchial sleeve resection [Reprinted with permission (18)].

unconditioned rule.

VATS SL are reported to be performed either by a uniportal or a multiportal approach, and different intercostals spaces are described for the 4 cm long incision (5,14). In our experience, the minithoracotomy is placed in the 4th or the 5th intercostals space in the anterior axillary line. The placement of this incision is a crucial point. If it is performed too posterior, it does not allow a correct angle to the endoscopic instruments and provides potential conflicts. For the eventual remaining ports, we believe that a planned VATS SL has not to change the typical behaviour of the surgical team regarding number and place of the incisions.

After pleural exploration to confirm the preoperative findings, the dissection of the hilum begins and does not differ from a traditional VATS lobectomy.

The mediastinal pleura are usually opened with an energy device, the pulmonary ligament is divided to obtain a full mobilisation of the lung, and vascular elements are dissected and transected by vascular staplers in the usual order: first pulmonary veins, then arteries.

Lymphadenectomy should be done before the bronchial anastomosis. This is necessary mainly for two reasons: (I) to mobilise the hilum entirely avoiding tension during the anastomosis; (II) to set the lymph nodal status correctly with potential frozen section examinations if needed.

An N1+ intraoperative finding is not an absolute contraindication to a VATS SL. On the other hand, if unexpected N2+ is detached at the tracheobronchial angle a pneumonectomy is usually needed with or without thoracotomy conversion by the surgeon's experience.

As suggested by Gonzalez-Rivas *et al.* (15) the bronchial sleeve end-to-end anastomosis is the more complex

bronchoplastic procedure. In the beginning, the bronchus is cut by a cold scalpel, and then the sections of the bronchial stumps may be completed with scissors. Negative frozen sections of the margin are mandatory to go on.

The anastomosis could be done mainly in four different ways: (I) a running suture for the membranous part and single stitches for the cartilage (knots are tied outwards); (II) double continuous suture; (III) a single continuous suture for the whole anastomosis; (IV) fully interrupted sutures. A 3–0 polydioxanone suture (PDS) is the choice by some of the authors (14–17), but Prolene 3–0 continuous suture is well described also.

Visual air leak check under water must be accomplished at the lung re-expansion, and a bronchoscopy is advocated before closure.

RU VATS SL

Ma and Liu (17) successfully reported a VATS RU SL in a 66-year-old patient who underwent two cycles of neoadjuvant therapy for a squamous cell carcinoma involving main stem right, RU and intermedium bronchi. They started a triportal right VATS with the first incision in the eighth intercostal space (midaxillary line) for a 30° camera; then the utility incision (third intercostals space, 4 cms, periaxillary line) and the third port (nine space, post axillary line) were accomplished under direct vision.

The authors choose 3–0 interrupted absorbable sutures for the anastomosis.

The technical steps of the operation were the followings (*Figure 1*): (I) section of the pulmonary ligament; (II) transection of the pulmonary upper lobe vein (vascular stapler); (III) transection of the Boyden truncus and posterior ascending pulmonary artery (PA) (vascular stapler); (IV) completion of the fissures (linear stapler); (V) subcarinal lymph nodes dissection with fully exposure and mobilization of the distal right main bronchus and intermedium; (VI) resection with cold long scalpel of the bronchial cartilaginea wall and with scissors of the pars membranacea; (VII) accomplishing traction sutures on the lateral walls to reduce tension; (VIII) suture of the bronchial membrane with interrupted sutures; (IX) circumference end-to-end anastomoses with interrupted sutures too of the cartilaginea; (X) removal of the specimens with protective endobag; (XI) completion of the lymphadenectomy. Negative frozen-section margins and water test were performed. The Authors put one chest tube through the midaxillary port incision.

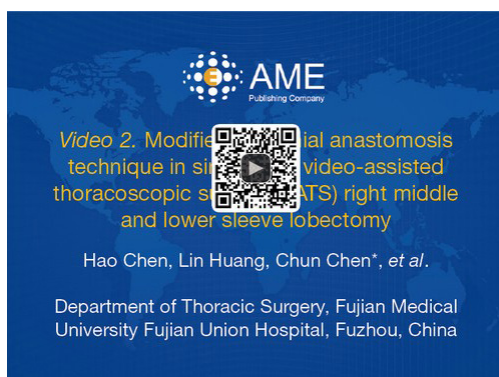

Figure 2 Modified bronchial anastomosis technique in singleport video-assisted thoracoscopic surgery (VATS) right middle and lower sleeve lobectomy [Reprinted with permission (20)].

Right medium (RM) and lower VATS SL

Chen *et al.* (19) proposed an interesting modified anastomotic technique for VATS SL; in particular, we focused on a RM and right lower (RL) VATS SL performed by a uniportal approach.

The sequence of the surgical steps is quite the same as described previously for the RU SL: section of the pulmonary ligament, transection of the vein, arteries, fissures.

After removing the “en bloc” specimen (lobes with target bronchus), negative frozen-section examination of the cut bronchial margins, and complete lymphadenectomy, they start the anastomosis between the right main stem bronchus and the RU lobar one with a double needle 3–0 Prolene continuous suture.

This anastomotic technique (*Figure 2*) begins from the deepest point of the pars membranacea (knot tied outside) and consists of four steps: (I) first quarter of the posterior lumen circumference from the most beneath knot to the posterior side; (II) the second quarter from the interior to the superficial side of the posterior lumen circumference; (III) first and (IV) second quarter of the anterior wall are sutured in the same way, taking care of positioning the last knot outside the anterior portion of the bronchial wall, allowing suture tightness regulation.

The Authors put one chest drainage through the operating port and a posterior venous catheter in the seventh or the eighth intercostal space. They documented a successful series of 32 VATS SL carried out by a three-portal (19) or a uniportal (5) approach without intra-operative deaths nor major complications due to surgery.

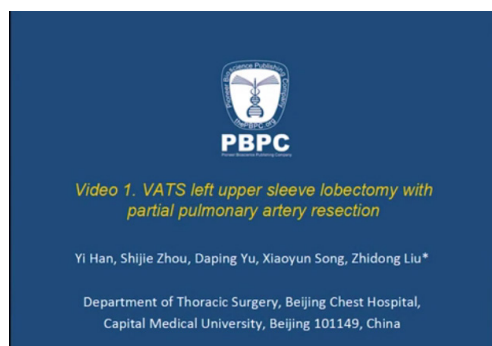


Figure 3 VATS left upper sleeve lobectomy with partial pulmonary artery resection [Reprinted with permission (22)].

Left upper (LU) VATS SL

LU VATS SL and more in general VATS left SL procedures are more complex, because of the presence of the aortic arch and the features of the left PA regarding length and size. Often a VATS SL on the left side is associated with a vascular sleeve anastomosis (double sleeve) or a partial artery resection.

Han *et al.* (21) documented a successful VATS LU SL with partial artery resection by a tri-portal approach in 2013. The patient, a 64-year-old male patient, presented with a squamous cell carcinoma of the left hilum. The arterioplasty was carried out with a Prolene 3–0 running suture (*Figure 3*) while the anastomosis between the left main stem and the left lower (LL) bronchi was realised with a running 3–0 absorbable suture in 3–0 absorbable reinforced by three interrupted points (knot outside the bronchial wall).

LL VATS SL

LL VATS SL is a challenging pulmonary resection.

In a recent large series of 118 VATS SL by Huang *et al.* (23), only 10 LL VATS SL were reported. Following the basic principles of an open SL, the vascular elements are transected first, and then come the bronchus separation. The main stem left bronchus, and the LU one are separately transected with a cold scalpel.

After the confirm of negative frozen section examination and the lymph nodal clearance, the reconstruction begins (*Figure 4*). The Authors stressed the importance of the surgeon’s ability in this context. Factors like the tension of the anastomosis and stumps diameters must be considered in every VATS SL, especially in an LL one. After checking

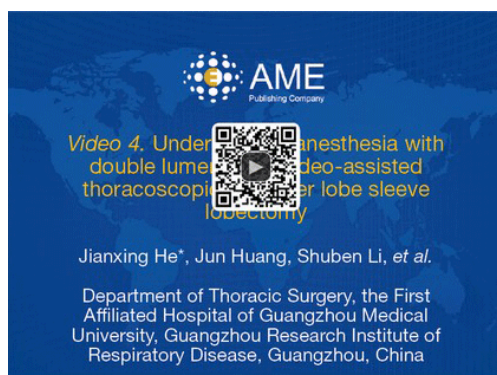


Figure 4 Under general anesthesia with double lumen tube, video-assisted thoracoscopic left lower lobe sleeve lobectomy [Reprinted with permission (24)].

this and blood suction from the surgical field, the anastomosis is carried out by a continuous suture of Prolene 3-0 and negative water test is done (*Figure 4*).

Role of team members

VATS SL and more in general VATS lobectomies entail a surgical equipe of two operators: the first surgeon and the assistant. Regardless of the number of ports, most of the minimally invasive approaches are anterior: both the operative surgeon than the assistant who holds the camera, are positioned in front of the patient. However, some authors (19) describe the assistant opposite to the first surgeon in uniportal procedures, with a central monitor at the head of the patient.

The scrub nurse is positioned on the opposite side of the operating table but is not a rule. For a VATS SL an experienced anesthesiologist is mandatory to guarantee optimal split ventilation, especially if a right-side double lumen tube is needed and management of potential complication during the procedure.

A mention required the rehabilitation nurse involved in the early postoperative period: a protocol of daily exercises is basilar for a quick recovery of pulmonary functions and good expectoration.

Postoperative management

A patient underwent a VATS SL must be enrolled in a fast-track surgery protocol if fit.

The meaning is that the extent of the pulmonary resection is not a contraindication.

The post-operative management is finalised to early mobilisation to allow the patient make a cough and valid expectoration. Short fluid administration, early removal of the urinary catheter (within the first 48 hours) and of the chest drain is preferable.

Prophylactic use of antibiotics is needed.

Chest X-ray from the post-operative day (POD) one to three provides good information about the residual lung ventilation and may address the physicians to a flexible fiber-optic bronchoscopy or not.

A pre-discharge bronchoscopy to check the bronchial suture is not mandatory, but strongly recommended under the clinical suspicious of dehiscence or bronco-pleural fistula.

Tip, tricks and pitfalls

Various techniques have been described to perform a proper end-to-end bronchial anastomosis. The ability of the surgeon plays a central role in achieving a radical resection and good post-operative outcomes.

Most anastomotic complications depend on the disruption of the blood supply. So, as in open surgery, it is fundamental for the surgeon an optimal knowledge of the bronchial blood supply. Another cause of potential complication is a tensioned anastomosis. To avoid this, an adequate mobilisation of the distal lobe must be achieved. Interrupted or continuous suture makes no significant differences in outcomes. We believe that the surgeon must do as he likes in the choice of the suture (absorbable versus Prolene) if the basic principles are accomplished. In our clinical practice, we use a double running suture of Prolene 3-0 and cover the suture with pericardial fat. Last but not least, don't forget the luminal disparity: in this sense, a small wedge resection of the cartilaginous part of the large bronchus can be accomplished to fashion the diameters.

Potential postoperative complications of a VATS SL may be easy to manage, like sputum retention and atelectasis, or life-threatening like bronco-pleural fistulas or dehiscence of the anastomosis may occur. Dramatic complications, if not treatable by an interventional bronchoscope or a conservative approach, may require a reintervention. A second VATS look is allowed, by the surgeon's experience, but a traditional open approach may offer more safety and chance to success.

Acknowledgements

None.

Footnote

Conflicts of Interest: The authors have no conflicts of interest to declare.

References

1. Thomas CP. Conservative resection of the bronchial tree. *J R Coll Surg Edinb* 1956;1:169-86.
2. Ma Z, Dong A, Fan J, et al. Does sleeve lobectomy concomitant with or without pulmonary artery reconstruction (double sleeve) have favorable results for non-small cell lung cancer compared with pneumonectomy? A meta-analysis. *Eur J Cardiothorac Surg* 2007;32:20-8.
3. Ferguson MK, Lehman AG. Sleeve lobectomy or pneumonectomy: optimal management strategy using decision analysis techniques. *Ann Thorac Surg* 2003;76:1782-8.
4. Roviario G, Rebuffat C, Varoli F, et al. Videoendoscopic pulmonary lobectomy for cancer. *Surg Laparosc Endosc* 1992;2:244-7.
5. Gonzalez-Rivas D, Fernandez R, Fieira E, et al. Uniportal video-assisted thoracoscopic bronchial sleeve lobectomy: first report. *J Thorac Cardiovasc Surg* 2013;145:1676-7.
6. Mahtabifard A, Fuller CB, McKenna RJ. Video-assisted thoracic surgery sleeve lobectomy: a case series. *Ann Thorac Surg* 2008;85:S729-32.
7. Nakanishi K. Video-assisted thoracic surgery lobectomy with bronchoplasty for lung cancer: initial experience and techniques. *Ann Thorac Surg* 2007;84:191-5.
8. Li Y, Wang J. Video-assisted thoracoscopic surgery sleeve lobectomy with bronchoplasty: an improved operative technique. *Eur J Cardiothorac Surg* 2013;44:1108-12.
9. Chen H, Xu G, Zheng B, et al. Initial experience of single port video-assisted thoracoscopic surgery sleeve lobectomy and systematic mediastinal lymphadenectomy for non-small-cell lung cancer. *J Thorac Dis* 2016;8:2196-202.
10. Martin-Ucar AE, Chaudhuri N, Edwards JG, et al. Can pneumonectomy for non-small cell lung cancer be avoided? An audit of parenchymal sparing lung surgery. *Eur J Cardiothorac Surg* 2002;21:601-5.
11. De Leyn P, Dooms C, Kuzdzal J, et al. Revised ESTS guidelines for preoperative mediastinal lymph node staging for non-small-cell lung cancer. *Eur J Cardiothorac Surg* 2014;45:787-98.
12. McKenna RJ Jr, Mahtabifard A, Pickens A, et al. Fast-tracking after video-assisted thoracoscopic surgery lobectomy, segmentectomy, and pneumonectomy. *Ann Thorac Surg* 2007;84:1663-7.
13. Predina JD, Kunkala M, Aliperti LA, et al. Sleeve lobectomy: current indications and future directions. *Ann Thorac Cardiovasc Surg* 2010;16:310-8.
14. Huang J, Li J, Qiu Y, et al. Thoracoscopic double sleeve lobectomy in 13 patients: a series report from multi-centers. *J Thorac Dis* 2015;7:834-42.
15. Gonzalez-Rivas D, Fieira E, Delgado M, et al. Uniportal video-assisted thoracoscopic sleeve lobectomy and other complex resections. *J Thorac Dis* 2014;6:S674-S681.
16. Zhang Z, Yuan F, Yin R, et al. Left upper lobectomy with bronchoplasty in uniportal video-assisted thoracic surgery for bronchial carcinoid. *J Vis Surg* 2016;2:84.
17. Ma Q, Liu D. VATS right upper lobe bronchial sleeve resection. *J Thorac Dis* 2016;8:2269-71.
18. Ma Q, Liu D. VATS right upper lobe bronchial sleeve resection. *Asvide* 2016;3:340. Available online: <http://www.asvide.com/articles/1109>
19. Chen H, Huang L, Xu G, et al. Modified bronchial anastomosis in video-assisted thoracoscopic sleeve lobectomy: a report of 32 cases. *J Thorac Dis* 2016;8:2233-40.
20. Chen H, Huang L, Chen C, et al. Modified bronchial anastomosis technique in singleport video-assisted thoracoscopic surgery (VATS) right middle and lower sleeve lobectomy. *Asvide* 2016;3:335. Available online: <http://www.asvide.com/articles/1104>
21. Han Y, Zhou S, Yu D, et al. Video-assisted thoracic surgery (VATS) left upper sleeve lobectomy with partial pulmonary artery resection. *J Thorac Dis* 2013;5 Suppl 3:S301-3.
22. Han Y, Zhou S, Yu D, et al. VATS left upper sleeve lobectomy with partial pulmonary artery resection. Available online: <http://www.asvide.com/articles/153>
23. Huang J, Li S, Hao Z, et al. Complete video-assisted thoracoscopic surgery (VATS) bronchial sleeve lobectomy. *J Thorac Dis* 2016;8:553-74.
24. He J, Huang J, Li S, et al. Under general anesthesia with double lumen tube, video-assisted thoracoscopic left lower lobe sleeve lobectomy. *Asvide* 2016;3:154. Available online: <http://www.asvide.com/articles/909>

doi: 10.21037/jovs.2017.03.03

Cite this article as: Davoli F, Bertolaccini L, Pardolesi A, Solli P. Video-assisted thoracoscopic surgery bronchial sleeve lobectomy. *J Vis Surg* 2017;3:41.