



## Case Report

# Giant palmar lipoma – an unusual cause of carpal tunnel syndrome<sup>☆</sup>



Gaizka Ribeiro\*, Marta Salgueiro, Miguel Andrade, Victor Santos Fernandes

Hospital de Santa Maria (CHLN), Serviço de Cirurgia Plástica, Lisboa, Portugal

### ARTICLE INFO

#### Article history:

Received 14 July 2016

Accepted 16 August 2016

Available online 14 August 2017

#### Keywords:

Lipoma

Carpal tunnel syndrome

Hand

Median nerve

#### Palavras-chave:

Lipoma

Síndrome do túnel carpal

Mão

Nervo mediano

### ABSTRACT

Lipoma is a quite common type of soft-tissue tumor, but it is rarely found in the hand. Hand lipomas are generally asymptomatic; however, when they become too large or when they are present in some specific location, they can cause symptoms due to compression of the median nerve. These tumors must be correctly characterized preoperatively with imaging exams and the proper management is the complete removal of the tumor and release of the median nerve. The authors present the case of a female patient with carpal tunnel syndrome due to compression of the median nerve by a giant palmar lipoma, successfully treated with tumor excision and nerve release.

© 2017 Sociedade Brasileira de Ortopedia e Traumatologia. Published by Elsevier Editora Ltda. This is an open access article under the CC BY-NC-ND license (<http://creativecommons.org/licenses/by-nc-nd/4.0/>).

### Lipoma palmar gigante – Uma causa pouco usual de síndrome do túnel cárpico

#### RESUMO

O lipoma é um tumor frequente dos tecidos moles, mas a sua localização na mão é rara. Os lipomas da mão geralmente são assintomáticos; contudo, quando apresentam um grande crescimento ou em determinadas localizações, podem causar sintomas devido à compressão do nervo mediano. Esses tumores devem ser devidamente caracterizados pré-operatoriamente com um exame de imagem e seu correto tratamento baseia-se na sua excisão completa e liberação do nervo mediano. Apresentamos o caso clínico de uma paciente com o diagnóstico de síndrome do túnel carpal resultante de compressão do nervo mediano por um lipoma palmar gigante, tratada com sucesso com lipectomia e decompressão nervosa.

© 2017 Sociedade Brasileira de Ortopedia e Traumatologia. Publicado por Elsevier Editora Ltda. Este é um artigo Open Access sob uma licença CC BY-NC-ND (<http://creativecommons.org/licenses/by-nc-nd/4.0/>).

<sup>☆</sup> Paper developed at Hospital de Santa Maria (CHLN), Serviço de Cirurgia Plástica, Lisbon, Portugal.

\* Corresponding author.

E-mail: [akziag@sapo.pt](mailto:akziag@sapo.pt) (G. Ribeiro).

<http://dx.doi.org/10.1016/j.rboe.2017.08.001>

2255-4971/© 2017 Sociedade Brasileira de Ortopedia e Traumatologia. Published by Elsevier Editora Ltda. This is an open access article under the CC BY-NC-ND license (<http://creativecommons.org/licenses/by-nc-nd/4.0/>).

## Introduction

Lipomas are very frequent benign soft tissue tumors,<sup>1-8</sup> but their incidence in the hand is rare.<sup>1-6</sup> Lipomas are considered giant tumors when they are 5 cm<sup>2,3</sup> or more in diameter, and they generally behave as asymptomatic tumefactions, of slow and progressive growth<sup>5,8</sup>; however, sometimes they can lead to symptomatology due to compression of adjacent structures.<sup>1-3,5,8,9</sup> Peripheral nerve compression by lipomas is very uncommon. Few cases of carpal tunnel syndrome resulting from median nerve compression by a lipoma are described in the literature.<sup>4,6</sup> The anatomic particularities of the hand require special care in the diagnostic and therapeutic approach to these tumors.<sup>3</sup> In this article we describe a clinical case of a seventy-year-old female patient with a diagnosis of giant palmar lipoma that leads to carpal tunnel syndrome, successfully treated with a lipectomy and release of the anterior annular ligament of the carpus.

## Clinical case

A seventy-year-old female, leucodermic patient, was referred to a plastic surgery consultation by the attending physician due to swelling on the palmar side of the left hand (non-dominant hand), with progressive growth over the last year, and complaints of paresthesia and pain in the first three fingers of the left hand. The patient underwent a computed axial tomography of the hand and wrist required by her physician, which revealed a formation of adipose density with some fine internal septations, with well-defined contours, intramuscular location with extension to the deep spaces of the hand and with about 6.5 cm of cross-sectional axis and 6.5 of longitudinal axis, findings suggesting the diagnosis of giant palmar lipoma (Fig. 1)

On examination, the patient had a palpable, movable mass at the level of the thenar eminence, of soft and painless consistency (Fig. 2). The percussion of the mass triggered complaints of paresthesia of the first three fingers of the left hand (positive Tinel's sign). The patient had no motor complaints of the hand, with preservation of strength and digital pincer function. Axillary adenopathies were not palpable.

An electromyography of the wrist was done, which identified aspects consistent with marked left median nerve lesion.

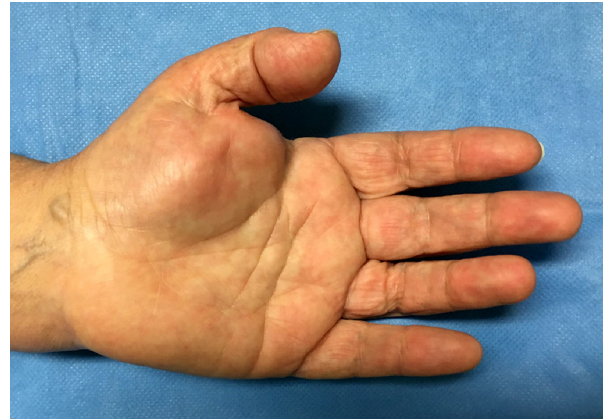

Fig. 2 – Swelling of the thenar eminence.

With the diagnosis obtained, surgical treatment was proposed to the patient. In a supine position, under brachial plexus anesthesia and controlled ischemia of the upper limb with a pneumatic tourniquet, tumor excision was performed. Through a palmar incision, the palmar fascia was opened and the tumor was dissected and excised (Fig. 3). The median nerve and its branches were duly identified and preserved (Fig. 4). The anterior annular carpal ligament was sectioned. After revision of the hemostasis, the incision was closed in a single plane with non-absorbable sutures under passive drainage. The procedure lasted for about 2 h and there were no complications. The patient was discharged on the same day and was followed up at an outpatient clinic. The anatomopathological result confirmed the diagnosis of lipoma.

After five months, there was reversion of complaints of paresthesia and pain of the first three fingers of the hand. During this period, no clinical signs of tumor recurrence were identified, and there was good wound healing (Fig. 5).

## Discussion

Lipomas are the most frequent tumors in the human body<sup>1-8</sup>; however, their location in the hand is rare,<sup>1-6</sup> which is a challenge in terms of a diagnostic and therapeutic approach.<sup>3</sup>

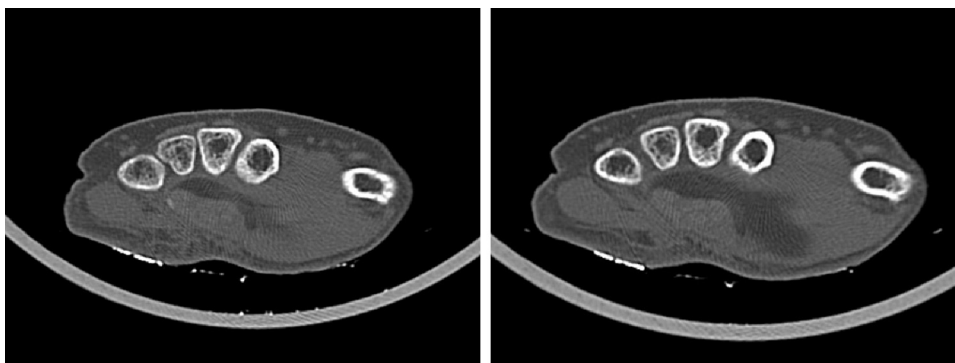
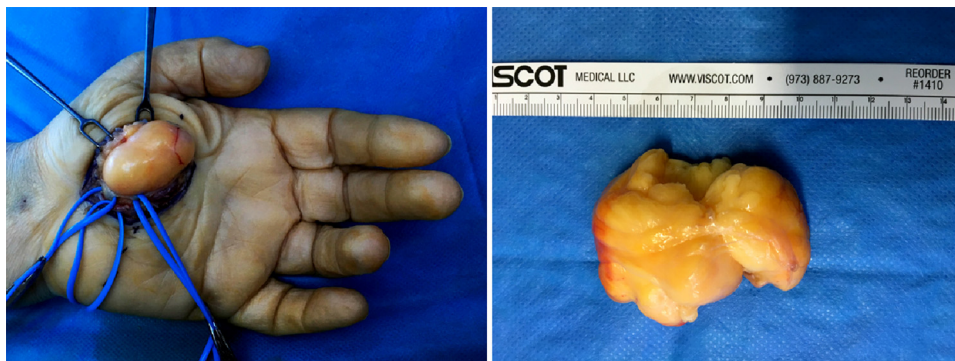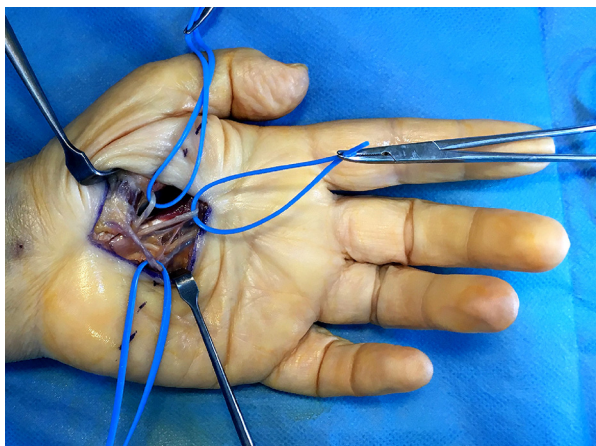


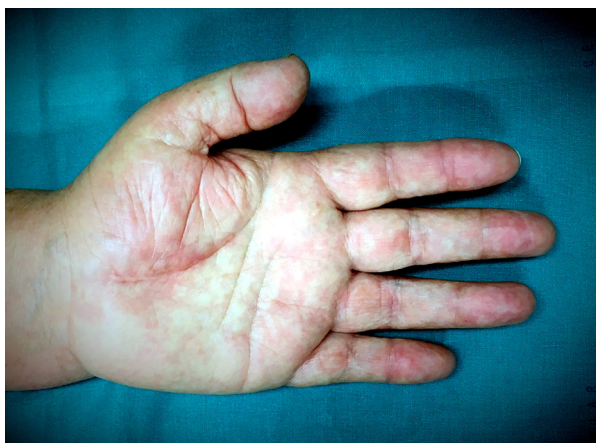Fig. 1 – Preoperative hand axial computed tomography.



**Fig. 3 – Intraoperative photo of palmar lipoma.**



**Fig. 4 – Intraoperative photo where the median nerve and branches can be seen.**



**Fig. 5 – Postoperative photo after five months.**

Hand lipoma has a higher incidence in individuals between 50 and 60 years and is generally asymptomatic, revealing itself as a mobile and painless mass of progressive growth. Sometimes, when it becomes massive or in certain locations, it can cause symptoms resulting from nervous compression.<sup>1-4,6,8,9</sup> Intramuscular or subfascial giant lipomas of the hand (>5 cm of diameter) can be the cause of carpal tunnel syndrome; there are few cases described in the literature.<sup>6</sup>

When carpal tunnel syndrome secondary to giant lipoma is suspected, hand imaging (ideally a computed axial tomography or magnetic resonance imaging) is essential, allowing a better characterization of the size and location of the tumor, as well as its relation with the neighboring vascular and nerve structures.<sup>1-4,6,8,9</sup> These exams are also important to establish the differential diagnosis with malignant tumors, because these hand tumors of more than 5 cm of diameter are highly suggestive of malignancy.<sup>2,3,6,7</sup> A wrist electromyogram is equally indispensable for documenting the nerve lesion.<sup>3,6</sup>

The treatment of these patients involves tumor excision and median nerve release in the carpal tunnel. A monoblock excision of the lipoma should be ideally done, with careful dissection that allows the identification and preservation of all vascular and nerve structures adjacent to the tumor, to reduce the risk of iatrogenic injury.<sup>1,3,6,8,9</sup>

Although hand lipomas are rare, they should not be neglected as a possible case of median nerve compression in the carpal tunnel. Its correct treatment relies on the adequate tumor topographic characterization, on a surgical approach that preserves the anatomic structures involved, and on a complete excision, reducing the risk of recurrence.

### Conflicts of interest

The authors declare no conflicts of interest.

### REFERENCES

1. Mohan L, Semoes J. Thenar intramuscular lipoma: an unusual case. *Internet J Surg.* 2007;17:1-3. Available from: <http://print.ispub.com/api/0/ispub-article/9785>.
2. Yildiran G, Akdag O, Karamese M, Selimoglu M, Tosun Z. Giant lipomas of the hand. *Hand Microsurg.* 2015;4(1):8-11.
3. Fazilleau F, Williams T, Richou J, Sauleau V, Nen D. Median nerve compression in carpal tunnel caused by a giant lipoma. *Case Rep Orthop.* 2014;2014:1-5. Available from: <http://www.hindawi.com/journals/crior/2014/654934/>.
4. Azwa N, Shalimar A, Jamari S. A palmar lipoma with median and ulnar nerve compressive symptoms. *Malays Orthop J.* 2007;1:33-5.
5. Oviedo E, Roca P, Compañía F, Bueno J. Lipoma arborescente, tumor poco frecuente como causa de sinovite extensora de la mano. *Rev Iberoam Cir Mano.* 2015;43:111-6.

- 
6. Sbai MA, Benzarti S, Msek H, Boussen M, Khorbi A. Carpal tunnel syndrome caused by lipoma: a case report. *Pan Afr Med J.* 2015;22:51.
  7. Morales C, López J, Gargollo C, Jiménez Y. Hand lipoma, surgical en clinically na underestimated tumor. *Cir Plást Iberolatinoam.* 2011;37:349-53.
  8. Nadar MM, Bartoli CR, Kasdan ML. Lipomas of the hand: a review and 13 patient case series. *Eplasty.* 2010;10:e66.
  9. Ramirez-Montaña L, Lopez RP, Ortiz NS. Giant lipoma of the third finger of the hand. *Springerplus.* 2013;2(1):164.