

Bilateral Contrast-enhanced Dual-Energy Digital Mammography: Feasibility and Comparison with Conventional Digital Mammography and MR Imaging in Women with Known Breast Carcinoma¹

Maxine S. Jochelson, MD
D. David Dershaw, MD
Janice S. Sung, MD
Alexandra S. Heerdt, MD
Cynthia Thornton, RT(R)(M)
Chaya S. Moskowitz, MD
Jessica Ferrara, BS
Elizabeth A. Morris, MD

¹From the Department of Radiology, Memorial Sloan-Kettering Cancer Center, 1275 York Ave, New York, NY 10065. From the 2010 RSNA Annual Meeting. Received May 15, 2012; revision requested June 27; revision received July 23; accepted August 17; final version accepted September 7. Supported in part by GE Healthcare. Address correspondence to M.S.J. (e-mail: jochelsm@mskcc.org).

© RSNA, 2012

Purpose:

To determine feasibility of performing bilateral dual-energy (DE) contrast agent-enhanced (CE) digital mammography and to evaluate its performance compared with conventional digital mammography and breast magnetic resonance (MR) imaging in women with known breast cancer.

Materials and Methods:

This study was approved by the institutional review board and was HIPAA compliant. Written informed consent was obtained. Patient accrual began in March 2010 and ended in August 2011. Mean patient age was 49.6 years (range, 25–74 years). Feasibility was evaluated in 10 women with newly diagnosed breast cancer who were injected with 1.5 mL per kilogram of body weight of iohexol and imaged between 2.5 and 10 minutes after injection. Once feasibility was confirmed, 52 women with newly diagnosed cancer who had undergone breast MR imaging gave consent to undergo DE CE digital mammography. Positive findings were confirmed with pathologic findings.

Results:

Feasibility was confirmed with no adverse events. Visualization of tumor enhancement was independent of timing after contrast agent injection for up to 10 minutes. MR imaging and DE CE digital mammography both depicted 50 (96%) of 52 index tumors; conventional mammography depicted 42 (81%). Lesions depicted by using DE CE digital mammography ranged from 4 to 67 mm in size (median, 17 mm). DE CE digital mammography depicted 14 (56%) of 25 additional ipsilateral cancers compared with 22 (88%) of 25 for MR imaging. There were two false-positive findings with DE CE digital mammography and 13 false-positive findings with MR imaging. There was one contralateral cancer, which was not evident with either modality.

Conclusion:

Bilateral DE CE digital mammography was feasible and easily accomplished. It was used to detect known primary tumors at a rate comparable to that of MR imaging and higher than that of conventional digital mammography. DE CE digital mammography had a lower sensitivity for detecting additional ipsilateral cancers than did MR imaging, but the specificity was higher.

© RSNA, 2012

Breast cancer is diagnosed in approximately 200 000 American women every year and is their second leading cause of cancer death (1). Mammography is the only imaging modality that has been shown to reduce mortality from breast cancer, but it is an imperfect tool with an overall sensitivity of 75%–85%, which drops as low as 30%–50% in women with a *BRCA* gene mutation (2–6). Specificity is limited; positive predictive value of a biopsy recommendation is in the 25%–45% range (7). For staging, sensitivity may be even poorer, with missed multifocal or multicentric disease resulting in incorrect treatment options being offered to the patient.

Better depiction is possible with contrast agent-enhanced (CE) breast magnetic resonance (MR) imaging. This is owing to its ability to map abnormal blood flow related to neovascularity associated with carcinoma. The sensitivity of MR imaging for the depiction of breast carcinoma has been reported in the 79%–98% range (8,9). It is the most accurate method for determining the size of invasive breast cancer, although it may overestimate the size of ductal carcinoma in situ (DCIS) (10). A meta-analysis of 19 studies has shown that MR imaging depicts mammographically occult multicentric or multifocal disease in 16% of patients (11). These additional findings have led to management changes in 10%–20% of patients (12,13), particularly in women with tumors larger than 4 cm, lobular cancers, and dense breast tissue (14). With the advent of preoperative staging breast MR imaging,

clinically and mammographically occult contralateral cancers have been detected in 3%–5% of women (15).

Although breast MR imaging is extremely sensitive, specificity is limited, leading to additional workups and benign biopsies (16). Additionally, good quality breast MR imaging is expensive, time-consuming, and not universally available. Patients with pacemakers, certain aneurysm clips or other metallic hardware, an allergy to contrast agents, or severe claustrophobia are unable to undergo MR imaging.

If mammography could map blood flow, some of its shortcomings in cancer depiction might be obviated. It could then be substituted for MR imaging in those patients who are not candidates for MR imaging.

The development of dual-energy (DE) CE digital mammography has made the clinical use of intravenous contrast enhancement with mammography a possibility. Its use has been previously reported in studies involving imaging of only a single breast (17,18). Our study was undertaken to ascertain if bilateral two-view DE CE digital mammography was possible and to compare its ability to depict and to be used to stage known breast cancers with that of conventional digital mammography and MR imaging.

Materials and Methods

GE Healthcare (Buc, France) provided the equipment upgrade for this study, as well as partial financial support for the performance of the examinations and research staff. The authors had complete control of the data and the information submitted for publication.

Institutional review board approval was obtained for this Health Insurance Portability and Accountability Act-compliant study. Written informed consent was obtained. Patient accrual began in

Implication for Patient Care

- If DE CE digital mammography is able to depict breast cancers in a fashion similar to that of MR imaging, it could potentially be used in staging breast cancer.

March 2010 and ended in August 2011. Patients with newly diagnosed unilateral breast cancer (index lesions were biopsy proved) were referred by their breast surgeons. All patients were required to have two breasts without implants and to be older than 21 years. Patients with any renal insufficiency or contrast agent allergy were excluded. Patients who were pregnant, possibly pregnant, or lactating were excluded. Patients who were not undergoing surgery as their initial treatment were also excluded.

Conventional digital mammograms were obtained for all patients either at our institution or at other centers, which were reviewed either by hard or soft copy. The person interpreting the DE CE digital mammograms (M.S.J., D.D.D., and J.S.S., with 4–30 years of breast imaging experience) interpreted the conventional digital mammograms for study purposes.

DE CE digital mammography was performed by using a digital mammography unit (Seno DS; GE, Buc, France) that had been adapted to obtain two images in each view: a low-energy image (below the k edge of iodine [33.2 keV]) and a high-energy image (above the k edge). The tube voltage used depended on the breast thickness and glandularity and ranged from 26 to 30 kVp for low-energy acquisition and from 45 to

Advances in Knowledge

- Bilateral dual-energy (DE) contrast agent-enhanced (CE) digital mammography is feasible.
- DE CE digital mammography can be used to detect breast cancer by demonstrating enhancement of neovascularity associated with breast cancer.
- DE CE digital mammography depicted additional cancers in the breast with better specificity than did MR imaging.

Published online before print

10.1148/radiol.12121084 **Content codes:** BR DM

Radiology 2013; 266:743–751

Abbreviations:

CE = contrast agent enhanced

CI = confidence interval

DCIS = ductal carcinoma in situ

DE = dual energy

Author contributions:

Guarantor of integrity of entire study, M.S.J.; study concepts/study design or data acquisition or data analysis/interpretation, all authors; manuscript drafting or manuscript revision for important intellectual content, all authors; manuscript final version approval, all authors; literature research, M.S.J., D.D.D., J.S.S.; clinical studies, M.S.J., D.D.D., A.S.H., C.T., J.F., E.A.M.; experimental studies, M.S.J., C.T., J.F., E.A.M.; statistical analysis, C.S.M., J.F.; and manuscript editing, M.S.J., D.D.D., J.S.S., A.S.H., C.T., E.A.M.

Conflicts of interest are listed at the end of this article.

49 kVp for high-energy acquisition. The DE recombination algorithm was dedicated to processing the low- and high-energy images into iodine images. The algorithm, which used the low- and high-energy x-ray spectra and the compressed breast thickness as input, was designed to suppress the background breast tissue for all breast thicknesses and types to highlight the iodine-enhanced areas. It used an image chain model to simulate the signal intensity levels for varying glandular percentages and iodine thicknesses and derived the mathematical form of the combination of the low- and high-energy images that resulted in an iodine image. The recombination algorithm ensured the visibility of iodine at a concentration of 0.5 mg/cm, which is lower than the clinically expected concentration. Mammography Quality Standards Act guidelines for quality control of the performance and interpretation of mammograms were followed. Additional radiation dose was approximately 20% that of routine full-field digital mammography or the equivalent of one additional view.

Thirty-one patients had their MR imaging and DE CE digital mammography examinations performed on the same day. The order was not randomized and depended on scheduling availability. The time between the examinations was greater than an hour.

Intravenous injection of contrast agent was performed prior to patient positioning. Patients received 1.5 mL of contrast agent per kilogram of body weight at an injection speed of 3 mL/sec, which is the same dose used for computed tomography. Imaging began 2.5–5 minutes after the injection and continued for 3–5.1 minutes, with a mean imaging time of 3.6 minutes. In one patient, imaging lasted 10 minutes after completion of the contrast agent injection. Although two initial examinations were satisfactorily completed by using Omnipaque 300 (iohexol, GE, Shanghai, China), conspicuity of lesions was subjectively improved with the use of Omnipaque 350 (iohexol, GE, Shanghai, China).

Patient positioning and performance of DE CE digital mammography

were no different from those of conventional mammography, because the intravenous line was disconnected prior to positioning. None of the patients experienced nausea or vomiting. No contrast agent reactions occurred.

Image analysis was performed by one of three breast imagers (M.S.J., D.D.D., J.S.S.). Six training cases, which included corresponding ultrasonographic (US) images, MR images, and pathologic proof, were reviewed before enrollment of patients into the study. Lesions that showed enhancement beyond breast background were considered to be abnormal. Analysis of the DE CE digital mammogram and MR images was performed with the conventional digital mammogram available. MR imaging was interpreted by one of 10 breast imagers (including M.S.J., D.D.D., J.S.S., and E.A.M., with 4–30 years of breast imaging experience) while blinded to DE CE digital mammography results. If the person reading the MR image had read the DE CE digital mammogram, another radiologist was assigned to read the breast MR image for that patient. DE CE digital mammography interpretation was performed with the reader blinded to MR imaging results. The breast imager interpreting the DE CE digital mammogram was blinded to the MR imaging results for that patient.

Feasibility

Ten women comprised the feasibility portion of the study. These patients were not included in the group of patients whose examinations were compared with conventional digital mammography and MR imaging. Patients in the feasibility phase ranged in age from 38 to 64 years, with a mean age of 51.6 years.

Varying orders of imaging were randomly attempted in 15 patients: craniocaudal and mediolateral oblique views of the unaffected breast followed by those of the affected breast; craniocaudal view of the affected breast followed by craniocaudal and mediolateral oblique views of the unaffected breast in the same order; and craniocaudal view of the unaffected breast followed

by that in the affected breast and then mediolateral oblique views in the same order.

Parameters used to determine the technical adequacy of the CE mammograms were based on standard parameters used in the daily evaluation of unenhanced mammograms. To assess spatial and contrast resolution, we used mammography phantoms used in daily quality assurance. Mammographic images were evaluated to ensure that the entire breast, from chest wall to nipple, was included on each image. Image quality was assessed as satisfactory or not with respect to image sharpness, presence of artifacts, and blurring of the images by one of the three DE CE digital mammography-trained imagers (M.S.J., D.D.D., J.S.S.).

Comparison of DE CE Mammography to MR Imaging

Seventy-two women gave consent to participate in this part of the study. Their ages ranged from 25 to 74 years (mean, 48.9 years). Thirteen MR examinations were performed at outside centers, and 39 were performed at our institution. The time between MR imaging and DE CE digital mammography ranged from 0 to 28 days (mean, 6 days; median, 0 days). Both low-energy and postcontrast subtraction images were evaluated to determine the location and size of the index cancer, the presence of additional sites of disease, and the distance between disease sites, which was used to determine whether surgery would involve conservation (multifocal disease) or mastectomy (multicentric disease). The size of the index lesion (both infiltrative and in situ components) was believed to be accurate if it was not more than 0.5 cm different from the size of the lesion described at lumpectomy or mastectomy. Any finding that would modify patient treatment was confirmed with biopsy. There were no suspicious lesions seen at DE CE mammography that were not also seen at either conventional mammography or MR imaging. Stereotactic, US-guided, or MR imaging-guided core-needle biopsies were performed for all additional lesions. For women undergoing

treatment with mastectomy, findings depicted on images were correlated with pathologic analysis of the mastectomy specimen. Any lesion believed to be probably benign (Breast Imaging Reporting and Data System category 3) was followed up with mammography or MR imaging at 6 months.

Statistical Analysis

We compared DE CE digital mammography alone to conventional mammography alone and to breast MR imaging alone. The breast lesions were the unit of analysis. As such, it is impossible to estimate the specificity and false-positive rate (19). Our study used the recommendations of Obuchowski and colleagues (20), who reported the proportion of patients with at least one false-positive finding and the mean number of false-positive findings per patient. In our study, there were no patients who had more than one false-positive finding on either imaging test. Exact binomial 95% confidence intervals (CIs) were computed for this estimate. CIs around an estimate of zero are replaced by one-sided 97.5% CIs. The McNemar exact test was used to evaluate whether there was a significant difference in the mean number of false-positive findings per patient between the two imaging tests. A *P* value of less than .05 was considered to indicate a significant difference.

For analyses restricted to the index lesion, where the reference standard was available for all patients, we provide estimates of the sensitivity of each imaging method with the corresponding 95% CIs. For analyses that include lesions beyond the index lesion, the data were restricted by the fact that, in patients who underwent a lumpectomy rather than a mastectomy, the pathologic reference standard was only available if one of the imaging methods under study showed a lesion. This design leads to extreme verification bias, and it is impossible to directly estimate the sensitivity and negative predictive value. It is, however, possible to compare the sensitivities of MR imaging and DE CE digital mammography and to provide estimates of the relative sensitivity, defined here as

the sensitivity of DE CE digital mammography divided by the sensitivity of MR imaging (21). To test whether the relative sensitivity differed significantly from one, we used a regression framework described in detail by Pepe (section 7.2.4 of reference 22) and fit generalized estimating equations by assuming a binomial family but using a log link function and specifying an independent working correlation structure. Ninety-five percent CIs for the estimated relative sensitivity were formed by using robust standard errors. Positive predictive values were estimated by using all data and were compared in a similar regression framework by using generalized estimating equations (21).

All analyses were performed by using software (Stata 11.2 for Windows; Stata, College Station, Tex).

Results

Eighty-two patients provided consent for the study (10 for the feasibility arm, 72 for the comparison arm).

Feasibility

All 10 of the initial DE CE digital mammograms were of satisfactory quality. Contrast enhancement remained present for up to 10 minutes after the completion of the injection. The order in which the images were obtained did not seem to affect the quality of the images. The final sequence was craniocaudal view in the unaffected breast, craniocaudal view in the affected breast, mediolateral oblique view in the unaffected breast, and then mediolateral oblique view in the affected breast.

There was a ring of increased density surrounding the periphery of the breasts due to radiation scatter, which slightly limited evaluation of the breast periphery.

Comparison to Conventional Mammography and MR Imaging

Of the 72 patients, 20 were excluded for the following reasons: three chose neoadjuvant chemotherapy, three had technical problems with their examinations, four had breasts too large for the detectors, three had MR images that could not

be obtained from an outside facility, two were lost to follow-up, one went elsewhere for care, three withdrew consent, and one patient was withdrawn owing to personal issues at the request of the surgeon. Technical problems included one each of operator error, unit shut down, and delay in image acquisition.

Of the 52 remaining patients, age ranged from 25 to 74 years (mean, 49 years). There were 47 patients with invasive ductal carcinoma with or without DCIS, three patients with infiltrating lobular carcinoma, one patient with DCIS only, and one patient with DCIS with microscopic invasion.

Conventional digital mammography depicted 42 (81% [95% CI: 67%, 90%]) of 52 index cancers. DE CE digital mammography and MR imaging each depicted 50 (96% [95% CI: 87%, 99%]) of 52 index lesions (Fig 1). For depicting the index lesion, the sensitivity of both MR imaging and DE CE digital mammography was 96% (50 of 52; 95% CI: 87%, 99%; *P* > .99). Both imaging tests failed to depict two index lesions, but the two that were missed were different. The lesions missed with DE CE digital mammography were also missed with conventional digital mammography, while the lesions missed with MR imaging were seen with conventional digital mammography and DE CE digital mammography. The relative sensitivity of DE CE digital mammography compared with conventional digital mammography was 1.19 (95% CI: 1.06, 1.34; *P* = .005). The relative sensitivity of MR imaging compared with conventional digital mammography was 1.19 (95% CI: 1.03, 1.38; *P* = .022).

Lesions depicted with DE CE digital mammography ranged from 4 to 67 mm (median, 17 mm). The size of the lesions depicted with DE CE digital mammography approximated pathologic size in all but two patients. In those patients, DE CE digital mammography resulted in overestimation of lesion size by 1 cm in one patient and by 1.7 cm in the other. MR imaging was accurate in both. The two lesions that were occult on DE CE digital mammographic images included a 2-cm infiltrating lobular carcinoma, which manifested as a palpable mass

Figure 1

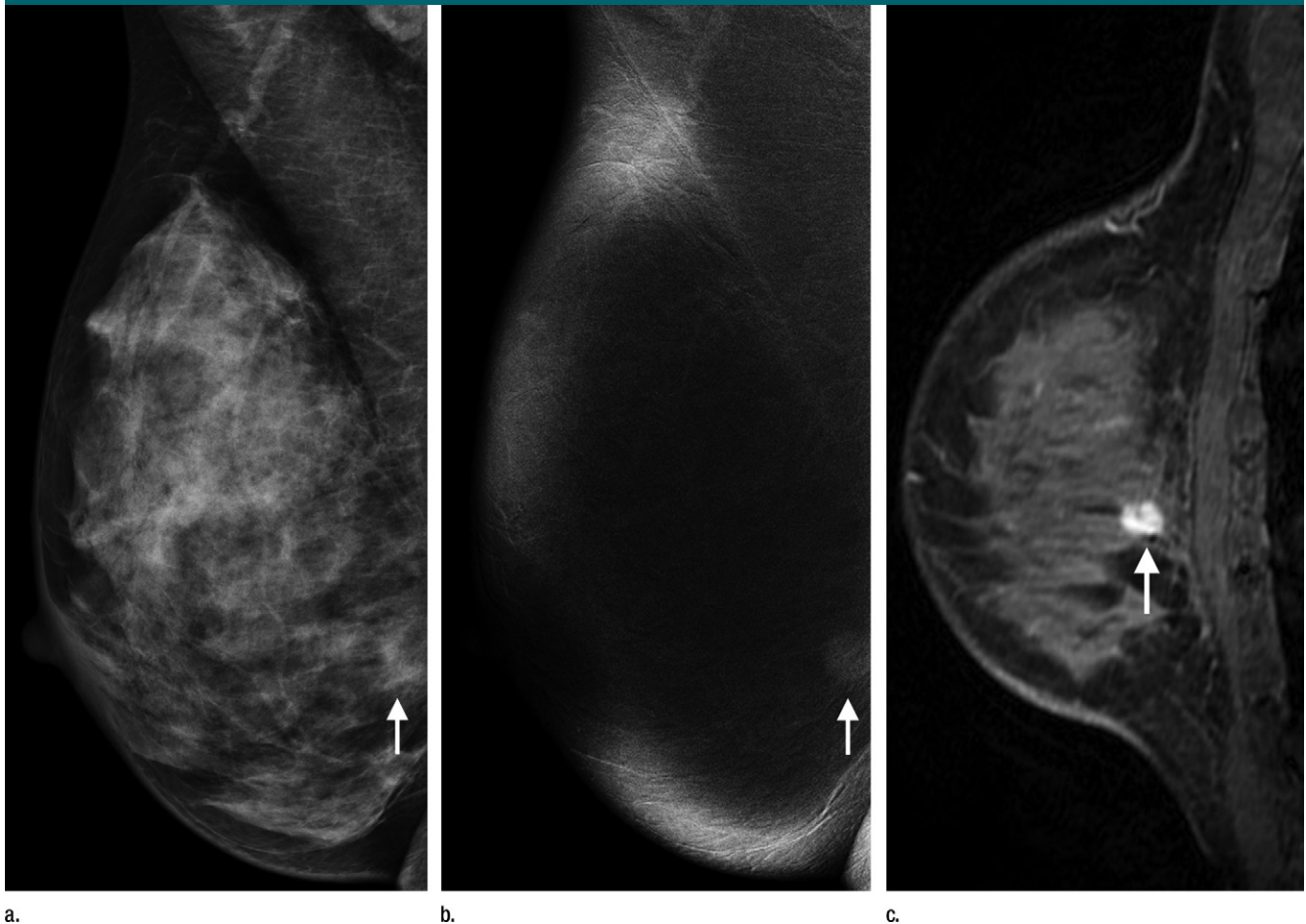


Figure 1: Right (a) mediolateral oblique conventional digital mammographic, (b) DE CE mammographic, and (c) sagittal MR images show infiltrating ductal carcinoma (arrows) of the right breast in 43-year-old woman.

Table 1

Findings beyond the Index Tumor with Each Imaging Method

Finding	Conventional Digital Mammography	DE CE Digital Mammography	MR Imaging
Breasts with additional cancer ($n = 16$)	4 (25)	9 (56)	15 (94)
Additional sites of ipsilateral cancer ($n = 25$)	7 (28)	14 (56)	22 (88)
Contralateral cancer ($n = 1$)	0	0	0

Note.—Data are number of findings. Numbers in parentheses are percentages of total number of findings.

and was seen as multicentric disease with multiple enhancing masses on MR images. The other lesion missed with DE CE digital mammography was a 5-mm invasive ductal carcinoma with associated DCIS. It was seen as a 7-mm area of clumped enhancement on MR

images. The two lesions that were occult on MR images included a 7-mm invasive ductal carcinoma with DCIS that manifested as a 4-mm nodule on conventional mammographic images and as a 4-mm enhancing nodule on DE CE digital mammographic images. The

other occult lesion was an area of DCIS that manifested as a 13-mm cluster of calcifications on conventional mammographic images and as a 14-mm spiculated enhancing mass on DE CE digital mammographic images. There was one case of contralateral breast cancer: It was Paget disease that was not evident on either DE CE digital mammographic or MR images but was found at pathologic analysis after the patient underwent a prophylactic mastectomy.

MR imaging surpassed DE CE digital mammography in ability to depict additional sites of malignancy (Table 1). Sixteen patients had multifocal or multicentric cancers, and MR imaging depicted 15 (94%) of the 16 additional sites, while DE CE digital mammography

Figure 2

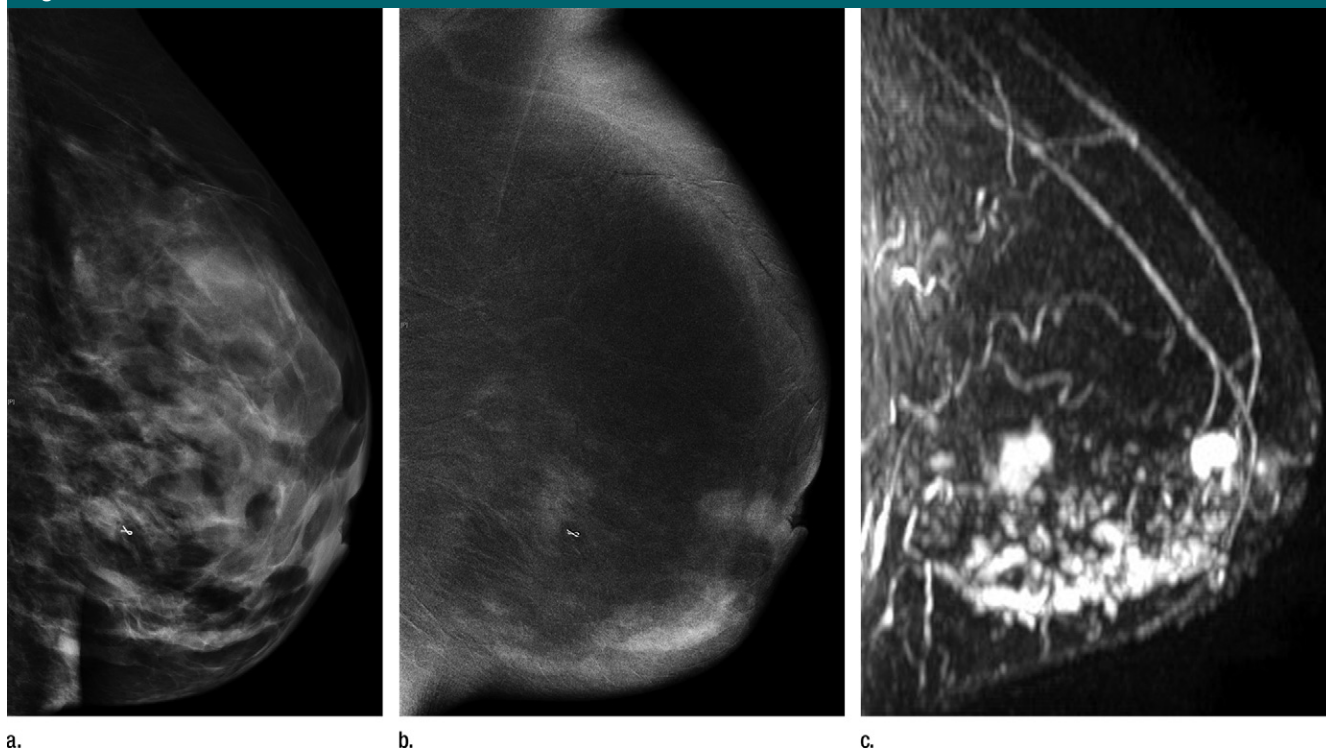


Figure 2: Images in 39-year-old woman with infiltrating ductal carcinoma and extensive DCIS who presented with left breast pain and nipple retraction. **(a)** Left mediolateral oblique conventional digital mammographic image shows dense breast tissue. Left **(b)** mediolateral oblique DE CE mammographic and **(c)** sagittal subtraction MR images show multicentric disease. Marker clip can be seen on **a** and **b**.

depicted just nine (56%). Twenty-five additional ipsilateral lesions were found in these 16 patients. MR imaging depicted 22 (88%), DE CE digital mammography depicted 14 (56%), and conventional digital mammography depicted four (25%). The size of the additional lesions not depicted with DE CE digital mammography ranged from 1 to 15 mm (median, 7 mm). All findings that would modify treatment were confirmed with core-needle biopsy prior to making treatment decisions. Patients were converted from breast conservation to mastectomy if they had biopsy confirmation of multicentric disease. Any additional findings at MR imaging or DE CE digital mammography were correlated with surgical or mastectomy specimens. Regarding changing surgery from conservation to mastectomy, MR imaging was superior in three patients. It was used to detect 100% of the patients requiring mastectomy, while DE CE digital mammography was used to

Table 2

Pathologically Proven Findings that Changed Patient Treatment

Category	Conventional Digital Mammography	DE CE Digital Mammography	MR Imaging
No. of patients with modified treatment (<i>n</i> = 11)	4	8	11
Percentage of patients with modified treatment	36	73	100
Percentage of total patients (<i>n</i> = 52)	8	15	21

identify 73% (Table 2). In determining which women required mastectomy, the addition of DE CE digital mammography or MR imaging to conventional mammography conveyed a considerable advantage (Fig 2).

Of the 52 patients, two (4%; 95% CI: 0%, 13%) had one false-positive finding at DE CE digital mammography, and 13 (25%; 95% CI: 14%, 39%) had one false-positive finding at MR imaging (Table 3). There were two false-positive lesions in the ipsilateral breast at DE CE digital mammography, and biopsy

of both was also recommended at MR imaging. Pathologic analysis identified them as a radial scar and a fibroadenoma. No contralateral false-positive lesions were found at DE CE digital mammography. There were 13 false-positive findings at MR imaging; eight in the ipsilateral breast and five in the contralateral breast. Eight core-needle biopsies and eight additional surgical procedures were performed as a result of these false-positive findings. Biopsy results yielded the following: one radial scar, two fibroadenomas, two papillary

Table 3

False-Positive Findings

Category	Ipsilateral Breast		Contralateral Breast	
	DE CE Digital Mammography	MR Imaging	DE CE Digital Mammography	MR Imaging
No. of patients with false-positive findings	2	8	0	5
Percentage of patients with false-positive findings ($n = 13$)	15	62	0	38
Percentage of total patients ($n = 52$)	4 (0, 13)	15 (7, 28)	0 (0, 13)	10 (3, 21)

Note.—Data in parentheses are 95% CIs.

lesions, three cases of atypical ductal hyperplasia, one atypical lobular hyperplasia, and four cases of benign tissue. None of the high-risk lesions were upgraded at surgery.

An enhancing lesion seen on DE CE digital mammographic images was significantly more likely to be malignant than one seen on MR images, with a positive predictive value of 97% (64 of 66) for DE CE digital mammography and of 85% (72 of 85) for MR imaging ($P < .01$).

Discussion

Prior investigators have reported on the ability of DE CE digital mammography to depict breast cancers. Early studies were performed by using a temporal subtraction technique. Patients were injected with contrast agent after a baseline image while the breast was compressed, and up to seven additional images were obtained after injection. Subtraction was performed, yielding both kinetic curves and a CE image. By using this technique, Jong et al (23) depicted enhancement in eight of 10 patients with breast cancer. None was depicted in seven of 12 benign lesions. Dromain et al (24) depicted enhancement in 16 of 20 patients with carcinoma and found that the size of the area of enhancement correlated with the histologic size of the cancer. Despite this initial success, this technique had limitations. Motion artifacts were a problem owing to long imaging times. Additionally, only a single view of one breast could be evaluated per injection.

Initial feasibility trials of DE CE digital mammography were conducted by Lewin et al (25) with a digital mammography unit that was not designed for contrast agent use. Nevertheless, they were able to perform two low- and high-energy views of a single breast after contrast agent injection. They identified 13 of 13 cancers. Two benign lesions enhanced weakly. Since then, hardware and software adaptations that automate the DE technique have been developed. By using this technology, Dromain et al (26) reported a comparison of DE CE digital mammography and unenhanced conventional mammography to mammography alone and to mammography with US in 142 lesions in 120 patients. Sensitivity for DE CE digital mammography with conventional mammography was 93% versus 78% for conventional mammography alone ($P < .001$). Specificity was unchanged. There was no significant improvement in sensitivity and specificity between DE CE digital mammography with conventional and US with conventional mammography.

Our findings demonstrated that bilateral DE CE digital mammography was easily accomplished and well tolerated. As opposed to the rapid washout seen with MR imaging, enhancement with DE CE digital mammography remained present for at least 10 minutes after contrast agent infusion was complete. As such, the order in which the images were obtained did not appear to be critical. It is uncertain why there is a difference in enhancement curves between MR imaging and DE CE digital mammography. Differences in molecular

structure between gadolinium and iohexol may contribute to this.

We were able to show that DE CE digital mammography was comparable to MR imaging for the depiction of the index tumor in patients with known breast cancer. Each identified 50 (96%) of 52 lesions. This was significantly better than conventional digital mammography, which only depicted 42 (81%) of 52. This percentage is comparable to that reported in screening studies. Conventional mammography failed to depict both cancers missed with DE CE digital mammography. Those not seen with MR imaging were found with conventional mammography. Owing to the small number of missed index lesions, no distinct pattern could be discerned. DE CE digital mammographic images did not depict disease in one of the three patients with infiltrating lobular carcinoma. This patient had an enhancing mass on MR images. The second occult lesion was a 5-mm invasive ductal carcinoma, which was seen as clumped enhancement on MR images without a discrete mass. Of the two lesions not depicted by using MR imaging, one was pure DCIS, and the other was a small area of invasive ductal carcinoma with DCIS.

DE CE digital mammography depicted lesions independent of size, depicting cancers as small as 4 mm. The size range of cancers missed was 1–20 mm, with a median of 7 mm. It appears that the usefulness of this test was not a function of size but, rather, a function of histologic characteristics of the individual tumors and contrast agent pharmacology. This is a functional imaging technique more similar to MR imaging than to unenhanced mammography. Tumor size on DE CE digital mammographic images was an accurate indicator of histologic size of the tumor, with measurements on DE CE digital mammographic images corresponding to pathologic size in all but two patients. Accuracy of tumor measurement is important in determining surgical treatment.

Breast cancers are often multifocal and multicentric (27). Additional foci of ipsilateral breast cancer are often

mammographically occult and are identified more frequently with MR imaging (10). The advantage of MR imaging in staging needs to be balanced with its disadvantages: greater expense, lack of accessibility, and the frequency of false-positive examinations. False-positive examinations lead to an increased number of biopsies and of patients choosing mastectomies and delay the time to definitive treatment (28–30). Among our patients, DE CE digital mammography was less sensitive than MR imaging but resulted in fewer false-positive findings. The size of additional lesions not depicted by DE CE digital mammography ranged from 1 to 15 mm, with a median of 7 mm. Of the additional lesions found with DE CE digital mammography, only two were benign, and both were also seen on MR images. However, MR imaging was used to identify 100% of the patients requiring mastectomy, while DE CE digital mammography helped identify 73%. These data suggest that DE CE digital mammography has the potential to be a valuable additional imaging tool in women with breast cancer for assisting in selecting the correct surgical procedure. These data also raise the question of the potential value of DE CE digital mammography in evaluating symptomatic women or in screening women with dense breasts or elevated breast cancer risk. Because all women in this study were known to have carcinoma, the ability of DE CE digital mammography to depict carcinoma reliably in a screening setting or in the evaluation of symptomatic women has not been tested and remains unknown.

Our study had several limitations. The number of patients studied was small. There were no standardized objective methods of image quality evaluation or phantoms. Therefore, in the evaluations of image quality in general and in terms of timing and order of image acquisition, only subjective opinions could be rendered. Our study was performed by using a prototype unit. There is a ring of increased density surrounding the periphery of the breasts owing to radiation scatter, which limited evaluation of this region; subtle

areas of enhancement could potentially be obscured as a result, although this was not the case in any of our patients. This technology has undergone additional development and modification since the manufacture of the unit used in our study. How the technical modifications will change the usefulness of this equipment is unknown.

Bilateral DE CE digital mammography is feasible and easily accomplished. It depicted known primary tumors at a rate comparable to that of MR imaging and higher than that of conventional digital mammography. DE CE digital mammography had a lower sensitivity for depicting additional ipsilateral cancers compared with MR imaging, but the specificity was higher.

Acknowledgment: The authors thank David Caumartin, without whose insight and support this project would never have been possible.

Disclosures of Conflicts of Interest: M.S.J. Financial activities related to the present article: GE Healthcare provided some funding to pay for the actual research per patient, but authors were completely in control of the patients and data. Financial activities not related to the present article: author receives payment for lecture from Cardinal Health for Webinar on PET/CT. Other relationships: none to disclose. D.D.D. No relevant conflicts of interest to disclose. J.S.S. No relevant conflicts of interest to disclose. A.S.H. No relevant conflicts of interest to disclose. C.T. No relevant conflicts of interest to disclose. C.S.M. No relevant conflicts of interest to disclose. J.F. No relevant conflicts of interest to disclose. E.A.M. No relevant conflicts of interest to disclose.

References

- Jemal A, Bray F, Center MM, Ferlay J, Ward E, Forman D. Global cancer statistics. *CA Cancer J Clin* 2011;61(2):69–90.
- Kerlikowske K, Carney PA, Geller B, et al. Performance of screening mammography among women with and without a first-degree relative with breast cancer. *Ann Intern Med* 2000;133(11):855–863.
- Kuhl CK, Schmutzler RK, Leutner CC, et al. Breast MR imaging screening in 192 women proved or suspected to be carriers of a breast cancer susceptibility gene: preliminary results. *Radiology* 2000;215(1):267–279.
- Warner E, Plewes DB, Hill KA, et al. Surveillance of BRCA1 and BRCA2 mutation carriers with magnetic resonance imaging, ultrasound, mammography, and clinical breast examination. *JAMA* 2004;292(11):1317–1325.
- Leach MO, Boggis CR, Dixon AK, et al. Screening with magnetic resonance imaging and mammography of a UK population at high familial risk of breast cancer: a prospective multicentre cohort study (MARIBS). *Lancet* 2005;365(9473):1769–1778.
- Kriege M, Brekelmans CT, Boetes C, et al. Efficacy of MRI and mammography for breast-cancer screening in women with a familial or genetic predisposition. *N Engl J Med* 2004;351(5):427–437.
- Van Ongeval C, Van Steen A, Vande Putte G, et al. Does digital mammography in a decentralized breast cancer screening program lead to screening performance parameters comparable with film-screen mammography? *Eur Radiol* 2010;20(10):2307–2314.
- Morris EA, Liberman L, Ballon DJ, et al. MRI of occult breast carcinoma in a high-risk population. *AJR Am J Roentgenol* 2003;181(3):619–626.
- Berg WA. Rationale for a trial of screening breast ultrasound: American College of Radiology Imaging Network (ACRIN) 6666. *AJR Am J Roentgenol* 2003;180(5):1225–1228.
- Esserman LJ, Kumar AS, Herrera AF, et al. Magnetic resonance imaging captures the biology of ductal carcinoma in situ. *J Clin Oncol* 2006;24(28):4603–4610.
- Houssami N, Hayes DF. Review of preoperative magnetic resonance imaging (MRI) in breast cancer: should MRI be performed on all women with newly diagnosed, early stage breast cancer? *CA Cancer J Clin* 2009;59(5):290–302.
- Fischer U, Kopka L, Grabbe E. Breast carcinoma: effect of preoperative contrast-enhanced MR imaging on the therapeutic approach. *Radiology* 1999;213(3):881–888.
- Bedrosian I, Mick R, Orel SG, et al. Changes in the surgical management of patients with breast carcinoma based on preoperative magnetic resonance imaging. *Cancer* 2003;98(3):468–473.
- Mann RM, Veltman J, Barentsz JO, Wobbes T, Blickman JG, Boetes C. The value of MRI compared to mammography in the assessment of tumour extent in invasive lobular carcinoma of the breast. *Eur J Surg Oncol* 2008;34(2):135–142.
- Lehman CD, Gatsonis C, Kuhl CK, et al. MRI evaluation of the contralateral breast in women with recently diagnosed breast cancer. *N Engl J Med* 2007;356(13):1295–1303.
- Houssami N, Ciatto S, Macaskill P, et al. Accuracy and surgical impact of magnetic resonance imaging in breast cancer staging: systematic review and meta-analysis in detection

- of multifocal and multicentric cancer. *J Clin Oncol* 2008;26(19):3248–3258.
17. Dromain C, Thibault F, Adler G. Dual energy contrast-enhanced digital mammography: preliminary clinical results [abstr]. In: Radiological Society of North America scientific assembly and annual meeting program. Oak Brook, Ill: Radiological Society of North America, 2007; 326.
 18. Diekmann F, Marx C, Jong R, Dromain C, Toledano AY, Bick U. Diagnostic accuracy of contrast-enhanced digital mammography as an adjunct to mammography. Presented at the European Congress of Radiology, Vienna, Austria, May 9, 2007.
 19. Moskowitz CS, Zabor EC, Jochelson M. Breast imaging: understanding how accuracy is measured when lesions are the unit of analysis. *Breast J* 2012;18(6):557–563.
 20. Obuchowski NA, Mazzone PJ, Dachman AH. Bias, underestimation of risk, and loss of statistical power in patient-level analyses of lesion detection. *Eur Radiol* 2010;20(3):584–594.
 21. Leisenring W, Alonzo T, Pepe MS. Comparisons of predictive values of binary medical diagnostic tests for paired designs. *Biometrics* 2000;56(2):345–351.
 22. Pepe MS. The statistical evaluation of medical tests for classification and prediction. Oxford, England: Oxford University Press, 2003.
 23. Jong RA, Yaffe MJ, Skarpathiotakis M, et al. Contrast-enhanced digital mammography: initial clinical experience. *Radiology* 2003;228(3):842–850.
 24. Dromain C, Balleyguier C, Muller S, et al. Evaluation of tumor angiogenesis of breast carcinoma using contrast-enhanced digital mammography. *AJR Am J Roentgenol* 2006;187(5):W528–W537.
 25. Lewin JM, Isaacs PK, Vance V, Larke FJ. Dual-energy contrast-enhanced digital subtraction mammography: feasibility. *Radiology* 2003;229(1):261–268.
 26. Dromain C, Thibault F, Muller S, et al. Dual-energy contrast-enhanced digital mammography: initial clinical results. *Eur Radiol* 2011;21(3):565–574.
 27. Fisher ER, Gregorio R, Redmond C, Vellios F, Sommers SC, Fisher B. Pathologic findings from the National Surgical Adjuvant Breast Project (protocol no. 4). I. Observations concerning the multicentricity of mammary cancer. *Cancer* 1975;35(1):247–254.
 28. Bleicher RJ, Ciocca RM, Egleston BL, et al. Association of routine pretreatment magnetic resonance imaging with time to surgery, mastectomy rate, and margin status. *J Am Coll Surg* 2009;209(2):180–187.
 29. Fisher B. Role of science in the treatment of breast cancer when tumor multicentricity is present. *J Natl Cancer Inst* 2011;103(17):1292–1298.
 30. Morrow M, Waters J, Morris E. MRI for breast cancer screening, diagnosis, and treatment. *Lancet* 2011;378(9805):1804–1811.